Burdenko's Journal of Neurosurgery
2026, No. 5, pp. 100–105
https://doi.org/10.17116/neiro2026900515100

Molecular diagnosis of non-syndromic craniosynostosis: new challenges for real clinical practice

© E.S. Makashova[1, 2], A.V. Efremova[3], L.A. Satanin[1], I.V. Kanivets[4, 5]

[1]Burdenko Neurosurgical Center, Moscow, Russia;
[2]Loginov Moscow Clinical Scientific Practical Center, Moscow, Russia;
[3]Bochkov Medical Genetic Research Center, Moscow, Russia;
[4]Russian Medical Academy of Continuous Professional Education, Moscow, Russia;
[5]Genomed LLC, Moscow, Russia

ABSTRACT

Craniosynostoses (CS) are a congenital malformation caused by absence or premature closure of skull sutures. This leads to deformation and impaired growth of skull. Traditionally, syndromic and non-syndromic forms are distinguished. For a long time, it was believed that molecular genetic mechanisms are significant exclusively for syndromic CS. However, clear data on involvement of somatic and germinal mutations in pathogenesis of non-syndromic forms were accumulated in recent years. Currently, there are no unified clinical guidelines defining the strategy for molecular genetic diagnosis for non-syndromic CS. This creates difficulties for neurosurgeons when choosing the optimal diagnostic method. The purpose of the article was to analyze modern ideas about effectiveness of various methods of molecular diagnosis of non-syndromic CS and to evaluate their role in routine clinical practice of neurosurgical departments.

Keywords: *craniosynostosis, non-syndromic craniosynostosis, whole exome sequencing, high-throughput parallel sequencing.*

INFORMATION ABOUT THE AUTHORS:
Makashova E.S. — https://orcid.org/0000-0003-2441-8818
Efremova A.V. — https://orcid.org/0000-0002-1360-7042
Satanin L.A. — https://orcid.org/0000-0003-2051-1855
Kanivets I.V. — https://orcid.org/0000-0003-0499-5167
Corresponding authors: Makashova E.S. — e-mail: emakashova@nsi.ru

TO CITE THIS ARTICLE:
Makashova ES, Efremova AV, Satanin LA, Kanivets IV. Molecular diagnosis of non-syndromic craniosynostosis: new challenges for real clinical practice. *Burdenko's Journal of Neurosurgery*. 2026;90(5):100–105. (In Russ.). https://doi.org/10.17116/neiro202690051100

Abbreviations
MPS — massively parallel sequencing
CS — craniosynostosis

Introduction

CS is a group of disorders characterized by congenital absence or premature closure of cranial sutures with abnormal skull development, deformities and potential neurological impairments [1]. There are syndromic and non-syndromic (isolated) forms of CS [2].

Syndromic CS is premature fusion of cranial sutures in context of genetic syndrome and accompanied by multiple congenital anomalies (craniofacial, skeletal, neurological, etc.) [3]. Unlike non-syndromic forms, syndromic CS has a distinct monogenic basis with autosomal dominant, recessive or X-linked inheritance. Non-syndromic CS typically involves premature closure of one or more cranial sutures without systemic anomalies. Among non-syndromic CS, sagittal suture synostosis is the most common followed by coronal and metopic synostosis [4]. According to recent data, the majority of non-syndromic CS have a hereditary etiology [2, 5]. Moreover, CS may not be the sole manifestation of disease.

Non-syndromic CS was traditionally recognized as only surgical issue requiring cranioplasty in all cases. However, modern genetic researches radically change this approach and demonstrate that specific molecular mechanisms often underlie "isolated" suture fusion. For instance, patients with genetic variants in genes associated with syndromic forms (e.g., FGFR2, TWIST1) and mild or atypical phenotype are at significantly higher risk of CS recurrence or postoperative intracranial hypertension. Thus, the cause of non-syndromic CS can be crucial for appropriate monitoring and treatment.

This article presents current data on molecular mechanisms underlying pathogenesis of CS and outlines molecular diagnostic algorithm for non-syndromic CS.

Common mechanisms underlying syndromic and non-syndromic CS

According to current data, syndromic CS follows a Mendelian inheritance pattern. They are associated with pathogenic variants in genes such as FGFR1, FGFR2, FGFR3, TWIST1, RAB23, EFNB1, TCF12, MSX2, POR and ERF [6—9]. CS associated with chromosomal abnormalities are less common. Available MPS and advanced detection of somatic variants enabled sequencing of various tissues and identification of somatic variants including in the same genes implicated in non-syndromic CS [9]. Somatic mosaicism implies ⩾ 2 genetically distinct cell populations in the same human resulting from post-zygotic genetic variants [10]. Unlike germline or constitutional mutations (variants), somatic mosaic variants may affect only specific organs. They are rarely transmitted to offspring (with the exception of somatic mosaicism co-occurring with gonadal mosaicism meaning the pathogenic variant is present in subset of germ cells). Thus, patients with somatic mosaicism possess healthy cells and cells with pathogenic variants, and mutated cells are potentially detectable only in affected tissues. Patients with mosaic variants may not have cardinal signs of disease, that complicates early diagnosis.

Twigg S.R.F. et al. [9] described 8 patients with Curry-Jones syndrome and mosaic variants in the SMO gene. All patients underwent MPS of affected and unaffected tissues. Coronal CS was observed in 4 (50%) cases. Notably, isolated coronal synostosis was the most common, whereas multiple synostoses are typical for constitutional variants. In at least one patient, coronal synostosis was a baseline sign of disease along with nonspecific cutaneous manifestations such as linear hypopigmented bands and toe syndactyly. Early diagnosis of Curry-Jones syndrome is crucial for appropriate treatment and follow-up considering high risk of malignant neoplasms.

Tønne E. et al. [7] found mosaic variants in 4 out of 381 cases. In one male, somatic variant in the EFNB1 gene resulted in craniofrontonasal dysplasia. Typically, males with this syndrome have only hypertelorism, whereas full phenotype occurs only in females. In other 3 cases, mosaic variants were detected in healthy parents of patients with syndromic craniosynostosis.

In 2007, Anderson P.J. et al. [11] attempted to detect somatic mosaicism in patients with non-syndromic craniosynostosis involving a single suture (sagittal, metopic, or unicoronal synostosis). However, the authors failed to identify pathogenic variants in the FGFR1, FGFR2, FGFR3 and TWIST genes in genomic DNA or DNA extracted from cultures of osteoprogenitor cells surgically excised from sutures. The authors also recommend further screening for genetic variants in genes associated with syndromic forms of craniosynostosis (MSX2 and ALX4) and in regulatory regions of the FGFR1, FGFR2, FGFR3 and TWIST genes. Furthermore, high incidence of non-syndromic forms of craniosynostosis may be due to epigenetic or environmental factors that requires further analysis.

According to some studies, there may be rare genetic variants in genes associated with syndromic forms of craniosynostosis in patients with non-syndromic craniosynostosis. For instance, various genetic variants in the TCF12 gene including nonsense variants, frameshift variants, microdeletions and duplications, as well as larger structural rearrangements were identified in patients with coronal craniosynostosis [12].

Interestingly, other carriers of these variants without symptoms of disease were identified in families of these patients. Perhaps, this may be due to the mechanism of haploinsufficiency (inability of healthy allele compensation) [13]. Furthermore, haploinsufficiency and incomplete penetrance may account for failure to detect pathogenic variants in patients with non-syndromic CS, as pathogenicity of a variant might be misjudged in segregation analysis. Identifying a variant of uncertain clinical significance in proband's parents together with insufficient data and scarcity of functional analysis in routine clinical practice can lead to erroneous attribution of causality when interpreting genetic results.

Many novel CS-associated genes are characterized by variable expressivity and incomplete penetrance. For example, numerous publications describe phenotypic heterogeneity associated with the Pro250Arg variant in the FGFR3 gene [14]. A mutation in this gene can result in severe Muenke syndrome with bilateral coronal suture synostosis, microcephaly and developmental delay, as well as may also be found in general population. In patients with FGFR, CS may be found in one parent or arise from a de novo pathogenic variant. In milder phenotypes (Muenke or Crouzon syndromes), inheritance of pathogenic variant from affected parent is common. Identifying the molecular-genetic cause of disease in a proband is essential for the family, as it enables analysis of genetic risk of recurrence among relatives and determination of the most effective preventive strategy. Other craniofacial anomalies within the same family were described for certain variants. This complicates analysis of variant causality.

New genes associated with non-syndromic craniosynostosis

Searching for new genes associated with non-syndromic craniosynostosis is a key area in modern molecular diagnosis and neurosurgery. Over the past decade, several new genes whose mutations were associated with sagittal and coronal non-syndromic CS were identified. In 2012, Justice C.M. et al. [14] described sagittal CS resulting from variants in the BMP2 and BBS9 genes. A year later, Twigg S.R.F. et al. and Sharma V.P. et al. [9, 15] reported unilateral or bilateral coronal CS associated with variants in the TCF12 and ERF genes in patients with syndromic and non-syndromic CS.

The TCF12 gene encodes transcription factor 12. The last one is expressed in the nuclei of stem cells. It is es-

Genes associated with non-syndromic craniosynostosis

Non-syndromic craniosynostosis	
Gene	Synostosis
SMAD6	Sagittal
TCF12	Sagittal, unilateral or bilateral coronal
ERF	Sagittal, lambdoid, coronal

sential for osteoblast differentiation [16]. Patients with syndromic CS and TCF12 mutation can have various anomalies of facial skull, external ear and limbs, whereas non-syndromic CS may manifest as isolated coronal CS [17]. According to current data, TCF12 variants account for up to 32% of all cases of bilateral coronal synostosis and 10% of unilateral coronal synostosis. Furthermore, TCF12 is a heterodimer of several other transcription factors, including TWIST1 encoding class A 38 basic helix-loop-helix protein. The last one influences cellular differentiation and regulates osteogenesis [18, 19]. Mutations in the TWIST1 gene lead to Saethre-Chotzen syndrome with limb anomalies and coronal craniosynostosis [18]. The TCF12—TWIST1 heterodimer likely regulates structure of coronal suture between frontal bones (arising from neural crest) and parietal bones (arising from mesoderm). These dimers appear to inhibit osteoblast differentiation by modulating the RUNX2 and FGFR signaling pathways [15].

Patients with ERF gene mutations may present with either syndromic (Chiari malformation, psychomotor and speech developmental delays, craniofacial anomalies) or non-syndromic cases (with exclusively sagittal, unilateral or bilateral lambdoid or multiple-suture synostosis) [20, 21].

Data on genes implicated in pathogenesis of non-syndromic craniosynostosis are summarized **(Table)** [1, 8, 9].

Diagnostic algorithm for patients with non-syndromic craniosynostosis

In real-world clinical practice, optimal sequence of molecular genetic tests is crucial for diagnostic efficiency. An ideal approach should maximize variant detection while minimizing duration of diagnostic process and financial burden on the family. Considering new data regarding incomplete penetrance and consequent limitations of segregation analysis, bioinformatic analysis with a thorough phenotypic assessment of proband and family members to rule out other craniofacial anomalies becomes important. Currently, there is no clear evidence comparing efficacy of targeted gene panels versus whole-exome sequencing. Chen J. et al. [22] evaluated incremental diagnostic yield of whole-exome sequencing in identifying causative variants in patients with syndromic and non-syndromic craniosynostosis. The study included 264 patients (163 ones with syndromic and 101 ones with non-syndromic craniosynostosis) who underwent sequencing of genes (FGFR2, FGFR3, TWIST1, EFNB1, TCF12, SKI, RAB23, FGFR1, TGFBR2, POR, SMAD3, ERF, TGFBR1, MSX2, RECQL4, TGFB2 and IFT43) associated with CS and whole-exome sequencing for negative results of panel sequencing. Panel sequencing identified pathogenic or likely pathogenic variant in 52.7% (139/264) of cases. Whole-exome sequencing identified pathogenic or likely pathogenic variant in other 10 patients. Thus, incremental diagnostic yield of whole-exome sequencing was 3.8%. Taking into account different costs of testing, the authors note higher cost-effectiveness of targeted gene panel testing compared to whole-exome sequencing despite slightly lower diagnostic value.

Gaillard L. et al. [21] analyzed molecular diagnostic results in 502 patients with craniosynostosis who underwent various combinations of chromosomal microarray analysis, targeted gene panel testing, whole-exome sequencing, hotspot sequencing, and MLPA (multiplex ligation-dependent probe amplification). Targeted gene panel testing and chromosomal microarray analysis demonstrated the highest diagnostic yield.

According to the Erasmus University recommendations on craniosynostosis, all patients with CS should undergo molecular genetic testing. However, specific testing algorithm and scope are not defined [18].

The University of Mexico guidelines [19] recommend molecular genetic testing of the FGFR2, FGFR3 and TWIST1 genes for all children with unilateral or bilateral coronal synostosis. Hotspot analysis is recommended to rule out common FGFR2 and FGFR3 mutations, while TWIST1 gene analysis is not specified. This recommendation is based on poorer postoperative outcomes in patients with TWIST1 gene variants. However, there are no precise recommendations regarding optimal method for identifying variants in this gene.

In our opinion, targeted gene panel sequencing as a first-line approach is advisable considering high incidence of single-nucleotide variants. Since somatic mosaicism is theoretically possible in CS patients, it is appropriate to perform targeted gene panel sequencing using DNA extracted from bone tissue within CS site. Whole-

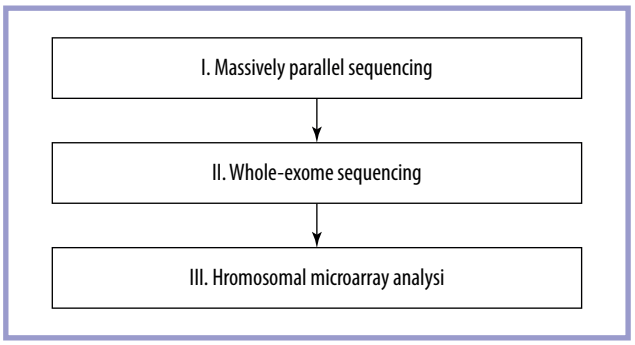

Algorithm for DNA diagnosis.

genome sequencing may be performed as the second stage for patients with negative results of gene panel sequencing and typical signs of syndromic CS. As the third step, chromosomal microarray analysis can be conducted to detect chromosomal abnormalities **(Figure)**.

Importantly, the term "non-syndromic CS" is arbitrary and, moreover, outdated in light of current data on pathogenesis of syndromic and non-syndromic CS. New data on molecular mechanisms underlying non-syndromic CS indicate necessary revision of the concept of CS. On one hand, gene mutations and chromosomal aberrations are the primary mechanisms of non-syndromic CS. On the other hand, different variants within the same genes can lead to either syndromic or non-syndromic CS. Thus, distinguishing non-syndromic CS appears redundant and fails to accurately reflect pathogenesis of disease.

Conclusion

Molecular genetic diagnosis of craniosynostosis is currently a significant issue. In view of incomplete penetrance for several diseases, identifying the genetic cause of CS is crucial for prevention of recurrence in families. Furthermore, different efficacy of surgical treatment in patients with mutations in different genes underscores the need for rapid and available diagnostic testing for various patients. Data on capabilities of various methods for identifying causative variants in non-syndromic craniosynostosis are currently presented in small cohort studies that often lack comparative analyses of efficacy. Targeted panels may improve detection of causative variants, but further data are required to confirm their advantages over whole-exome sequencing.

Thus, integration of molecular genetic diagnosis into neurosurgical practice could enhance personalized treatment and reduce the incidence of redo surgical interventions.

Author contribution:
Concept and design of the study — Satanin L.A.
Collection and analysis of data — Efremova A.V., Makashova E.S.
Writing the text — Efremova A.V., Makashova E.S.
Editing — Satanin L.A., Kanivets I.V.

No conflict of interests to declare.

REFERENCES

1. Albaugh SL, Diaz A, Wang E, Shen TC, Williams L, He TC, Reid RR. Systematic Review of Nonsyndromic Craniosynostosis: Genomic Alterations and Impacted Signaling Pathways. *Plastic and Reconstructive Surgery.* 2024;153(2):383e-396e. https://doi.org/10.1097/PRS.0000000000010522
2. Alperovich M, Tonello C, Mayes LC, Kahle KT. Non-syndromic craniosynostosis. *Nature Reviews Disease Primers.* 2025;11(1):24. https://doi.org/10.1038/s41572-025-00607-4
3. Musolf AM, Justice CM, Erdogan-Yildirim Z, Goovaerts S, Cuellar A, Shaffer JR, Marazita ML, Claes P, Weinberg SM, Li J, Senders C, Zwienenberg M, Simeonov E, Kaneva R, Roscioli T, Di Pietro L, Barba M, Lattanzi W, Cunningham ML, Romitti PA, Boyadjiev SA. Whole genome sequencing identifies associations for nonsyndromic sagittal craniosynostosis with the intergenic region of *BMP2* and noncoding RNA gene *LINC01428*. *Scientific Reports.* 2024;14(1):8533. https://doi.org/10.1038/s41598-024-58343-w
4. Malagón-Hidalgo HO, Monroy-Cedillo JL. Fundamentals of Non-Syndromic Craniosynostosis. In: De-Luna-Gallardo D, Marquez-Espriella C, Cienfuegos-Monroy R, eds. *Plastic and Reconstructive Surgery Fundamentals.* Cham: Springer; 2024. https://doi.org/10.1007/978-3-031-61894-9_23
5. Marbate T, Kedia S, Gupta DK. Evaluation and Management of Nonsyndromic Craniosynostosis. *Journal of Pediatric Neurosciences.* 2022;17(Suppl 1):S77-S91. https://doi.org/10.4103/jpn.JPN_17_22
6. Jabs EW, Lewanda AF. Craniosynostosis. In: Rimoin DL, Pyeritz RE, Korf BR, eds. *Emery & Rimoin's principles and practice of medical genetics.* London: Elsevier; 2013.
7. Tønne E, Due-Tønnessen BJ, Mero IL, Wiig US, Kulseth MA, Vigeland MD, Sheng Y, von der Lippe C, Tveten K, Meling TR, Helseth E, Heimdal KR. Benefits of clinical criteria and high-throughput sequencing for diagnosing children with syndromic craniosynostosis. *European Journal of Human Genetics.* 2021;29(6):920-929. https://doi.org/10.1038/s41431-020-00788-4
8. Bukowska-Olech E, Sowińska-Seidler A, Larysz D, Gawliński P, Koczyk G, Popiel D, Gurba-Bryśkiewicz L, Materna-Kiryluk A, Adamek Z, Szczepankiewicz A, Dominiak P, Glista F, Matuszewska K, Jamsheer A. Results from Genetic Studies in Patients Affected with Craniosynostosis: Clinical and Molecular Aspects. *Frontiers in Molecular Biosciences.* 2022;9:865494. https://doi.org/10.3389/fmolb.2022.865494
9. Twigg SRF, Hufnagel RB, Miller KA, Zhou Y, McGowan SJ, Taylor J, Craft J, Taylor JC, Santoro SL, Huang T, Hopkin RJ, Brady AF, Clayton-Smith J, Clericuzio CL, Grange DK, Groesser L, Hafner C, Horn D, Temple IK, Dobyns WB, Curry CJ, Jones MC, Wilkie AOM. A Recurrent Mosaic Mutation in *SMO*, Encoding the Hedgehog Signal Transducer Smoothened, Is the Major Cause of Curry-Jones Syndrome. *The American Journal of Human Genetics.* 2016;98(6):1256-1265. https://doi.org/10.1016/j.ajhg.2016.04.007
10. Coorens THH, Oh JW, Choi YA, Lim NS, Zhao B, Voshall A, Abyzov A, Antonacci-Fulton L, Aparicio S, Ardlie KG, Bell TJ, Bennett JT, Bernstein BE, Blanchard TG, Boyle AP, Buenrostro JD, Burns KH, Chen F, Chen R, Choudhury S, Doddapaneni HV, Eichler EE, Evrony GD, Faith MA, Fazzio TG, Fulton RS, Garber M, Gehlenborg N, Germer S, Getz G, Gibbs RA, Hernandez RG, Jin F, Korbel JO, Landau DA, Lawson HA, Lennon NJ, Li H, Li Y, Loh PR, Marth G, McConnell MJ, Mills RE, Montgomery SB, Natarajan P, Park PJ, Satija R, Sedlazeck FJ, Shao DD, Shen H, Stergachis AB, Underhill HR, Urban AE, VonDran MW, Walsh CA, Wang T, Wu TP, Zong C, Lee EA, Vaccarino FM; Somatic Mosaicism across Human Tissues Network. The Somatic Mosaicism across Human Tissues Network. *Nature.* 2025;643(8070):47-59. https://doi.org/10.1038/s41586-025-09096-7
11. Anderson PJ, Cox TC, Roscioli T, Elakis G, Smithers L, David DJ, Powell B. Somatic *FGFR* and *TWIST* mutations are not a common cause of isolated nonsyndromic single suture craniosynostosis. *Journal of Craniofacial Surgery.* 2007;18(2):312-314. https://doi.org/10.1097/scs.0b013e31802d6e76
12. Foss-Skiftesvik J, Larsen CC, Stoltze UK, Kofod T, Hove H, Bøgeskov L, Østergaard E. The role of pathogenic *TCF12* variants in children with coronal craniosynostosis-a systematic review with addition of two novel cases. *Child's Nervous System.* 2024;40(11):3655-3671. https://doi.org/10.1007/s00381-024-06544-z
13. Yu JW, Yoon JG, Han C, Noh SH, Shin DM, Yang YM, Kim YO, Shim KW, Lee MG. Digenic impairments of haploinsufficient genes in patients with craniosynostosis. *JCI Insight.* 2025;10(4):e176985. https://doi.org/10.1172/jci.insight.176985

14. Justice CM, Yagnik G, Kim Y, Peter I, Jabs EW, Erazo M, Ye X, Ainehsazan E, Shi L, Cunningham ML, Kimonis V, Roscioli T, Wall SA, Wilkie AO, Stoler J, Richtsmeier JT, Heuzé Y, Sanchez-Lara PA, Buckley MF, Druschel CM, Mills JL, Caggana M, Romitti PA, Kay DM, Senders C, Taub PJ, Klein OD, Boggan J, Zwienenberg-Lee M, Naydenov C, Kim J, Wilson AF, Boyadjiev SA. A genome-wide association study identifies susceptibility loci for nonsyndromic sagittal craniosynostosis near *BMP2* and within *BBS9*. *Nature Genetics*. 2012;44(12):1360-1364. https://doi.org/10.1038/ng.2463

15. Sharma VP, Fenwick AL, Brockop MS, McGowan SJ, Goos JA, Hoogeboom AJ, Brady AF, Jeelani NO, Lynch SA, Mulliken JB, Murray DJ, Phipps JM, Sweeney E, Tomkins SE, Wilson LC, Bennett S, Cornall RJ, Broxholme J, Kanapin A; 500 Whole-Genome Sequences (WGS500) Consortium; Johnson D, Wall SA, van der Spek PJ, Mathijssen IM, Maxson RE, Twigg SR, Wilkie AO. Mutations in *TCF12*, encoding a basic helix-loop-helix partner of TWIST1, are a frequent cause of coronal craniosynostosis. *Nature Genetics*. 2013;45(3):304-307. https://doi.org/10.1038/ng.2531

16. Cao LR, Zhang C, Deng ZQ, Qiu YX, Zhang Z, Fan HY, Li J, Wu HB. Transcription Factor TCF12-Mediated Maternal Gene Expressions in Mouse Oocyte Are Prerequisites of Successful Fertilisation and Zygotic Genome Activation. *Cell Proliferation*. 2026;59(3):e70110. https://doi.org/10.1111/cpr.70110

17. Choi TM, Bruggink R, Hoekstra JWM, Mathijssen IMJ, Wolvius EB, Ongkosuwito EM. Semi-automated three-dimensional analysis of maxillary anomalies in patients with Muenke syndrome, Saethre-Chotzen syndrome or *TCF12*-related craniosynostosis: A retrospective study. *Journal of Cranio-Maxillofacial Surgery*. 2025;53(8):1205-1212. https://doi.org/10.1016/j.jcms.2025.04.008

18. Faasse M, Mathijssen IMJ; ERN CRANIO Working Group on Craniosynostosis. Guideline on Treatment and Management of Craniosynostosis: Patient and Family Version. *Journal of Craniofacial Surgery*. 2023;34(1):418-433. https://doi.org/10.1097/SCS.0000000000009143

19. Castro Coyotl DM, Rosas Huerta XO, Sánchez Vázquez JJ, Díaz Sánchez MI, Rodríguez Peralta JS, Tetitla Munive JM, Peralta Porras ML, Arellano Cruz AJ, Sosa García JO, Fareli González CJ. Guía de práctica clínica para el diagnóstico, tratamiento y rehabilitación de craneosinostosis no sindrómica en los 3 niveles de atención [Guide to clinical practice for the diagnosis, treatment and rehabilitation of non-syndromic craniosynostosis on 3 levels of care]. *Cirugía y Cirujanos*. 2017;85(5):401-410. (In Spanish). https://doi.org/10.1016/j.circir.2016.10.028

20. Glass GE, O'Hara J, Canham N, Cilliers D, Dunaway D, Fenwick AL, Jeelani NO, Johnson D, Lester T, Lord H, Morton JEV, Nishikawa H, Noons P, Schwiebert K, Shipster C, Taylor-Beadling A, Twigg SRF, Vasudevan P, Wall SA, Wilkie AOM, Wilson LC. *ERF*-related craniosynostosis: The phenotypic and developmental profile of a new craniosynostosis syndrome. *American Journal of Medical Genetics — Part A*. 2019;179(4):615-627. https://doi.org/10.1002/ajmg.a.61073

21. Gaillard L, Goverde A, Weerts MJA, de Klein A, Mathijssen IMJ, Van Dooren MF. Genetic diagnostic yield in an 11-year cohort of craniosynostosis patients. *European Journal of Medical Genetics*. 2023;66(10):104843. https://doi.org/10.1016/j.ejmg.2023.104843

22. Chen J, Zhang P, Peng M, Liu B, Wang X, Du S, Lu Y, Mu X, Lu Y, Wang S, Wu Y. An additional whole-exome sequencing study in 102 panel-undiagnosed patients: A retrospective study in a Chinese craniosynostosis cohort. *Frontiers in Genetics*. 2022;13:967688. https://doi.org/10.3389/fgene.2022.967688

Received 03.03.2026
Reviced 29.05.2026
Accepted 20.07.2026