Burdenko's Journal of Neurosurgery
2026, No. 5, pp. 90–99
https://doi.org/10.17116/neiro202690051590

Paragangliomas of the head and neck: diagnosis and treatment. Part 1. Epidemiology and diagnosis

© A.D. Akhmedov, V.A. Lukshin, S.V. Zolotova, D.S. Kim, D.R. Rustamova, D.Yu. Usachev

Burdenko Neurosurgery Center, Moscow, Russia

ABSTRACT

Background. Head and neck tumors cross several clinical specialties. Diagnostic and treatment approaches vary significantly depending on specialty, and there is no a unified diagnostic standard for paragangliomas in these areas. In this report, we summarize available data on these tumors and present own patient evaluation protocol.

Objective. To systematize modern information on epidemiology, pathogenesis and diagnosis of paragangliomas.

Material and methods. We present literature review and retrospective analysis of instrumental and laboratory data of patients with head and neck paragangliomas.

Results. We analyzed modern diagnostic methods: imaging (Doppler ultrasound, CT, MRI, PET CT), biochemical (catecholamines and their metabolites), and molecular genetic (mutation testing) tests. Advantages and limitations of each method were identified. We also present optimal algorithms for their combination for early and accurate disease detection.

Conclusion. This analysis systematized the approach to diagnostic algorithm for patients with head and neck paragangliomas. The capabilities of modern imaging methods allow for identification of potentially malignant and familial forms of disease, which are fundamentally different from sporadic forms. Available data underlie a differentiated approach to treatment strategy. This positively impacts treatment outcomes. This aspect will be discussed in the second part of the article.

Keywords: *paraganglioma, chemodectoma, neurovascular bundle, SDHx mutations.*

INFORMATION ABOUT THE AUTHORS:
Akhmedov A.D. — https://orcid.org/0000-0001-5780-8519
Lukshin V.A. — https://orcid.org/0000-0001-5787-484X
Zolotova S.V. — https://orcid.org/0000-0001-8893-3830
Kim D.S. — https://orcid.org/0000-0003-2354-6930
Rustamova D.R. — https://orcid.org/0009-0005-6716-6456
Usachev D.Yu. — https://orcid.org/0000-0002-9811-9442
Corresponding authors: Rustamova D.R. — e-mail: Rustamova@nsi.ru, Akhmedov A.D. — e-mail: AAhmedov@nsi.ru

TO CITE THIS ARTICLE:
Akhmedov AD, Lukshin VA, Zolotova SV, Kim DS, Rustamova DR, Usachev DYu. Paragangliomas of the head and neck. Epidemiology and diagnosis. *Burdenko's Journal of Neurosurgery*. 2026;90(5):90–99. (In Russ.). https://doi.org/10.17116/neiro20269005190

Introduction

Head and neck paragangliomas account for up to 0.6% of all neoplasms in this region and up to 50% of all paragangliomas. The risk of malignant transformation is estimated at 3—5%, risk of hormonal activity — at 1—3% [1]. Paragangliomas can occur at any age, though the peak incidence falls within 4-6 decades of life. Notably, one-third of these tumors are hereditary and clearly associated with genetic mutations. The 5-year survival rate does not exceed 50% in patients with metastases regardless of sporadic or hereditary nature of disease [2—4]. Neurosurgeons, oncologists, vascular surgeons, otolaryngologists, maxillofacial surgeons, and radiologists are involved in diagnosis and treatment of paragangliomas. However, there is still no a unified interdisciplinary approach to management of these patients.

The purpose of this study was to develop a unified diagnostic algorithm for patients with paragangliomas by systematizing current data on epidemiology, pathogenesis and diagnostic methods, while accounting for multidisciplinary nature of disease and the need to minimize the risk of neurological complications.

Epidemiology

The annual incidence of paragangliomas is 1—3 cases per 100.000. All paragangliomas possess metastatic potential; 5—15% of tumors follow malignant course. Neoplasms associated with SDHB mutations demonstrate the most aggressive metastatic behavior with metastasis rates reaching 50% [1]. Primary diagnosis typically occurs between 40 and 50 years, although hereditary forms may manifest at earlier age. The female-to-male ratio is approximately 2:1. Paragangliomas may be associated with some syndromic disorders: multiple endocrine neoplasia

(MEN 2A, MEN 2B), von Hippel-Lindau disease, hereditary paraganglioma / pheochromocytoma syndromes (mutations in succinate dehydrogenase complex genes SDHD, SDHB, SDHC, SDHA), and Carney-Stratakis syndrome (SDHB / SDHD) [2, 4, 5].

Paragangliomas are predominantly located along glossopharyngeal and vagus nerves, in carotid body, middle ear, jugular foramen, nodose ganglion, larynx and along cervical sympathetic chain (i.e. any region containing parasympathetic or sympathetic paraganglionic tissue). Among all paragangliomas, carotid forms account for up to 70%, vagal forms — 10—15%, jugular forms — 10%, tympanic forms — no more than 5% [6].

Carotid paragangliomas

Carotid body paragangliomas arise at bifurcation of common carotid artery, primarily from chemoreceptors ("chemodectoma"). The annual incidence of this specific localization is 1—2 cases per 100.000. The Shamblin classification [7] is used to assess surgical risk of internal carotid artery (ICA) injury. This classification takes into account tumor size and vascular wall involvement. Three types are distinguished:

1) type I — the tumor involves only one wall of ICA;
2) type II — the tumor encompasses more than one wall but does not encircle the vessel;
3) type III — the tumor circumferentially encases all ICA walls with surrounding nerves potentially located in neoplasm.

Type III is further subdivided into two subgroups:

a) IIIa — intact ICA segment between tumor and skull base;
b) IIIb — tumor extending to the skull base **(Fig. 1)**.

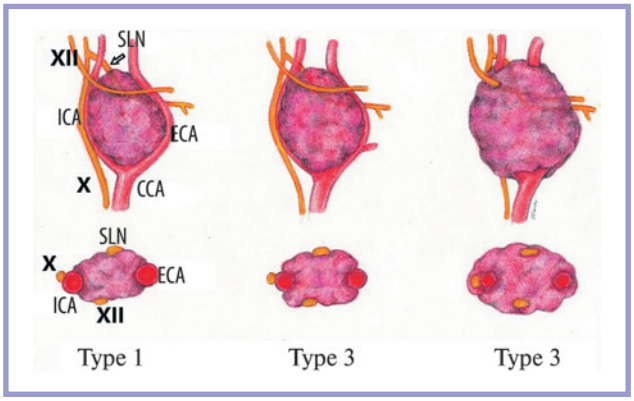

Fig. 1. **Variants of carotid body paragangliomas depending on involvement of surrounding vessels and nerves (illustration by Lyutova M.A.).**
SLN — superior laryngeal nerve; X — vagus nerve; XII — hypoglossal nerve; ICA — internal carotid artery; ECA — external carotid artery; CCA — common carotid artery.

Vagus nerve paraganglioma (vagal paraganglioma)

The incidence is 0.1—0.3 cases per 100.000. The tumor may be located at any point along the vagus nerve but predominantly arises from inferior (nodose) or plexiform ganglion (more cranially) **(Fig. 2)**. ECA and ICA displacement is a typical topographic-anatomical feature. Paraganglioma at the level or below CCA bifurcation displaces the arteries anteriorly. Higher tumor localization displaces these structures anteriorly and laterally. Vagal paragangliomas tend to extend towards skull base and, in some cases, grow intracranially through jugular foramen [8].

Jugular paraganglioma

This tumor arises from paraganglia of jugular glomus, and it is invariably located within jugular foramen. The tumor is characterized by aggressive local growth

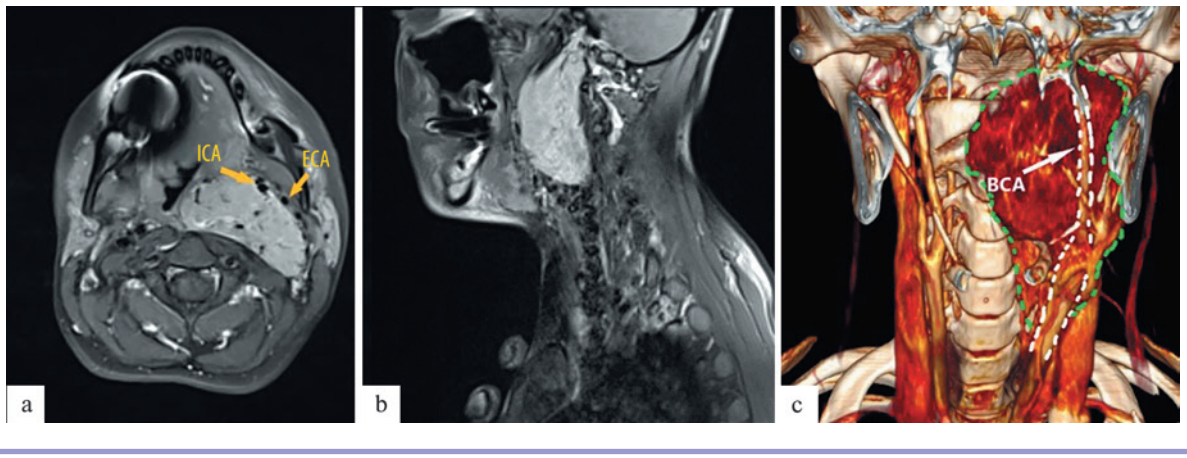

Fig. 2. **Vagus nerve paraganglioma arising from its inferior ganglion. MR and CT angiography demonstrating tumor-induced anterior and lateral displacement of internal and external carotid arteries.**
a — MRI of soft tissues of the neck, axial scan; b — MRI of soft tissues of the neck, sagittal scan; c — 3D CT angiography of the head and neck, anterior scan.

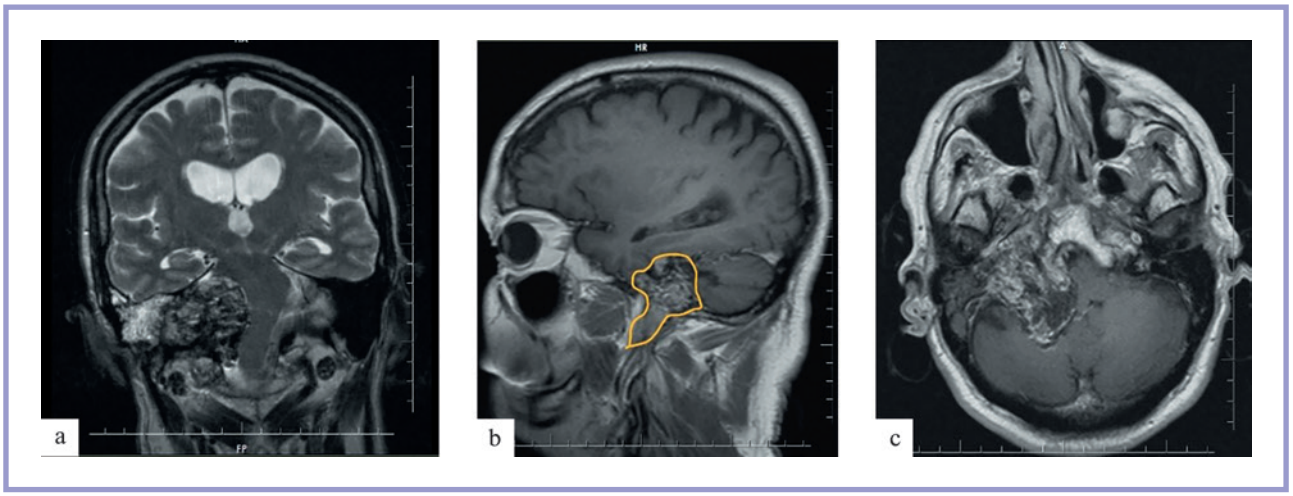

Fig. 3. **MRI of a patient with recurrent jugular paraganglioma 10 years after primary diagnosis. The patient underwent partial resections followed by multiple partial tumor embolization.**
No radiotherapy was administered. MRI demonstrates neoplasm extending both intracranially and extracranially. a — MRI of the head and neck, coronal scan; b — MRI of the head and neck, sagittal scan; the tumor growing from jugular foramen in both directions is outlined; c — MRI of the head and neck, axial scan.

with frequent bone destruction, extracranial and intracranial spread **(Fig. 3)**. The incidence is 0.1—0.3 cases per 100.000 [9, 10].

Tympanic paraganglioma

This tumor arises from Jacobson's nerve or tympanic plexus. It is less common than other tumors (0.05—0.1 per 100.000) and characterized by the most benign and slow-growing behavior [9] **(Fig. 4)**.

Multiple paragangliomas

Hereditary forms are characterized by multiple lesions. These may be bilateral carotid tumors, combination of carotid and vagal locations or combination of paraganglioma with pheochromocytoma. Carotid body paragangliomas are usually sporadic, while vagal and jugular tumors are more frequently associated with hereditary factors. For instance, a neoplasm may simultaneously demonstrate features of carotid and vagal paragangliomas, or examination reveals contralateral lesions **(Fig. 5)** [11].

Malignant paragangliomas

Metastases are the primary (and absolute) criterion of malignant paraganglioma. Liver, lung, bone and lymph node metastases are the most common [5]. Hereditary forms are characterized by higher risk of multiple lesions and, in specific mutations, higher risk of metastasis. In particular, the 5-year survival rate for patients with metastases and SDHB gene mutation reaches 50% [11].

Molecular classification

Hereditary forms of paraganglioma are identified in 40% of cases and associated with some genetic syndromes, including von Hippel-Lindau disease and neurofibromatosis type 1. To date, 15 genes involved in pathogenesis of paraganglioma are identified. Germline and somatic mutations account for 40% and 30% of cases, respectively [2]. Paragangliomas are predominantly associated with pseudohypoxic molecular cluster. Mean age of patients with mutations in SDHA, SDHB, SDHC, SDHD and SDHAF2 genes is approximately 30 years. SDHB mutation carriers have a 23—25% risk of metastases [12]. SDHB mutations are the strongest predictor of potential metastases. Therefore, even if metastases are absent upon examination, close long-term follow-up is mandatory.

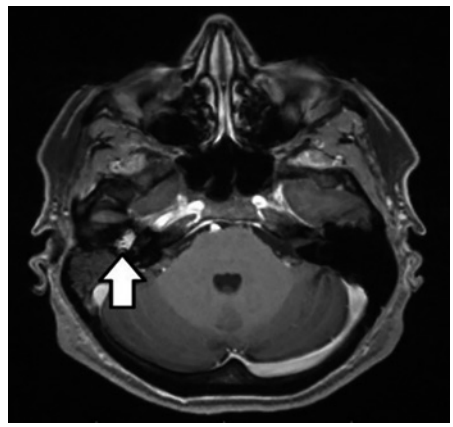

Fig. 4. **Tympanic paraganglioma. Contrast-enhanced MRI of the brain in a patient with tympanic paraganglioma.**

Carriers of SDHD / SDHAF2 mutations are at the highest risk of multiple paragangliomas [13, 14].

Clinical presentation

Head and neck paragangliomas most commonly manifest as a mass in the neck or oropharynx, sometimes accompanied by throat discomfort, foreign-body sensation or difficult swallowing. Dysphagia, nasal speech, hoarseness, snoring and sleep apnea can follow tumor growth. Otologic symptoms arise after tumor-induced obstruction of Eustachian tube. In rare cases, paragangliomas can trigger symptoms of catecholamine hypersecretion: sustained hypertension or blood pressure instability, headaches, episodes of profuse sweating, palpitations, skin pallor and feelings of anxiety or fear.

Early diagnosis is challenging. Indeed, parapharyngeal masses become palpable only when they reach a size of 2.5—3 cm or larger [3, 15].

Diagnosis

Evaluation of patients with suspected paraganglioma should be comprehensive and achieve several key objectives:

1) verification — confirmation of tumor and its nature as paraganglioma;
2) extent of disease — solitary or multiple lesions;
3) distant metastases — screening for potential secondary sites;
4) hormonal status — catecholamine activity of tumor;

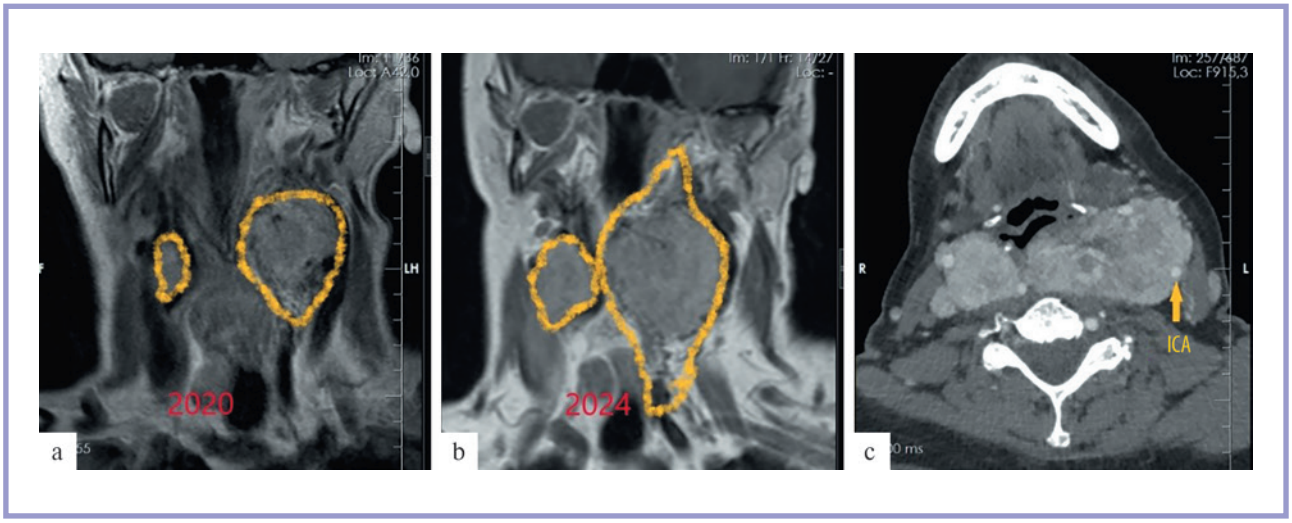

Fig. 5. **Multiple paragangliomas. Tumor size changes over a 4-year period without treatment.**
a — MRI of soft tissues of the neck, coronal scan, paragangliomas near the right and left neurovascular bundles, 2020; b — MRI of soft tissues of the neck, coronal scan, paragangliomas near right and left neurovascular bundles, 2024; c — CT angiography of the neck, axial scan. Tumor-induced ICA displacement posteriorly and laterally.

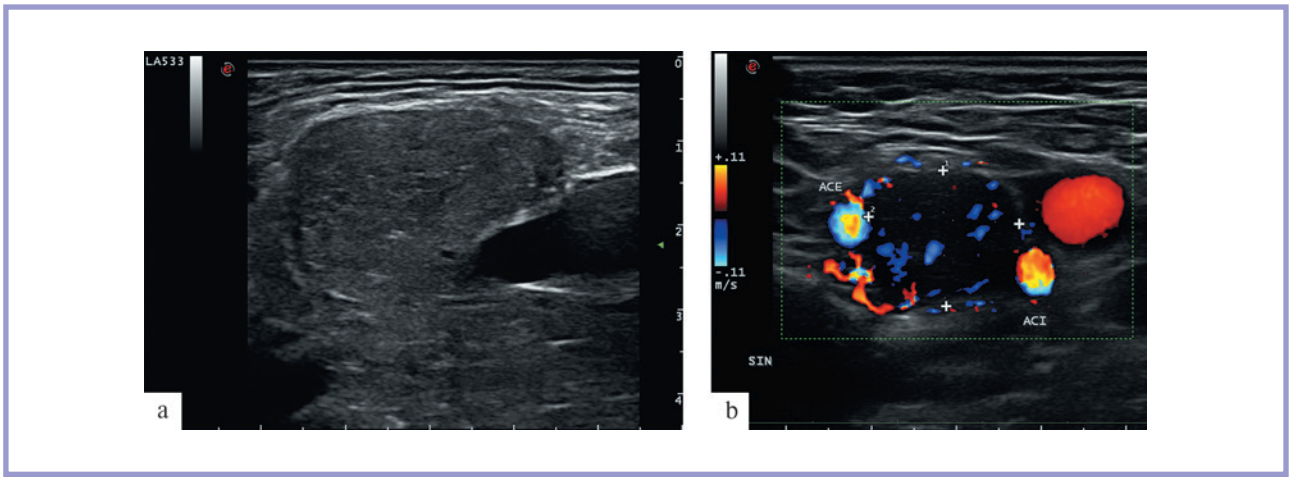

Fig. 6. **Ultrasound in a patient with carotid body paraganglioma.**
a hypoechoic, well-defined solid neoplasm (a) displacing internal and external carotid arteries and demonstrating active blood flow (Doppler mode) (b).

5) molecular genetic testing — screening for germline mutations to determine hereditary nature of disease and prognosis.

Laboratory tests

Elevated serum or urinary metanephrine is usually not typical for paraganglioma. However, these findings can indicate multifocal tumors [3, 16].

Clinical guidelines mandate genetic testing for all patients with paraganglioma. This is due to high prevalence of hereditary forms (up to 40% of cases) and prognostic significance of mutations. About 25% of patients with SDHB gene mutation will have distant metastases. Identification of hereditary predisposition in familial cases enables early tumor screening among relatives.

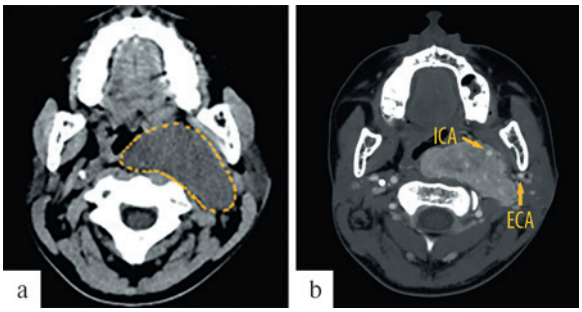

Fig. 7. **CT of a patient with vagal paraganglioma.**
a — imaging without contrast enhancement (homogeneous, solid, well-defined mass); b — active contrast enhancement (arrows indicate internal and external carotid arteries).

Ultrasound

Ultrasound is often a baseline diagnostic modality for patients presenting with a neck mass. Ultrasound visualizes paraganglioma as a solid, well-defined, hypoechoic mass with heterogeneous structure and multiple stromal vessels **(Fig. 6)**.

CT

On CT images without contrast enhancement, paraganglioma appears as a well-defined mass. Its density is comparable to that of the sternocleidomastoid muscle **(Fig. 7)**. Calcifications may be present inside the tumor. Contrast agent administration is followed by intense, homogeneous and rapid enhancement in early arterial phase (almost simultaneously with carotid artery imaging). Early contrast washout resulting from active venous drainage is also typical. CT angiography allows for assessment of topographic-anatomic relationship with surrounding arteries and veins, blood supply and venous drainage pathways. CT bone-window settings are useful to detect bone destruction in patients with high tumors.

MRI and MR angiography

MRI is a primary diagnostic modality for paraganglioma. T1WIs visualize paraganglioma as isointense, well-defined and solid mass; T2WIs demonstrate hyperintense signal with “salt and pepper” sign caused by high blood flow inside the tumor. This phenomenon is typical for paragangliomas >1 cm, but it is not pathognomonic and may be found in other vascularized tumors. The tumor

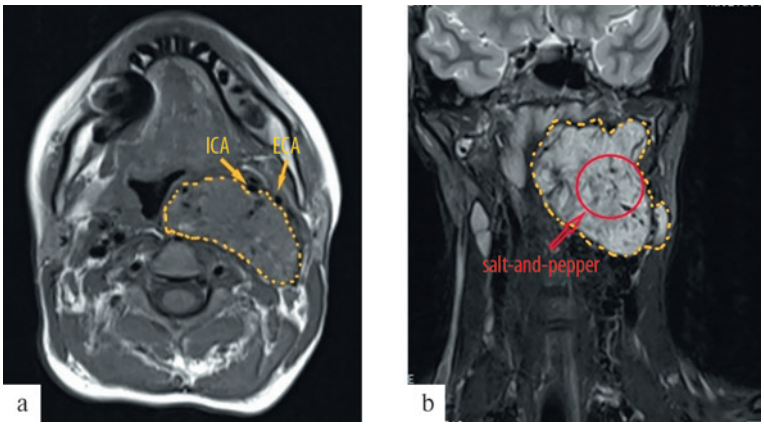

Fig. 8. **MRI of a patient with vagal nerve paraganglioma.**
a — T1WI without contrast enhancement: isointense solid tumor with well-defined margins; b — T2WI without contrast enhancement: hyperintense tumor with well-defined margins and “salt-and-pepper” sign (red circle) indicative of abundant pathological vasculature.

***Table*. Tumor blood flow, mean transit time, tumor blood volume and vascular permeability in tumor tissue among patients with various tumors of cervical neurovascular bundle (31 patients).**

	TBF, ml/100 g/min			MTT, s			TBV, ml/100 g			PS, ml/100g/min		
Tumors (*n*)	Min	Max	Me	Min	Max	Me	Min	Max	Me	Min	Max	Me
Adenomas (4)	12	70	40.9	7	13	9.23	2.4	7	4.1	20.6	31	25.6
Schwannomas (11)	23	68.6	46.8	4.5	10.2	7.75	1.6	8	3.86	0.6	28.6	18.2
Paragangliomas (9)	190	816	602.7	2.6	7.1	4.3	9.1	72	45.2	0.01	9.7	3.91
Pseudotumor (1)		39			7			2.6				
Lymphoepithelial cyst (1)		136			8.7			17			14	
Cavernous malformation (1)		91.65			17.57			22.54			7.1	
Chondrosarcoma (1)		58			5.84			3			18.85	
Solitary fibrous tumor (1)		325			6			25			21	
Venous hemangioma (1)		43			14.6			8			91	
Lipoma (1)		13			–			–			–	

Note: TBF — tumor blood flow; MTT — mean transit time; TBV — tumor blood volume; PS — vascular permeability.

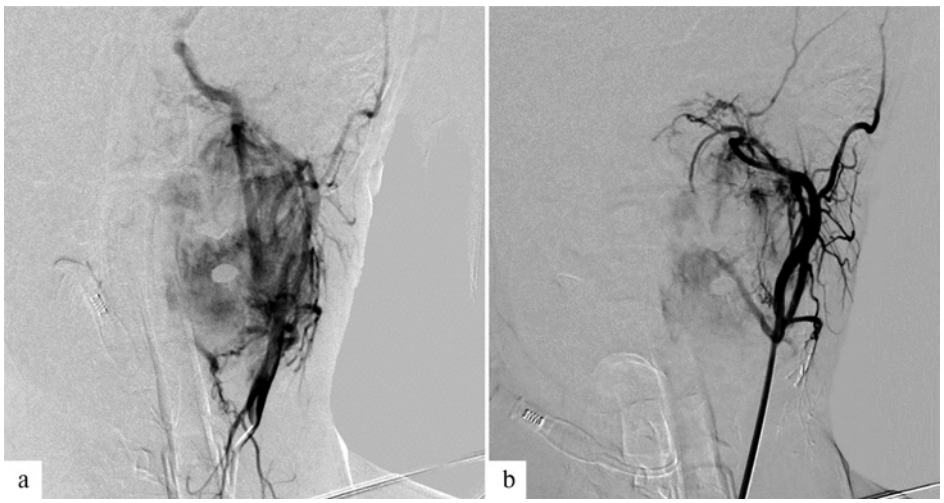

***Fig. 9.* Angiography of a patient with vagal nerve paraganglioma.**
a — before embolization, b — after successful partial embolization.

avidly accumulates gadolinium, that is valuable for detection of small lesions **(Fig. 8)**.

Direct angiography

Direct angiography is used to assess cerebrovascular reserve, perform balloon occlusion tests and preoperative tumor embolization [15]. There is currently no consensus regarding preoperative tumor embolization, and each case requires individual approach. Embolization is rare for carotid paragangliomas, whereas it is more common for subcranial tumor extension or vagal location **(Fig. 9)**.

CT perfusion

CT perfusion is a highly informative method for differential diagnosis of tumors involving neurovascular bundle of the neck. Paragangliomas are characterized by increased (more than tenfold) blood flow velocity and volumetric blood flow within pathological tissue compared to other lesions in this location **(Table**, **Fig. 10)**.

PET / CT

Whole-body PET / CT with ^{68}Ga-labeled somatostatin agonists is employed to detect multiple tumors

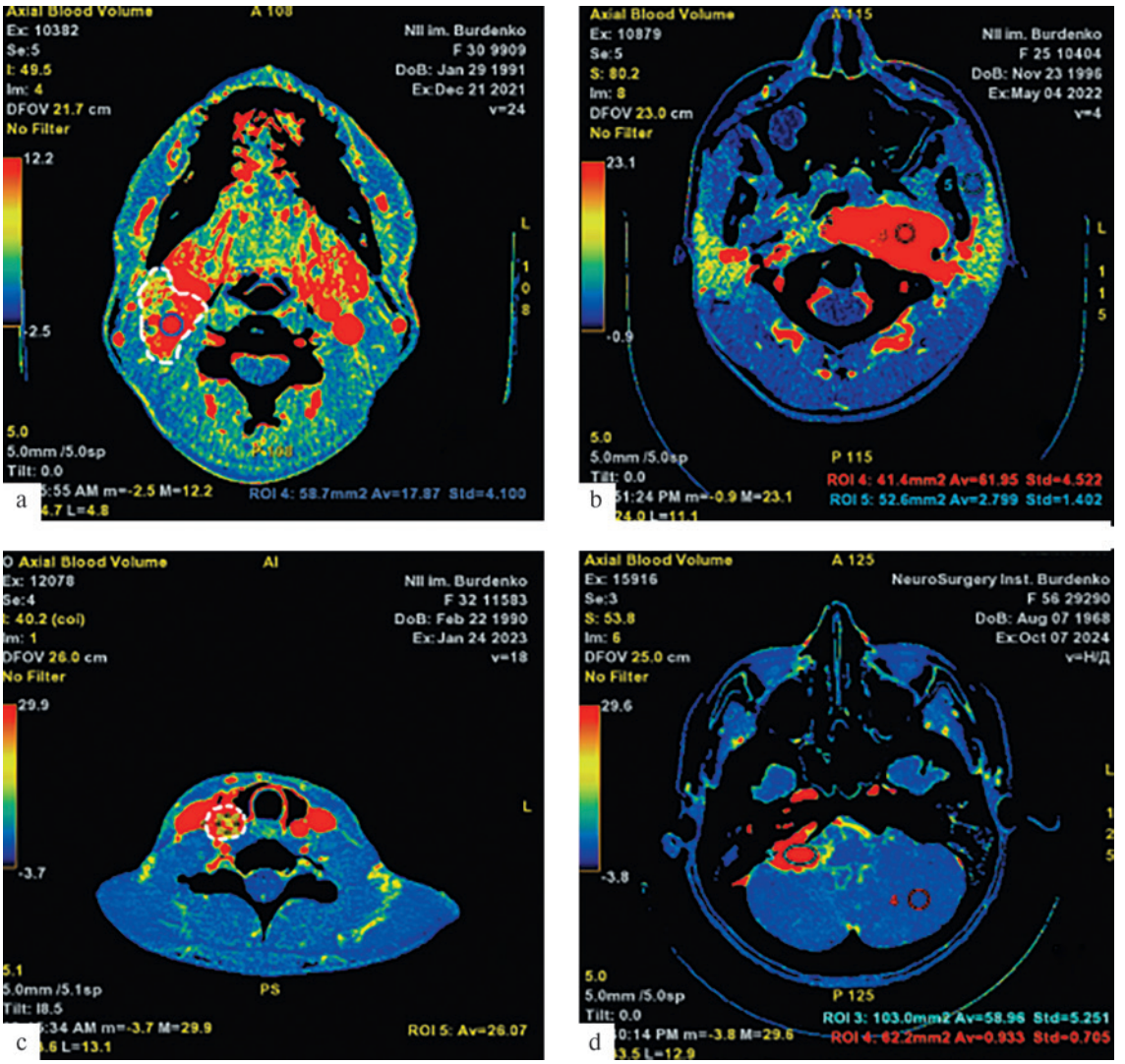

Fig. 10. **Blood flow parameters in paraganglioma of sympathetic trunk (a), vagus nerve (inferior ganglion) (b), vagus nerve (cervical segment) (c), and vagus nerve (plexiform ganglion) (d).**

and metastases **(Fig. 11)**. This procedure utilizes three DOTA peptides: DOTA-TOC, DOTA-TATE, and DOTA-NOC [17, 18]. These tracers have high affinity for type 2 somatostatin receptors. Currently, this method is the most accurate for diagnosing multiple head and neck paragangliomas and their metastases (sensitivity approaching 100%) [19—21].

Discussion

Head and neck paragangliomas can be hereditary, metastasize, and occur in association with syndromic diseases. This necessitates an expanded diagnostic algorithm integrating clinical, imaging and laboratory methods. In addition to conventional imaging (MRI and CT), integration of perfusion procedures for differential diagnosis, hybrid imaging techniques (PET/CT) and genetic testing makes it possible to obtain comprehensive information regarding extent of tumor at baseline assessment. This subsequently dictates treatment strategy.

Synthesizing the aforementioned data suggests a new approach to early detection of tumors in hereditary risk groups through screening of first-degree relatives. Metastatic forms of paraganglioma require management by oncologists and radiologists. Thus, treatment of patients with extra-adrenal paragangliomas necessitates a multidisciplinary approach and individual diagnostic / therapeutic plan involving neurosurgeons, endovascular surgeons, radiologists, endocrinologists, oncologists, otorhinolaryngologists, and rehabilitation specialists. While this strategy

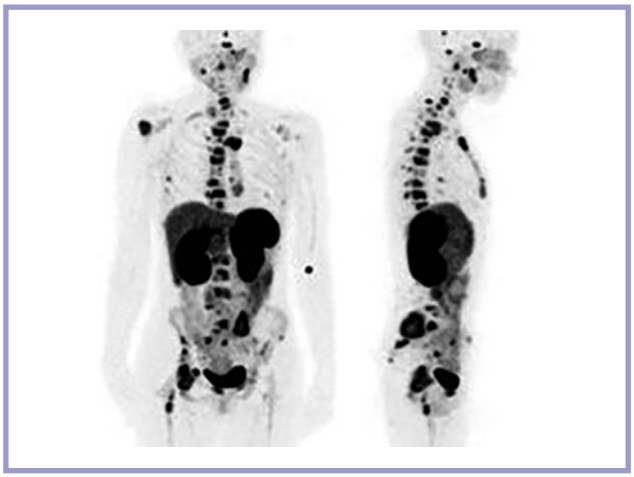

Fig. 11. **Multiple bone metastases in a patient with paragangliomas (irregularly shaped black lesions). Whole-body PET / CT with ^{68}Ga-DOTA-TATE.**

undoubtedly complicates coordination and increases costs, the ultimate treatment efficacy, lower recurrence rates and improved QoL and survival fully justify these efforts.

Conclusion

This report describes modern non-invasive diagnostic methods for patients with head and neck paragangliomas and outlines their advantages and limitations. Particular emphasis is placed on genetic testing for identifying hereditary forms and assessing the risk of malignant progression. These findings will underlie a differentiated approach to selecting treatment strategies, and this issue will be discussed in the second part of the article.

Author contribution:
Concept and design of the study — Akhmedov A.D., Lukshin V.A., Zolotova S.V., Usachev D.Yu.
Collection and analysis of data — Akhmedov A.D., Lukshin V.A., Zolotova S.V., Kim D.S., Rustamova D.R., Usachev D.Yu.
Writing the text — Akhmedov A.D., Zolotova S.V., Kim D.S., Rustamova D.R.
Editing — Akhmedov A.D., Lukshin V.A., Usachev D.Yu.

No conflict of interests to declare.

REFERENCES

1. Mannelli M, Castellano M, Schiavi F, Filetti S, Giacchè M, Mori L, Pignataro V, Bernini G, Giachè V, Bacca A, Biondi B, Corona G, Di Trapani G, Grossrubatscher E, Reimondo G, Arnaldi G, Giacchetti G, Veglio F, Loli P, Colao A, Ambrosio MR, Terzolo M, Letizia C, Ercolino T, Opocher G; Italian Pheochromocytoma/Paraganglioma Network. Clinically guided genetic screening in a large cohort of italian patients with pheochromocytomas and/or functional or nonfunctional paragangliomas. *The Journal of Clinical Endocrinology & Metabolism*. 2009;94(5):1541-1547. https://doi.org/10.1210/jc.2008-2419
2. Trache MC, Böttcher A, Betz CS. Hereditary head and neck paraganglioma: from basics to practical consequences. *Current Opinion in Otolaryngology & Head and Neck Surgery*. 2023;31(2):111-117. https://doi.org/10.1097/MOO.0000000000000867
3. Lider Burciulescu SM, Randon C, Duprez F, Huvenne W, Creytens D, Claes KBM, de Putter R, T'Sjoen G, Badiu C, Lapauw B. Clinical presentation of sporadic and hereditary pheochromocytoma/paraganglioma. *Endocrine Oncology*. 2023;3(1):e220040. https://doi.org/10.1530/EO-22-0040
4. Dahia PL. Pheochromocytoma and paraganglioma pathogenesis: learning from genetic heterogeneity. *Nature Reviews Cancer*. 2014;14(2):108-119. https://doi.org/10.1038/nrc3648
5. Snezhkina AV, Pavlov VS, Krasnov GS, Kalinin DV, Pudova EA, Stolbovskaya OV, Dunshina AV, Fedorova MS, Kudryavtseva AV. Non-Susceptibility Gene Variants in Head and Neck Paragangliomas. *International Journal of Molecular Sciences*. 2024;25(23):12762. https://doi.org/10.3390/ijms252312762
6. Sandow L, Thawani R, Kim MS, Heinrich MC. Paraganglioma of the Head and Neck: A Review. *Endocrine Practice*. 2023;29(2):141-147. https://doi.org/10.1016/j.eprac.2022.10.002
7. De Witte T, Van Den Heede K, Brusselaers N, Van Slycke S. Neck paragangliomas: a case report and literature review. *Acta Chirurgica Belgica*. 2024;124(6):508-513. https://doi.org/10.1080/00015458.2024.2392349
8. Rafieian S, Amini H, Rezaei O, Nozheh A, Yazdi NA. Multiple paragangliomas diagnosed in head, neck, and mediastinum: a case report. *Diagnostic Pathology*. 2025;20(1):109. https://doi.org/10.1186/s13000-025-01710-6
9. Zhong S, Zuo W. An Update on Temporal Bone Paragangliomas. *Current Treatment Options in Oncology*. 2023;24(10):1392-1407. https://doi.org/10.1007/s11864-023-01127-7
10. Yin S. [Review and prospect of the diagnosis and treatment of head and neck paragangliomas]. *Lin Chuang Er Bi Yan Hou Tou Jing Wai Ke Za Zhi*. 2024;38(9):773-776. (In Chinese). https://doi.org/10.13201/j.issn.2096-7993.2024.09.001
11. Eid M, Foukal J, Sochorová D, Tuček Š, Starý K, Kala Z, Mayer J, Němeček R, Trna J, Kunovský L. Management of pheochromocytomas and paragangliomas: Review of current diagnosis and treatment options. *Cancer Medicine*. 2023;12(13):13942-13957. https://doi.org/10.1002/cam4.6010
12. Strasser V, Steinbichler T. Paragangliome im Kopf-Hals-Bereich [Paragangliomas of the head and neck]. *Radiologie*. 2024;64(12):960-970. (In German). https://doi.org/10.1007/s00117-024-01395-w
13. Fishbein L, Leshchiner I, Walter V, Danilova L, Robertson AG, Johnson AR, Lichtenberg TM, Murray BA, Ghayee HK, Else T, Ling S, Jefferys SR, de Cubas AA, Wenz B, Korpershoek E, Amelio AL, Makowski L, Rathmell WK, Gimenez-Roqueplo AP, Giordano TJ, Asa SL, Tischler AS; Cancer Genome Atlas Research Network; Pacak K, Nathanson KL, Wilkerson MD. Comprehensive Molecular Characterization of Pheochromocytoma and Paraganglioma. *Cancer Cell*. 2017;31(2):181-193. https://doi.org/10.1016/j.ccell.2017.01.001
14. Imperiale A, Berti V. SDH-related head and neck paragangliomas: Unraveling PET radiomics beyond ^{18}F-FDG. *Best Practice & Research Clinical Endocrinology & Metabolism*. 2025;39(1):101926. https://doi.org/10.1016/j.beem.2024.101926
15. Koh ES, Dabsha A, Rahouma M, Zappi K, Srinivasan Y, Hickner A, Kutler DI. Succinate dehydrogenase mutations in head and neck paragangliomas: A systematic review and meta-analysis of individual patients' data. *Head & Neck*. 2024;46(7):1795-1808. https://doi.org/10.1002/hed.27652
16. Smith JD, Harvey RN, Darr OA, Prince ME, Bradford CR, Wolf GT, Else T, Basura GJ. Head and neck paragangliomas: A two-decade institutional experience and algorithm for management. *Laryngoscope Investigative Otolaryngology*. 2017;2(6):380-389. https://doi.org/10.1002/lio2.122
17. Palade DO, Hainarosie R, Zamfir A, Vrinceanu D, Pertea M, Tusaliu M, Mocanu F, Voiosu C. Paragangliomas of the Head and Neck: A Review of the Latest Diagnostic and Treatment Methods. *Medicina*. 2024;60(6):914. https://doi.org/10.3390/medicina60060914
18. Taïeb D, Timmers HJ, Hindié E, Guillet BA, Neumann HP, Walz MK, Opocher G, de Herder WW, Boedeker CC, de Krijger RR, Chiti A, Al-Nahhas A, Pacak K, Rubello D; European Association of Nuclear Medi-

cine. EANM 2012 guidelines for radionuclide imaging of phaeochromocytoma and paraganglioma. *European Journal of Nuclear Medicine and Molecular Imaging.* 2012;39(12):1977-1995. https://doi.org/10.1007/s00259-012-2215-8

19. Vimawala SN, Graboyes AZ, Bennett B, Bonanni M, Abbasi A, Oliphant T, Alonso-Basanta M, Rassekh C, Cohen D, Brant JA, Huan Y. Head and Neck Paragangliomas: Overview of Institutional Experience. *Cancers.* 2024;16(8):1523. https://doi.org/10.3390/cancers16081523

20. Janssen I, Chen CC, Millo CM, Ling A, Taieb D, Lin FI, Adams KT, Wolf KI, Herscovitch P, Fojo AT, Buchmann I, Kebebew E, Pacak K. PET/CT comparing ^{68}Ga-DOTATATE and other radiopharmaceuticals and in comparison with CT/MRI for the localization of sporadic metastatic pheochromocytoma and paraganglioma. *European Journal of Nuclear Medicine and Molecular Imaging.* 2016;43(10):1784-1791. https://doi.org/10.1007/s00259-016-3357-x

21. Aydemir G, Ardic FN, Kara CO, Bir F. Head and Neck Paragangliomas: 16-year Single-center Experience and Mini Review on Diagnosis, Treatment, and Follow-up. *Medeniyet Medical Journal.* 2024;39(3):192-203. https://doi.org/10.4274/MMJ.galenos.2024.91668

Received 12.08.2025
Reviced 04.05.2026
Accepted 20.07.2026

Comment

Head and neck paragangliomas account for up to 0.6% of all head and neck tumors and up to 50% of all paragangliomas. The risk of malignant transformation is estimated at 3—5%, the risk of hormonal activity — at 1-3%. The disease can manifest at any age, though the peak incidence occurs between the third and sixth decades of life. Diagnosis and treatment involve neurosurgeons, oncologists, vascular surgeons, otolaryngologists, maxillofacial surgeons, and radiologists. However, there is currently no a unified approach to patient management. The authors present a review of modern literature and their own clinical experience. The purpose of the study was to summarize information on epidemiology, pathogenesis, and diagnosis of paragangliomas using up-to-date data. The article is well-structured and illustrated, as well as contains appropriate subsections. The study makes a favorable impression. The authors comprehensively described current concepts regarding etiology, diagnosis, genetic characteristics, and markers of head and neck paragangliomas. This report will be useful for neurosurgeons, oncologists, vascular surgeons, and radiologists.

Lukyanchikov V.A. (Moscow)