Burdenko's Journal of Neurosurgery
2026, No. 5, pp. 61–69
https://doi.org/10.17116/neiro20269005161

Desmoplastic infantile gangliogliomas/astrocytomas: clinical course, surgery and morphological diagnosis

© K.B. Matuev[1, 2], S.K. Gorelyshev[1, 2], E.A. Khukhlaeva[1, 2], L.V. Shishkina[1], M.V. Ryzhova[1]

[1]Burdenko Neurosurgical Center, Moscow, Russia;
[2]Russian Medical Academy of Continuous Professional Education, Moscow, Russia

ABSTRACT

Desmoplastic infantile gangliogliomas (DIG) and astrocytomas (DIA) are benign brain tumors in infants. They comprise 1.3–15.8% of tumors in infants / young children and 0.5–1% in older children. In the latest 2021 WHO classification of the CNS tumors, DIG and DIA are included in the group of neuronal and glioneuronal tumors and considered as a single entity within this group despite some morphological differences. In this classification, they are classified as low-grade tumors (Grade I). However, several cases of DIG/DIA with aggressive behavior were described in the literature.

Objective. To analyze 2 different clinical courses of DIG/DIA with various neuroimaging signs, intraoperative situations and morphological pictures with review of appropriate literature.

Material and methods. Two main courses of disease in children with DIG/DIA are presented. The first one is characterized by rapid growth of tumor, its large size upon diagnosis with progressive intracranial hypertension. The second type includes slow growth, small size, and only focal neurological symptoms.

Results and conclusion. DIG/DIA are rare tumors and most often diagnosed in the first 2 years of life. They have some common neuroradiological and histological features with malignant brain tumors (malignant glioma of infancy, PNET), but another prognosis. Aggressive clinical course, rapid tumor growth, MR-based differential diagnosis involving multiple histological forms and histopathological findings potentially mimicking malignant tumor complicate differential diagnosis, as it was in the second case. Probably, such an aggressive clinical course is associated with significant spread of neoplastic astrocytic and neuronal components with foci of primitive embryonic cell complexes with increased proliferative index. Surgery is preferable. Difficult resection of these tumors is associated with rich vascularity, high risk of fatal bleeding, no border with normal brain tissue, and tendency to infiltrate functionally significant structures of the central nervous system.

Keywords: *desmoplastic infantile gangliogliomas, desmoplastic infantile astrocytomas, morphology, surgical treatment.*

INFORMATION ABOUT THE AUTHORS:
Matuev K.B. — https://orcid.org/0000-0001-7725-7435
Gorelyshev S.K. — https://orcid.org/0000-0003-0984-2039
Shishkina L.V. — https://orcid.org/0000-0002-7961-4245
Ryzhova M.V. — https://orcid.org/0000-0003-0147-2301
Corresponding author: Matuev K.B. — e-mail: kmatuev@nsi.ru

TO CITE THIS ARTICLE:
Matuev KB, Gorelyshev SK, Khukhlaeva EA, Shishkina LV, Ryzhova MV. Desmoplastic infantile gangliogliomas/astrocytomas: clinical course, surgery and morphological diagnosis. *Burdenko's Journal of Neurosurgery*. 2026;90(5):61–69. (In Russ.).
https://doi.org/10.17116/neiro20269005146

Introduction

Desmoplastic infantile gangliogliomas (DIGs) and desmoplastic infantile astrocytomas (DIAs) are benign brain tumors typically occurring in infancy. They account for 1.3-15.8% of such tumors in infants and young children and 0.5—1% in older groups with higher prevalence in boys [1]. Mean age of children with this disease is 18 months (median 9 months) [2].

In the latest (2021) WHO classification of the CNS tumors, DIGs and DIAs are included in neuronal and glioneuronal tumors. They are considered a single entity within this group, despite certain morphological differences [1]. They are classified as low-grade tumors (Grade I). However, several cases of DIG/DIA with aggressive behavior were described in the literature [3].

There are only case reports devoted to DIG/DIA due to rarity of this disease. Identifying common patterns is possible only in meta-analyses of available data. Therefore, descriptions of all patients with DIG/DIA are essential to expand the database and facilitate further generalizations [4].

There are 2 patterns of disease progression in children with DIG/DIA. The first one is characterized by rapid tumor growth and large tumor size, as well as progressive signs of intracranial hypertension. The second pattern in-

volves slow growth and small tumor size with typically focal neurological symptoms.

The purpose of the study was to analyze two cases of DIG/DIA differing in clinical course, neuroimaging features, intraoperative findings and morphological presentation, as well as to review appropriate literature data.

Case # 1

A 1.5-year-old male patient experienced the first seizure with staring spell and gaze fixation at the age of 10 months (June 2022). Seizures recurred twice despite antiepileptic therapy. Brain MRI revealed medial tumor of the right temporal lobe with uniform contrast enhancement **(Fig. 1)**.

In February 2023, microsurgical resection was performed via right-sided pterional approach. We identified tumor tissue immediately beneath the base of the right temporal lobe pole at a depth of approximately 2 cm. After partial dissection of the Sylvian fissure, we started resection using bipolar forceps, aspirator and microsurgical instruments. There was a heterogeneous structure of tumor. Its part in Sylvian fissure adjacent to tributaries of the middle cerebral artery and internal carotid artery was dense, partially calcified and difficult for resection with ultrasonic aspirator. Another part extended into mediobasal regions. It was less dense, light yellow in color, friable and penetrated deep into the temporal lobe. We gradually resected the tumor within visible margins using microinstruments under microscopic guidance. Resection of dense component adjacent to internal carotid artery was accompanied by bradycardia, and we left a thin calcified fragment. Hemostasis was followed by closure of dura mater, bone flap fixation and soft tissue suturing.

Histological examination

Tumor tissue consisted predominantly of desmoplastic leptomeningeal component comprising spindle-shaped cells embedded in collagenous matrix. Fine fibers surrounded tumor cells. There was a clear boundary between cortical surface and desmoplastic tumor. Perivascular mononuclear inflammatory infiltrates were observed, but no embryonal-like tumor cells were detected in specimen. Immunohistochemical analysis revealed focal GFAP expression in tumor cells, whereas neuronal markers (synaptophysin, neurofilaments) were expressed in neoplastic ganglion cells and cells lacking clear neuronal differentiation. The Ki-67 index was low (<1—2%).

Considering morphological and immunohistochemical findings, we diagnosed DIG WHO Grade I **(Fig. 2)**.

Postoperative MRI revealed no complications and no evidence of residual tumor **(Fig. 3)**.

There were no postoperative paroxysmal symptoms; antiepileptic therapy was discontinued one year after surgery.

Follow-up MRI at two years showed no evidence of tumor recurrence **(Fig. 4)**.

Case # 2

We present a 6-month-old female infant. At 5 months of age, the pediatrician noted fast head circumference growth. Neurosonography revealed frontoparietal cystic lesion. Brain MRI demonstrated a large tumor in the right frontoparietal region with intense contrast enhancement and mass effect **(Fig. 5)**.

In view of suspected malignant nature and possible adjuvant therapy alone, we performed open biopsy on January 16, 2025 to clarify morphological diagnosis. Histological findings necessitated a differential diagnosis between meningioma, solitary fibrous tumor, desmoplastic infantile ganglioglioma, and malignant infantile glioma. In the absence of definitive morphological diagnosis, we preferred total resection.

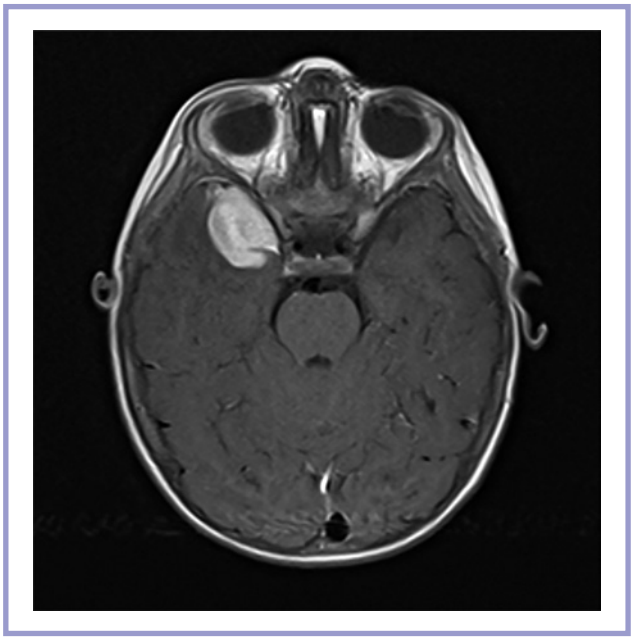

Fig. 1. **Axial contrast-enhanced T1WI (medial tumor of the right temporal lobe with uniform contrast enhancement).**

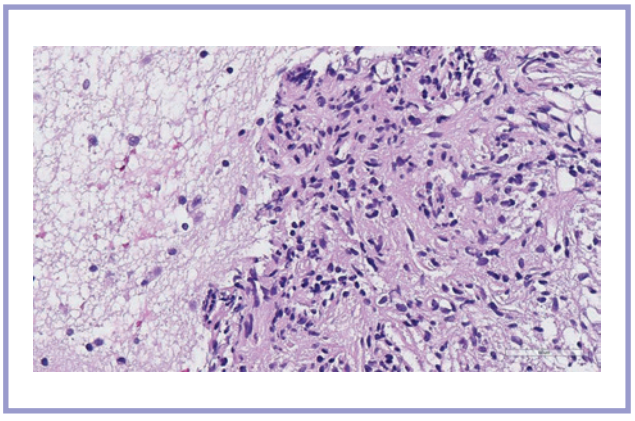

Fig. 2. **Desmoplastic infantile ganglioglioma: tumor cells (right) in loose connective tissue matrix; tumor border with edematous brain tissue (left side of the image). Hematoxylin and eosin stain, ×400.**

On February 17, 2025, microsurgical resection was performed through extended right-sided frontotemporal craniotomy. Tense dura mater did not transmit pulsation. There were hemorrhages across the entire surface and from the bone. We exposed anterior margin of tumor. It was light yellow in color, extremely firm and intimately adherent to dura mater in some areas. We fragmented and resected tumor tissue using monopolar cauterization in "cut" mode. Resection was performed almost entirely using monopolar cauterization. The tumor was extremely firm throughout. In some areas, monopolar cauterization was ineffective. We excised these fragments using dural scissors. In deep inferior regions, tumor had looser consistency, and we easily removed it via standard sucker. There was diffuse growth without clear boundaries with brain tissue, i.e. it was impossible to distinguish diffuse growth and edema of intact brain tissue. Bleeding at several sites was controlled via coagulation and monopolar cautery. After excision of tumor, we opened a cystic component over the frontal and parietal lobes. Sphenoid wing and Sylvian fissure with vascular structures were exposed. There was a large cavity after resection. Hemostasis implied gauze and bipolar cauterization, and the cavity was filled with saline. Dura mater repair was performed using artificial dural substitute and Tachocomb. Fragments of thinned bone flap were contoured, repositioned and fixed with silk sutures. Soft tissues were closed in layers. All specimens were scheduled for histological examination.

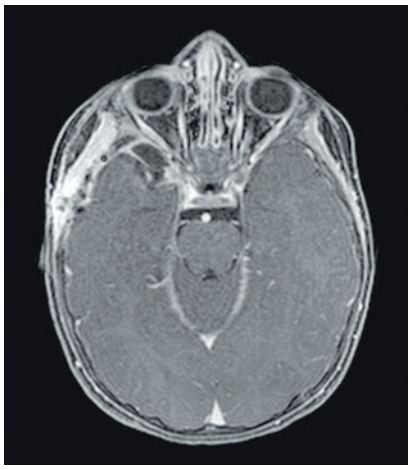

Fig. 3. **Axial contrast-enhanced T1WI after resection of medial tumor in the right temporal lobe (no residual tumor).**

Histological examination

Along with clear desmoplastic component consisting of dense bundles of fibrous tissue with sparse fibroblasts, we visualized multiple coalescing foci of moderately pleomorphic cells with normochromic nuclei and occasional mitotic figures, as well as sites of increased cellularity and nuclear hyperchromasia **(Fig. 6)**. Immunohistochemical analysis revealed positive expression of GFAP and Syn in tumor cells, CD34 expression in several foci and nuclear expression of INI1. There was negative expression of EMA, PR250 and STAT6. The Ki-67 index was heterogeneous (up to 8—10% in areas of increased cellularity). Morphologically and immunophenotypically, the tumor was consistent with DIG/DIA (WHO Grade I). Molecular analysis revealed no BRAF gene mutations or KIAA1549:BRAF fusions (frequently described in DIG/DIA) and NTRK1, NTRK2, NTRK3, ALK or ROS rearrangements. Unusual and rare nature of case necessitated DNA methylation analysis. DNA methylation profile was analyzed using the Infinium MethylationEPIC Bead-

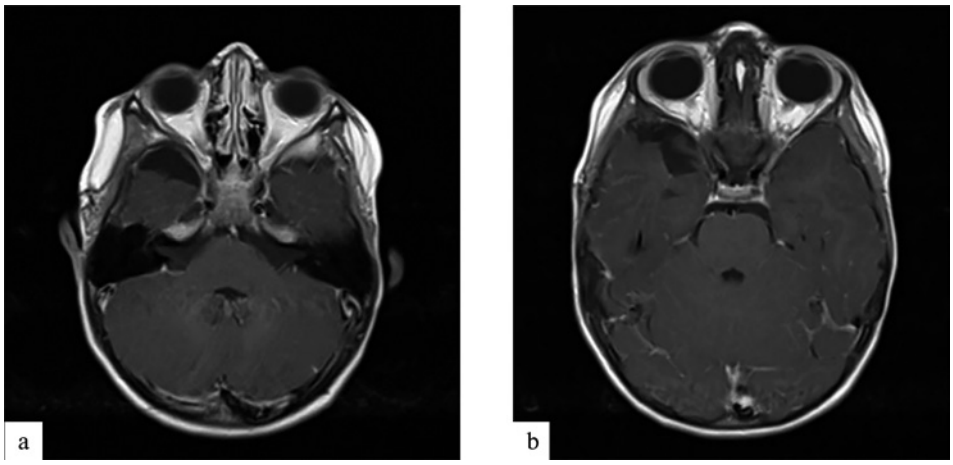

Fig. 4. **Follow-up MRI in 2 years after resection of medial tumor in the right temporal lobe (axial contrast-enhanced T1WI, no signs of tumor recurrence).**

Chip kit (Illumina, USA) and NextSeq 550 instrument (Illumina, USA). Results were analyzed via the MolecularNeuropathology.org platform (Brain Tumor Classifier, v. 12.8). Methylation analysis classified the tumor as DIG/DIA with a matching score of 0.99989. No chromosomal copy number alterations were detected. The profile was balanced, and the MGMT promoter was not methylated.

Thus, immunohistochemical and molecular-genetic findings corresponded to DIG/ganglioastrocytoma WHO Grade I.

Postoperative follow-up revealed no complications. Contrast-enhanced MRI after 9 months revealed no evidence of continued tumor growth **(Fig. 7)**.

Discussion

In 1984, Taratuto A.L. et al. [5] first described a group of brain tumors with astrocytic component in infants (superficial cerebral astrocytoma). In 1987, VandenBerg S.R. et al. [6] grouped these tumors under the name DIG. These brain tumors were characterized by the following features: 1) astrocytic and ganglionic differentiation; 2) desmoplastic stroma; 3) large size; 4) cystic component; 5) manifestation within 18 months of life; 6) favorable prognosis. Tumors with distinct ganglionic differentiation (DIG) and those with similar characteristics but exclusively astrocytic cellular composition (DIA) were distinguished later according to histological characteristics. As previously mentioned, the latest 2021 WHO classification groups DIG and DIA together under "neuronal and glioneuronal tumors" as low-grade (Grade I) tumors. In 2025, Lampros M. et al. [4] published the largest review devoted to clinical and histological characteristics, as well as treatment details. This was a meta-analysis of 103 articles and 222 patients.

Current research confirms the importance of genetic classification for DIG/DIA cases. Lampros M. et al. [4] suggested that tumors with wild-type BRAF V600 may demonstrate more aggressive behavior. According to recent molecular data, DIG/DIA cases with high-grade histological features retain the same genetic alterations as their low-grade counterparts but acquire additional mutations

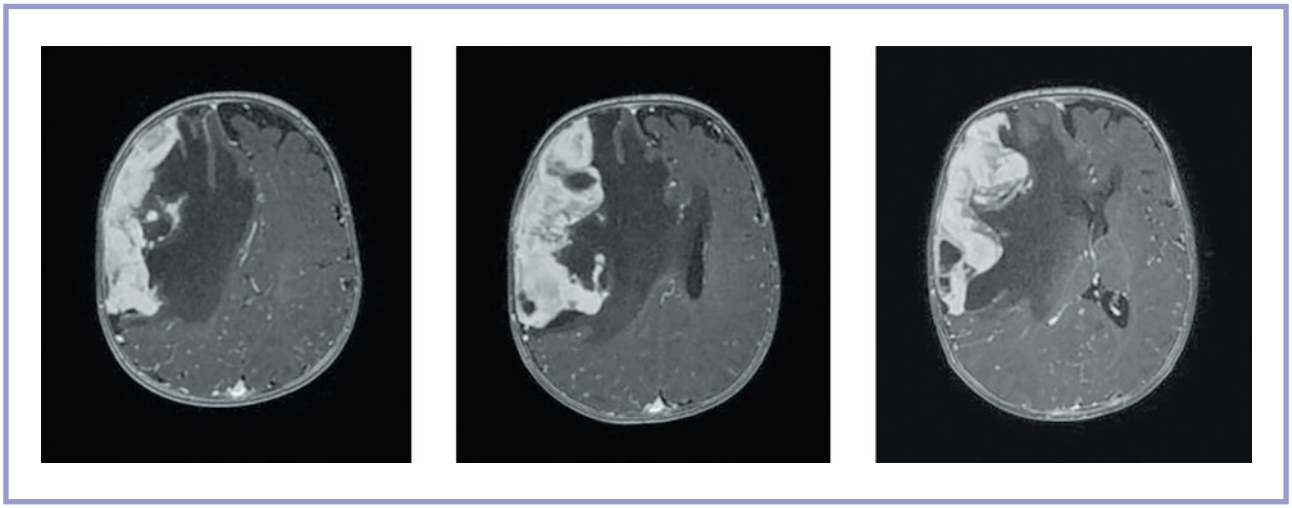

Fig. 5. **Axial contrast-enhanced T1WI (large tumor in the right frontoparieto-temporal region containing small cystic components with contrast enhancement).**

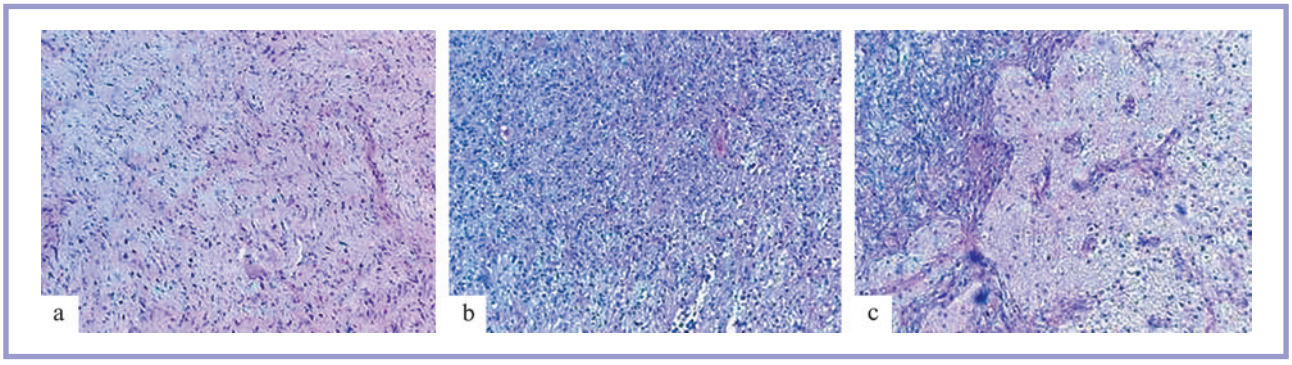

Fig. 6. **Histological specimen.**
a — proliferation of fibrous fibers with sparsely distributed fibroblastic cells; b — tumor focus composed of primitive embryonic cells with high cellularity, nuclear polymorphism and multiple vessels; c — focus of invasive growth into brain tissue with increased vascularization of infiltration zone; hematoxylin and eosin stain, ×200.

in the TP53 and ATRX genes. This suggests potential molecular progression. Furthermore, transcriptional profiling demonstrated high expression of genes and transcription factors associated with proliferation including MYC and E2F in high-grade areas. This indicates a shift towards more aggressive biological phenotype [4, 7]. Wang Q. et al. [8] noted higher likelihood of favorable outcomes with recurrence-free survival after total resection. Interestingly, there are literature data on spontaneous regression after subtotal resection without adjuvant therapy [9]. Thus, the factors influencing aggressive behavior of DIG/DIA remain a subject of investigation.

Topography and symptoms

In most cases, DIG and DIA are supratentorial predominantly hemispheric tumors. They typically involve multiple lobes (most commonly frontal and parietal regions) while suprasellar tumors are rare [10, 11].

Duration of disease is usually short in infants with open cranial sutures (3—6 months). Large tumor volume determines appropriate symptoms including rapid head growth (60% of cases) accompanied by prolapse of anterior fontanelle, "setting-sun" sign and bulging of the overlying bones (as observed in our second case).

Duration of disease is somewhat longer in older children (6—9 months). Classic symptoms of intracranial hypertension coexist with focal neurological syndromes corresponding to localization of tumor [2, 11].

Imaging

Almost all DIG/DIA present a solid superficial component associated with uni- or multilocular cyst. CT visualizes solid component as isodense or slightly hyperdense lesion with intense contrast enhancement. MRI visualizes hypodense solid component on T1- and T2-weighted images, while cystic content is classically hypodense on T1WI and hyperdense on T2WI. Following intravenous contrast administration, solid component and adjacent dura mater actively capture contrast agent. T2 hyperintensity of tumor cysts and infancy are key features distinguishing DIG/DIA from pleomorphic xanthoastrocytomas. Dysembryoplastic neuroepithelial tumors (DNETs) may be distinguished by smaller size and no contrast enhancement [2, 4, 11].

Surgical management

Surgery is the primary treatment for DIG/DIA. These tumors are intraoperatively characterized by dense consistency due to desmoplasia (stromal reaction involving fibrous proliferation) and wide cortical contact of cystic components. DIG and DIA arise from meninges and cortex. Total resection may be difficult due to adherence to the cortex and dura mater. This is a crucial for tumors in functionally eloquent areas or those extending to basal dura mater or sagittal sinus.

Furthermore, typical presentation in infants makes intraoperative blood loss the factor limiting extent of resection in some cases. Indeed, a staged approach may be necessary [2, 11].

In our series, the tumor was less dense in the first case, and its resection was not associated with severe blood loss. The second tumor was extremely dense and involved dura mater (resembling a meningioma). Its resection was accompanied by controllable but critical for this age bleeding due to extensive vascularity in cellular regions and infiltrative growth zone.

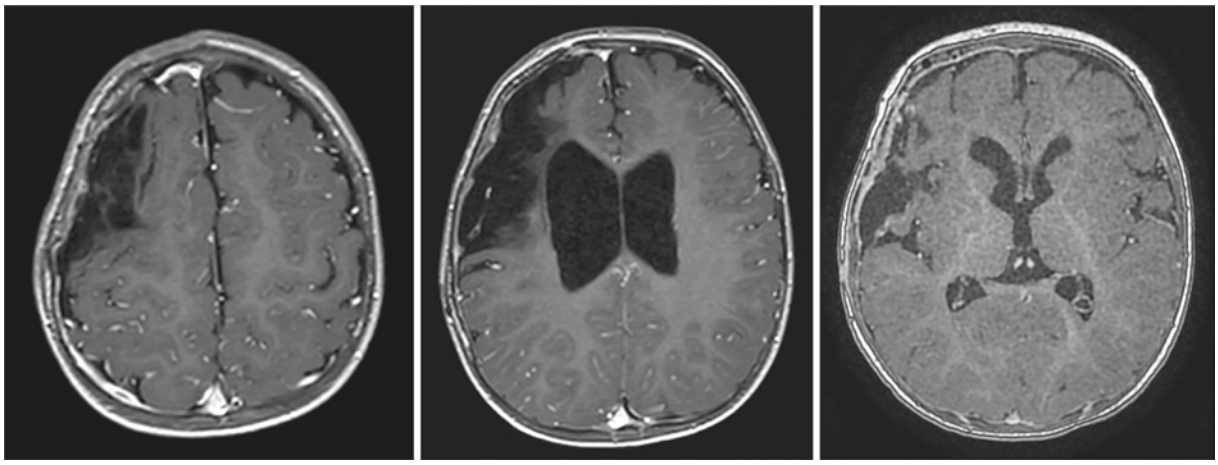

Fig. 7. **Axial contrast-enhanced T1WI after 1 year.**
No evidence of continued tumor growth.

Histopathology and genetics

DIG/DIA are biphasic tumors composed of distinct desmoplastic leptomeningeal and neuroepithelial components. The latter consists of either astrocytic cell population alone or neuronal component with ganglionic differentiation. Like pilocytic astrocytomas, they are classified as low-grade tumors (WHO Grade I) and coded as neoplasms of uncertain behavior in the International Classification of Diseases. However, these tumors frequently contain foci of primitive embryonic tumor cells characterized by high cellularity and mitotic figures. This component may predominate in tumor tissue, often driving more aggressive growth and complicating accurate diagnosis and grading. Lampros et al. [4] reported high Ki-67 index in more than 20% of cases, although aggressive biological behavior was observed in only 9%.

Genetic analysis of DIG/DIA revealed either normal karyotype or non-clonal abnormalities. Genomic losses were detected at loci 5q13.3, 21q22.11 (TMEM50B, DNAJC28) and 10q21.3 in both DIG and DIA, whereas copy number gains appear to be absent or extremely rare. Although EGFR and MYCN amplification was previously described in DIG, amplification of genes typically observed in high-grade infantile gliomas (EGFR, MYCN, PDGFRA) is absent [12].

In our cases, morphological diagnosis presented no difficulties in the first instance, and diagnosis was verified via immunohistochemical analysis. In the second case, diagnosis was extremely difficult due to extensive spread of neoplastic astrocytic and neuronal components with foci of primitive embryonic cell clusters with high proliferative index and only focal desmoplastic component. No BRAF gene mutations or fusions were detected. Consequently, a rigorous differential diagnosis with infant-type malignant glioma was necessary through molecular genetic testing (direct Sanger sequencing and DNA methylation analysis).

According to the literature, adjuvant therapies are generally not recommended. However, chemotherapy may be considered if surgical intervention is not feasible. Radiotherapy is limited by age considerations. Various studies found no clear benefit. Thus, this approach may be advisable in patients over 5 years old or as a last resort for tumors recurring after surgery and chemotherapy [4, 11].

Conclusion

Desmoplastic infantile gangliogliomas and desmoplastic infantile astrocytomas are rare tumors most frequently diagnosed within the first two years of life. They have certain similar neuroradiological and histological features with malignant brain tumors (such as infant-type malignant glioma or primitive neuroectodermal tumor), but another prognosis.

Aggressive clinical course, rapid tumor growth, necessary histological differentiation in MR assessment and histopathological findings mimicking malignant tumors complicate differential diagnosis, as observed in our second case. This aggressive clinical course is likely associated with extensive spread of neoplastic astrocytic and neuronal components, accompanied by foci of primitive embryonic cell clusters with high proliferative index.

Surgical intervention is preferable. Challenges associated with resection of such tumors include their vascularization, high risk of fatal hemorrhage, no clear boundary with normal brain tissue and tendency to infiltrate functionally critical CNS structures. Staged resection may be a strategy to prevent acute complications in infants. Additional treatment is generally unnecessary after total resection. Chemotherapy is necessary for infants with progressive disease if further resection is not feasible. Radiotherapy is the last resort for children over 5 years old who do not respond to chemotherapy.

Author contribution:
Concept and design of the study — Matuev K.B., Gorelyshev S.K., Shishkina L.V.
Collection and analysis of data — Matuev K.B., Shishkina L.V.
Writing the text — Matuev K.B.
Statistical analysis — Matuev K.B., Shishkina L.V., Khukhlaeva E.A.
Editing — Matuev K.B., Shishkina L.V., Khukhlaeva E.A., Gorelyshev S.K., Ryzhova M.V.

No conflict of interests to declare.

REFERENCES

1. Louis DN, Perry A, Wesseling P, Brat DJ, Cree IA, Figarella-Branger D, Hawkins C, Ng HK, Pfister SM, Reifenberger G, Soffietti R, von Deimling A, Ellison DW. The 2021 WHO Classification of Tumors of the Central Nervous System: a summary. *Neuro-Oncology*. 2021;23(8):1231-1251. https://doi.org/10.1093/neuonc/noab106
2. Tamburrini G, Colosimo C Jr, Giangaspero F, Riccardi R, Di Rocco C. Desmoplastic infantile ganglioglioma. *Child's Nervous System*. 2003;19(5-6): 292-297. https://doi.org/10.1007/s00381-003-0743-z
3. Wang S, Sun MZ, Abecassis IJ, Weil AG, Ibrahim GM, Fallah A, Ene C, Leary SES, Cole BL, Lockwood CM, Olson JM, Geyer JR, Ellenbogen RG, Ojemann JG, Wang AC. Predictors of mortality and tumor recurrence in desmoplastic infantile ganglioglioma and astrocytoma—and individual participant data meta-analysis (IPDMA). *Journal of Neuro-Oncology*. 2021;155(2):155-163. https://doi.org/10.1007/s11060-021-03860-1
4. Lampros M, Baxevanidis P, Tsegkelidis K, Alexiou GA, Voulgaris S. Desmoplastic infantile ganglioglioma and astrocytoma: A narrative review of the literature. *Child's Nervous System*. 2025;41(1):324. https://doi.org/10.1007/s00381-025-06982-3

5. Taratuto AL, Monges J, Lylyk P, Leiguarda R. Superficial cerebral astrocytoma attached to dura. Report of six cases in infants. *Cancer.* 1984;54(11): 2505-2512. https://doi.org/10.1002/1097-0142(19841201)54:11<2505::aid-cncr2820541132>3.0.co;2-g

6. VandenBerg SR, May EE, Rubinstein LJ, Herman MM, Perentes E, Vinores SA, Collins VP, Park TS. Desmoplastic supratentorial neuroepithelial tumors of infancy with divergent differentiation potential ("desmoplastic infantile gangliogliomas"). Report on 11 cases of a distinctive embryonal tumor with favorable prognosis. *Journal of Neurosurgery.* 1987;66(1):58-71. https://doi.org/10.3171/jns.1987.66.1.0058

7. Chiang J, Li X, Jin H, Wu G, Lin T, Ellison DW. The molecular characteristics of low-grade and high-grade areas in desmoplastic infantile astrocytoma/ganglioglioma. *Neuropathology and Applied Neurobiology.* 2022;48(4):e12801. https://doi.org/10.1111/nan.12801

8. Wang Q, Meng J, Cheng J, Zhang S, Hui X, Li Q, Liu W, Ju Y, Sun L. Multifocal Desmoplastic Infantile Ganglioglioma/Astrocytoma (DIA/DIG): An Institutional Series Report and a Clinical Summary of This Rare Tumor. *Frontiers in Oncology.* 2022;11:608129. https://doi.org/10.3389/fonc.2021.608129

9. Takeshima H, Kawahara Y, Hirano H, Obara S, Niiro M, Kuratsu J. Postoperative regression of desmoplastic infantile gangliogliomas: report of two cases. *Neurosurgery.* 2003;53(4):979-983; discussion 983-984. https://doi.org/10.1227/01.neu.0000084165.60662.6d

10. Wang Q, Zhang Y, Zhang H, Hui X, Liu W. Suprasellar desmoplastic infantile astrocytoma and ganglioglioma: an institutional series report and a clinical summary of this rare tumor. *Frontiers in Oncology.* 2025;15:1674829. https://doi.org/10.3389/fonc.2025.1674829

11. Imperato A, Spennato P, Mazio F, Arcas E, Ozgural O, Quaglietta L, Errico ME, Cinalli G. Desmoplastic infantile astrocytoma and ganglioglioma: a series of 12 patients treated at a single institution. *Child's Nervous System.* 2021;37(7):2187-2195. https://doi.org/10.1007/s00381-021-05057-3

12. Gessi M, Zur Mühlen A, Hammes J, Waha A, Denkhaus D, Pietsch T. Genome-wide DNA copy number analysis of desmoplastic infantile astrocytomas and desmoplastic infantile gangliogliomas. *Journal of Neuropathology & Experimental Neurology.* 2013;72(9):807-815. https://doi.org/10.1097/NEN.0b013e3182a033a0

Received 20.04.2026
Reviced 03.06.2026
Accepted 20.07.2026

Comment

The authors present 2 patients with desmoplastic infantile ganglioglioma (DIG) and desmoplastic infantile astrocytoma (DIA) along with analysis of current literature data. The authors highlight specific features of clinical course, namely aggressive behavior of these tumors despite classification as low-grade malignancies.

The study aligns with the journal's scope. This report holds significant practical and scientific value due to rarity of this pathology, course of disease (often atypical for low-grade gliomas and typical for young children) and no standardized treatment strategy. These factors necessitate descriptions of all clinical cases to expand the database and enable future meta-analyses.

The authors propose an explanation for aggressive behavior and different prognoses in some children with DIG/DIA, particularly those of a very young age. An indisputable strength of this report is the detailed account of surgical procedures and their nuances, alongside a meticulous description of histological findings. The authors emphasize the role of total resection in young children due to limitations of adjuvant therapy. Moreover, total resection can be achieved through a staged approach.

The reference list includes up-to-date sources. However, approximately 70% of studies were published more than 5—10 years ago. On the other hand, this may reflect rarity of disease underscoring the importance of this study.

The abstract fully reflects the structure and content of the study. The manuscript is interesting for neurosurgeons, oncologists and pathologists. This study contributes to understanding of biology of these tumors and personalized treatment strategies.

Kim A.V. (Saint Petersburg)