Burdenko's Journal of Neurosurgery
2026, No. 5, pp. 54–60
https://doi.org/10.17116/neiro20269005154

Surgical treatment of anterior visual pathway gliomas in children using intraoperative neurophysiological monitoring and MR tractography

© N.I. Golovin, S.K. Gorelyshev, A.A. Ogurtsova, R.M. Afandiev

Burdenko Neurosurgery Center, Moscow, Russia

ABSTRACT

Background. Surgical resection of anterior visual pathway gliomas carries a high risk of postoperative visual deficit. The goals of surgical treatment are maximum safe removal of tumor and histological verification. Diffusion tensor imaging (DTI) with reconstruction of visual pathways and intraoperative monitoring of visual evoked potentials (VEP) were proposed to reduce the risk of potential visual dysfunction.

Objective. To demonstrate two cases of surgical treatment for anterior visual pathway gliomas using preoperative MR tractography of visual pathways and intraoperative VEP monitoring.

Material and methods. Two patients with anterior visual pathway tumors underwent preoperative MR tractography of visual pathways. Intraoperative VEP monitoring was performed.

Results. Extent of resection in both cases was determined by preoperative MR tractography and intraoperative neurophysiological monitoring of VEP. Ophthalmological status in early postoperative period demonstrated positive dynamics in the 1st patient and no changes in the 2nd patient.

Conclusion. Preoperative MR tractography of visual pathways and intraoperative neurophysiological monitoring of VEP with electrophysiological identification of visual pathways may potentially enable safer tumor resection and minimize the risk of postoperative visual deficit.

Keywords: *optic pathway glioma, MR tractography, intraoperative neurophysiological monitoring of VEP.*

INFORMATION ABOUT THE AUTHORS:
Golovin N.I. — https://orcid.org/0000-0002-8347-4695
Gorelyshev S.K. — https://orcid.org/0000-0003-0984-2039
Ogurtsova A.A. — https://orcid.org/0000-0003-3595-2696
Afandiev R.M. — https://orcid.org/0000-0001-6384-7960
Corresponding author: Golovin N.I. — e-mail: GolovinNI@nsi.ru

TO CITE THIS ARTICLE:
Golovin NI, Gorelyshev SK, Ogurtsova AA, Afandiev RM. Surgical treatment of anterior visual pathway gliomas in children using intraoperative neurophysiological monitoring and MR tractography. *Burdenko's Journal of Neurosurgery*. 2026;90(5):54–60. (In Russ.).
https://doi.org/10.17116/neiro20269005154

Abbreviations

VEP — visual evoked potentials
IONM — intraoperative neurophysiological monitoring

Introduction

Anterior visual pathway gliomas are rare and predominantly low-grade tumors with infiltrative growth along optic nerves, chiasm and optic tracts. These tumors often involve hypothalamic structures and third ventricle. These neoplasms account for 3-7% of all intracranial neoplasms in children. They are classified as either sporadic or associated with neurofibromatosis type 1 [1—6].

Resection of anterior visual pathway gliomas is an extremely challenging objective with high risk of damage to visual pathways and potential postoperative deterioration of baseline visual disorders.

In modern neurosurgical practice, surgical planning now goes beyond careful assessment of standard clinical MR protocols. One can also analyze brain pathways using diffusion tensor imaging, specifically MR tractography of visual pathway [7, 8].

IONM is standard practice when resecting brain tumors near functionally critical areas and pathways. Intraoperative functional assessment of visual pathways is possible through VEP monitoring and electrophysiological identification of visual pathways [9—11].

There are only a few international studies addressing surgical treatment of anterior visual pathway gliomas in children using IONM and MR tractography of visual pathways. No Russian studies on this issue currently exist.

The purpose of the study was to present two clinical cases of surgical treatment of anterior visual pathway gliomas using preoperative MR tractography of visual pathways and intraoperative monitoring of visual evoked potentials.

Case #1

A 6-year-old female patient experienced progressive vision loss for 5—6 months prior to admission. MRI revealed a large tumor involving the chiasm, both optic tracts and subcortical structures of the left hemisphere **(Fig. 1a, b)**. Ophthalmological examination in our hospital revealed decrease in visual acuity to 0.1 in the right eye and almost blindness in the left eye, as well as right-sided homonymous hemianopia.

MR tractography of visual pathway was performed to select the optimal surgical approach **(Fig. 1c, d)**. Considering standard MRI and MR tractography data, we preferred a combined frontotemporal approach as the most optimal for this case.

Osteoplastic frontotemporal craniotomy was performed. At baseline, we used ultrasound imaging to determine depth of tumor near the left optic tract causing deformation of temporal lobe and subcortical structures. Corticotomy of the middle temporal gyrus was performed. We identified tumor tissue margin at a depth of 2.5 cm. The mass was dense and gray-yellow in color. Combined removal of tumor implied ultrasonic aspirator, bipolar cauterization, suction device and fenestrated forceps. As the tumor was resected, we visualized dura mater at the base of the middle cranial fossa and segment of ambient cistern medially. The next stage involved subfrontal approach to chiasmal region. A large tumor involving optic chiasm was exposed. We incised tumor capsule and excised a large mass replacing the left half of the chiasm. The lateral border of resection was internal carotid artery, superior border - A1 segment of anterior cerebral artery. Posteriorly, arachnoid membrane of interpeduncular cistern was exposed. Resection was accompanied by VEP monitoring via alternating flash stimulation of eyes and direct stimulation of visual pathways near the left optic tract. Electrophysiological medial stimulation of surgical field elicited stable responses from visual pathways in the area of the left optic tract **(Fig. 2b)**. This correlated with topography of optic tract fibers as determined by preoperative MR tractography.

Partial resection of tumor was performed to prevent neurological deterioration. After surgery, there was a defect with depression of brain parenchyma.

Histological examination revealed pilocytic astrocytoma (Grade I).

In early postoperative period, ophthalmological status improved. Visual acuity of the right eye increased to 0.2.

Contrast-enhanced MRI on the sixth postoperative day visualized partial resection of tumor, postoperative defect within the chiasm and the left optic tract, as well as regression of subcortical deformation **(Fig. 3)**.

Case # 2

A 5-year-old patient experienced right-sided fine-amplitude nystagmus, progressive visual acuity loss in both eyes and delayed physical growth for two years prior to surgery. Genetic evaluation revealed no objective clinical or laboratory evidence of neurofibromatosis type 1. Contrast-enhanced brain MRI revealed a mass involving the optic chiasm and third ventricle bottom with apred to optic tracts **(Fig. 4a**, b). Ophthalmological examination revealed visual acuity decrease to 0.3 in the left eye and almost blindness of the right eye. There were bitemporal visual field defects. Endocrine assessment revealed growth hormone deficiency and secondary hypothyroidism.

In our hospital, MR reconstruction of visual pathways was performed to assess their anatomical location and involvement in tumor process **(Fig. 4c**, d). Considering standard MR sequences and MR tractography, we preferred a right-sided subfrontal approach for tumor resection.

Right-sided osteoplastic frontal craniotomy was followed by right-sided subfrontal approach to chiasmal area. We visualized the tumor originating from the deformed

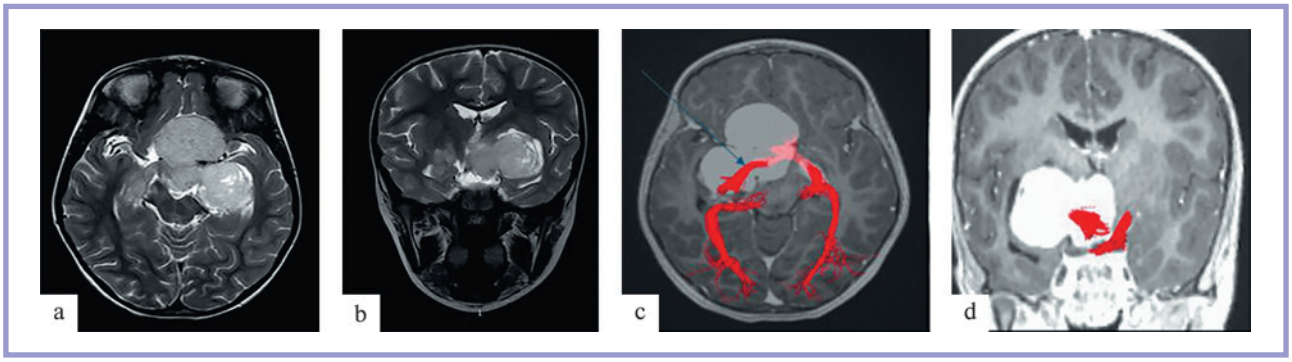

Fig. 1. **Patient 1.**
a, b — preoperative T2WI (a — axial scan, b — coronal scan). A tumor involving the chiasm, both optic tracts and subcortical structures of the left hemisphere is visualized; c, d — preoperative MR tractography of visual pathways in axial (c) and coronal (d) projections. The blue arrow indicates the left optic tract.

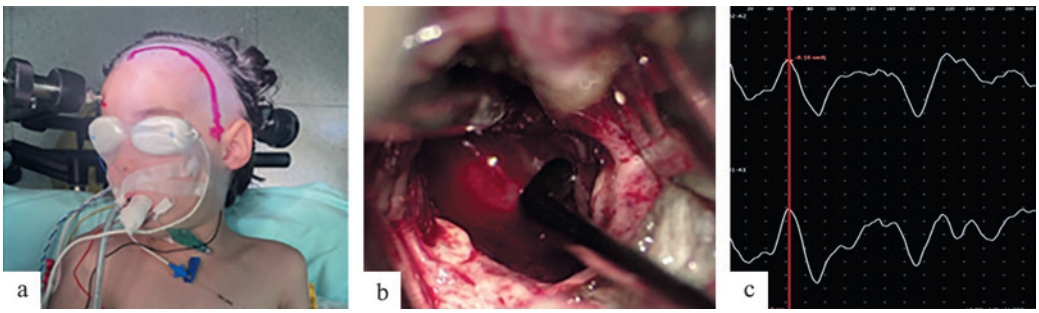

Fig. 2. **Patient 1.**
a — intraoperative image; b — direct stimulation of the left optic tract; c — visual evoked potential components following direct optic tract stimulation.

chiasm and ophthalmic segment of the right internal carotid artery. Direct stimulation elicited responses from visual pathways (both optic nerves, right optic tract and altered chiasm on both sides) **(Fig. 5)**. Tumor mass in anterior chiasm with minimal response amplitude was identified as the safest site for biopsy. Considering these findings, we performed open biopsy alone. Tumor tissue harvesting was performed using forceps in the area with minimal response to stimulation.

Histological examination revealed pilocytic astrocytoma (Grade I).

Early postoperative ophthalmological assessment showed no deterioration in visual function.

Follow-up brain MRI revealed findings consistent with open biopsy of chiasmal neoplasm **(Fig. 6)**.

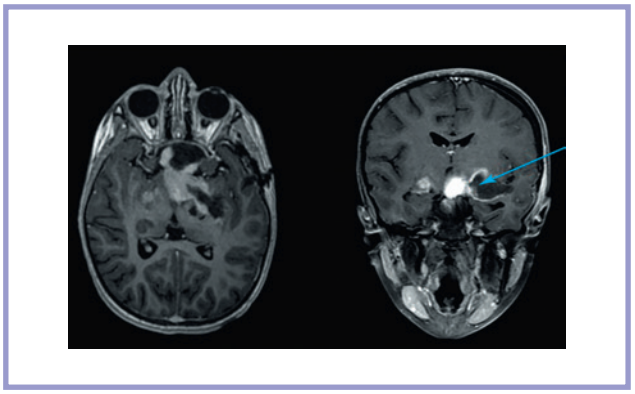

Fig. 3. **Patient 1.**
Contrast-enhanced axial and coronal T1WIs. Boundary of tumor resection zone near the left optic tract is marked with a blue arrow.

Discussion

Currently, there are no standardized approaches to surgical treatment of anterior visual pathway gliomas. Indications for surgery, extent of resection and optimal timing are a subject of active debate and disagreement. Importantly, total resection of these tumors is impossible due to growth from visual pathways, proximity of functionally critical brain structures and narrow surgical access. Consequently, surgical intervention usually implies biopsy, partial resection, sometimes subtotal resection and cerebrospinal fluid shunting procedures.

The primary objectives of resection are excision of tumor with minimal risk of visual dysfunction, relief of hydrocephalus (if present) and histological verification of tumor. According to many international authors [12—16], extent of resection depends on tumor location, visual function, neurological deficit and hydrocephalus. Preservation of preoperative visual function is the priority. Regardless of extent of resection, all patients undergo postoperative chemotherapy.

A meta-analysis demonstrated improvement of visual acuity in 24.6% of patients after various resections. Preoperative visual function was stable in the majority (68.2%) of patients, while visual impairment occurred in 18.2% of cases [17].

There are few data on intraoperative monitoring of visual function (visual evoked potentials) in surgery for anterior visual pathway gliomas. In recent years, VEP monitoring became interesting among neurosurgeons and neurophysiologists due to widespread intravenous anesthesia minimizing suppression of VEP components by anesthetic agents, technical advancements in intraoperative VEP recording equipment and improvements of software. These factors significantly enhanced accuracy and reliability of visual potential recording, as well as increased sensitivity and validity of this method [9, 11].

Available studies describe, among other things, intraoperative direct cortical and subcortical stimulation of visual pathways. However, the majority of these publications focus on surgery for hemispheric tumors near optic radiation and occipital lobe tumors [18—20]. To date, there are no similar studies regarding surgical treatment of anterior visual pathway gliomas in children.

MR tractography is aimed at reconstructing brain pathways (specifically, visual pathways) to assess their relationship to the tumor and involvement in patholog-

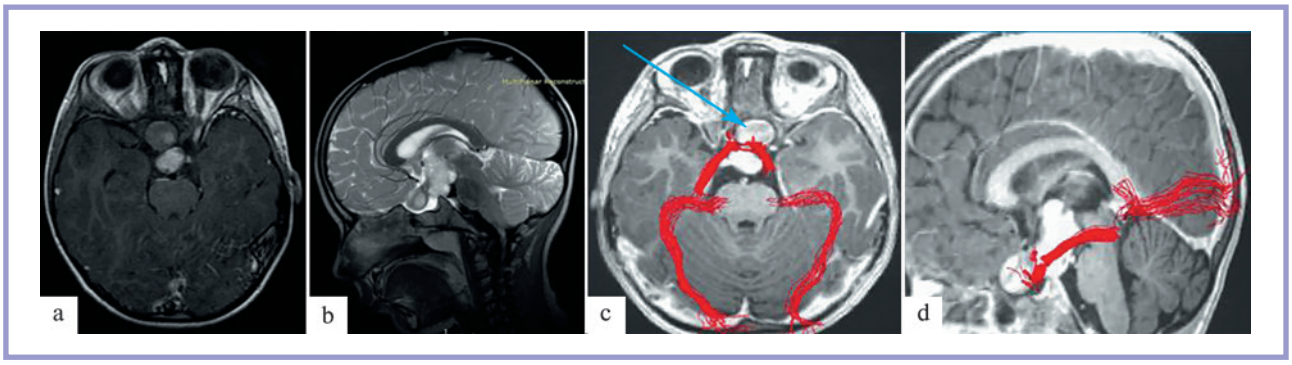

Fig. 4. **Case 2.**
T1- and T2-weighted images; a — axial scan, b — sagittal scan; there is a tumor involving optic chiasm and extending into the third ventricle and both optic tracts; c, d — preoperative MR tractography of visual pathways in axial (c) and sagittal (d) views. The blue arrow indicates the tumor not incorporating optic nerve fibers.

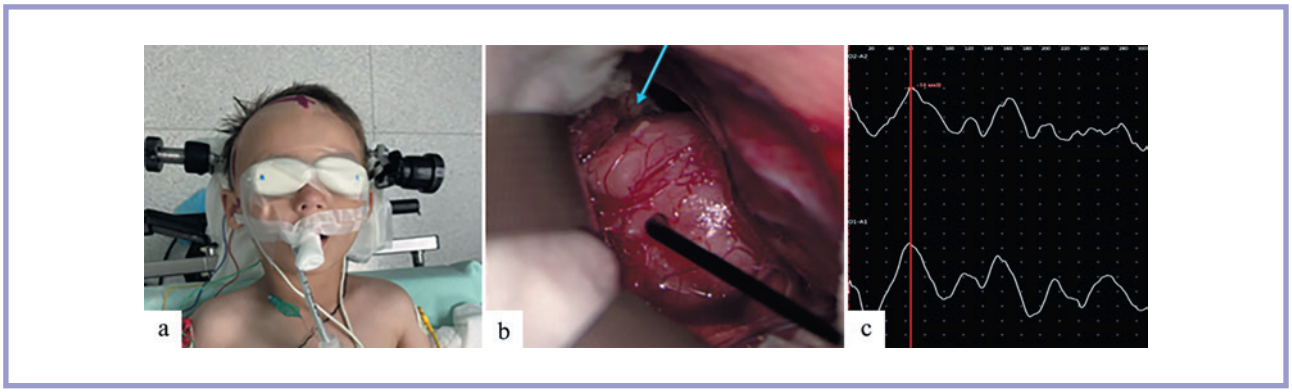

Fig. 5. **Case 2.**
a — intraoperative image; b — direct stimulation of anterior visual pathway structures (the blue arrow indicates the left optic nerve); c — components of visual evoked potentials following chiasmal stimulation.

ical process. Importantly, visual pathway possesses specific anatomical characteristics that pose significant challenges for reconstruction. For instance, its location near major blood vessels at the base of the brain and crossing of fibers at the optic chiasm complicate reconstruction. In light of these limitations, a reconstruction system based on high angular resolution diffusion imaging (CSD-HARDI) data was developed [7, 8]. We used this technique in two cases.

We chose surgical strategy considering neuroimaging and intraoperative monitoring data. Comparison of topographic data on visual pathway location with IOM results can be crucial for determining the optimal extent of resection.

In the 1st case, predominantly medial position of the left optic tract relative to the large tumor necessitated transtemporal approach. We determined resection margin via correlation with intraoperative monitoring data. In the 2nd case, MR tractography visualized visual pathways outside the tumor, and the last one was localized anterior to chiasm. IOM yielded responses from optic nerves, right optic tract and chiasm. We harvested histological specimens from the area with minimal amplitude of responses. Partial resection of tumor was carried out in both cases (partial resection in the first case and extended biopsy in the second case). In the first case, we observed mild ophthalmological improvement, specifically better visual acuity in the right eye. This was likely due to decompression of visual pathways. In the second case, there was no objective evidence of visual impairment.

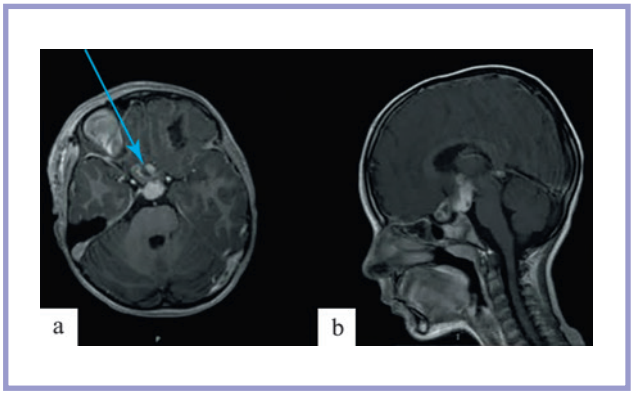

Fig. 6. **Case 2.**
Contrast-enhanced T1WI (a — axial; b — sagittal). The blue arrow indicates the biopsy site.

Conclusion

Preoperative MR tractography of visual pathways and intraoperative neurophysiological monitoring of visual evoked potentials combined with visual pathway identification in surgical treatment of anterior visual pathway gliomas in children may enable safer resection and reduce the risk of visual impairment. Further research is required for appropriate statistical analysis.

Author contribution:
Concept and design of the study — Gorelyshev S.K., Ogurtsova A.A., Golovin N.I.
Collection and analysis of data — Golovin N.I., Gorelyshev S.K., Ogurtsova A.A.
Writing the text — Golovin N.I.
Edited — Gorelyshev S.K., Ogurtsova A.A., Afandiev R.M.

No conflict of interests to declare.

REFERENCES

1. Elzaafarany O, Elhomosany S, Rincones A, Dlugi V, Mokhtari S. Optic Pathway Glioma: Current Treatment Approaches and Ongoing Clinical Trials. *Brain Sciences.* 2025;15(8):894. https://doi.org/10.3390/brainsci15080894
2. Amato A, Imbimbo BP, Falsini B. Neurofibromatosis type 1-associated optic pathway gliomas: pathogenesis and emerging treatments. *European Review for Medical and Pharmacological Sciences.* 2023;27(12):5636-5653. https://doi.org/10.26355/eurrev_202306_32804
3. Chen Y, Yu J, Ge S, Jia R, Song X, Wang Y, Fan X. An Overview of Optic Pathway Glioma With Neurofibromatosis Type 1: Pathogenesis, Risk Factors, and Therapeutic Strategies. *Investigative Ophthalmology & Visual Science.* 2024;65(6):8. https://doi.org/10.1167/iovs.65.6.8
4. Kim JW, Phi JH, Kim SK, Lee JH, Park SH, Won JK, Choi JY, Kang HJ, Park CK. Comparison of the clinical features and treatment outcomes of pilocytic astrocytoma in pediatric and adult patients. *Child's Nervous System.* 2023;39(3):583-591. https://doi.org/10.1007/s00381-023-05839-x
5. Modrzejewska M, Olejnik-Wojciechowska J, Roszyk A, Szychot E, Konczak TD, Szemitko M, Peregud-Pogorzelski JW. Optic Pathway Gliomas in Pediatric Population-Current Approach in Diagnosis and Management: Literature Review. *Journal of Clinical Medicine.* 2023;12(21):6709. https://doi.org/10.3390/jcm12216709
6. Yaman Bajin I, Bouffet E. Optic pathway and hypothalamic glioma, old problems, new paradigms. *Pediatric Hematology Oncology Journal.* 2023;8(2):102-110. https://doi.org/10.1016/j.phoj.2023.04.003
7. Li S, Xiao W, Tong Z, Li L, Zhang Y. The Use of Diffusion Tensor Imaging in the Differentiation and Surgical Planning of Suprasellar Hypothalamic-Opticochiasmatic Glioma and Craniopharyngioma in Children. *World Neurosurgery.* 2024;193:474-482. https://doi.org/10.1016/j.wneu.2024.09.074
8. Carrozzi A, Gramegna LL, Sighinolfi G, Zoli M, Mazzatenta D, Testa C, Lodi R, Tonon C, Manners DN. Methods of diffusion MRI tractography for localization of the anterior optic pathway: A systematic review of validated methods. *NeuroImage: Clinical.* 2023;39:103494. https://doi.org/10.1016/j.nicl.2023.103494
9. Soumpasis C, Díaz-Baamonde A, Ghimire P, Baig Mirza A, Borri M, Jarosz J, Gullan R, Ashkan K, Bhangoo R, Vergani F, Lavrador JP, Mirallave Pescador A. Intraoperative Neuromonitoring of the Visual Pathway in Asleep Neuro-Oncology Surgery. *Cancers.* 2023;15(15):3943. https://doi.org/10.3390/cancers15153943
10. Guzzi G, Ricciuti RA, Della Torre A, Lo Turco E, Lavano A, Longhini F, La Torre D. Intraoperative Neurophysiological Monitoring in Neurosurgery. *Journal of Clinical Medicine.* 2024;13(10):2966. https://doi.org/10.3390/jcm13102966
11. Olmsted ZT, Silverstein JW, Einstein EH, Sowulewski J, Nelson P, Boockvar JA, D'Amico RS. Evolution of flash visual evoked potentials to monitor visual pathway integrity during tumor resection: illustrative cases and literature review. *Neurosurgical Review.* 2023;46(1):46. https://doi.org/10.1007/s10143-023-01955-z
12. Kim JW, Kim SK. The role of surgery for optic pathway gliomas in the era of precision medicine. *Child's Nervous System.* 2024;40(10):3075-3083. https://doi.org/10.1007/s00381-024-06450-4
13. Karbe AG, Gorodezki D, Schulz M, Tietze A, Gruen A, Driever PH, Schuhmann MU, Thomale UW. Surgical options of chiasmatic hypothalamic glioma-a relevant part of therapy in an interdisciplinary approach for tumor control. *Child's Nervous System.* 2024;40(10):3065-3074. https://doi.org/10.1007/s00381-024-06498-2
14. Bertalanffy H, Gallieni M, Mahmoodi R, Fahlbusch R, Kar S, Di Rocco C. Surgical Treatment of Optic Pathway Hypothalamic Gliomas. *Advances and Technical Standards in Neurosurgery.* 2025;55:17-45. https://doi.org/10.1007/978-3-031-90762-3_2
15. Samples DC, Mulcahy Levy JM, Hankinson TC. Neurosurgery for Optic Pathway Glioma: Optimizing Multidisciplinary Management. *Frontiers in Surgery.* 2022;9:884250. https://doi.org/10.3389/fsurg.2022.884250
16. Hill CS, Khan M, Phipps K, Green K, Hargrave D, Aquilina K. Neurosurgical experience of managing optic pathway gliomas. *Child's Nervous System.* 2021;37(6):1917-1929. https://doi.org/10.1007/s00381-021-05060-8
17. Albalkhi I, Shafqat A, Bin-Alamer O, Mallela AN, Gersey ZC, Fernandes Cabral D, Sabbagh AJ, Hadjipanayis CG, González-Martínez JA, Friedlander RM, Abou-Al-Shaar H. Complications and visual outcomes following surgical resection of pediatric optic pathway/hypothalamic gliomas: a systematic review and meta-analysis. *Child's Nervous System.* 2024;40(7):2033-2042. https://doi.org/10.1007/s00381-024-06407-7
18. Bezbabicheva TS, Maryashev SA, Ogurtsova AA, Eliseeva NM, Afandiev RM, Pogosbekyan EL, Pronin IN, Pitskhelauri DI. Intraoperative monitoring of cortical visual evoked potentials in resection of tumors near the optic radiation. *Burdenko's Journal of Neurosurgery.* 2025;89(6):46-53. (In Russ.). https://doi.org/10.17116/neiro20258906146
19. Maryashev SA, Dombaanai BS, Eliseeva NM, Ogurtsova AA, Bayev AA, Pitskhelauri DI, Pronin IN. Intraoperative visual evoked potential recording in occipital tumor surgery. *Burdenko's Journal of Neurosurgery.* 2023;87(4):35-45. (In Russ.). https://doi.org/10.17116/neiro20238704135
20. Carrai R, Martinelli C, Baldanzi F, Gabbanini S, Gori B, Masi G, Troiano S, Bonaudo C, Esposito A, Muscas G, Tola S, Caramelli R, Spalletti M, Lolli F, Grippo A, Bucciardini L, Amadori A, Della Puppa A. Feasibility of Intraoperative Visual Evoked Potential Monitoring by Cortical Strip Electrodes in Patients During Brain Surgery: A Preliminary Study. *World Neurosurgery.* 2023;171:175-180.e0. https://doi.org/10.1016/j.wneu.2022.12.032

Received 04.06.2026
Accepted 20.07.2026

Comment

Anterior visual pathway gliomas are rare and account for 20—30% of all gliomas in children. Treating these tumors is still a highly complex challenge. On one hand, these gliomas are intimately associated with functionally critical structures, on the other — postoperative outcome and disability are decisive factors for the child's future. Consequently, the goal is not merely surgical treatment but also preservation of function (vision).

The authors present two pediatric patients with visual pathway gliomas who underwent surgery under intraoperative neurophysiological monitoring and MR tractography to ensure procedural safety. This combination of methods enabled effective preoperative planning and real-time intraoperative monitoring.

Once again, we see a successful example of interdisciplinary integration across neuro-specialties involving coordinated efforts of neurosurgeons, neurophysiologists, ophthalmologists and imaging specialists.

Semenova Zh.B. (Moscow)