Burdenko's Journal of Neurosurgery
2026, No. 5, pp. 32–38
https://doi.org/10.17116/neiro20269005132

Clinical presentation of brain abscesses: from classic triad to silent forms

© A.I. Baranich, A.A. Sychev, I.A. Savin, N.V. Kurdyumova, M.V. Sukhorukova, D.N. Andreev, O.I. Sharipov, Z.Sh. Veliev, D.S. Korotkov

Burdenko Neurosurgical Center, Moscow, Russia

ABSTRACT

Despite relatively small incidence, brain abscesses are life-threatening with high risk of death and persistent neurological deficits. A key factor limiting early diagnosis is polymorphic and nonspecific clinical presentation.

Objective. To analyze the structure and incidence of clinical symptoms in a cohort of patients with brain abscesses treated at the Burdenko Neurosurgical Center.

Material and methods. A single-center study was based on medical records of patients with newly diagnosed and confirmed brain abscesses hospitalized for surgical treatment at the Burdenko Neurosurgery Center between January 2022 and December 2025. Verification was based on contrast-enhanced MRI and/or intraoperative data.

Results. The study included 41 patients with verified intracranial abscesses. The most common symptoms were headache (51.2%) and focal neurological deficit (48.8%). Fever was detected in 19.5% of patients, classic triad (headache, focal neurological deficit, fever) — in only 7.3% of patients. There were no symptoms (subclinical presentation) in 19.5% of patients. Atypical and silent forms of disease comprised 73.2%.

Conclusion. Silent and atypical forms account for 73.2% of cases, while classic triad of symptoms is recorded in only 7.3% of patients. This decreases its diagnostic value. In this regard, patients with focal neurological symptoms or severe headaches, even afebrile cases, and previous possible cause of infection (otitis, sinusitis, odontogenic infection, etc.) seem reasonable not only to have brain abscess but also be scheduled for neuroimaging with specialized modes.

Keywords: *abscess, CNS infection, brain abscesses, clinical presentation.*

INFORMATION ABOUT THE AUTHORS:
Baranich A.I. — https://orcid.org/0000-0002-1167-0742
Sychev A.A. — https://orcid.org/0000-0002-0038-1005
Savin I.A. — https://orcid.org/0000-0003-3874-4147
Kurdyumova N.V. — https://orcid.org/0000-0002-9741-0692
Sukhorukova M.V. — https://orcid.org/0000-0002-1168-2356
Andreev D.N. — https://orcid.org/0000-0001-5473-4905
Sharipov O.I. — https://orcid.org/0000-0003-3777-5662
Veliev Z.Sh. — https://orcid.org/0009-0004-4545-8215
Korotkov D.S. — https://orcid.org/0000-0002-2204-4480
Corresponding author: Baranich A.I. — e-mail: anastasia.baranich@gmail.com

TO CITE THIS ARTICLE:
Baranich AI, Sychev AA, Savin IA, Kurdyumova NV, Sukhorukova MV, Andreev DN, Sharipov OI, Veliev ZSh, Korotkov DS. Clinical presentation of brain abscesses: from classic triad to silent forms. *Burdenko's Journal of Neurosurgery*. 2026;90(4):32–38. (In Russ.).
https://doi.org/10.17116/neiro20269005132

Introduction

Despite relatively low incidence, brain abscesses are still a life-threatening condition with high risk of death and persistent neurological deficits [1, 2]. Polymorphic and nonspecific clinical presentation is a key factor complicating early diagnosis. Therefore, updated data on prevalence of symptoms in patients with a verified diagnosis of brain abscess are necessary.

The purpose of this study was to analyze the structure and incidence of symptoms in patients with brain abscesses treated at the Burdenko Neurosurgery Center.

An additional objective was description of typical symptom combinations and incidence of atypical and latent forms of disease.

Material and methods

A single-center study was based on analysis of medical records. The study included patients with newly diagnosed brain abscesses hospitalized for surgical treatment at the Burdenko Neurosurgery Center between January 2022 and December 2025. The diagnosis was verified

by contrast-enhanced MRI and/or intraoperative data. Exclusion criteria: extracranial abscesses (spinal abscesses, those associated with distal end of shunt system, etc.), concomitant intracranial infections or soft tissue infections of the head, recurrent brain abscesses.

To ensure data completeness, we used a hospital-based clinical and microbiological monitoring system. The last one has functioned since 2022. If infection was suspected, the attending physician consulted the antibacterial therapy team. This fact was recorded in medical record together with diagnosis and treatment regimen. Monthly analysis of all antibacterial therapy prescriptions allows us to assess dynamics of pathogens causing hospital-acquired and community-acquired infections. This monitoring enabled identification and subsequent analysis of all patients with brain abscess throughout the specified period.

Results

Over a four-year period, 64 patients with abscess were admitted to the Burdenko Neurosurgery Center. According to exclusion criteria, 41 patients with intracranial abscesses were included. The excluded cases predominantly included extracranial abscesses, as well as abscesses as complications of meningitis, osteomyelitis or recurrences of previous process. The study group included five pediatric patients (age 1—10 years) and 36 adults. Among adults, mean age was 56.1 years (range 28—78). There were 19 women and 17 men.

The most common clinical signs of brain abscesses were headache and focal neurological deficit (51.2% (*n*=21) and 48.8% (*n*=20) of patients, respectively) **(Fig. 1)**. Fever was less common (only 19.5% (*n*=8) of patients).

The classic triad (headache, focal neurological deficit, fever), typical for brain abscesses [3], was verified in only 7.3% (*n*=3) of patients **(Fig. 2)**. In contrast, 19.5% (*n*=8) of patients had subclinical presentation without these symptoms.

Analysis of clinical manifestations of brain abscess revealed predominant atypical and latent forms (73.2%, *n*=30). These forms were more common than classic symptom complex and indicated lower prognostic value for baseline diagnosis.

Single-symptom variants predominated among atypical and latent forms (53.7% (*n*=22) of patients) **(Table 1)**. Focal neurological deficit (31.7%; *n*=13) and headache alone (22.0%; *n*=9) were the most common. No isolated fever was observed.

Two-symptom forms were observed in 19.5% (*n*=8) of patients. The most common combination was focal deficit with headache and no fever (9.8%; *n*=4). Combination of focal deficit with fever was observed in 7.3% (*n*=3) of cases, and combination of headache with fever was the least common (2.4%; *n*=1).

Previous epileptic seizures were observed in 18.2% (*n*=6/33) of patients, and they took basic anticonvulsant therapy upon admission. The vast majority of patients (81.8%; *n*=27) did not have previous and in-hospital seizures.

Table 1. **Clinical manifestations of brain abscess.**

Symptoms	Number of patients, *n*	%
I. Classic triad (headache, focal neurological deficit, fever)	3	7.3
II. Subclinical form (no symptoms)	8	19.5
III. Atypical / latent forms	30	73.2
A. Single-symptom	22	53.7
Focal neurological deficit alone	13	31.7
Headache alone	9	22.0
Fever alone	0	0
B. Two symptoms	8	19.5
Headache + focal neurological deficit	4	9.8
Headache + fever	1	2.4
Focal neurological deficit + fever	3	7.3

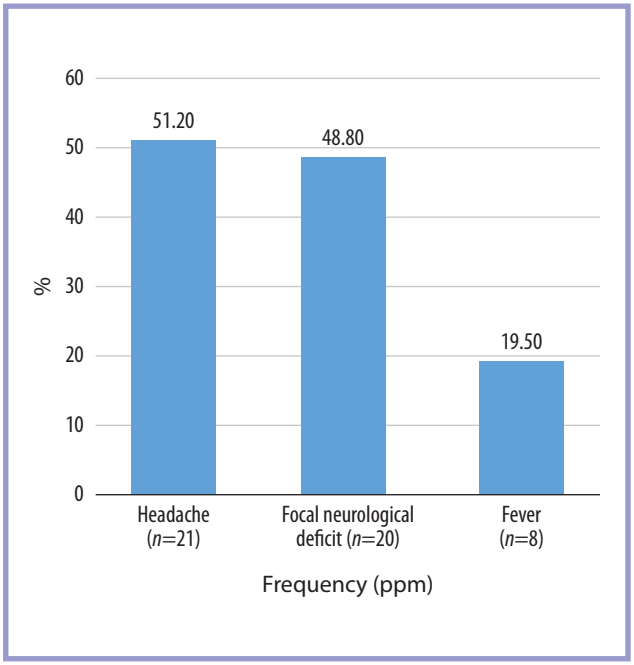

Fig. 1. **Incidence of various clinical signs in brain abscesses (*n*=41).**

Microbiological characteristics. Gram-positive cocci prevailed among microbiological pathogens. Staphylococcus spp. was detected in 26.8% of cases. Of these, S. aureus comprised 36.4%. Streptococcus spp. was isolated in 19.5% of cases **(Fig. 3)**. In some cases, these microorganisms were found together with anaerobic flora.

Among gram-negative species, Enterobacter cloacae, Pseudomonas aeruginosa, Citrobacter freundii, Escherichia coli and Klebsiella aerogenes were identified in 12.2% (5 out of 41 cases) of patients.

Table 2. **Clinical presentation in various pathogens.**

Pathogen	*n*	Focal deficit, % (*n*)	Fever, % (*n*)	Headache, % (*n*)
Staphylococcus spp.	11	27.3 (3)	9.1 (1)	45.5 (5)
Streptococcus spp.	8	62.5 (5)	37.5 (3)	75 (6)
All gram-negative pathogens	4	25 (1)	25 (1)	50 (2)
Eikenella corrodens	1	100 (1)	0	100 (1)
Nocardia abscessus	1	100 (1)	100 (1)	0
Listeria monocytogenes	1	0	0	0
Aspergillus fumigatus	1	0	0	0

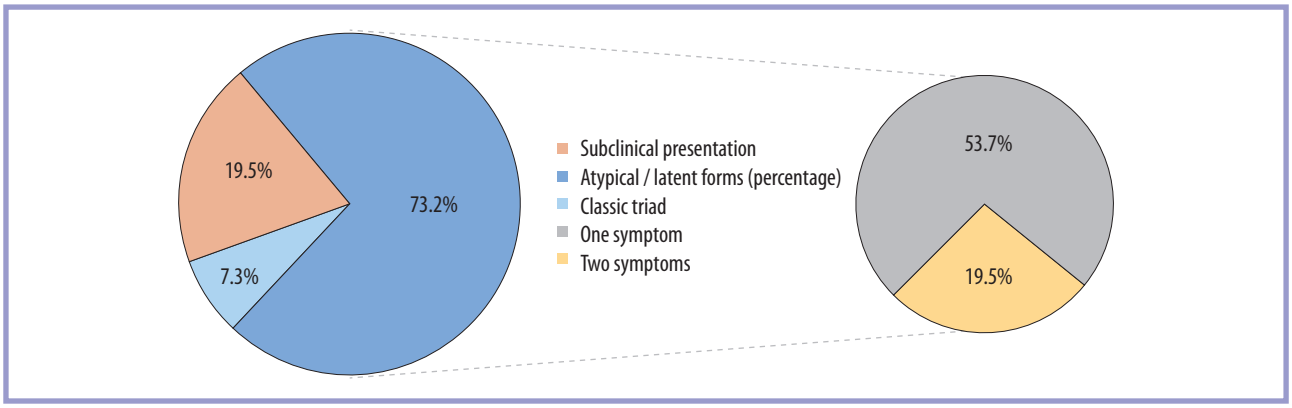

Fig. 2. **Distribution of patients with brain abscesses depending on clinical presentation.**

Anaerobic spectrum included Eikenella corrodens, Actinomyces odontolyticus and Veillonella parvula. In addition, Nocardia abscessus and Listeria monocytogenes were found in 2 cases. In one case, postoperative abscess had fungal nature (Aspergillus fumigatus).

No microbial growth was noted in 31.7% of samples. There were no HIV-positive patients. However, six patients had previous radiotherapy.

Our previous analysis revealed a relationship between etiology and spectrum of microorganisms, with the latter largely determined by primary infectious factor [4].

Relationship between pathogen and clinical presentation. Our results do not allow for significant conclusions due to small sample size. Nevertheless, we analyzed possible associations between abscess etiology and clinical manifestations.

In staphylococcal infection, focal neurological deficit was observed in only 27.3% of cases, fever - in 9.1%. Headache was the most common symptom (45.5%). Asymptomatic course of abscesses caused by methicillin-resistant Staphylococcus aureus (MRSA) in this cohort is noteworthy.

Streptococci are characterized by high incidence of focal deficit (62.5%) and headache (75%), but these symptoms are not mandatory. Fever was recorded in 37.5% of cases, primarily in abscesses associated with S. pneumoniae and combination of S. intermedius with Actinomyces odontolyticus.

Among Gram-negative pathogens, only E. coli was accompanied by a comprehensive triad of symptoms. C. freundii presented with headache alone, while E. cloacae and P. aeruginosa were not accompanied by any clinical manifestations.

There were no significant differences in clinical picture between groups of Gram-positive, Gram-negative and anaerobic pathogens due to small sample size.

Discussion

In a modern cohort of patients with brain abscesses, latent and atypical forms occur in 19.5% and 53.7% of cases, respectively, while their total proportion is 73.2%. Classic diagnostic triad (headache, focal neurological deficit and fever) was detected in only 7.3% of patients. This limited its primary role in baseline diagnosis.

This pattern (predominant latent and atypical forms with low incidence of classic triad) may be due to several factors. First, the great number of patients with concomitant immunosuppression (e.g., after chemo- or radiotherapy, prolonged intake of glucocorticosteroids, etc.) naturally weakens systemic inflammatory response. In our study, 14.6% of patients had previous radiotherapy. Secondly, widespread and often empirical antibacterial outpatient therapy can partially suppress infectious process and mask typical symptoms.

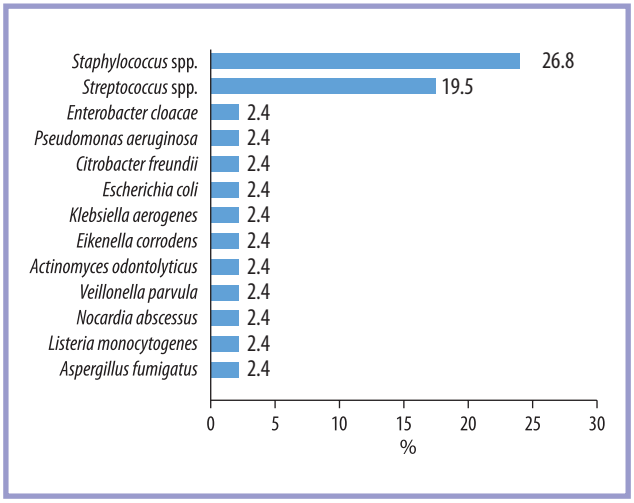

Fig. 3. **Spectrum of abscess pathogens.**

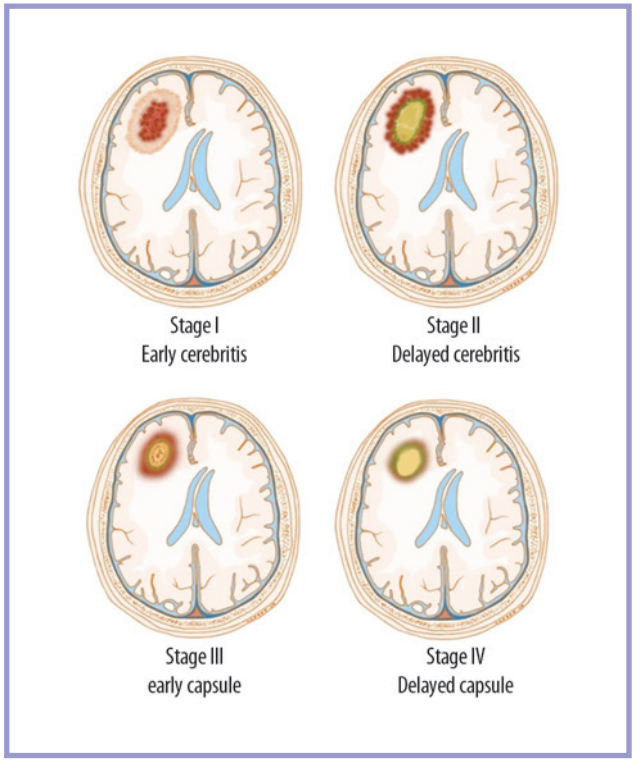

Fig. 4. **Stages of brain abscess.**

Abscess is a dynamic process **(Fig. 4)**. Early cerebritis (1–3 days) is characterized by severe vasogenic edema without purulent core. In delayed stage of cerebritis (4–9 days), necrotic center and capsule appear. Perifocal edema reaches maximum, and it is the main mechanism of symptoms (headache, focal deficit) at this stage [5].

According to the literature, the period between onset of disease and seeking medical attention has recently decreased from 8 to 3 days [6]. This corresponds to the period of early and late cerebritis. Availability of highly sensitive neuroimaging methods allows for diagnosis at these stages. Encapsulation stage (after 10–14 days) is characterized by dense capsule and regression of edema, but focal gliosis occurs. The last one becomes a precursor to long-term complications such as epilepsy.

The incidence of seizures in our study (18.2%) is consistent with literature data and confirms the role of this complication [7]. Identification of risk factors of epileptic seizures (localization of abscess, seizures upon admission) dictates the need for careful neurological and electrophysiological monitoring in these patients, as well as requires special attention to antibacterial therapy to minimize drug-drug interactions with anticonvulsants [8].

We found no significant differences in clinical picture between patients with different pathogens due to small sample size (n=41). However, qualitative analysis revealed certain trends. In case of staphylococcal etiology, focal neurological disorders occurred only in 27%, fever — in 9%, headache — in 45.5% of cases. Streptococci were characterized by higher incidence of focal neurological disorders (62.5%) and headache (75%); fever occurred in 37.5% of cases (mainly in S. pneumoniae and association with A. odontolyticus). Among gram-negative pathogens, only E. coli gave the classic triad of symptoms, while E. cloacae and P. aeruginosa were not accompanied by any symptoms. Rare pathogens (Eikenella corrodens, Nocardia abscessus, Listeria monocytogenes, Aspergillus fumigatus) demonstrated various clinical patterns, but clear conclusions were impossible due to small sample size.

This study adds to the evidence that clinical picture can vary, even with the same source of infection.

Thus, focusing on fever and classical symptoms is ineffective for timely diagnosis of brain abscess. In a patient with potential source of infection (otitis, sinusitis, odontogenic lesion, infective endocarditis, etc.), appearance or progression of focal neurological deficit or severe headache, even without fever, should inspire neuroimaging with special modes and targeted inclusion of brain abscess in differential range both when planning the examination protocol and interpreting the results.

Contrast-enhanced MRI of the brain is the “gold standard” of neuroimaging to confirm the diagnosis and determine treatment strategy. Indeed, MRI is superior to CT in sensitivity and specificity. A decisive advantage of MRI is diffusion-weighted images where purulent content of abscess demonstrates a pathognomonic sign, e.g. restricted diffusion (high signal on diffusion-weighted images and low signal on ADC maps). This sign is the most significant differential criterion for distinguishing between abscess and tumor [9]. In addition, MRI is critical for diagnosis of life-threatening complications, such as abscess rupture into ventricular system with subsequent ventriculitis. This event should be suspected in case of sudden progression of cephalalgia and meningeal symptoms [10].

Conclusion

Our findings demonstrate clinical features of brain abscess in modern cohort. Latent and atypical forms account for 73.2% of cases, while classic triad of symptoms is recorded in only 7.3% of patients. This fact decreases significance of this diagnostic sign. Thus, even afebrile patients with focal neurological symptoms or severe headache and previous possible source of infection (otitis, sinusitis, odontogenic infection, etc.) require inclusion of brain abscess in differential diagnostic range and appropriate neuroimaging.

Author contribution:
Concept and design of the study — Baranich A.I., Sychev A.A.
Collection and analysis of data — Baranich A.I., Kurdyumova N.V., Sukhorukova M.V., Veliev Z.Sh., Korotkov D.S.
Statistical analysis — Baranich A.I., Sharipov O.I.
Writing the text — Baranich A.I.
Illustrations — Andreev D.N.
Editing — Sychev A.A., Savin I.A., Sukhorukova M.V., Kurdyumova N.V., Andreev D.N., Sharipov O.I.

No conflict of interests to declare.

REFERENCES

1. Bodilsen J, Eriksen EM, Nielsen MD, Duerlund LS, Mariager T, Nielsen H, Brouwer MC. Clinical features and outcome of brain abscess after introduction of CT and MRI: A meta-analysis. *Journal of Infection*. 2025; 90(2):106394. https://doi.org/10.1016/j.jinf.2024.106394
2. Bodilsen J, D'Alessandris QG, Humphreys H, Iro MA, Klein M, Last K, Montesinos IL, Pagliano P, Sipahi OR, San-Juan R, Tattevin P, Thurnher M, de J Treviño-Rangel R, Brouwer MC; ESCMID Study Group for Infections of the Brain (ESGIB). European society of Clinical Microbiology and Infectious Diseases guidelines on diagnosis and treatment of brain abscess in children and adults. *Clinical Microbiology and Infection*. 2024;30(1):66-89. https://doi.org/10.1016/j.cmi.2023.08.016
3. Brouwer MC, Coutinho JM, van de Beek D. Clinical characteristics and outcome of brain abscess: systematic review and meta-analysis. *Neurology*. 2014;82(9):806-813. https://doi.org/10.1212/WNL.0000000000000172
4. Baranich AI, Sychev AA, Savin IA, Kurdyumova NV, Sukhorukova MV, Veliev ZSh, Korotkov DS, Kakurin KO, Kudrina VG. Causes and microbiological spectrum of brain abscesses: modern data. *Burdenko's Journal of Neurosurgery*. 2026;90(3):36-41. (In Russ.). https://doi.org/10.17116/neiro20269003136
5. Akhaddar A. *Atlas of Infections in Neurosurgery and Spinal Surgery*. Cham: Springer International Publishing; 2017.
6. Bodilsen J, Duerlund LS, Mariager T, Brandt CT, Petersen PT, Larsen L, Hansen BR, Omland LH, Tetens MM, Wiese L, Jørgensen RL, Leth S, Nielsen H; DASGIB study group. Clinical features and prognostic factors in adults with brain abscess. *Brain*. 2023;146(4):1637-1647. https://doi.org/10.1093/brain/awac312
7. Bodilsen J, Duerlund LS, Mariager T, Brandt CT, Wiese L, Petersen PT, Larsen L, Hansen BR, Omland LH, Tetens MM, Jørgensen RL, Leth S, Nielsen H; for DASGIB. Risk Factors and Prognosis of Epilepsy Following Brain Abscess: A Nationwide Population-Based Cohort Study. *Neurology*. 2023;100(15):e1611-e1620. https://doi.org/10.1212/WNL.0000000000206866
8. Baranich AI, Sychev AA, Savin IA, Kudrina VG. Drug interactions in neurosurgical patients. *Burdenko's Journal of Neurosurgery*. 2023;87(6):100-105. https://doi.org/10.17116/neiro202387061100
9. Moradi Z, Mohammadzadeh S, Mohebbi A, Noshak AS, Moradi N, Mohammadi A, Sotoudeh H. Diagnostic Performance of DWI and ADC Parameter in Differentiating Brain Abscess from Malignant Ring-Enhancing Brain Lesions: A Systematic Review and Meta-analysis. *European Journal of Radiology*. 2026;195:112531. https://doi.org/10.1016/j.ejrad.2025.112531
10. Achempim-Ansong P, Darko NK, Ju R, Barrie U. Primary intraventricular brain abscess: a systematic review of risk factors, etiology, and management. *Egyptian Journal of Neurosurgery*. 2025;40:101. https://doi.org/10.1186/s41984-025-00446-1

Received 17.02.2026
Revised 29.04.2026
Accepted 07.05.2026

Comment

The authors analyzed symptoms of brain abscesses and variants of clinical manifestations. They emphasize significant prevalence of atypical forms not corresponding to classical triad of symptoms. Many patients with 1—2 symptoms and asymptomatic forms indicate low value of clinical, laboratory and neurological assessments in diagnosis of brain abscesses. Spectrum of microorganisms detected in 68% of patients with abscesses did not reveal a clear correlation with clinical manifestations. The authors emphasize the role of MR features. The last ones are usually decisive in diagnosis of brain abscesses, especially in latent and asymptomatic forms of disease. The relationship of clinical variants with abscess location and size, cerebrospinal fluid pathway occlusion, severity of perifocal edema and brain dislocation is the subject of subsequent studies.

Grigoryan Yu.A. (Moscow)