Burdenko's Journal of Neurosurgery 2026,
No. 5, pp. 25-31
https://doi.org/10.17116/neiro20269005125

Intraoperative rupture of cerebral aneurysms during microsurgical clipping as a risk factor of residual aneurysm enlargement

© Yu.V. Pilipenko[1, 2], Sh.Sh. Eliava[1], M.B. Kholmatov[1], D.A. Starostenko[3], D.N. Okishev[1], A.N. Konovalov[1, 2], F.V. Grebenev[1]

[1]Burdenko Neurosurgery Center, Moscow, Russia;
[2]Sechenov First Moscow State Medical University (Sechenov University), Moscow, Russia;
[3]Pirogov Russian National Research Medical University, Moscow, Russia.

ABSTRACT

Background. Aneurysm neck clipping is preferable for saccular aneurysms due to stable occlusion. However, postoperative follow-up angiography reveals residual aneurysm in some cases after clipping. Long-term outcomes depend on clipping quality. Currently, there is no consensus regarding further management of these patients.

Objective. To analyze residual cerebral aneurysms within the first year after surgery, and to identify prognostic factors of enlargement and rupture of aneurysm remnant.

Material and methods. In 2024, clipping of 654 cerebral aneurysms in 550 patients was performed. Residual aneurysms were identified in 49 (7.5%) cases. Clipping quality was estimated in accordance with classification by Yu.V. Pilipenko. Three patients with partial exclusion (R4) underwent redo surgery in early postoperative period. Among 46 patients with residual aneurysms, we enrolled 25 patients with available clinical and angiographic data within one year after surgery.

Results. There were no CT signs of residual aneurysm enlargement in 22 (88%) out of 25 cases. In two patients (8%), enlargement of remnant required redo clipping. Fatal rupture of aneurysm remnant occurred in 1 (4%) case. All three patients experienced intraoperative aneurysm rupture during primary surgery.

Conclusion. Intraoperative rupture significantly increases the risk of residual aneurysm enlargement. Localization in Anterior communicating artery (ACjoA) and clipping quality ≥R3 are potential risk factors requiring further studies of larger cohorts.

Keywords: *residual aneurysm, incomplete clipping, aneurysm remnant, cerebral aneurysm clipping, aneurysm growth, intraoperative rupture.*

INFORMATION ABOUT THE AUTHORS:
Pilipenko Yu.V. — https://orcid.org/0000-0003-4001-3212
Eliava Sh.Sh. — https://orcid.org/0000-0001-6103-9329
Kholmatov M.B. — https://orcid.org/0000-0001-9916-722X
Starostenko D.A. — https://orcid.org/0009-0005-3436-4579
Okishev D.N. — https://orcid.org/0000-0003-0815-5624
Konovalov An.N. — https://orcid.org/0000-0002-0932-4752
Grebenev F.V. — https://orcid.org/0000-0003-2622-7804
Corresponding author: Starostenko D.A. — e-mail: daria-starosten@yandex.ru

TO CITE THIS ARTICLE:
Pilipenko YuV, Eliava ShSh, Kholmatov MB, Starostenko DA, Okishev DN, Konovalov AnN, Grebenev FV. Intraoperative rupture of cerebral aneurysms during microsurgical clipping as a risk factor of residual aneurysm enlargement. *Burdenko's Journal of Neurosurgery*. 2026;90(5):25–31. (In Russ.). https://doi.org/10.17116/neiro20269005125

Abbreviations

CTA — computed tomography angiography
ACoA — anterior communicating artery

Introduction

Cerebral aneurysm neck clipping is a preferable approach providing the most stable occlusion. A key prognostic factor for favorable long-term outcomes is total occlusion of aneurysm.

Residual aneurysm detection rate ranges from 6.55% to 11.9% depending on sensitivity of intraoperative and postoperative imaging methods [1, 2]. Such a remnant is a clinically significant factor, as it poses potential risk of aneurysm enlargement and rupture [3, 4]. Consequently, patients with residual aneurysms are advised to undergo follow-up angiography for detection of residual aneurysm changes in a timely manner.

The purpose of the study was to analyze evolution of residual cerebral aneurysms within the first year after surgery and to identify prognostic factors of aneurysm remnant enlargement and rupture.

Material and methods

In 2024, there were 550 patients with 654 cerebral aneurysms who underwent surgery at the 3rd clinical department of the Burdenko Neurosurgery Center.

All aneurysms were saccular. We excluded patients with fusiform aneurysms, as these cases typically involve more complex procedures with another classification of clipping quality.

We assessed clipping quality after 2—6 postoperative days using CTA or cerebral angiography.

To classify aneurysm remnants, we used a previously proposed classification for saccular aneurysms [5]. This classification distinguishes 5 grades of occlusion: R1 — total occlusion; R2 — subtotal occlusion (partial contrast enhancement of aneurysm neck up to 1 mm); R3 — residual neck (1—3 mm, no diverticula or additional chambers); R4 — partial occlusion (partial contrast enhancement of aneurysm fundus, another aneurysm chamber or diverticulum of the neck); R5 — no occlusion (contrast enhancement of the entire aneurysm dome).

Postoperative in-hospital angiography revealed residual aneurysms in 49 (7.5%) cases: R2 in 34 patients, R3 in 12 and R4 in 3 cases.

Three patients with grade R4 underwent redo surgery in early postoperative period (microsurgical clipping — 2, endovascular occlusion with microcoils resulting in total occlusion of residual component — 1). One patient had residual aneurysm grade R3 after redo microsurgical procedure.

We analyzed data on 47 patients discharged with residual cerebral aneurysms over subsequent 1-year follow-up. Follow-up clinical data (covering at least one year) were available for 46 patients, angiographic data - for 24 patients.

Three patients died throughout the follow-up period. In two cases, the exact cause of death was not verified. We excluded these patients from final analysis because it was impossible to confirm or rule out the relationship between death and residual aneurysm rupture.

One patient died from intracranial hemorrhage. This case is included in the main group also comprising 24 patients with available follow-up clinical and angiographic data.

Age of 25 patients in the study group ranged from 35 to 76 years (mean 54.8±11). There were 12 female and 13 male patients. At primary surgery, cerebral aneurysms were small (3—5 mm) in 6 patients, medium (6—14 mm) in 15 and large (15—24 mm) in 4 patients.

Nine patients (36%) presented with subarachnoid hemorrhage. Of these, 5 ones underwent surgery in acute phase (4—14 days), 4 patients — in non-acute phase (more than 14 days). Sixteen patients did not present with hemorrhage.

Follow-up CT angiography was performed in 10.84±4.71 months after surgery.

We compared qualitative indicators using the Fisher's exact test (two-sided) due to small sample size.

Follow-up period was variable. Thus, we assessed the rate of events using patient-years to analyze the probability of disease progression. Statistical analysis of growth predictors was performed using the Fisher's exact test and the Mann—Whitney U-test.

Results

Throughout one-year follow-up period, neurological status was stable in 24 out of 25 patients. One patient (4%) experienced fatal intracranial hemorrhage. We assume enlargement and subsequent rupture of residual aneurysm in this case.

Follow-up CT angiography revealed enlargement of residual neck of the clipped aneurysm in 2 (8%) patients. Both patients underwent elective redo surgery (residual neck clipping) **(Fig. 1, 2)**.

The total follow-up was 271 months (equivalent to 22.6 patient-years). The estimated progression rate was 0.133 cases of aneurysm enlargement per a patient-year. Thus, mean annual risk of residual aneurysm enlargement in this cohort was 13.3%.

Certain preoperative and intraoperative data are presented **(Table)**.

For statistical analysis, patients were divided into two groups: no residual aneurysm enlargement (22 (88%) patients) and progressive enlargement of remnant (3 (12%) patients). In one patient, enlargement was not angiographically confirmed. However, fatal hemorrhage was attributed to probable aneurysm rupture.

All three patients in the second group had residual AComA aneurysm and intraoperative rupture of aneurysm at primary surgery.

Between-group differences in IOR (4 (18%) out of 22 and 3 (100%) out of 3) were significant (Fisher's exact test, p=0.015). Importantly, unstable estimation of effect size with wide 95% confidence interval is due to extremely small sample size in the second group.

Regarding the fact that all enlarging remnants involved AComA, we found no significant differences when comparing them to AComA residual aneurysms without enlargement (p=0.230).

Enlargement of residual aneurysm after R2 clipping was observed in only 1 (5.9%) out of 17 cases. Enlargement after R3 clipping was observed in 2 (33.3%) out of 6 patients. No significant between-group differences were likely due to small sample size.

Discussion

After microsurgical clipping of cerebral aneurysms, residual aneurysm filling can occur in 8—12% of cases [5, 6].

To date, there are few studies regarding the management of patients with residual aneurysms or recommendations for follow-up imaging, even though the necessity

***Table*. Comparison of baseline characteristics of cerebral aneurysms.**

Follow-up data	*n*	Baseline size, *n* (%)			SAH, *n* (%)	Localization, *n* (%)			IOR, *n* (%)	Occlusion grade at discharge, *n* (%)	
		2—5 mm	6—14 mm	15—24 mm		ICA	AComA	MCA		R2	R3
No enlargement	22	5 (23)	13 (59)	4 (18)	8 (36)	4 (18.2)	11 (50)	7 (31.8)	4 (18)	16 (73)	6 (27)
Rupture	1		1 (100)		0 (0)		1 (100)		1 (100)		1 (100)
Remnant enlargement	2	1 (50)	1 (50)		1 (50)		2 (100)		2 (100)	1 (50)	1 (50)
Total	25	6	15	4	9	4	15	7	7	17	8

Note: SAH — subarachnoid hemorrhage; ICA — internal carotid artery; AComA — anterior communicating artery; MCA — middle cerebral artery; IOR — intraoperative rupture.

of such monitoring is evident due to the risk of disease progression. According to some data, the annual probability of residual aneurysm enlargement or rupture is 1.9% [2]. It is generally considered that enlarging residual aneurysms always require retreatment to prevent rupture [2].

Morphology of residual aneurysm significantly influences the likelihood of progression. In a retrospective study by Obermueller K. et al. [6], "dog-ear" type remnants were relatively stable. In our study, 1 (5.9%) patient with R2 grade (equivalent of "dog-ear" remnant) had enlargement of residual aneurysm after 13 postoperative months.

In 2022, Han H.J. et al. [7] demonstrated that residual neck was an independent predictor of recurrence and delayed hemorrhage. In 2025, Mori K. et al. [8] analyzed the outcomes of surgical clipping using long-term follow-up angiography (7.1 ± 4.6 years after surgery). They found the annual risk of residual aneurysm growth and rupture to be approximately 1.6%. Consequently, some authors recommend delayed angiography for patients with residual aneurysms.

When assessing predictors of residual aneurysm instability, some authors emphasize the role of baseline aneurysm size. Large aneurysm (11—25 mm) increase the risk of incomplete clipping [6]. Thorsteinsdottir J. et al. [2] reported long-term outcomes of aneurysm clipping. Among 25 aneurysms with residual neck, no en-

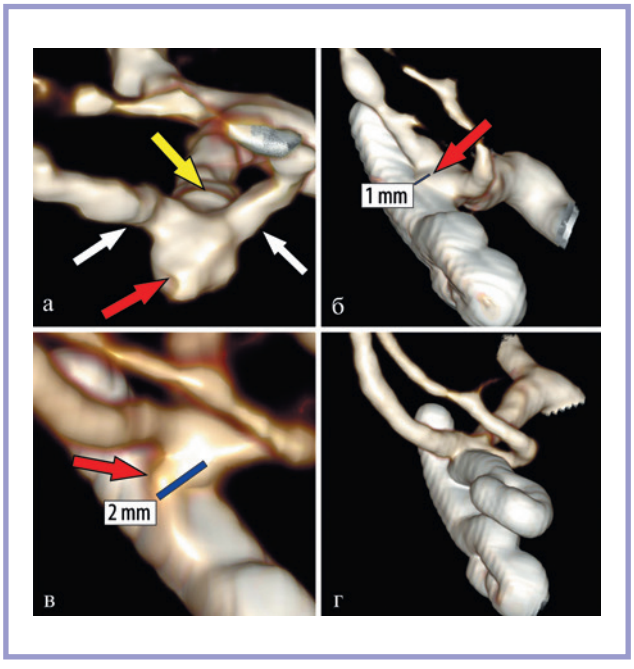

***Fig. 1.* CT angiography. Residual aneurysm enlargement (grade R2 clipping).**
a — preoperative CTA: anterior communicating artery aneurysm (3 mm) — red arrow; left A1 segment of anterior cerebral artery — yellow arrow; A2 segments of anterior cerebral arteries — white arrows; b — CTA after 5 postoperative days (surgery complicated by intraoperative aneurysm rupture): residual neck of approximately 1 mm (arrow); c — CTA in 13 months after surgery: residual aneurysm neck enlargement to 2 mm (arrow); d — CTA after redo surgery: total occlusion of aneurysm.

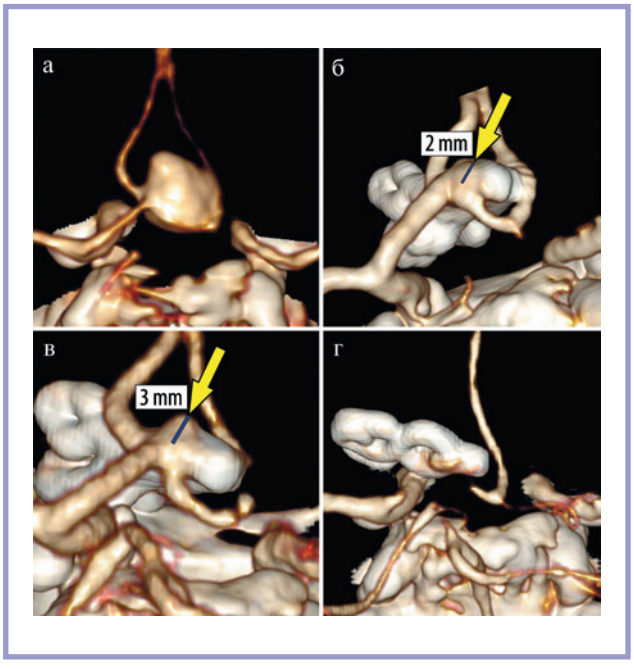

***Fig. 2.* CT angiography. Residual aneurysm enlargement (clipping grade R3).**
a — preoperative CTA: 13-mm anterior communicating artery aneurysm; b — CTA on postoperative day 2 following a procedure complicated by intraoperative rupture: residual neck of approximately 2 mm (arrow); c — CTA in 6 months after surgery: residual aneurysm neck enlargement to 3 mm (arrow); d — CTA following occlusion of aneurysm along with A2 segment of the left anterior cerebral artery complicated by intraoperative aneurysm rupture and severe hemorrhage.

largement was observed in any case. The authors suggest that remnants of small aneurysms are almost unlikely to grow. In our study, 1 (17%) out of 6 initially small aneurysms demonstrated enlargement throughout one-year follow-up period.

Along with size, aneurysm location is a significant hemodynamic factor. There are data on higher likelihood of complete occlusion for middle cerebral artery aneurysms [6]. In a large study by Jabbarli R. et al. [9], 7 out of 112 partially clipped aneurysms showed residual neck enlargement, and there were 2 cases of hemorrhage from previously clipped aneurysm. The follow-up period ranged from 1 day to 67 months. Aneurysm location in anterior communicating artery was significant. This location was identified as a predictor of residual aneurysm enlargement ($p < 0.003$). In our study, all aneurysms with subsequent enlargement involved ACoA.

Literature data confirm that intraoperative aneurysm rupture is a factor contributing to incomplete clipping [10]. Hemorrhage impairs visualization of surgical field, complicates total aneurysm occlusion and increases the risk of residual neck. However, there are currently no studies confirming that IOR is a prognostic factor for subsequent growth or rupture of residual aneurysm.

In this study, all three patients with residual aneurysm enlargement throughout a year experienced intraoperative rupture at baseline surgery. This finding may be a marker of baseline vascular wall fragility. It is known that chronic inflammatory reaction is present in aneurysm wall. This reaction is associated with tissue degeneration and predisposes to bleeding [11]. Emergency surgical interventions necessitated by intraoperative rupture cause additional trauma, exacerbate local endothelial damage [12] and trigger local wall inflammation. Altered blood flow dynamics (shear stress) impinging upon the weakened neck initiate pathological remodeling and further enlargement of residual aneurysm [13].

Considering own findings and literature data, we propose the following algorithm for monitoring of angiographically confirmed residual aneurysm (risk-based stratification of patients with incompletely occluded cerebral aneurysms followed by angiography for the high-risk group). The high-risk group should include patients with intraoperative aneurysm rupture, residual aneurysm of anterior communicating artery and R3 grade of occlusion (incomplete occlusion). Early follow-up angiography (3—6 months after discharge) is indicated for these patients due to the risk of rapid hemodynamic remodeling of the traumatized wall. For all other patients, mandatory follow-up assessment is scheduled after 12 months.

Conclusion

Intraoperative rupture significantly increases the risk of subsequent enlargement or rupture of residual aneurysm. Consequently, patients with intraoperative aneurysm rupture require early postoperative angiography (3—6 months after surgery). Redo surgery is indicated for signs of residual aneurysm enlargement. AComA involvement and clipping grade ⩾R3 are potential risk factors for enlargement and rupture of residual cerebral aneurysm. These factors require further study in larger cohorts.

Author contribution:
Concept and design of the study — Pilipenko Yu.V., Kholmatov M.B.
Collection and analysis of data — Kholmatov M.B., Pilipenko Yu.V., Starostenko D.A.
Writing the text — Starostenko D.A., Pilipenko Yu.V.
Editing — Eliava Sh.Sh., Okishev D.N., Konovalov An.N., Grebenev F.V.

No conflict of interests to declare.

REFERENCES

1. Turpo-Pequeña AG, Santos-Vargas SA, Loza-Chipa HR, Lamas FM, Espinoza-Laura GA, Núñez-Basurco CS, Medina-Neira DN, Benites-Bustamante VA, Osorio-Pacheco RR, Turpo-Peqqueña JR, Huanca-Quispe G, Vizcarra-Vizcarra CA, Gómez B, Rivillas JA, Hernández-Mayori R. Efficacy of intraoperative indocyanine green videoangiography (ICG-VA) and FLOW 800 in the surgical management of intracranial aneurysms: a systematic review and meta-analysis. *Acta Neurochirurgica.* 2026;168(1):24. https://doi.org/10.1007/s00701-026-06779-6
2. Thorsteinsdottir J, Schwarting J, Forbrig R, Siller S, Tonn JC, Liebig T, Schichor C. Detection of remnants in clipped unruptured intracranial aneurysms by intraoperative CT-angiography and postoperative DSA: clinical relevance and follow-up. *Acta Neurochirurgica.* 2025;167(1):109. https://doi.org/10.1007/s00701-025-06518-3
3. Wach J, Vychopen M, Güresir A, Guranda A, Nestler U, Güresir E. A Long-Term Comparative Analysis of Endovascular Coiling and Clipping for Ruptured Cerebral Aneurysms: An Individual Patient-Level Meta-Analysis Assessing Rerupture Rates. *Journal of Clinical Medicine.* 2024;13(6):1778. https://doi.org/10.3390/jcm13061778
4. Li G. Recurrence rate of intracranial aneurysms: a systematic review and a meta-analysis comparing craniotomy and endovascular coiling. *Neurosurgical Review.* 2025;48(1):80. https://doi.org/10.1007/s10143-025-03183-z
5. Pilipenko YuV, Eliava ShSh, Pronin IN, Okishev DN, Abramyan AA. Completeness of brain aneurysm exclusion according to CT angiography. *Burdenko's Journal of Neurosurgery.* 2020;84(6):76-85. (In Russ.). https://doi.org/10.17116/neiro20208406176
6. Obermueller K, Hostettler I, Wagner A, Boeckh-Behrens T, Zimmer C, Gempt J, Meyer B, Wostrack M. Frequency and risk factors for postoperative aneurysm residual after microsurgical clipping. *Acta Neurochirurgica.* 2021;163(1):131-138. https://doi.org/10.1007/s00701-020-04639-5
7. Han HJ, Lee W, Kim J, Park KY, Park SK, Chung J, Kim YB. Incidence rate and predictors of recurrent aneurysms after clipping: long-term follow-up study of survivors of subarachnoid hemorrhage. *Neurosurgical Review.* 2022;45(5):3209-3217. https://doi.org/10.1007/s10143-022-01828-x

8. Mori K, Numazawa S, Watanabe S, Nakao Y, Yamamoto T, Takeuchi S, Toyooka T, Wada K. Clipping of Unruptured Intracranial Aneurysm via Various Keyhole Mini-craniotomy Procedures: Substantial Curability and Psychological Comfort in 350 Cases over 20 Years. *Neurologia Medico-Chirurgica.* 2025;65(12):590-598. https://doi.org/10.2176/jns-nmc.2025-0161

9. Jabbarli R, Pierscianek D, Wrede K, Dammann P, Schlamann M, Forsting M, Müller O, Sure U. Aneurysm remnant after clipping: the risks and consequences. *Journal of Neurosurgery.* 2016;125(5):1249-1255. https://doi.org/10.3171/2015.10.jns151536

10. Brekke-Kumley B, Yeganeh K, Fox M, Cler K, Lawton MT, Tayebi Meybodi A. Outcomes following intraoperative rupture of cerebral aneurysms during microsurgical clipping: a systematic review and meta-analysis. *Neurosurgical Review.* 2026;49(1):290. https://doi.org/10.1007/s10143-026-04221-0

11. Abramyan AA, Pilipenko YuV, Belousova OB, Shmelev ND, Eliava ShSh. Microsurgical and endovascular treatment of residual and recurrent cerebral aneurysms. *Burdenko's Journal of Neurosurgery.* 2023;87(4):107-115. (In Russ.). https://doi.org/10.17116/neiro202387041107

12. Itani M, Aoki T. Mechanisms of Intracranial Aneurysm Rupture: An Integrative Review of Experimental and Clinical Evidence. *Journal of Clinical Medicine.* 2025;14(22):8256. https://doi.org/10.3390/jcm14228256

13. Ogilvy CS, Tatit RT, Loly VTR, Ramirez-Velandia F, Lima JSB, Baccin CE. Exploring the hemodynamic behavior of residual aneurysms after coiling and clipping: A computational flow dynamic analysis. *Surgical Neurology International.* 2024;15:376. https://doi.org/10.25259/SNI_686_2024

Received 30.03.2026
Reviced 27.04.2026
Accepted 20.07.2026

Comment

This study is of great practical importance for neurosurgeons specializing in microsurgical treatment of cerebral aneurysms. The authors analyzed a large patient cohort, demonstrated the rate of subtotal / partial aneurysm clipping and identified specific location associated with recurrent rupture after previous inadequate clipping. They also identified intraoperative aneurysm rupture as a primary factor leading to partial clipping. This study is characterized by good design, appropriate analysis, significant results and reasonable conclusions. The authors proposed an algorithm for postoperative imaging after partial aneurysm clipping.

Dubovoy A.V. (Novosibirsk)