Burdenko's Journal of Neurosurgery
2026, No. 5, pp. 16–24
https://doi.org/10.17116/neiro20269005116

Single-portal endoscopic decompression for degenerative lumbosacral spinal stenosis: a prospective single-center study

© L.R. Gabrielyan, N.A. Konovalov, R.A. Onoprienko, E.S. Brinyuk, S.V. Kaprovoy, B.A. Zakirov

Burdenko Neurosurgery Center, Moscow, Russia

ABSTRACT

Background. Degenerative lumbosacral spinal stenosis is one of the leading causes of chronic pain and disability in elderly patients. Single-portal endoscopic interlaminar bilateral decompression is a promising minimally invasive method. However, prospective data are limited.

Material and methods. A single-center prospective study included 50 patients with central single-level lumbosacral degenerative stenosis who underwent single-portal endoscopic interlaminar bilateral decompression through a unilateral approach. VAS, ODI, MacNab and GAS scores were assessed. We also analyzed surgery time and 6-month morbidity.

Results. By the 6th month, VAS scores of low back and leg pain decreased by 5.6 and 6.7 points. ODI score decreased by 48.2 points ($p<0.001$). Satisfactory outcomes according to MacNab scale comprised 80%, GAS ≥0 — 82%. Dural damage and explorations were observed in 4% of cases, and there were no infectious complications. Mean surgery time decreased from 230 to 127 min along with accumulation of experience ($p<0.001$).

Conclusion. Single-portal endoscopic interlaminar bilateral decompression from a unilateral approach is an effective option for degenerative lumbosacral stenosis. Multiple-center studies with long-term follow-up are needed to evaluate long-term outcomes and compare this surgery with other minimally invasive techniques.

Keywords: *degenerative spinal stenosis, endoscopic decompression, single-portal endoscopic decompression, surgical treatment of degenerative stenosis, minimally invasive surgery, endoscopic surgery.*

INFORMATION ABOUT THE AUTHORS:
Gabrielyan L.R. — https://orcid.org/0009-0003-6787-9136
Konovalov N.A. — https://orcid.org/0000-0002-9976-948X
Onoprienko R.A. — https://orcid.org/0000-0002-8637-9079
Brinyuk E.S. — https://orcid.org/0000-0001-6184-7481
Kaprovoy S.V. — https://orcid.org/0000-0001-8813-2793
Zakirov B.A. — https://orcid.org/0000-0002-8782-850X
Corresponding author: Gabrielyan L.R. — e-mail: gabrielyanLR@nsi.ru

TO CITE THIS ARTICLE:
Gabrielyan LR, Konovalov NA, Onoprienko RA, Brinyuk ES, Kaprovoy SV, Zakirov BA. Single-portal endoscopic decompression for degenerative lumbosacral spinal stenosis: a prospective single-center study. *Burdenko's Journal of Neurosurgery*. 2026;90(5):16–24. (In Russ.). https://doi.org/10.17116/neiro20269005116

Introduction

Degenerative lumbosacral spinal stenosis is one of the most common causes of chronic pain in the lower back and lower extremities in elderly patients. This disease leads to persistent limitation of daily activity, loss of ability to work and impaired quality of life [1—4]. Optimal surgical strategy for degenerative stenosis is important considering increased life expectancy and high prevalence of degenerative-dystrophic changes in intervertebral discs, ligamentum flavum and facet joints.

Classical open laminectomy provides effective decompression of dural sac and nerve roots, but it is associated with extensive resection of bones and ligaments, damage to paravertebral muscles, high risk of iatrogenic instability and prolonged hospital-stay and rehabilitation [3, 5, 6]. Microsurgical and tubular techniques reduced surgical invasiveness and soft tissue dissection while maintaining the effectiveness of decompression. These methods created a new "gold standard" for surgical treatment of this pathology — microsurgical decompression. However, this did not solve the problem of intraoperative trauma to paravertebral tissues and retraction of muscles and ligaments [3, 7—10].

Single-port endoscopic techniques became the next stage in evolution of minimally invasive spine surgery. Ruetten S. et al. [11] developed interlaminar single-port endoscopic decompression and first described this approach for herniated intervertebral discs in the mid-2000s. Further modifications of this method described by Komp

M. et al. [12] made it possible to extend it to bilateral decompression of central degenerative spinal canal stenosis via unilateral interlaminar approach. Available samples and comparative studies demonstrate that single-port endoscopic decompression for degenerative lumbar stenosis is accompanied by reduced VAS scores of pain, improved functional status (ODI score), favorable clinical outcomes (Macnab criteria), reduced length of hospital-stay and acceptable safety [2, 10, 13—15]. However, there are few available data on this issue.

The purpose of this prospective single-center study was to evaluate clinical effectiveness and safety of single-port endoscopic interlaminar decompression for degenerative lumbosacral spinal stenosis.

Material and methods

Study design

A single-center prospective observational study included patients with degenerative lumbosacral spinal stenosis who underwent single-port endoscopic bilateral decompression through a unilateral approach. The same surgeon performed all interventions in our hospital (Burdenko Neurosurgery Center). We enrolled 50 patients and analyzed anthropometric and demographic indicators (age, gender, body mass index). All patients underwent preoperative clinical, neurological and instrumental examination: VAS scores of pain in the lower back and lower extremities, ODI score and level of stenosis. Postoperative follow-up period was 6 months with examinations after 1 postoperative day, 3 and 6 months.

Inclusion and exclusion criteria

Inclusion criteria: 1) age > 18 years; 2) severe syndrome of neurogenic intermittent claudication, as well as radiculopathy syndrome; 3) degenerative lumbosacral spinal stenosis confirmed by MRI with compression of dural sac and nerve roots due to hypertrophy of ligamentum flavum and facet joints without severe discogenic compression as a dominant cause of stenosis; 4) ineffective drug therapy for at least 3 months before surgery; 5) no previous surgery for severe central stenosis (with radiculopathy and/or clinical signs of intermittent neurogenic claudication) at the same level; 6) available follow-up data at three time points (1 day, 3 and 6 months after surgery).

Exclusion criteria: 1) verified segmental instability (functional spondylography data); 2) severe spinal deformities requiring correction; 3) intervertebral disc herniation as a primary cause of compression; 4) prior interventions at the target segment; 5) concurrent neoplastic, traumatic, or infectious spinal lesions; 6) severe comorbidities with extremely high anesthetic and surgical risk; 7) involvement of two or more segments.

Surgical technique

All procedures were performed in prone position under general anesthesia. We used interlaminar approach and single-port endoscopic system for bilateral decompression via unilateral approach at the target level. Following intraoperative radiographic verification, a 1—1.2 cm longitudinal skin incision was made over appropriate interlaminar space. Next, we placed retractors of increasing diameter and a port **(Fig. 1)**. The endoscope was inserted through this port under continuous saline irrigation. After identification of bony landmarks within the access zone, we used a high-speed burr for partial resection of the caudal edge of the arch of superior vertebra up to attachment of ligamentum flavum. Selective resection of medial aspect of the facet joint was also performed. Once the hypertrophied ligamentum flavum was visualized, we resected this ligament using Kerrison rongeurs for decompression of dural sac and nerve root on the side of approach. Since all patients presented with central stenosis, subsequent stage involved contralateral decompression via partial resection of the base of the spinous process and contralateral arch, as well as excision of hypertrophied ligamentum flavum on the opposite side. This resulted in spinal canal remodeling and bilateral decompression of dural sac and nerve roots **(Fig. 2)**. We assessed decompression considering visual release of dural sac and nerve roots, as well as recovery of their pulsation and mobility upon manipulations. Intraoperative computed tomography was as an additional method for evaluating the adequacy of decompression. Final hemostasis was achieved using bipolar cauterization.

Clinical assessment was performed preoperatively, on the first postoperative day, after 3 and 6 months. Primary outcome measures included VAS scores of lower back and lower limb pain (0—10), ODI score, subjective outcome assessment after 6 months (the modified Macnab criteria) and GAS score after 6 months. Additionally, perioperative parameters were evaluated: surgery time (min), length of hospital-stay (days), intraoperative dural tear, infectious complications and redo surgery. Dynamics of surgery time was also analyzed regarding learning curve.

Statistical analysis

Statistical analysis was performed using IBM SPSS Statistics v.26.0. Quantitative data were tested for normality using the Shapiro—Wilk test. VAS scores had non-parametric distribution, and we analyzed pre- and post-operative variables using the Wilcoxon signed-rank test. Quantitative variables were described as median and interquartile range (Me [IQR]). Means and standard deviations (M±SD) were also provided for clinical interpretation. The Mann—Whitney test was used for between-group comparison of surgery time, Spearman's correlation — for assessing the relationship between surgery time and sequential number of the procedure.

The Macnab and GAS outcomes were described using absolute and relative frequencies (*n*, %). Favorable outcomes included "excellent" or "good" ones (Macnab scale) and GAS score ⩾0. Differences were significant at $p<0.05$.

Results

The study included 50 patients with degenerative lumbosacral stenosis who underwent single-port endoscopic interlaminar bilateral decompression via unilateral approach. Mean age was 61.3±11.2 years (range 42—82). There were 27 (54.0%) women and 23 (46.0%) men. Mean body mass index was 31.7±6.6 kg/m². L4—L5 decompression was the most common (31 (62.0%) patients). L3—L4, L5—S1 and L2—L3 decompression was performed in 9 (18.0%), 6 (12.0%) and 4 (8.0%) patients, respectively. Mean surgery time (including learning curve) was 178.6 ± 61.1 min (158 [128—225]). In majority of cases, patients were discharged on the second postoperative day.

Pain and functional status

Preoperative VAS score of pain was 6.0 [6.0—7.0] for lumbar region and 7.5 [7.0—8.0] for lower extremities. On the first postoperative day, these values decreased (1.0 [1.0—2.0] and 0.0 [0.0—1.0] scores, respectively). By the 3rd month, these values were 1.0 [0.0—1.0] and 0.0 [0.0—1.0] scores, respectively. They were stable after 6-month follow-up (1.0 [0.0—1.0] and 0.0 [0.0—1.0] scores, respectively).

By the 6th month, VAS score of lower back pain decreased by 5.6 ± 1.3 points (95% CI −6.0; −5.3; $p<0.001$), lower limb pain — by 6.7±1.4 points (95% CI −7.1; −6.3; $p < 0.001$; Wilcoxon test).

Preoperative ODI score was 64.0 [56.5—75.0], after 6 months — 16.0 [12.0—20.5] points. Thus, mean reduction was 48.2±14.3 points (95% CI −52.2; −44.2; $p<0.001$, Wilcoxon test).

Safety

Intraoperative dural tear occurred in 2 (4%) patients. Small size of defect required no dura mater repair. This is consistent with management for such complications in endoscopic procedures [16, 17]. There was no wound CSF leakage, pseudomeningocele or postoperative neurological deficits in these patients. Redo surgery was required for 2 (4%) patients due to inadequate neural decompression. No infectious complications were noted.

Clinical and functional outcomes

According to the Macnab scale, we observed excellent results in 26 (52.0%) patients, good outcomes in 14 (28.0%), satisfactory in 8 (16.0%) and poor in 2 (4.0%) patients after 6 months. Favorable outcomes (excellent + good) comprised 80.0%.

The median GAS score after 6 months was 1 [0—2] point. Distribution was as follows: -2 points — 2 (4.0%) patients; -1 point — 7 (14.0%) patients; 0 points — 14 (28.0%) patients; +1 point — 14 (28.0%) patients; +2 points — 13 (26.0%)

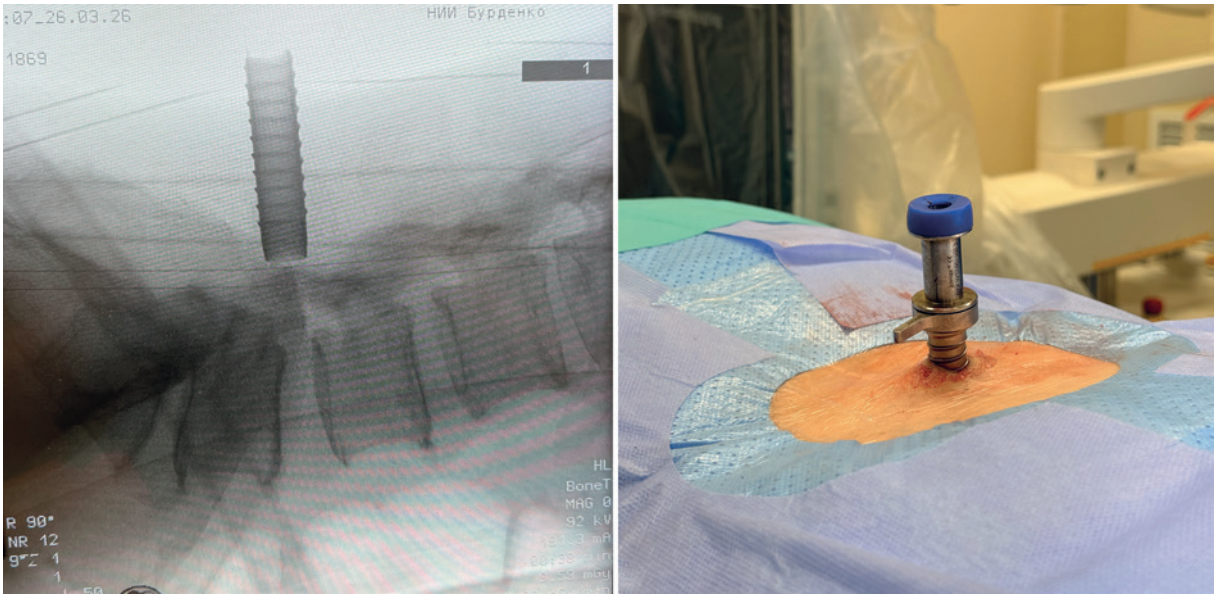

Fig. 1. **Single-port positioning for endoscopic L4—L5 decompression.**

patients. Achieving or exceeding individually significant treatment goals (GAS ⩾0) was observed in 41 (82.0%) patients.

Learning curve

Chronological analysis of surgery time revealed a trend towards shorter intervention as surgical experience accumulated. Mean surgery time for the first 25 procedures was 230.1±40.7 min, for subsequent 25 cases — 127.1±21.2 min (p<0.001). Finally, surgery became shorter by 44.8% when comparing the first and the last procedure.

Sequential analysis of groups comprising 12—13 surgeries revealed a gradual reduction in surgery time: 245.2±37.9 min (cases 1—12), 216.2±39.5 min (cases 13—25), 143.7±11.4 min (cases 26—37) and 111.8 ± 15.7 min (cases 38—50). Correlation analysis confirmed a strong inverse relationship between surgery number and its duration (Spearman's rank correlation coefficient r=−0.893; p<0.001).

Discussion

Our results demonstrate a significant clinical effect of single-port endoscopic interlaminar bilateral decompression via unilateral approach for degenerative lumbosacral spinal stenosis. Mean VAS score of lumbar pain decreased by 5.6 points, radicular pain in lower limbs — by 6.7 points. The ODI score decreased by 48.2 points. These values are consistent with meta-analysis by Lee C.-H. et al. [18]. The authors reported mean reductions of 5.95 points for lower limb pain, 4.22 points for lumbar pain and 41.71 points for ODI after single-port endoscopic interlaminar decompression. Similarly, other meta-analyses and systematic reviews demonstrated efficacy of this method [19—21].

The cumulative rate of favorable outcomes in our series was 80.0%. This is comparable to data from previous studies by X. Qu et al. (87.5%, n=40) and K. Y. Goh et al. (89.09%, n=275) [22, 23]. Somewhat lower rate in our series may be attributed to more severe baseline functional impairment and inclusion of learning period.

The GAS scale complements objective assessment by subjective significance of the outcome for a particular patient. Achieving or exceeding individually significant goals (GAS ⩾0) was recorded in 82.0% of patients. This indicates high satisfaction with outcomes in this cohort.

The incidence of intraoperative dural tear in our series was 4% (2 patients). This value slightly exceeds mean rate reported in systematic reviews devoted to endoscopic decompression. For instance, Kalanchiam G.P. et al. [24] reported 3.2% incidence of intraoperative dural tear. Dural repair was not performed in accordance with management protocol for small dural defects in endoscopic procedures. Surgery proceeded until adequate decompression with subsequent skin closure [16, 17]. There was no postoperative wound CSF leakage, pseudomeningocele, or neurological deficits. Redo surgery rate was 4% (2 patients), and these interventions were necessitated by inadequate decompression. These data are comparable to overall redo surgery rate (3.5%) in the literature [25].

Chronological analysis revealed surgery time reduction as experience was gained. Mean surgery time was 230.1±40.7 min for the first 25 patients and 127.1±21.2 min for subsequent 25 patients. Reduction amounted to 44.8% (p<0.001). A step-by-step analysis of groups comprising 12—13 consecutive procedures demonstrated progressive shortening of interventions: from 245.2±37.9 min in the first 12 cases to 111.8±15.7 min for the 38th—50th procedures. The Spearman rank correlation coefficient between surgery sequence number and its duration was −0.893 (p<0.001). This indicates a strong inverse relationship and learning curve typical of endoscopic interventions **(Fig. 4)**.

Our findings are consistent with literature data on single-port endoscopic decompression as a process requiring approximately 20—30 consecutive procedures before sur-

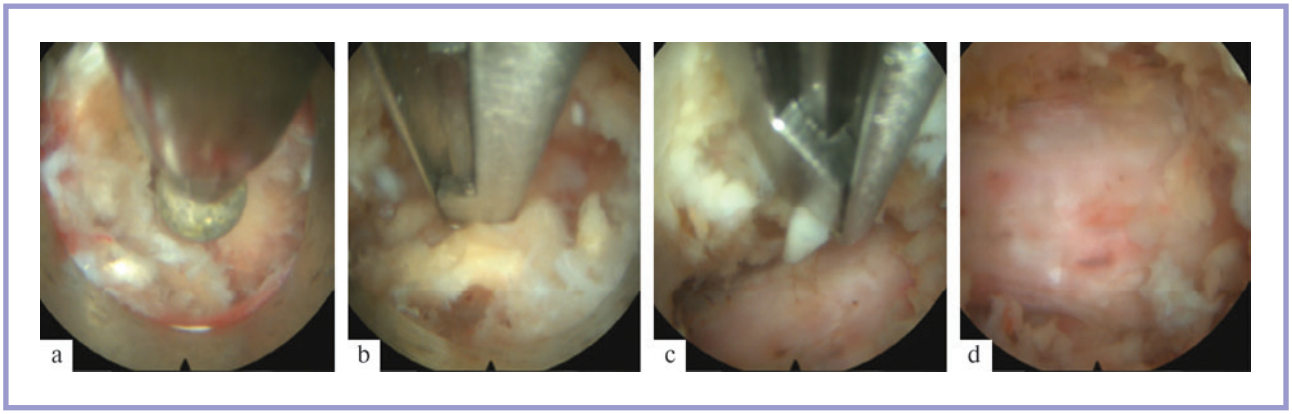

Fig. 2. **Stages of endoscopic decompression.**
a — bone resection at the level of stenosis; b — ipsilateral excision of ligamentum flavum; c — contralateral decompression; d — spinal canal after decompression.

gery time stabilizes and performance variability decreases [26, 27]. Importantly, while surgery time decreased significantly, clinical outcomes (the Macnab scale) and complication rates were comparable throughout the learning period. This demonstrates safety and reproducibility of technique even in learning phase.

Single-port endoscopic interlaminar decompression for degenerative lumbar stenosis enables target decompression of spinal canal and lateral recesses under visual guidance. Degenerative stenosis is accompanied by narrow interlaminar window, while hypertrophied ligamentum flavum and bones (laminae, facet joints) contribute to canal stenosis. In these cases, endoscopic technique allows for selective resection of pathological tissues while preserving structural integrity [22, 25]. Intraoperative CT may be an adjunct in learning phase or in case of severe degenerative changes or atypical local anatomy.

Continuous saline irrigation and high-resolution endoscopic optics facilitate clear visualization of surgical site while minimizing muscle trauma. In our sample, this is followed by significant clinical improvement, short-term hospital-stay (3.1±1.0 days including preoperative period) and low rates of complications and redo surgeries. These findings align with available data on single-port endoscopic interlaminar decompression for spinal stenosis.

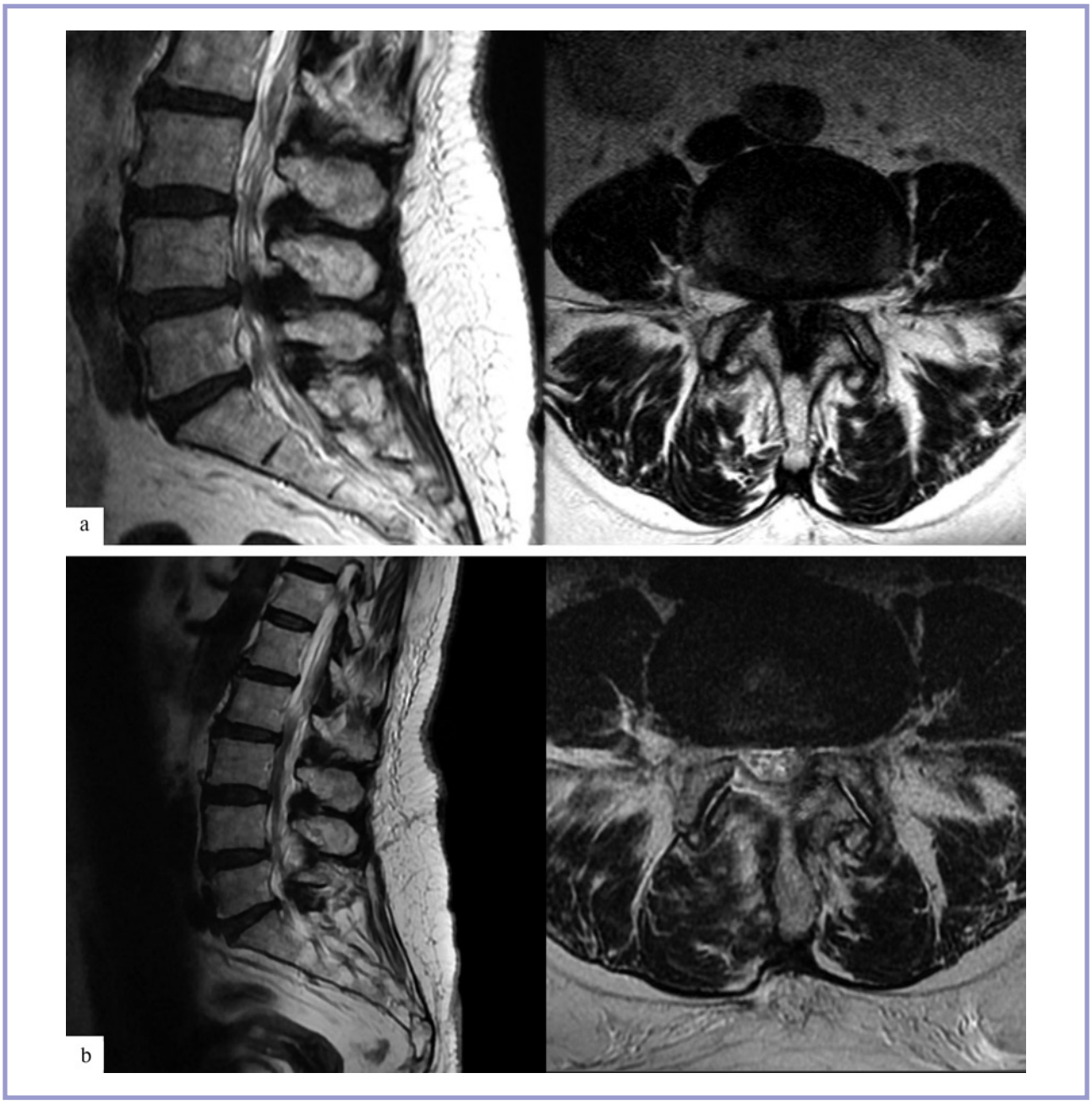

Fig. 3. **MRI of degenerative spinal stenosis L4—L5 before (a) and after (b) single-port endoscopic decompression.**

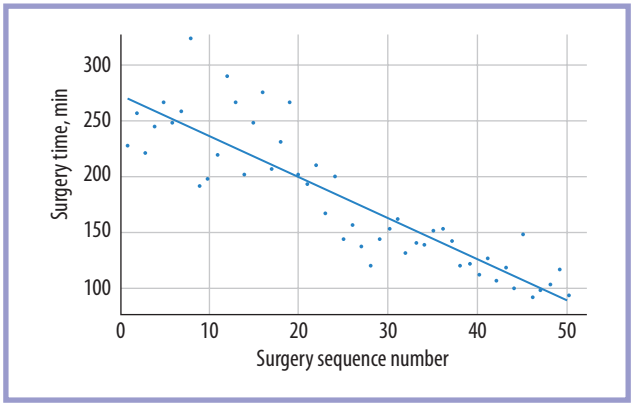

Fig. 4. **Learning curve.**

Study limitations

This study has several limitations that should be considered when interpreting the results. Single-center design and relatively small sample size (50 patients) complicate data extrapolation on a larger population. No control group precludes comparison of endoscopic technique with microsurgical or tubular decompression as common procedures for degenerative stenosis.

An additional limitation is inclusion of surgeries throughout the learning period. This influenced mean surgery time, but did not compromise clinical outcomes or complication rates. To further validate these results, we need for multiple-center prospective studies with longer follow-up (at least 1—2 years) and comparative studies evaluating single-port endoscopic interlaminar bilateral decompression (via unilateral approach) with microsurgical decompression and other minimally invasive techniques regarding efficacy, safety, cost and learning curve.

Conclusion

In patients with degenerative lumbosacral spinal stenosis, single-port endoscopic interlaminar bilateral decompression via unilateral approach demonstrated high clinical efficacy, pain relief and improvement of functional status (ODI score) after 6-month postoperative follow-up. The majority of patients achieved favorable outcomes according to the Macnab scale, as well as individually significant therapeutic goals according to the GAS scale. This confirms objective and subjective meaningful functional improvements. Safety of the procedure including intraoperative dural tears, redo surgeries and infectious complications was comparable to available data and acceptable for these minimally invasive interventions. Furthermore, learning curve analysis revealed a significant reduction in surgery time as experience was gained without compromising clinical outcomes. These findings justify this method as an effective, minimally invasive surgical option for degenerative lumbar stenosis. However, further multiple-center studies with longer follow-up periods are necessary to evaluate durability of results and efficacy compared to other decompression techniques.

Author contribution:
Concept and design of the study — Gabrielyan L.R., Konovalov N.A.
Collection and analysis of data — Gabrielyan L.R., Brinyuk E.S., Kaprovoy S.V., Zakirov B.A.
Writing the text — Gabrielyan L.R.
Statistical analysis — Gabrielyan L.R., Onoprienko R.A.
Editing — Konovalov N.A., Onoprienko R.A., Brinyuk E.S.

No conflict of interests to declare.

REFERENCES

1. Katz JN, Zimmerman ZE, Mass H, Makhni MC. Diagnosis and Management of Lumbar Spinal Stenosis: A Review. *Journal of the American Medical Association*. 2022;327(17):1688-1699. https://doi.org/10.1001/jama.2022.5921
2. Yusupova AR, Gushcha AO, Arestov SO, Petrosyan DV. Percutaneous endoscopic decompression of the central degenerative stenoses of the lumbosacral spine. *Russian Journal of Neurosurgery*. 2024;26(4):14-21. (In Russ.). https://doi.org/10.17650/1683-3295-2024-26-4-14-21
3. Konovalov NA, Nazarenko AG, Asuytin DS, Brinyuk ES, Kaprovoi SV, Zakirov BA. Degenerative lumbar spine stenosis: minimally invasive microsurgical methods of treatment. *Burdenko's Journal of Neurosurgery*. 2021; 85(4):87-95. (In Russ.). https://doi.org/10.17116/neiro20218504187
4. Grin AA, Nikitin AS, Yusupov SR. Surgical treatment of spinal canal stenosis at the lumbar level in the elderly and senile patients. *Russian journal of neurosurgery*. 2020;22(1):93-102. (In Russ.). https://doi.org/10.17650/1683-3295-2020-22-1-93-102
5. Hamdan TA, Abdul Hassan AS. Spinal instability following multilevel decompressive laminectomy without fusion for degenerative lumbar canal stenosis. *World Journal of Surgery and Surgical Research*. 2020;3:1193.
6. Nerland US, Jakola AS, Solheim O, Weber C, Rao V, Lønne G, Solberg TK, Salvesen Ø, Carlsen SM, Nygaard ØP, Gulati S. Minimally invasive decompression versus open laminectomy for central stenosis of the lumbar spine: pragmatic comparative effectiveness study. *British Medical Journal*. 2015;350:h1603. https://doi.org/10.1136/bmj.h1603
7. Soares RO, Astur N, Rabello de Oliveira L, Kanas M, Wajchenberg M, Martins DE. Qualitative Evaluation of Paraspinal Musculature After Minimally Invasive Lumbar Decompression: A Prospective Study. *International Journal of Spine Surgery*. 2024;18(4):448-454. https://doi.org/10.14444/8631
8. Liang Z, Xu X, Rao J, Chen Y, Wang R, Chen C. Clinical Evaluation of Paraspinal Mini-Tubular Lumbar Decompression and Minimally Invasive Transforaminal Lumbar Interbody Fusion for Lumbar Spondylolisthesis Grade I with Lumbar Spinal Stenosis: A Cohort Study. *Frontiers in Surgery*. 2022;9:906289. https://doi.org/10.3389/fsurg.2022.906289
9. Kartal A, Manalil NF, Hamad MK, Paracha S, Robayo A, Wang E, Hussain I, Härtl R. Minimally invasive tubular decompression versus traditional open surgery for lumbar spinal stenosis: a systematic review and meta-analysis. *Scientific Reports*. 2025;16(1):176. https://doi.org/10.1038/s41598-025-28949-9
10. Khalepa RV, Amelina EV, Kubetsky YuE. Endoscopic and microsurgical decompression for central lumbar spinal stenosis. *Russian Journal of Spine Surgery*. 2024;21(3):59-68. (In Russ.). https://doi.org/10.14531/ss2024.3.59-68

11. Ruetten S, Komp M, Godolias G. A New full-endoscopic technique for the interlaminar operation of lumbar disc herniations using 6-mm endoscopes: prospective 2-year results of 331 patients. *Minimally Invasive Neurosurgery.* 2006;49(2):80-87. https://doi.org/10.1055/s-2006-932172
12. Komp M, Hahn P, Merk H, Godolias G, Ruetten S. Bilateral operation of lumbar degenerative central spinal stenosis in full-endoscopic interlaminar technique with unilateral approach: prospective 2-year results of 74 patients. *Journal of Spinal Disorders and Techniques.* 2011;24(5):281-287. https://doi.org/10.1097/BSD.0b013e3181f9f55e
13. Lewandrowski KU, Yeung A. Lumbar Endoscopic Bony and Soft Tissue Decompression With the Hybridized Inside-Out Approach: A Review And Technical Note. *Neurospine.* 2020;17(Suppl 1):S34-S43. https://doi.org/10.14245/ns.2040160.080
14. Song Q, Zhu B, Zhao W, Liang C, Hai B, Liu X. Full-Endoscopic Lumbar Decompression versus Open Decompression and Fusion Surgery for the Lumbar Spinal Stenosis: A 3-Year Follow-Up Study. *Journal of Pain Research*. 2021;14:1331-1338. https://doi.org/10.2147/JPR.S309693
15. Ju CI, Kim P, Ha SW, Kim SW, Lee SM. Contraindications and Complications of Full Endoscopic Lumbar Decompression for Lumbar Spinal Stenosis: A Systematic Review. *World Neurosurgery.* 2022;168:398-410. https://doi.org/10.1016/j.wneu.2022.07.066
16. Trathitephun W, Asawasaksakul A, Jaruwanneechai K, Pakdeenit B, Suebsing A, Liu Y, Kim JS, Suvithayasiri S. Intraoperative Management of Iatrogenic Durotomy in Endoscopic Spine Surgery: A Systematic Review. *Neurospine.* 2024;21(3):756-766. https://doi.org/10.14245/ns.2448346.173
17. Kamenova M, Leu S, Mariani L, Schaeren S, Soleman J. Management of Incidental Dural Tear During Lumbar Spine Surgery. To Suture or Not to Suture? *World Neurosurgery.* 2016;87:455-462. https://doi.org/10.1016/j.wneu.2015.11.0455
18. Lee CH, Choi M, Ryu DS, Choi I, Kim CH, Kim HS, Sohn MJ. Efficacy and Safety of Full-endoscopic Decompression via Interlaminar Approach for Central or Lateral Recess Spinal Stenosis of the Lumbar Spine: A Meta-analysis. *Spine.* 2018;43(24):1756-1764. https://doi.org/10.1097/BRS.0000000000002708
19. Yu A, Kurapatti M, Hoang R, Hong J, Shrestha N, Stadler R, Campbell P, Song J, Lee J, Cho SK. Comparison of biportal versus uniportal endoscopic decompression for the treatment of lumbar degenerative disease: a systematic review and meta-analysis. *Asian Spine Journal.* 2026;20(3):558-571. https://doi.org/10.31616/asj.2025.0104
20. Perez-Roman RJ, Gaztanaga W, Lu VM, Wang MY. Endoscopic decompression for the treatment of lumbar spinal stenosis: an updated systematic review and meta-analysis. *Journal of Neurosurgery: Spine.* 2021;36(4):549-557. https://doi.org/10.3171/2021.8.SPINE21890
21. Chin BZ, Yong JH, Wang E, Sim SI, Lin S, Wu PH, Hey HWD. Full-endoscopic versus microscopic spinal decompression for lumbar spinal stenosis: a systematic review & meta-analysis. *The Spine Journal.* 2024;24(6):1022-1033. https://doi.org/10.1016/j.spinee.2023.12.009
22. Qu X, Zhang L, Xie Z, Zhang J, Huang Y, Li N, Luo X. Efficacy of endoscopic interlaminar decompression in lumbar spinal stenosis: a retrospective study. *Scientific Reports.* 2024;14(1):26956. https://doi.org/10.1038/s41598-024-77337-2
23. Goh KY, Hsu JC, Lee CY, Huang TJ, Chen CM, Wu MH. Uniportal Endoscopic Interlaminar Decompression in Lumbar Spinal Stenosis: A Comprehensive Review. *International Journal of Spine Surgery.* 2021;15(Suppl 3):S54-S64. https://doi.org/10.14444/8164
24. Kalanchiam GP, Kaliya-Perumal AK, Sampath L, Boey ETH, Oh JY. Complications in Uniportal vs Unilateral Biportal Endoscopic Decompression for Lumbar Spinal Stenosis: A Scoping Review. *Global Spine Journal.* 2026;16(1):724-733. https://doi.org/10.1177/21925682251346413
25. Gatam AR, Gatam L, Phedy, Mahadhipta H, Ajiantoro, Aprilya D. Full Endoscopic Lumbar Stenosis Decompression: A Future Gold Standard in Managing Degenerative Lumbar Canal Stenosis. *International Journal of Spine Surgery.* 2022;16(5):821-830. https://doi.org/10.14444/8338
26. Park SC, Park SM, Chung HJ, You YJ. Learning curve for full-endoscopic lumbar decompression via interlaminar approach using the learning curve cumulative summation analysis. *Journal of Orthopaedic Surgery and Research*. 2025;20(1):297. https://doi.org/10.1186/s13018-025-05699-y
27. Machado J, Martins P, Mendes Santos P, Vila Real R, Costa J, Rocha L, Neto A, Bastos N. Achieving Efficiency in Full Endoscopic Interlaminar Lumbar Decompression: A Prospective Learning-Curve Cumulative Summation Analysis and Its Impact on Patient-Reported Outcomes. *Cureus.* 2025;17(12):e98634. https://doi.org/10.7759/cureus.98634

Received 24.04.2026
Accepted 20.07.2026