Burdenko's Journal of Neurosurgery
2026, No. 5, pp. 5–15
https://doi.org/10.17116/neiro2026900515

Scoring system for unstable gunshot wounds to the thoracolumbar spine

© V.A. Manukovsky[1—3], A.O. Kelin[1, 2], M.N. Kravtsov[4—6], G.I. Antonov[1, 2], V.I. Badalov[4], I.V. Basankin[7], Z.Sh. Aliev[8]

[1]National Medical Research Center for High Medical Technologies - Vishnevsky Central Military Clinical Hospital, Krasnogorsk, Russia;
[2]Peoples' Friendship University of Russia, Moscow, Russia;
[3]Department of Emergency Surgery at the branch of the Kirov Military Medical Academy, Moscow, Russia;
[4]Kirov Military Medical Academy, St. Petersburg, Russia;
[5]Dzhanelidze Research Institute for Emergency Care, St. Petersburg, Russia;
[6]Mechnikov North-Western State Medical University, St. Petersburg, Russia;
[7]Research Institute — Ochapovsky Regional Clinical Hospital No. 1, Krasnodar, Russia;
[8]Burdenko Main Military Clinical Hospital, Moscow, Russia

ABSTRACT

Background. According to the authors, up to 9.8% of gunshot wounds to the spine are unstable. The lack of tactical classification complicates decision-making regarding the need for fusion surgery. Thus, a scoring protocol was developed for assessing unstable gunshot wounds to the thoracolumbar spine.

Material and methods. The second phase of the study involved survey of 19 expert surgeons. Participants completed the questionnaires twice with a 2-month interval. The Kappa coefficient was used to determine inter- and intra-expert agreement regarding applicability of classifications, presence of injury and contribution of injury of specific anatomical structure to destabilization. The third stage involves statistical analysis and development of a scoring tactical classification.

Results. Traditional assessment systems for closed spinal injuries have extremely low reproducibility when applied to gunshot wounds. Experts demonstrated the greatest consensus when assessing bilateral fractures of the facet joints (κ=0.553—0.614) or roots of arches (κ=0.683—0.713) and vertebral body destruction involving both endplates (κ=0.556—0.570 — moderate agreement). A scoring tactical surgical classification of unstable gunshot wounds to the thoracolumbar spine was developed.

Conclusion. AUC (0.866 for unstable and 0.888 for stable cases) allows the developed classification to be characterized as an "excellent classifier". Considering 87.9% sensitivity and 72.3% specificity (for unstable cases), we can recommend this method for neurosurgeons and traumatologists to optimize treatment strategies for the wounded.

Keywords: *combat spinal trauma, spinal injuries, thoracolumbar spine injuries, gunshot wounds to the spine, classification of spinal fractures, classification of gunshot wounds to the spine, unstable spinal fractures.*

INFORMATION ABOUT THE AUTHORS:
Manukovsky V.A. — https://orcid.org/0009-0000-7727-9589
Kelin A.O. — https://orcid.org/0009-0000-0848-2524
Kravtsov M.N. — https://orcid.org/0000-0003-2486-6995
Antonov G.I. — https://orcid.org/0000-0001-6201-9207
Badalov V.I. — https://orcid.org/0000-0002-8461-2252
Basankin I.V. — https://orcid.org/0000-0003-3549-0794
Aliev Z.Sh. — https://orcid.org/0000-0002-3531-9703
Corresponding author: Kelin A.O. — e-mail: alexandrkelin@yandex.ru

TO CITE THIS ARTICLE:
Manukovsky VA, Kelin AO, Kravtsov MN, Antonov GI, Badalov VI, Basankin IV, Aliev ZSh. Scoring system for unstable gunshot and blast-fragmentation wounds to the thoracolumbar spine. *Burdenko's Journal of Neurosurgery*. 2026;90(5):5–15. (In Russ.). https://doi.org/10.17116/neiro2026900515

Abbreviations

FSU — functional spinal unit

Introduction

The incidence of gunshot spinal injuries has increased by approximately 10.3% annually over the last two decades. They are currently third common spinal and spinal cord injuries [1, 2]. Surgical treatment is required for 6.3—41% of such injuries [3—5]. Gunshot fractures of the thoracic and lumbar spine are usually biomechanically stable. This is due to the mechanism of damage to vertebral bones and ligaments differing from blunt trauma [6—9]. Nevertheless, up to 9.8% of patients present with unstable fractures [4, 10].

No tactical classification and clear concept of mechanical stability regarding gunshot wounds complicates deci-

sion-making on the need for fixation [8, 11]. Previous classifications, such as those by Kosinskaya N.S. and GATA-SMI, describe radiographic trajectory of wounding projectile and allow for suspicion of dural injury [12, 13]. However, their limitation is no recommendations regarding the need for FSU stabilization. Classifications designed for blunt spinal injuries often fail to provide decision-making on fusion surgery for gunshot wounds [14—16].

Considering CT data on spinal gunshot injuries, we developed a scoring protocol for assessing instability in gunshot injuries to the thoracic and lumbar spine intended for neurosurgeons and traumatologists [11].

Material and methods

We analyzed responses from 19 expert surgeons regarding 30 cases that met selection criteria [17]. The previously developed questionnaires were used [11]. There were 13 neurosurgeons and 6 traumatologists among experts. All participants specialize in spinal trauma and work at specialized centers. Surgeons were provided with a guide on vertebral fracture classifications (AO Spine, TLICS, Load Sharing) and data on neurological status for each case [17]. Participants completed questionnaires twice with a two-month interval. Experts evaluated cases independently of one another. The questionnaires included questions regarding applicability of existing classifications (AO Spine, McCormack, TLICS, Denis) [15, 16, 18, 19] to each case. Surgeons were asked to diagnose any fracture and its significance:

Table 1. **Inter- and intra-observer agreement for available classifications of thoracolumbar spine fractures**

Classification	Kappa	95% CI		*p*
		Lower limit	Upper limit	
Primary answers				
McCormack	0.325	0.298	0.352	<0.001
TLICS	0.136	0.108	0.163	<0.001
AO Spine	0.266	0.238	0.293	<0.001
Denis	0.073	0.046	0.100	<0.001
Repeated answers				
McCormack	0.296	0.269	0.323	<0.001
TLICS	0.078	0.050	0.105	<0.001
AO Spine	0.296	0.269	0.324	<0.001
Denis	0.039	0.012	0.067	0.005
Intra-observer kappa				
McCormack	0.425			
TLICS	0.462			
AO Spine	0.520			
Denis	0.303			

0 — fracture does not affect instability;
1 —fracture affects instability in certain instances (combination with fractures of other structures), but such injury alone does not lead to destabilization;
2 — fracture of this structure (even without other injuries) results in absolute instability.

The kappa (κ) coefficient was used to assess inter-observer agreement among surgeons and intra-observer agreement regarding applicability of classifications, presence of injury and contribution of each anatomical structure to instability. We interpreted this coefficient using the Landis and Koch scale, where κ value <0.2 indicates slight agreement, 0.2—0.4 — fair, 0.4—0.6 — moderate, 0.6—0.8 — substantial, >0.8 — almost perfect. Vertebral arch and/or facet joint fractures were included in subgroup analysis (unilateral or bilateral fractures) to assess intra-group agreement. After analysis of results, we proposed a scoring system. After statistical analysis, we adjusted this classification to optimize specificity and sensitivity.

We assessed sensitivity and specificity of classification using Fletcher's methodology. The report was prepared in accordance with the GRRAS guidelines.

Results

Applicability of classifications of blunt fractures of the thoracolumbar spine

For the TLICS and Denis systems, we obtained statistically low inter-observer agreement (κ<0.2), although experts noted applicability of the Denis system for some fractures **(Fig. 1)**. The κ values were slightly higher for the McCormack and AO Spine classifications (fair agreement, 0.2<κ 0.4). Moderate intra-observer agreement was found for all classifications (0.4<κ<0.6), except for the Denis concept (κ=0.303) **(Table 1)**.

Significance of damage to specific bone structures regarding FSU instability

For posterior extra-articular osteoligamentous complex, we obtained moderate-to-fair inter-observer agreement (κ=0.44 and κ=0.374). There was moderate inter-observer agreement regarding no influence of transverse process fractures on instability (κ=0.417 and κ=0.434). Consequently, this parameter was excluded from classification. There were low κ values for significance of damage (specifically, articular process fractures) to a single facet joint (κ=0.257 and κ=0.325). This discrepancy arose because, in some instances, surgeons regarded damage to a single joint within FSU as an independent criterion for instability. In other cases, such damage was considered to cause instability only in conjunction with other fractures. Accordingly, this parameter was evaluated regarding its impact on instability.

Table 2. **Inter- and intra-observer kappa values for significance of fracture**

Structure	Impact on instability	Initial response. inter-observer kappa	Repeated response. inter-observer kappa	Intra-observer kappa
Posterior extra-articular osteoligamentous complex	No	0.253	0.176	0.679
	Yes	0.440	0.374	
Transverse processes	No	0.417	0.434	0.551
	Yes	0.041	0.082	
Facet joint on one side	No	0.180	0.032	0.576
	Yes	0.257	0.325	
Facet joint on both side	No	0.027	−0.002	0.622
	Yes	0.553	0.614	
Vertebral arch on one side	No	0.135	0.030	0.577
	Yes	0.394	0.419	
Vertebral arch on both side	No	0.106	No responses	0.636
	Yes	0.683	0.713	
Vertebral arch and facet joint on one side	No	0.052	0.077	0.602
	Yes	0.316	0.316	
Vertebral arch and facet joint on both side	No	−0.005	No responses	0.578
	Yes	0.082	0.123	
Vertebral arch and facet joint from different sides	No	No responses	No responses	0.571
	Yes	0.541	0.517	
Vertebral body involving one endplate / perforated fracture	No	0.155	0.157	0.550
	Yes	0.338	0.307	
Vertebral body involving both endplates / destruction of vertebral body	No	0.036	-0.007	0.623
	Yes	0.570	0.556	
Damage to adjacent vertebrae	No	0.113	0.075	0.551
	Yes	0.569	0.564	

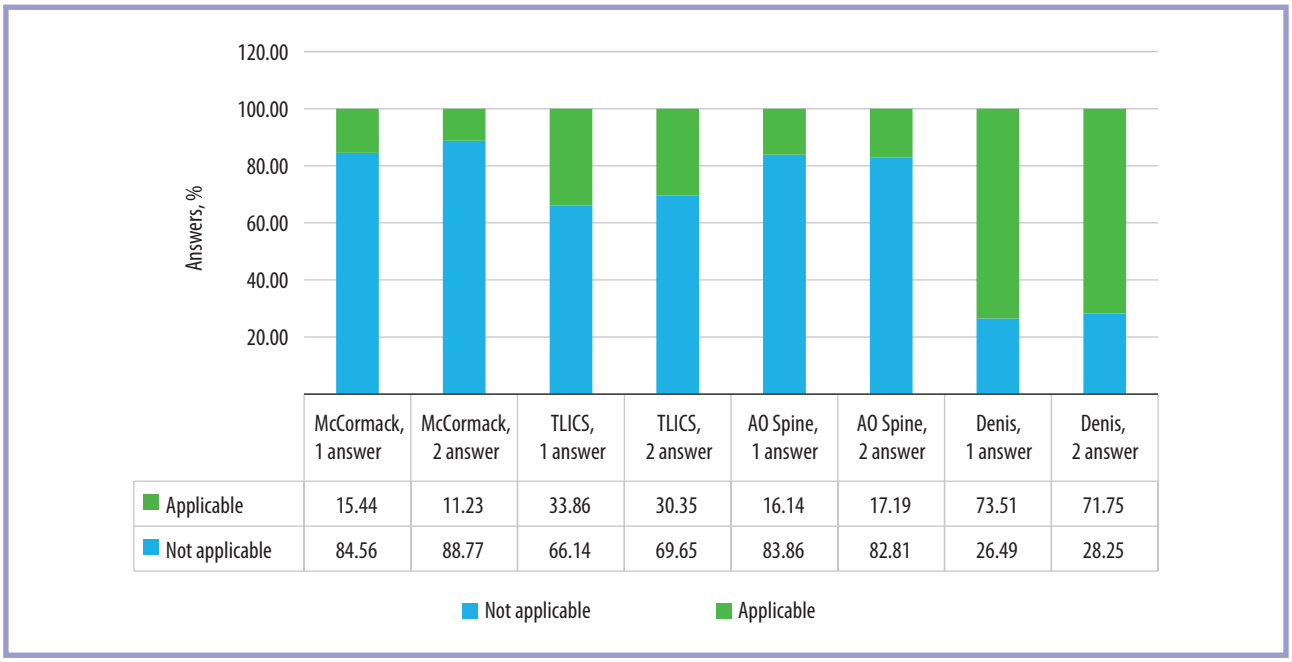

Fig. 1. **Answers regarding applicability of classifications.**

Table 3. **Classification of gunshot thoracolumbar spine fractures**

Damaged elements	Score	Damaged elements	Score
Facet joint on one side	1	Facet joint on both sides	10
Vertebral pedicle on one side	2	Vertebral pedicle on both sides	10
Perforated fracture or injury of one endplate	2	Damage to vertebral pedicle and facet joint from different sides	10
Adjacent vertebrae	3	Destruction of vertebral body or fracture of vertebral body involving both endplates	10
Posterior extra-articular osteoligamentous complex	2		
Assessment	**Total score**		
Stable fracture	0—6		
Borderline fracture	7—9		
Unstable fracture	⩾10		

There was moderate inter-observer agreement for unilateral vertebral arch fracture ($\varkappa$=0.394 and $\varkappa$=0.419).

We found moderate-to-substantial agreement for bilateral facet joint damage ($\varkappa$=0.553 and $\varkappa$=0.614) and bilateral vertebral arch fractures ($\varkappa$=0.683 and $\varkappa$=0.713). There was low disagreement regarding no effect of these structures on instability. High $\varkappa$ values classified these fractures as unequivocally destabilizing ones. Consequently, they were assigned maximum scores within classification.

All experts determined that bilateral damage to facet joints and vertebral arch led to instability. Considering moderate agreement ($\varkappa$=0.541 and $\varkappa$=0.517), we assigned the maximum grade to this fracture.

As with unilateral vertebral arch injury, we found fair inter-observer agreement regarding significance of fracture of vertebral body with one endplate (or perforated fracture of vertebral body) ($\varkappa$=0.338 and $\varkappa$=0.307). This parameter was also examined in greater detail.

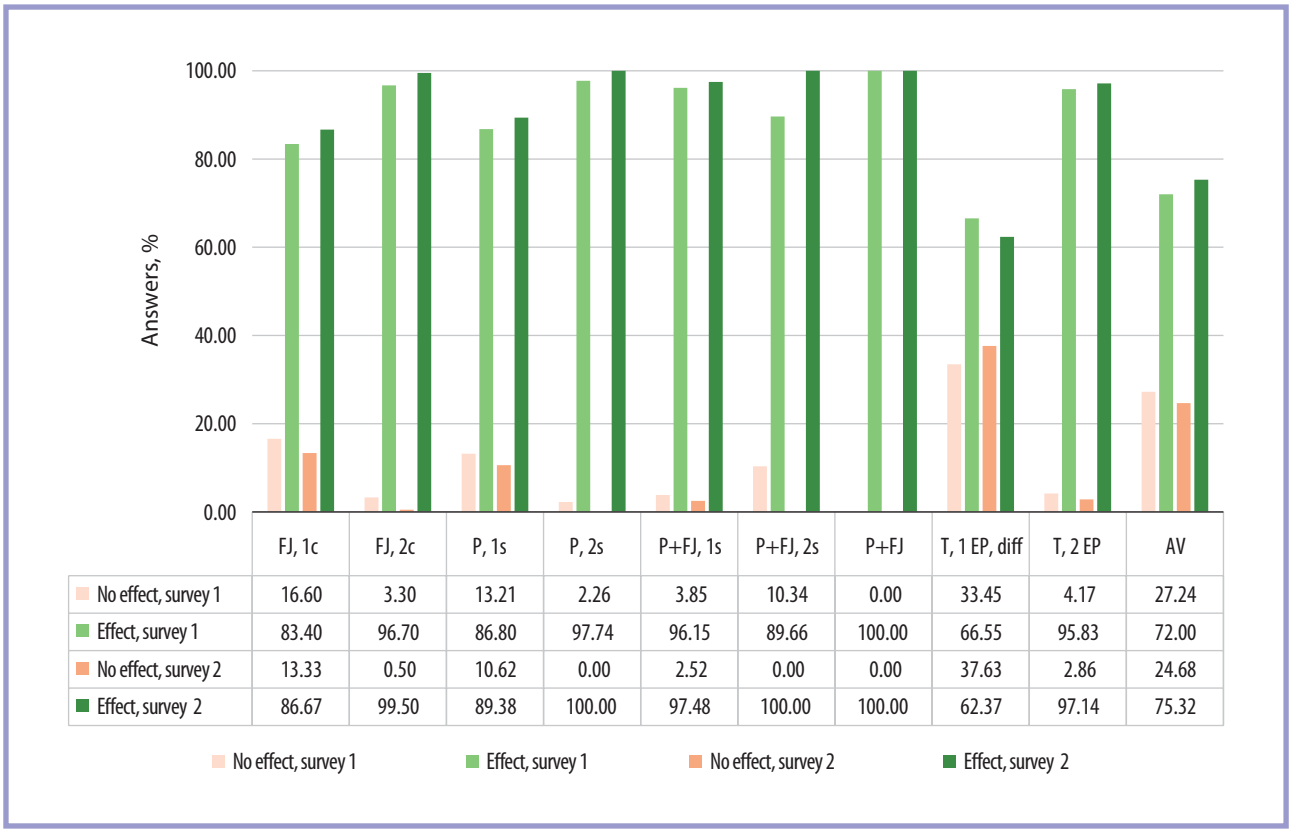

	FJ, 1c	FJ, 2c	P, 1s	P, 2s	P+FJ, 1s	P+FJ, 2s	P+FJ	T, 1 EP, diff	T, 2 EP	AV
No effect, survey 1	16.60	3.30	13.21	2.26	3.85	10.34	0.00	33.45	4.17	27.24
Effect, survey 1	83.40	96.70	86.80	97.74	96.15	89.66	100.00	66.55	95.83	72.00
No effect, survey 2	13.33	0.50	10.62	0.00	2.52	0.00	0.00	37.63	2.86	24.68
Effect, survey 2	86.67	99.50	89.38	100.00	97.48	100.00	100.00	62.37	97.14	75.32

Fig. 2. **Distribution of responses regarding the impact of fractures on instability.**
FJ — facet joint; P — pedicle; VB — vertebral body; AV — adjacent vertebra; 1s — unilateral; 2s — bilateral; diff — contralateral/different sides; EP — endplate.

Table 4. **Specificity and sensitivity for unstable fractures**

AUC	Standard error[a]	*p*	95% CI	
			Lower limit	Upper limit
0.866	0.015	<0.001	0.837	0.896

Table 5. **Specificity and sensitivity for stable fractures**

AUC	Standard error[a]	*p*	95% CI	
			Lower limit	Upper limit
0.888	0.015	<0.001	0.859	0.916

There was moderate agreement when assessing significance of destruction of vertebral body or its fracture involving both endplates ($\varkappa$=0.570 and $\varkappa$=0.556). We also classified this fracture as resulting in absolute instability. For all the aforementioned fractures, surgeons achieved moderate intra-observer agreement ($\varkappa_{min}$=0.551; $\varkappa_{max}$=0.679) **(Table 2)**.

Despite controversial inter-observer agreement regarding the impact of facet joint or vertebral arch fractures, the vast majority of surgeons acknowledged contribution of these bones. Expert surveys confirmed the influence of unilateral facet joint fractures and unilateral vertebral arch fractures on instability **(Fig. 2)**. These factors were included in classification, though they were not assigned absolute weight.

Distribution of responses regarding significance of bone fractures for instability is presented in **Fig. 3**, 4. In the vast majority of cases, participants believe that facet joint fractures influence FSU instability in certain instances (when combined with other injuries). A similar pattern was observed in responses concerning significance of unilateral pedicle fractures. Experts also noted the impact vertebral body fractures involving a single endplate on instability.

There was moderate inter-observer agreement regarding significance of fractures in adjacent vertebrae ($\varkappa$1=0.569; $\varkappa$2=0.564) **(Table 2)**. Surgeons considered this factor to influence instability in more than half of cases (60.51% and 60.34%). This variant is also described in scoring system as more significant.

Finalization of scoring system and assessment of its sensitivity / specificity

Bilateral damage to facet joints and/or fracture of vertebral pedicle, destruction of vertebral body or fracture of two endplates are classified as "absolutely unstable" even in case of isolated injury (within a single FSU). This allows for assignment of maximum values to these features.

Points for injuries of other structures were determined through iterative process. All score combinations, as well as instability assessments were tested for specificity and sensitivity. Final version of classification is presented in **Table 3**.

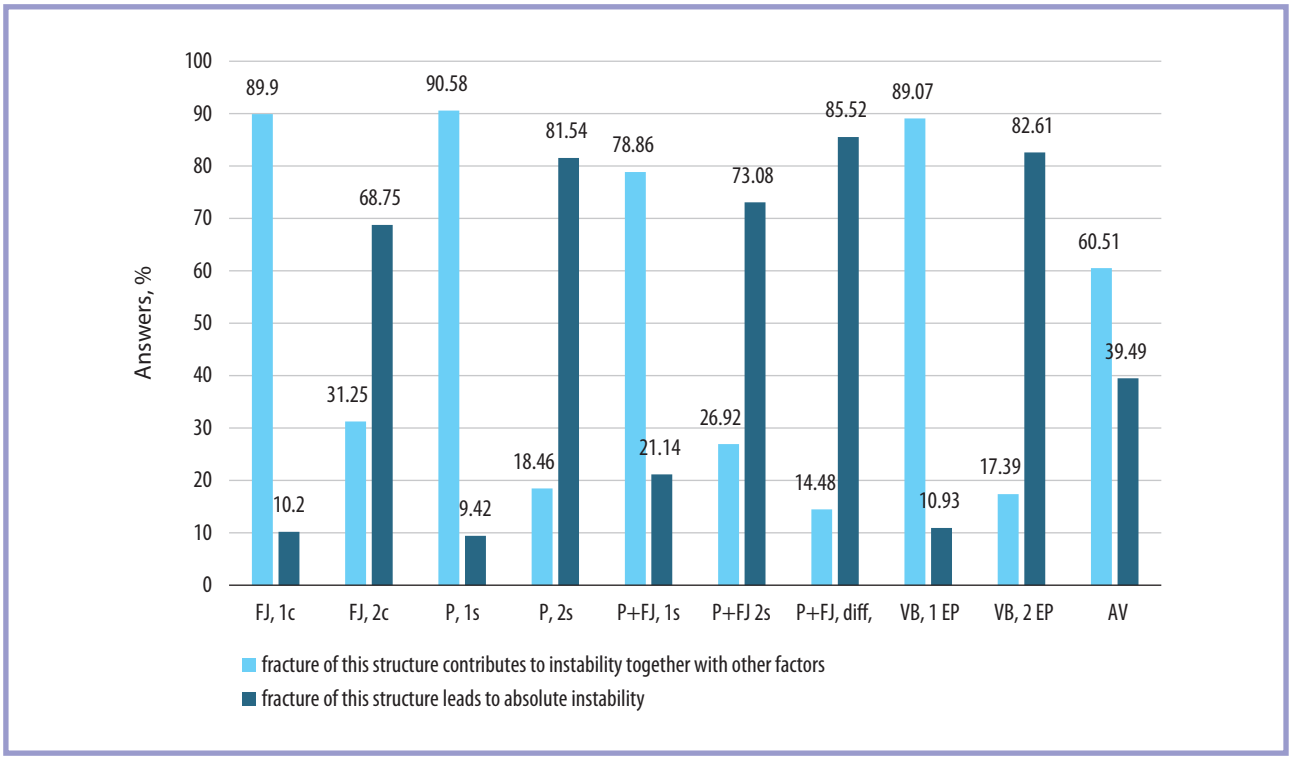

Fig. 3. **Assessment of fracture significance, first survey.**

For stable cases, sensitivity and specificity were 78.4% and 85.4% **(Table 4)**, for unstable fractures — 87.9% and 72.3%, respectively **(Table 5)**.

A new classification demonstrated high diagnostic accuracy for both outcomes. AUC was 0.866 (95% CI 0.837—0.896) for unstable fracture and 0.888 (95% CI 0.859—0.916) for stable fracture. Both values were significant ($p<0.001$) and corresponded to "excellent classifier" **(Fig. 5, 6)**.

Original classification offers a clear algorithm:

0—6 points — stable fracture not requiring surgical stabilization of functional spinal unit;

7—9 points — borderline injury (surgeon analyzed advisability of fusion surgery);

⩾10 points — unstable injury requiring stabilization of functional spinal unit.

Discussion

Traditional scoring systems (TLICS, Denis, AO Spine) are ineffective for gunshot spine injuries. Despite a high rate of positive responses regarding applicability of Denis con-

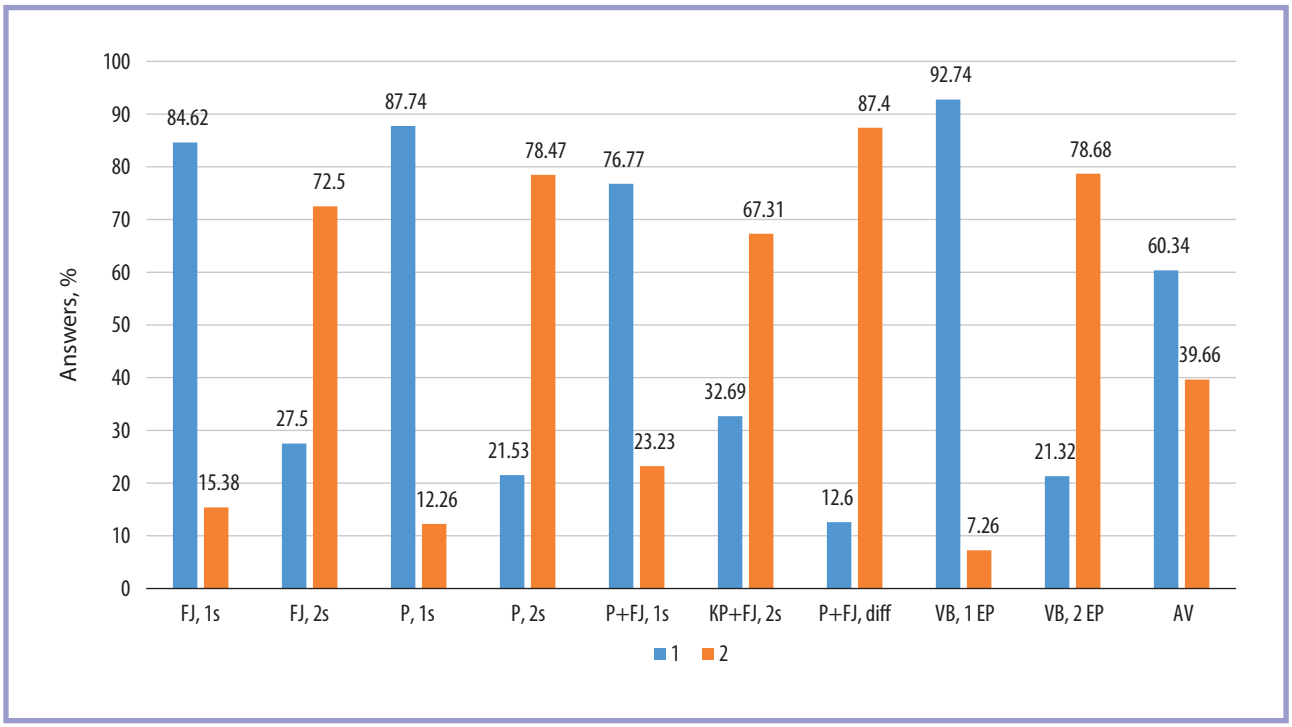

Fig. 4. **Assessment of fracture significance, second survey.**

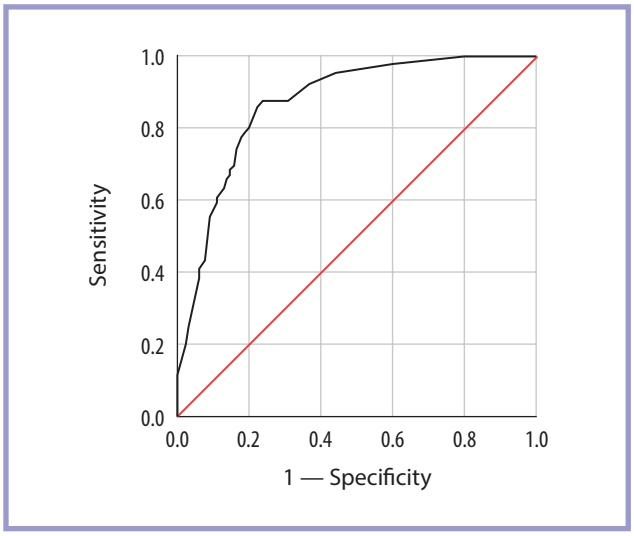

Fig. 5. **ROC curve for unstable fractures.**

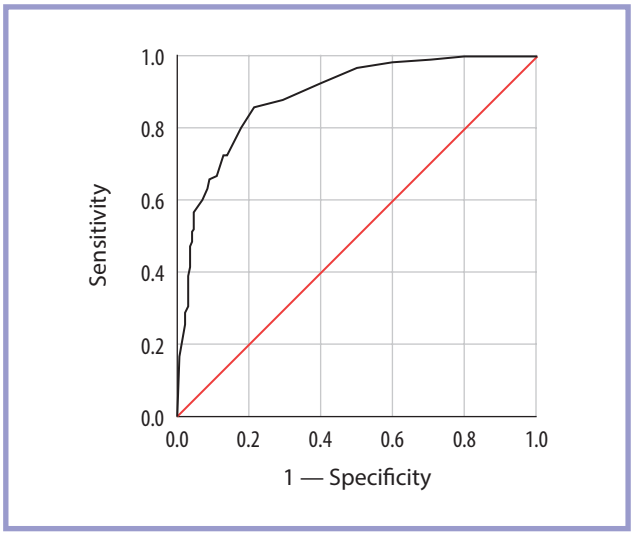

Fig. 6. **ROC curve for stable fractures.**

cept, we found significantly low inter-observer agreement (kappa coefficient 0.039 at repeated survey). This indicated that surgeons applied this classification to different (inconsistent) clinical cases. The McCormack and AO Spine classifications demonstrated slightly better, yet still insufficient results corresponding to fair agreement ($0.2<\varkappa<0.4$). This aligns with data on applicability of these systems for blunt trauma rather than ballistic injuries [10, 20]. Gunshot wounds are characterized by direct transfer of energy from the wounding projectile, cavitation and unpredictable trajectory of force distribution. There are certain difficulties to use traditional scoring systems in this patient population [10]. Most gunshot spine wounds are biomechanically stable. For instance, Gutierrez A. et al. [20] found no delayed instability after therapeutic treatment. Surgical stabilization is required in only 9.2—21% of cases [21].

In our study, survey of multidisciplinary group allowed for discussion among participants. This facilitated generation, discussion and inclusion of new perspectives in analysis. To avoid study limitations, we selected only specialists dealing with spinal and spinal cord injuries for expert analysis. We excluded survey results from several participants due to high number of unanswered items and high proportion of identical responses, as these factors could compromise the quality of statistical analysis. The Delphi method enabled data structuring and anonymous consensus among expert surgeons.

Expert consensus confirmed that only bilateral injuries of key structures (pedicle, facet joints) or complete destruction of vertebral body resulted in absolute instability. We developed a scoring system for assessing gunshot thoracolumbar spine injuries and criteria for appropriate patient management. This scale possesses excellent diagnostic accuracy (AUC 0.866—0.888). This is critically important, as many authors find no association between surgical decompression and neurological improvement (the ASIA scale) [10, 22—25]. This is particularly relevant for complete spinal cord injury, where the primary goal of surgery should shift towards mechanical stability.

Conclusion

Traditional classifications for blunt spinal injuries demonstrate extremely low reproducibility for gunshot wounds. Expert agreement was the highest regarding bilateral fractures of facet joints and pedicles, as well as vertebral body destruction involving both endplates. Transverse process fractures do not affect FSU stability, and we excluded this feature from final classification. Unilateral injuries of pedicles or facet joints generated more debate. Despite fair agreement regarding significance of perforated fractures, the vast majority (approximately 90%) of experts acknowledged their partial contribution to instability. Thus, we included this feature with low value.

For all bones, surgeons demonstrated moderate-to-substantial consistency in assessments upon re-evaluation two months later. This fact confirms significance of expert assessment as a foundation for a new classification system.

The Delphi method enabled objective assessment of specific injuries regarding FSU stability.

AUC characterizes original classification as an "excellent classifier" with 87.9% sensitivity and 72.3% specificity (for unstable fractures). This method can be recommended in neurosurgical and traumatological practice to optimize treatment strategies.

Author contribution:
Concept and design of the study — Manukovsky V.A., Kelin A.O., Kravtsov M.N., Antonov G.I.
Collection and analysis of data — Manukovsky V.A., Kelin A.O., Basankin I.V.
Statistical analysis — Manukovsky V.A., Kelin A.O., Kravtsov M.N., Badalov V.I., Aliev Z.Sh., Basankin I.V.
Writing the text — Manukovsky V.A., Kelin A.O.

No conflict of interests to declare.

REFERENCES

1. Lyons JG. Epidemiology of ballistic fractures in the United States: A 20-year analysis of the Firearm Injury Surveillance Study. *Injury*. 2022;53(11):3663-3672. https://doi.org/10.1016/j.injury.2022.09.011
2. Sankhyan M, Amin S, Botterbush KS, Urquiaga JF, Dwyer E, Place HM, Mercier PJ, El Tecle N, Mattei TA. Spinal gunshot wounds: A systematic review of the literature. *North American Spine Society Journal*. 2025;23:100755. https://doi.org/10.1016/j.xnsj.2025.100755
3. Bumpass DB, Buchowski JM, Park A, Gray BL, Agarwal R, Baty J, Zebala LP, Riew KD, Santiago P, Ray WZ, Wright NM. An update on civilian spinal gunshot wounds: treatment, neurological recovery, and complications. *Spine*. 2015;40(7):450-461. https://doi.org/10.1097/BRS.0000000000000797
4. Kulcheski ÁL, Graells XS, Sebben AL, Benato ML, Del Santoro PG. Management of spinal gunshot wound injuries. *Coluna/Columna*. 2021;20(3). https://doi.org/10.1590/S1808-185120212003242926
5. Orlov VP, Badalov VI, Mirzametov SD, Spitsyn MI. Classification of gunshot wounds to the spine and spinal cord. *Bulletin of the Russian Military Medical Academy*. 2026;28(1):45-56. (In Russ.). https://doi.org/10.17816/brmma681984
6. Jaiswal M, Mittal RS. Concept of Gunshot Wound Spine. *Asian Spine Journal*. 2013;7(4):359-364. https://doi.org/10.4184/asj.2013.7.4.359
7. Ricciardi GA, Cirillo I, Cabrera JP, Alvarenga Pereira OV, Vialle EN, Carazzo C, Dittmar M, Guiroy A, Yurac R, Schroeder GD. Mechanical Instability After Civilian Thoracolumbar Gunshot Injuries: A Systematic Review to Support Classification Development. *Global Spine Journal*. 2026;16(2):1300-1316. https://doi.org/10.1177/21925682251379371
8. Sconzo D, Penumaka A, Berube M, Wadhwa A, Arunachalam Sakthiyendran N, Balagurunath K, Wetsel Z, Enriquez-Marulanda A, Binello E. Management of civilian ballistic injuries to the spine: practice patterns and recovery outcomes at a level 1 trauma center. *Journal of Spine Surgery*. 2025;11(3):463-476. https://doi.org/10.21037/jss-25-66

9. Jacob A, Loibl M, Kruger S, Blankson BH, Zderic I, Wirtz CR, Dunn RN, Kruger NA. Civilian ballistic spinal cord injuries versus blunt trauma: comparative analysis of clinical characteristics, management, and outcomes. *The Spine Journal*. 2025;25(3):568-580. https://doi.org/10.1016/j.spinee.2024.10.006
10. Santangelo G, Wathen C, Pieters T, George DD, Worley L, Macaluso D, Dagli MM, Catanzaro S, Gu B, Welch WC, Petrov D, Vates GE, Ozturk AK, Schuster J, Stone JJ. Multi-institutional review of characteristics and management of gunshot wounds to the spine. *The Spine Journal*. 2024;24(9):1553-1560. https://doi.org/10.1016/j.spinee.2024.04.032
11. Esipov AV, Antonov GI, Manukovsky VA, Kravtsov MN, Chmutin GE, Timonin SYu, Danilov GV, Kelin AO. Scoring system for unstable spinal gunshot wounds: the study protocol. *Burdenko's Journal of Neurosurgery*. 2024;88(4):56-61. (In Russ.). https://doi.org/10.17116/neiro20248804156
12. Gupta R, Johnson R, Samadani U. Recovery of volitional movement with epidural stimulation after "complete" spinal cord injury due to gunshot: A case report and literature review. *Surgical Neurology International*. 2023;14:68. https://doi.org/10.25259/SNI_61_2023
13. Buendía Valdez DE, Soberanis Núñez AC, Taylor Martínez MA, Peña Rosas NP. Clasificación morfológica de heridas por proyectil de arma de fuego en columna vertebral [Morphological classification of gunshot wounds in the spine]. *Cir Columna*. 2025;3(3):158-166. (In Span.). https://doi.org/10.35366/120090
14. Trishkin DV, Kryukov EV, Alekseev DE, Samokhvalov IM, Alymov AN, Anufriev PL, Afonin SV, Balatskiy AV, Bobrov AE, Vlasov AP, Gritsanov AI, Zhiltsov AV, Zakharenko AA, Kavalerskiy AV, Kozlov KK, Kolsanov AV, Lebedev NV, Lubnin AYu, Moldaoglu KD, Popov VA, Popov SV, Remizov OV, Smirnov OA, Sokolov VV, Soroka VV, Stashkevich AV, Usenko LV, Khubutiya MSh, Chabak SV, Shapovalov KG, Shevchenko YuL. *Voenno-polevaya khirurgiya. Natsional'noe rukovodstvo.* M.: GEOTAR-Media; 2024. (In Russ.).
15. Vaccaro AR, Oner C, Kepler CK, Dvorak M, Schnake K, Bellabarba C, Reinhold M, Aarabi B, Kandziora F, Chapman J, Shanmuganathan R, Fehlings M, Vialle L; AOSpine Spinal Cord Injury & Trauma Knowledge Forum. AOSpine thoracolumbar spine injury classification system: fracture description, neurological status, and key modifiers. *Spine*. 2013;38(23):2028-2037. https://doi.org/10.1097/BRS.0b013e3182a8a381
16. Vaccaro AR, Lehman RA Jr, Hurlbert RJ, Anderson PA, Harris M, Hedlund R, Harrop J, Dvorak M, Wood K, Fehlings MG, Fisher C, Zeiller SC, Anderson DG, Bono CM, Stock GH, Brown AK, Kuklo T, Oner FC. A New Classification of Thoracolumbar Injuries: The Importance of Injury Morphology, the Integrity of the Posterior Ligamentous Complex, and Neurologic Status. *Spine.* 2005;30(20):2325-2333. https://doi.org/10.1097/01.brs.0000182986.43345.cb
17. Manukovsky VA, Kelin AO, Kravtsov MN, Antonov GI, Chmutin GE, Badalov VI, Kolesov SV, Basankin IV, Strunina YuV. Classification of unstable spinal gunshot wounds: interim results of the 2nd phase of the study. *Russian Journal of Neurosurgery*. 2025;27(3):46-57. (In Russ.). https://doi.org/10.63769/1683-3295-2025-27-3-46-57
18. McCormack T, Karaikovic E, Gaines RW. The load sharing classification of spine fractures. *Spine*. 1994;19(15):1741-1744. https://doi.org/10.1097/00007632-199408000-00014
19. Denis F. The three column spine and its significance in the classification of acute thoracolumbar spinal injuries. *Spine*. 1983;8(8):817-831. https://doi.org/10.1097/00007632-198311000-00003
20. Gutierrez A, Su YS, Vaughan KA, Miranda S, Chen HI, Petrov D, Malhotra NR, Schuster JM. Penetrating Spinal Column Injuries (pSI): An Institutional Experience with 100 Consecutive Cases in an Urban Trauma Center. *World Neurosurgery*. 2020;138:e551-e556. https://doi.org/10.1016/j.wneu.2020.02.173
21. Ricciardi G, Martinez O, Cabrera 21. J, Matta J, Davila V, Jimenez JM, Vilchis H, Tejerina V, Perez J, Cabrera JP, Yurac R. Spinal gunshot wounds: A retrospective, multicenter, cohort study. *Revista Espanola de Cirugia Ortopedica y Traumatologia*. 2024;68(4):328-335. https://doi.org/10.1016/j.recot.2023.07.001
22. Gizatullin ShKh, Aliev ZSh, Antonenko AV, Kazakov SP, Onnitsev IE. Endoscopic removal of an intradural foreign body from the lumbar spine after a blind penetrating gunshot wound (a case report). *Medical Bulletin of the Main Military Clinical Hospital named after N.N. Burdenko.* 2026;23(1). (In Russ.).
23. Avseytseva TYu, Ivolgin AF, Manukovskiy VA, Litvinenko IV, Tsygan NV, Mazur AS. Characteristics of combat-related spinal and spinal cord injuries in the acute and early phases among military servicemen. *Hospital Medicine: Science and Practice.* 2024;7(5):22-28. (In Russ.). https://doi.org/10.34852/GM3CVKG.2024.98.55.035
24. Ditzel RM, Kolcun JPG, Chiu L, Raksin PB, Towner JE. A natural history of penetrating ballistic spinal column injury: a single-center continuous case series: Presented at the 2025 AANS/CNS Joint Section on Disorders of the Spine and Peripheral Nerves. *Journal of Neurosurgery: Spine*. 2025;44(2):300-306. https://doi.org/10.3171/2025.6.SPINE25421
25. Ricciardi GA, Cabrera JP, Martínez O, Matta J, Vilchis H, Perez Ríos JJ, Carazzo CA, Dittmar M, Yurac R; AO Spine Latin America Trauma Study Group. Predicting early complications in patients with spinal gunshot wounds: A multicenter study. *Brain & Spine*. 2024;4:102766. https://doi.org/10.1016/j.bas.2024.102766

Received 21.01.2026
Reviced 19.03.2026
Accepted 20.07.2026

COMMENT

This study addresses an important problem in modern neurosurgery, traumatology and military field surgery (assessment of mechanical instability associated with gunshot thoracic and lumbar spine wounds). Under the rising incidence of spinal injuries caused by gunshots, shrapnel and landmines, surgeons increasingly face the need to make rapid and evidence-based decisions regarding spine fusion. Available classifications for blunt spinal trauma including AO Spine, TLICS, McCormick and Denis concept do not always adequately reflect biomechanical disruptions caused by gunshot wounds.

Scientific novelty of this report lies in development of a specialized, point-based tactical classification specifically for gunshot thoracolumbar spine wounds. This approach is well-founded. Indeed, the authors evaluate specific anatomical structures critical for FSU stability rather than simply transpose classifications for blunt trauma onto gunshot injuries. This is crucial for determining the need for spine fusion, when classic signs of instability are less obvious than in blunt flexion-distraction or rotational-translational injuries.

The study is methodologically sound. The authors employed expert assessment of clinical and radiographic cases, repeat evaluations after a two-month interval, inter- and intra-observer agreement using the kappa coefficient, and evaluation of diagnostic accuracy via ROC analysis. This design enabled not only creation of scale but also assessment of its reproducibility and practical utility. AUC for stable and unstable injuries demonstrates high diagnostic accuracy of original model. Practical utility is further enhanced by clear threshold values: stable injury, borderline zone, and unstable injury requiring fusion.

Analysis of limitations of available classifications warrants a particular attention. Traditional scoring systems for blunt thoracolumbar spine fractures lack sufficient reproducibility when applied to gunshot injuries. This constitutes a strong argument for developing a new management-oriented scale. Maximum scores in original classification were not assigned arbitrarily but based on expert consensus regarding the most critical destabilizing injuries.

Original classification may be useful for neurosurgeons, orthopedic surgeons, and military surgeons treating casualties with gunshot and blast-related spinal injuries. This system could potentially standardize management and reduce the risk of unreasonable refusal from fusion and excessively extensive surgery in patients with stable injuries. A scoring system will facilitate revision of relevant sections in military field surgery guidelines and determine the need for early fusion procedures. In turn, this will update equipment standards for forward-deployed specialized neurosurgical units ensuring them with appropriate instruments and implants.

The authors face a major task regarding retrospective and prospective validation of the scale and its integration into medical units and institutions.

Svistov D.V. (Saint Petersburg)