Burdenko's Journal of Neurosurgery
2026, No. 4, pp. 106–112
https://doi.org/10.17116/neiro202690031106

Microsurgical treatment of tentorial meningiomas: a systematic review

© R.A. Sultanov, R.S. Dzhindzhikhadze, A.V. Polyakov, V.S. Gadzhiagaev, A.N. Abdullaev, A.D. Zaitsev, E.I. Salyamova

Vladimirsky Moscow Regional Research Clinical Institute, Moscow, Russia

ABSTRACT
Tentorial meningiomas account for 3—6% of all intracranial meningiomas. Complexity of topographic and anatomical location along with variability of surgical approaches underscores the importance of investigating these tumors. A systematic review was conducted in accordance with the PRISMA 2020 guidelines. We enrolled the studies devoted to outcomes after microsurgical treatment between 1984 and 2024. Demographic characteristics, neuroimaging data and postoperative outcomes were estimated. A total of 18 studies were selected. There were 668 patients, mean age was 52.6 years (478 females, 190 males). Mean tumor diameter was 33±5.4 mm. Preoperative hydrocephalus was detected in 17.1% of cases. The rate of gross total resection was 78%, complication rate — 34.3%, mortality rate — 3.3%. Microsurgical resection is the gold standard for meningiomas. The purpose of surgery is safe resection of tumor while preserving neurovascular structures. Adjuvant therapy may be considered for small tumors or subtotal resection.

Keywords: *meningioma, tentorium cerebelli, posterior fossa, skull base.*

INFORMATION ABOUT THE AUTHORS:
Sultanov R.A. — https://orcid.org/0000-0003-1363-7564
Dzhindzhikhadze R.S. — https://orcid.org/0000-0003-3283-9524
Polyakov A.V. — https://orcid.org/0000-0001-7413-1968
Gadzhiagaev V.S. — https://orcid.org/0000-0001-7661-4402
Abdullaev A.N. — https://orcid.org/0000-0002-8297-9640
Zaitsev A.D. — https://orcid.org/0000-0002-0987-3436
Salyamova E.I. — https://orcid.org/0000-0001-6449-7114
Corresponding author: Sultanov R.A. — e-mail: rus4455@yandex.ru

TO CITE THIS ARTICLE:
Sultanov RA, Dzhindzhikhadze RS, Polyakov AV, Gadzhiagaev VS, Abdullaev AN, Zaitsev AD, Salyamova EI. Microsurgical treatment of tentorial meningiomas: a systematic review. *Burdenko's Journal of Neurosurgery*. 2026; 90(4):106–112. (In Russ.).
https://doi.org/10.17116/neiro202690041106

Introduction

Meningiomas are benign slow-growing tumors arising from arachnoid membrane cells. Intracranial meningiomas account for 25—40% of all primary CNS tumors. Among all intracranial meningiomas, tentorial meningiomas comprise 3—6% [1—7]. Surgical treatment is the gold standard for these tumors, although it has clear indications [8—12]. Radiotherapy can be used for small asymptomatic tumors and as adjuvant treatment for tumor growth control [13].

Several classifications of tentorial meningiomas are described in the literature. Taking into account complex anatomy of cerebellar tentorium and its notch, all ones are based on baseline growth site [12, 14, 15]. The most common and universal classification of tentorial meningiomas was proposed by Yasargil.

About 30% of all intracranial meningiomas are diagnosed incidentally. In other cases, tumors result symptoms due to brain compression [15]. Clinical manifestations of tentorial meningiomas before and after surgery depend on tumor growth nature that is associated with proximity of important neurovascular structures such as the brainstem, cranial nerves and large venous sinuses [5, 16—19].

Safe and effective surgical treatment requires a wide angle of attack, early visualization of tumor matrix and devascularization [9, 20—22]. Surgical approach depends on tumor size, location and relationship to critical brain structures. Variable approaches are used for tentorial meningiomas (convexital, interhemispheric and basal ones) [12, 18, 20—28].

Multiple reports devoted to tentorial meningiomas emphasize the relevance of this issue in neurosurgery. Taking into account various clinical manifestations, treatment approaches and potential complications, it is necessary to systematize available data to formulate clear recommendations for surgical treatment.

Table 1. **Characteristics of patients, meningiomas and treatment outcomes.**

Variable	Value
Patients, *n*	668
Age, years	52.6 (34-81)
Sex, *n*	Women — 478 Men — 190 Ratio 2.5:1
Tumor location, *n* (%)	Supratentorial — 180 (27) Infratentorial — 354 (53) Supra- and infratentorial — 134 (20)
Mean diameter, mm	33±5.4
Preoperative hydrocephalus, *n* (%)	114 (17.1)
Preoperative brainstem compression, *n* (%)	224 (33.5)
WHO Grade, *n*	I — 500; II — 40; III — 33; N — 113
CSF bypass surgery, *n*	VPS — 36; EVD — 11
Sinus invasion, *n* (%)	169 (25.3)
Resection quality, %	78
Complications, *n* (%)	4 (34.3)
Mortality, *n* (%)	21 (3.3)
Adjuvant therapy, *n* (%)	48 (7.5)

Note: VPS — ventriculoperitoneal shunting; EVD — external ventricular drainage; *N* — data not specified.

Material and methods

Searching strategy

A systematic review was conducted according to the PRISMA 2020 guidelines. We screened the Embase, Cochrane Library, PubMed and Google Scholar databases using the following keywords: «tentorial meningiomas», «tentorium», «falcotentorial meningiomas», «tentorial notch».

The following inclusion criteria were established: 1) original articles; 2) English-language reports; 3) sample size >1 patient; 4) available data on treatment method and outcomes; 5) description of only patients after surgical treatment.

The following exclusion criteria were used: 1) case reports; 2) unavailable full-text articles; 3) comments, letters to authors; 4) studies repeating data from the same patients; 5) description of only radiotherapy.

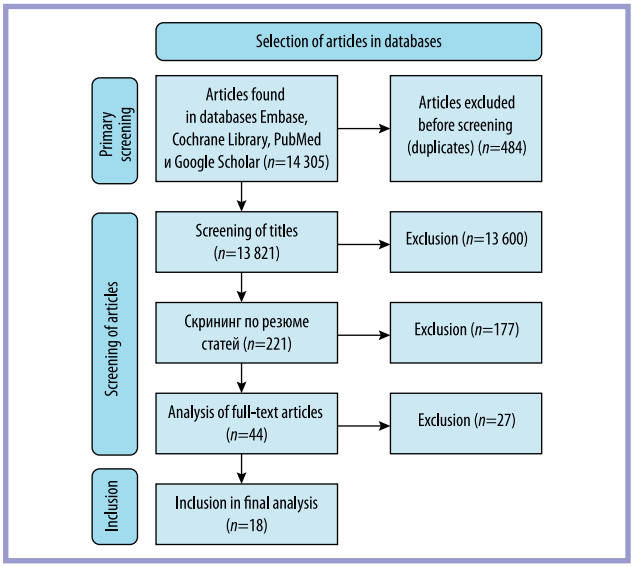

Figure. Study flowchart.

Data extraction

We extracted the following data: gender, age of patients, tumor location, relation to tentorium cerebelli, brainstem compression and hydrocephalus, tumor size before surgery, histological classification of meningiomas, data on CSF bypass surgery, venous sinus invasion, resection quality, complications, mortality and adjuvant treatment.

Topographic location of tentorial meningiomas was determined according to the Yasargil classification. T1–T2 — tentorial notch, T3–T8 — falcotentorial angle, T4 — paramedian location, T5 — confluence of sinuses, T6–T7 — lateral location.

Results

Selection of articles

Primary screening of the Embase, Cochrane Library, PubMed and Google Scholar databases identified 14.305 articles as of May 14, 2025 **(Figure)**. After re-

Table 2. Literature data.

Authors, years	Number of patients, *n*	M/F	Mean age, years	Tumor location					Relation to tentorium cerebelli, *n*			Mean iameter, mm	Hydrocephalus, *n*	Brainstem compression, *n*
				T1—T2	T3—T8	T4	T5	M	Supra-	Infra-	Supra- and infra-			
L.N. Sekhar et al., 1984 [22]	27	6/21	52	13	1	4	2	7	5	5	17	50	6	>14
B. Guidetti et al., 1988 [27]	61	20/41	50.7	21	8	6	0	26	23	25	13	N	N	>7
M. Samii et al., 1996 [20]	25	7/18	52	N	N	N	N	N	0	14	11	30	3	>19
P. Bret et al., 2000 [19]	27	7/20	53	10	7	3	3	4	4	17	6	35	13	>13
C. Schaller et al., 2002 [21]	25	3/22	56.4	4	3	5	0	13	10	9	6	40	1	>4
H. Bassiouni et al., 2004 [6]	81	12/69	55	19	7	12	2	41	15	59	7	N	16	>25
B.O. Colli et al., 2008 [2]	29	7/22	49.5	8	4	5	3	10	11	15	4	40	2	>12
D. Shukla et al., 2009 [28]	37	17/20	43	10	1	6	1	19	2	29	6	50	22	>21
P.H. Aguiar et al., 2010 [29]	30	8/22	49	3	3	5	5	14	12	13	5	43	6	>6
M. Hashemi et al., 2010 [11]	21	4/17	56	N	N	N	N	N	9	9	3	25	N	>12
C. Xiu et al., 2015 [26]	43	7/37	52.2	13	7	7	0	16	20	19	4	45	8	>N
A. Biroli et al., 2016 [7]	52	41/11	57	N	N	N	N	N	16	36	0	46	16	>N
A. Wagner et al., 2019 [30]	57	14/43	60	N	N	N	N	N	13	41	3	31	4	>N
C. Qin et al., 2020 [31]	53	12/41	52.5	N	N	N	N	N	5	23	25	39	2	>53
H.M. Soffar et al., 2021 [25]	32	7/25	48.4	11	2	2	0	17	9	14	9	N	1	>N
D. Cannizzaro et al., 2022 [32]	26	9/17	58.4	26	0	0	0	0	N	N	N	33.6	3	>26
A. AlBakry et al., 2023 [1]	18	6/12	50.2	4	2	1	3	8	5	10	3	54	5	>6
R.A. Sultanov et al., 2024 [18]	24	4/20	51.5	4	2	9	0	9	12	4	8	34	6	>6

Table 2. Literature data. (End)

Authors, years	WHO Grade			Ventricular drainage		Sinus invasion, *n* (%)	Resection quality, %	Complications, %	Mortality, *n* (%)	Adjuvant therapy, %
	I	II	III	VPS	EVD					
L.N. Sekhar et al., 1984 [22]	N	N	N	6	0	18 (67%)	44.40%	7.4—18.5	2 (7.4%)	N
B. Guidetti et al., 1988 [27]	N	N	N	N	N	49 (80%)	N	34	6 (9.8%)	0
M. Samii et al., 1996 [20]	N	N	N	2	1	4 (16%)	84%	4—28	0	N
P. Bret et al., 2000 [19]	26	1	0	8	0	7 (26%)	74%	55	1 (3.7%)	N
C. Schaller et al., 2002 [21]	20	5	0	0	1	8 (32%)	92%	20	0	1 (4%)
H. Bassiouni et al., 2004 [6]	77	3	1	3	0	18 (22%)	90%	42	2 (2.5%)	0
B.O. Colli et al., 2008 [2]	26	1	2	3	0	11 (38%)	87.50%	27.6	0	N
D. Shukla et al., 2009 [28]	26	5	2	2	0	N	45.90%	27	2 (5.4%)	7 (18.9%)
P.H. Aguiar et al., 2010 [29]	27	2	1	2	5	16 (53.3%)	86.70%	23	1 (3%)	6 (20%)
M. Hashemi et al., 2010 [11]	21	0	0	0	0	4 (19%)	90%	14.3	0	N
C. Xiu et al., 2015 [26]	34	8	1	0	2	2 (4.7%)	79%	2.3—4.6	0	6 (14%)
A. Biroli et al., 2016 [7]	46	6	0	1	0	13 (25%)	69%	10	0	6 (11.5%)
A. Wagner et al., 2019 [30]	52	4	1	4	0	13 (22.8%)	72%	15.8	1 (1.8%)	7 (12.3%)
C. Qin et al., 2020 [31]	53	0	0	0	0	6 (11.3%)	86.80%	3.8—15.1	0	4 (7.6%)
H.M. Soffar et al., 2021 [25]	30	2	0	3	0	N	81.30%	34.3	4 (12.5%)	N
D. Cannizzaro et al., 2022 [32]	24	0	2	N	N	N	84.60%	27	1 (3.8%)	5 (19%)
A. AlBakry et al., 2023 [1]	16	1	1	3	2	N	66.70%	27.8	1 (5.6%)	6 (33.3%)
R.A. Sultanov et al., 2024 [18]	22	2	0	2	0	N	91.70%	8.3	0	0

Note. T1–T2 — tentorial notch; T3–T8 — falctentorial angle; T4 — paramedian location; T5 — torcular region (confluence of sinuses); T6–T7 — lateral location.

moving duplicates, 13.821 articles were left for screening. After screening, we excluded 13.600 articles after analysis of titles and 177 manuscripts after analysis of abstracts. After analysis of full-text articles, we selected 18 articles.

Characteristics of patients and meningiomas

There were 18 articles devoted to microsurgical treatment of tentorial meningiomas between 1984 and 2024 (668 patients, 37.1 patients per a study, mean age 52.6 years). There were 478 women and 190 men (2.5:1) **(Table 1)**.

All meningiomas were classified according to the Yasargil classification, as well as in relation to tentorium cerebelli (supra-, infra- or infra- and supratentorial ones). There were 180 (27%) supratentorial meningiomas, 354 (54%) infratentorial tumors and 134 (20%) supra- and infratentorial meningiomas. Some authors proposed own classifications of meningiomas [18, 29, 30]. One study did not provide information on location of tumors in relation to tentorium cerebelli.

All patients underwent preoperative neuroimaging (MRI, CT). According to neuroimaging data, mean preoperative diameter of tentorial meningioma was 33±5.4 mm. Hydrocephalus was detected in 114 patients, brainstem compression — in 224 cases. All meningiomas are divided into 3 grades according to the WHO classification: Grade I — 500 patients, Grade II — 40 patients, Grade III — 33 patients.

Resection quality varies from 44.4% to 92% and depends on several key parameters: tumor size and location, relationship with surrounding neurovascular structures, presence of dissection plane between tumor capsule and pia mater, blood supply. Complication rate varies from 2.3% to 55%, mortality – from 0 to 12.5% [23, 28—30].

Ventriculoperitoneal shunting before or after resection was required in 36 (5.4%) cases. Eleven (1.6%) patients required external ventricular drainage in early postoperative period.

Discussion

The study included 18 studies devoted to microsurgical treatment of tentorial meningiomas over the past 40 years (1984 to 2024). The number of patients varied from 18 to 81 (mean 37.1 patients per a study).

Considering peculiarities of tentorial meningioma growth and principles of writing a systematic review, it is impossible to divide these tumors into two groups depending on clinical manifestations and surgical treatment, as well as postoperative period.

Headache and ataxia are the most common symptoms of tentorial meningioma. This is due to intracranial hypertension, hydrocephalus and compression of the brainstem/cerebellum and neurovascular structures [1, 7, 31—34].

Preoperative visual disturbances (reduced visual acuity and impaired visual fields) occurred in 9.6—38.9% of cases, dysfunction of oculomotor nerves (III, IV, VI) — in 3.3—28% of cases [1, 22, 24—26, 35—36].

Along with MRI and CT, neuronavigation and augmented reality techniques are introduced for individual virtual planning of surgical treatment [37—40].

According to most authors, digital subtraction cerebral angiography is controversial and ineffective for tentorial meningiomas [8, 14, 23, 25, 33]. Large randomized trials and reviews found no benefit of preoperative embolization compared to microsurgical resection. In addition, these methods may be associated with higher risk of postoperative venous thromboembolism [3, 8, 26, 35, 41, 42].

CSF shunting is an important treatment for patients with tentorial meningiomas. This method is used for rapid clinical deterioration, as well as to reduce intracranial pressure before tumor resection [16, 34, 36, 37, 43].

Neurosurgical technique for resection of tentorial meningioma implies several key principles: basal surgical approaches taking into account topographic localization, early visualization and devascularization of tumor matrix. Principles of microsurgical technique are based on manipulations within pial dissection border with early devascularization of tumor matrix and fragmentation of neoplasm while preserving all surrounding neurovascular structures [9, 18, 19, 22, 27].

Postoperative complications develop in 2.3—55% of cases. These events include surgical site infection and CSF leakage (7.1%), hemiparesis (6.6%), trigeminal nerve dysfunction (12%), hearing loss or deafness (5.3%), facial nerve dysfunction (4.2%), dysphagia (2.9%), ataxia (67.4%), oculomotor disorders (3.8—28%) and visual impairment (5.3—11.1%) [3, 16, 24]. We found the following factors influencing the outcomes of disease: location of tumor matrix, involvement of neurovascular structures, blood supply and tumor density, preoperative hydrocephalus, baseline status of patients [31, 32, 40, 44—46].

Mortality rate in the entire group was 3.3%. The main causes were brainstem edema and ischemia [7, 25, 28, 30], damage to large veins [1, 26, 32—34] and postoperative infectious complications [23, 31, 32] **(Table 2)**.

Over the past 40 years, skull base surgery has shifted towards a combined approach (surgery + radiotherapy). Although microsurgical treatment is still the gold standard for tentorial meningiomas, optimization of resection quality taking into account the possibilities of radiotherapy is confirmed by multiple modern studies and actively used as a method for tumor growth control [1, 4, 42—44, 47—51].

Conclusion

Despite available microsurgical techniques, tentorial meningiomas are still a complex pathology requiring an integrated approach. Advanced microsurgical techniques, preoperative planning of surgical approaches and adjuvant treatment make it possible to achieve the best results while maintaining high functional status and quality of life.

Author contribution:
Concept and design of the study — Sultanov R.A., Dzhindzhikhadze R.S.
Collection and analysis of data — Sultanov R.A., Salyamova E.I.
Statistical analysis — Polyakov A.V., Gadzhiagaev V.S., Zaitsev A.D.
Writing the text — Sultanov R.A., Abdullaev A.N.
Editing — Dzhindzhikhadze R.S.
No conflict of interests to declare.

REFERENCES

1. AlBakry A, Morsy AA, AlAwamry A, Taha MM, Samir MA. Surgical and functional outcomes of microsurgical resection of tentorial meningiomas: a single-center study. *Interdisciplinary Neurosurgery.* 2023;31:101706. https://doi.org/10.1016/j.inat.2022.101706
2. Colli BO, Assirati JA Jr, Deriggi DJ, Neder L, dos Santos AC, Carlotti CG Jr. Tentorial meningiomas: follow-up review. *Neurosurgical Review.* 2008;31(4):421-430; discussion 430. https://doi.org/10.1007/s10143-008-0141-9
3. Davidson C. Histopathologic and Molecular Evaluation of Meningioma. *Neurosurgery Clinics of North America.* 2023;34(3):311-318. https://doi.org/10.1016/j.nec.2023.02.001
4. Soni N, Ora M, Bathla G, Szekeres D, Desai A, Pillai JJ, Agarwal A. Meningioma: Molecular Updates from the 2021 World Health Organization Classification of CNS Tumors and Imaging Correlates. *AJNR American Journal of Neuroradiology.* 2025;46(2):240-250. https://doi.org/10.3174/ajnr.A8368
5. Ostrom QT, Price M, Neff C, Cioffi G, Waite KA, Kruchko C, Barnholtz-Sloan JS. CBTRUS Statistical Report: Primary Brain and Other Central Nervous System Tumors Diagnosed in the United States in 2016—2020. *Neuro-Oncology.* 2023;25(12 Suppl 2):iv1-iv99. https://doi.org/10.1093/neuonc/noad149
6. Bassiouni H, Hunold A, Asgari S, Stolke D. Tentorial meningiomas: clinical results in 81 patients treated microsurgically. *Neurosurgery.* 2004;55(1):108-116; discussion 116-118. https://doi.org/10.1227/01.neu.0000126886.48372.49
7. Biroli A, Talacchi A. Surgical Management of Lateral Tentorial Meningiomas. *World Neurosurgery.* 2016;90:430-439. https://doi.org/10.1016/j.wneu.2016.02.083
8. Han T, Liu X, Zhou J. Progression/Recurrence of Meningioma: An Imaging Review Based on Magnetic Resonance Imaging. *World Neurosurgery.* 2024;186:98-107. https://doi.org/10.1016/j.wneu.2024.03.051
9. Zhao X, Tavakol SA, Pelargos PE, Palejwala AH, Dunn IF. Open Surgical Approaches for Meningiomas. *Neurosurgical Clinics of North America.* 2023;34(3):381-391. https://doi.org/10.1016/j.nec.2023.02.004
10. Martz N, Salleron J, Dhermain F, Vogin G, Daisne JF, Mouttet-Audouard R, Tanguy R, Noel G, Peyre M, Lecouillard I, Jacob J, Attal J, Charissoux M, Veresezan O, Hanzen C, Huchet A, Latorzeff I, Coutte A, Doyen J, Stefan D, Feuvret L, Garcia GCTE, Royer P. Target volume delineation for radiotherapy of meningiomas: an ANOCEF consensus guideline. *Radiation Oncology.* 2023;18(1):113. https://doi.org/10.1186/s13014-023-02300-w
11. Hashemi M, Schick U, Hassler W, Hefti M. Tentorial meningiomas with special aspect to the tentorial fold: management, surgical technique, and outcome. *Acta Neurochirurgica.* 2010;152(5):827-834. https://doi.org/10.1007/s00701-009-0591-z
12. Supsupin EP Jr, Gonzales NS, Debnam JM. Anatomy and Pathology of the Skull Base: Malignant and Nonmalignant Lesions. *Oral and Maxillofacial Surgery Clinics of North America.* 2023;35(3):413-433. https://doi.org/10.1016/j.coms.2023.03.001
13. Himič V, Burman RJ, Fountain DM, Hofer M, Livermore LJ, Jeyaretna DS. Metastatic meningioma: a case series and systematic review. *Acta Neurochirurgica.* 2023;165(10):2873-2883. https://doi.org/10.1007/s00701-023-05687-3
14. Birua GJS, Sadashiva N, Konar S, Sai Phaneendra G, Jose Pulickal S, Shashidhar A, Prabhuraj AR, Beniwal M, Vazhayil V, Lingaraju TS, Arimappamagan A, Shukla D. Surgical outcome of sinodural meningiomas. *Journal of Clinical Neuroscience.* 2024;128:110804. hhttps://doi.org/10.1016/j.jocn.2024.110804.
15. Barić H, Komljenović S, Garcia SG, Niemelä M. Skull base meningiomas: A bibliometric analysis and comprehensive overview of clinical reports. *Neurochirurgie.* 2025;71(2):101632. https://doi.org/10.1016/j.neuchi.2025.101632
16. Dabecco R, Maniakhina L, Borghei-Razavi H. Keyhole retrosigmoid approach for resection of a petro-tentorial meningioma causing trigeminal neuralgia. *Clinical Neurology & Neurosurgery.* 2023;229:107723. https://doi.org/10.1016/j.clineuro.2023.107723
17. Sales AHA, Steiert C, Behringer SP, Bissolo M, Omer M, Loidl TB, Beck J, Grauvogel J. Falcotentorial Meningiomas: Insights from Surgical Strategies and Clinical Outcomes. *Journal of Clinical Medicine.* 2024;13(7):1963. https://doi.org/10.3390/jcm13071963
18. Sultanov RA, Dzhindzhikhadze RS, Polyakov AV, Gadzhiagaev VS, Zaitsev AD, Salyamova EI. Immediate and long-term results of microsurgical resection of tentorial meningiomas. *Head and Neck Tumors (HNT).* 2024;14(3):22-29. (In Russ.). https://doi.org/10.17650/2222-1468-2024-14-3-22-29
19. Bret P, Guyotat J, Madarassy G, Ricci AC, Signorelli F. Tentorial meningiomas. Report on twenty-seven cases. *Acta Neurochirurgica.* 2000;142(5):513-526. https://doi.org/10.1007/s007010050464
20. Samii M, Carvalho GA, Tatagiba M, Matthies C, Vorkapic P. Meningiomas of the tentorial notch: surgical anatomy and management. *Journal of Neurosurgery.* 1996;84(3):375-381. https://doi.org/10.3171/jns.1996.84.3.0375
21. Schaller C, Meyer B, Jung A, Erkwoh A, Schramm J. Results for microsurgical removal of tentorial meningiomas. *Zentralblatt für Neurochirurgie.* 2002;63(2):59-64. https://doi.org/10.1055/s-2002-33971
22. Sekhar LN, Jannetta PJ, Maroon JC. Tentorial meningiomas: surgical management and results. *Neurosurgery.* 1984;14(3):268-275. https://doi.org/10.1227/00006123-198403000-00002
23. Birua GJS, Sadashiva N, Konar S, Shashidhar A, Beniwal M, Vazhayil V, Shukla D. Surgical Outcome of Torcula Herophili Meningioma: An Institutional Experience. *World Neurosurgery.* 2024;184:e765-e773. https://doi.org/10.1016/j.wneu.2024.02.030
24. Nasrallah MP, Aldape KD. Molecular classification and grading of meningioma. *Journal of Neuro-Oncology.* 2023;161(2):373-381. https://doi.org/10.1007/s11060-022-04228-9
25. Soffar HM, El Shimy MM, Al-Shami H, Salah AM. Surgical management of tentorial meningiomas: case series. *The Egyptian Journal of Neurology, Psychiatry and Neurosurgery.* 2021;57:86. https://doi.org/10.1186/s41983-021-00340-1
26. Xiu C, Ma S, Zhang H, Wang Y, Yang J. Tentorial meningiomas: surgical options, clinical feature and management experience in 43 patients. *Clinical Neurology and Neurosurgery.* 2015;130:128-133. https://doi.org/10.1016/j.clineuro.2014.12.010
27. Guidetti B, Ciappetta P, Domenicucci M. Tentorial meningiomas: surgical experience with 61 cases and long-term results. *Journal of Neurosurgery.* 1988;69(2):183-187. https://doi.org/10.3171/jns.1988.69.2.0183
28. Shukla D, Behari S, Jaiswal AK, Banerji D, Tyagi I, Jain VK. Tentorial meningiomas: operative nuances and perioperative management dilemmas. *Acta Neurochirurgica.* 2009;151(9):1037-1051. https://doi.org/10.1007/s00701-009-0421-3
29. Aguiar PH, Tahara A, de Almeida AN, Kurisu K. Microsurgical treatment of tentorial meningiomas: Report of 30 patients. *Surgical Neurology International.* 2010;1:36. https://doi.org/10.4103/2152-7806.66851
30. Wagner A, Joerger AK, Lange N, Meyer B, Shiban E. Surgical and Functional Outcome after Resection of 57 Tentorial Meningiomas. *Scientific Reports.* 2019;9(1):14648. https://doi.org/10.1038/s41598-019-51260-3
31. Qin C, Wang J, Long W, Xiao K, Wu C, Yuan J, Pan Y, Zhang C, Su J, Yuan X, Liu Q. Surgical management of tentorial notch meningioma guided by further classification: a consecutive study of 53 clinical cases. *Frontiers in Oncology.* 2020;10:609056. https://doi.org/10.3389/fonc.2020.609056

32. Cannizzaro D, Milani D, Zaed I, Tropeano MP, Nicolosi F, Costa F, Servadei F, Fornari M, D'Angelo V, Cardia A. Tentorial Notch Meningiomas: Innovative Preoperative Management and Literature Review. *Frontiers in Surgery.* 2022;9:840271. https://doi.org/10.3389/fsurg.2022.840271
33. Beutler BD, Lee J, Edminster S, Rajagopalan P, Clifford TG, Maw J, Zada G, Mathew AJ, Hurth KM, Artrip D, Miller AT, Assadsangabi R. Intracranial meningioma: A review of recent and emerging data on the utility of preoperative imaging for management. *Journal of Neuroimaging.* 2024;34(5):527-547. https://doi.org/10.1111/jon.13227
34. Song D, Cai R, Lou Y, Zhang K, Xu D, Yan D, Guo F. Advancements in the application of MRI radiomics in meningioma. *Radiation Oncology.* 2025;20(1):105. https://doi.org/10.1186/s13014-025-02679-8
35. Upreti T, Dube S, Pareek V, Sinha N, Shankar J. Meningioma grading via diagnostic imaging: A systematic review and meta-analysis. *Neuroradiology.* 2024;66(8):1301-1310. https://doi.org/10.1007/s00234-024-03404-0
36. Van Gestel F, Frantz T, Buyck F, Geens W, Neuville Q, Bruneau M, Jansen B, Scheerlinck T, Vandemeulebroucke J, Duerinck J. Neuro-oncological augmented reality planning for intracranial tumor resection. *Frontiers in Neurology.* 2023;14:1104571. https://doi.org/10.3389/fneur.2023.1104571
37. Faulkner DE, Feng R, Matsoukas S, Odland IC, Philbrick B, Gutzweiller E, Tabani H, Bruhat A, Kwon F, Baker TS, Schlachter L, Oemke H, Kellner C, Mocco J, Fifi J, Shigematsu T, Majidi S, Shoirah H, Leacy R, Berenstein A, Shrivastava R, Dunn S, Bederson J, Rapoport BI. Quantifying extent of meningioma preoperative embolization through volumetric analysis: A retrospective case series. *Interventional Neuroradiology.* 2024;28:15910199241267312. https://doi.org/10.1177/15910199241267312
38. Sahm F, Bertero L, Brandner S, Capper D, Goldbrunner R, Jenkinson MD, Kalamarides M, Lamszus K, Albert NL, Mair MJ, Berghoff AS, Mawrin C, Wirsching HG, Maas SLN, Raleigh DR, Reifenberger G, Schweizer L, Suwala AK, Tabatabai G, Tabouret E, Short S, Wen PY, Weller M, Le Rhun E, Wesseling P, van den Bent M, Preusser M. European Association of Neuro-Oncology guideline on molecular testing of meningiomas for targeted therapy selection. *Neuro-Oncology*. 2025;27(4):869-883. https://doi.org/10.1093/neuonc/noae253
39. Giammattei L, Starnoni D, Peters D, George M, Messerer M, Daniel RT. Combined petrosal approach: a systematic review and meta-analysis of surgical complications. *Neurosurgical Review.* 2023;46(1):172. https://doi.org/10.1007/s10143-023-02072-7
40. Emara MR, Abdulsada AM, Alayyaf AS, Baban HA, Al-Hchaimi HA, Ismail M, Hoz SS. Ambient wing cistern: History, anatomy, imaging and approaches: An overview. *World Neurosurgery: X.* 2024;25:100395. https://doi.org/10.1016/j.wnsx.2024.100395
41. Jimenez AE, Mukherjee D. High-Value Care Outcomes of Meningiomas. *Neurosurgery Clinics of North America.* 2023;34(3):493-504. https://doi.org/10.1016/j.nec.2023.02.016
42. Mehta NH, Patel RV, Gupta S, Arora H, Nawabi NL, Karanth R, Sadler S, Medeiros L, Jha R, Chavarro VS, Bernstock JD, Smith TR, Arnaout O. Cerebellopontine Angle Meningiomas: A Multi-Institutional Cohort Study. *Neurosurgery.* 2024;97(1):105-111. https://doi.org/10.1227/neu.0000000000003258
43. Georgakopoulou VE, Mathioudakis N, Papalexis P, Aravantinou-Fatorou A, Tarantinos K, Sklapani P, Trakas N, Spandidos DA, Fotakopoulos G. Factors related to morbidity and mortality of meningiomas resection-associated venous thromboembolism (Review). *Molecular and Clinical Oncology.* 2023;19(3):70. https://doi.org/10.3892/mco.2023.2666
44. Pikis S, Mantziaris G, Dumot C, Xu Z, Sheehan J. Stereotactic Radiosurgery for Intracranial Meningiomas. *Neurosurgery Clinics of North America.* 2023;34(3):455-462. https://doi.org/10.1016/j.nec.2023.02.010
45. Ehret F, El Baya L, Erridge SC, Bussière M, Verhoeff JJC, Niyazi M, Preusser M, Minniti G, Shih HA. Radiation Therapy for Meningiomas — Where Do We Stand and What's on the Horizon? *International Journal of Radiation Oncology, Biology, Physics* 2025;121(3):599-612. https://doi.org/10.1016/j.ijrobp.2024.10.034
46. Gendreau JL, Sheaffer K, Macdonald N, Craft-Hacherl C, Abraham M, Patel NV, Herschman Y, Lindley JG. Stereotactic radiosurgery for cerebellopontine meningiomas: a systematic review and meta-analysis. *British Journal of Neurosurgery.* 2023;37(2):199-205. https://doi.org/10.1080/02688697.2022.2064425
47. Chen WC, Lucas CG, Magill ST, Rogers CL, Raleigh DR. Radiotherapy and radiosurgery for meningiomas. *Neuro-Oncology Advances.* 2023;5:67-83. https://doi.org/10.1093/noajnl/vdac088
48. Goldman MJ, Teh BS, Lo SS, Butler EB, Baskin DS. Radiosurgery for Intracranial Meningiomas: A Review of Anatomical Challenges and an Update on the Evidence. *Cancers.* 2024;17(1):45. https://doi.org/10.3390/cancers17010045
49. Abdallah HM, Mallela AN, Wei Z, Abou-Al-Shaar H, Niranjan A, Lunsford LD. Gamma Knife radiosurgery for meningiomas of the confluence of the falx and tentorium. *Journal of Neuro-Oncology.* 2023;161(2):225-233. https://doi.org/10.1007/s11060-022-04125-1
50. Gawish A, Abdulayev N, El-Arayed S, Röllich B, Ochel HJ, Brunner TB. A single-center experience with linear accelerator-based stereotactic radiotherapy for meningiomas: hypofractionation and radiosurgery. *Journal of Cancer Research and Clinical Oncology.* 2023;149(1):103-109. https://doi.org/10.1007/s00432-022-04450-y
51. Wei Z, Jose SG, Agarwal P, Worrell S, Kulich S, Donohue JK, Deng H, Hadjipanayis CG, Niranjan A, Lunsford LD. Adjuvant Stereotactic Radiosurgery for Clear Cell Meningiomas. *World Neurosurgery.* 2024;184:784-793. https://doi.org/10.1016/j.wneu.2024.02.043

Received 12.08.2025
Revised 04.05.2026
Accepted 07.05.2026