Burdenko's Journal of Neurosurgery
2026, No. 4, pp. 87–92
https://doi.org/10.17116/neiro20269003187

Battery of tests for speech mapping in brain surgery «Linguistic intraoperative support»

© E.P. Dmitrova[1], S.B. Buklina[2], N.E. Gronskaya[1], A.S. Zyryanov[3], A.V. Chrabaszcz[4], E.S. Krasilova[1], I.V. Makarova[1], A.Sh. Minnigulova[3], E.A. Stupina[3], O.A. Tasenko[1], V.A. Tolkacheva[5], K.V. Untila[1], M.I. Hodzhametova[1], M.V. Khudyakova[1], O.V. Dragoy[3]

[1]Nizhny Novgorod Branch of Higher School of Economics, Nizhny Novgorod, Russia;
[2]Burdenko Neurosurgical Center, Moscow, Russia;
[3]National Research University Higher School of Economics, Moscow, Russia;
[4]University of Pittsburgh, Pittsburgh, USA;
[5]Queensland University of Technology, Brisbane, Australia

ABSTRACT
Effective intraoperative speech mapping requires specific test with standardized linguistic material. The last one should capture speech function supported by brain region targeted for resection. It is necessary to develop a test tailored to specific patient's needs and document intraoperative linguistic support.
The objective of this report was to describe the procedure of intraoperative speech testing and battery of intraoperative tests for Russian language. We correlated intraoperative tests with brain regions and speech functions, as well as presented an application for intraoperative linguistic testing.

Keywords: *intraoperative speech tests, speech mapping, awake craniotomy.*

INFORMATION ABOUT THE AUTHORS:
Dmitrova E.P. — https://orcid.org/0009-0009-4150-230X
Buklina S.B. — https://orcid.org/0000-0002-9451-3565
Gronskaya N.E. — https://orcid.org/0000-0003-0593-2395
Zyryanov A.S. — https://orcid.org/0000-0002-3797-2722
Chrabaszcz A.V. — https://orcid.org/0000-0002-1766-7245
Krasilova E.S. — https://orcid.org/0009-0007-8503-1699
Makarova I.V. — https://orcid.org/0000-0002-8458-9777
Minnigulova A.Sh. — https://orcid.org/0000-0002-5568-8311
Stupina E.A. — https://orcid.org/0000-0001-7108-4393
Tasenko O.A. — https://orcid.org/0000-0001-7703-0142
Tolkacheva V.A. — https://orcid.org/0000-0001-7920-4935
Untila K.V. — https://orcid.org/0000-0003-0798-1350
Hodzhametova M.I. — https://orcid.org/0009-0002-9573-3698
Khudyakova M.V. — https://orcid.org/0000-0002-5293-3991
Dragoy O.V. — https://orcid.org/0000-0002-6777-5164
Corresponding author: Dmitrova E.P. — e-mail: dmitrovaelizaveta@yandex.ru

TO CITE THIS ARTICLE:
Dmitrova EP, Buklina SB, Gronskaya NE, Zyryanov AS, Chrabaszcz AV, Krasilova ES, Makarova IV, Minnigulova ASh, Stupina EA, Tasenko OA, Tolkacheva VA, Untila KV, Hodzhametova MI, Khudyakova MV, Dragoy OV. Battery of tests for speech mapping in brain surgery «Linguistic intraoperative support». *Burdenko's Journal of Neurosurgery*. 2026;90(4):87–92. (In Russ.).
https://doi.org/10.17116/neiro20269004187

Introduction

Intraoperative speech mapping in awake craniotomy is valuable to identify individual areas involved in speech in each patient. This enables maximum possible resection with minimal speech impairment [1—3].

Dmitrova E.P. et al. [4] reviewed basic concepts of speech localization in the brain, as well as tasks for speech mapping. The table summarizes this review and briefly presents the main speech functions, appropriate speech tests and brain regions (in speech-dominant hemisphere) responsible for each speech function. When selecting tests, it is important to consider that a single speech test is not limited to assessing a single function. For example, impaired articulation can be identified with any speech production task.We present a battery of tests and an application for intraoperative speech mapping, as well as describe testing procedure in details.

***Table*. Selection of intraoperative tests depending on localization of resection (in speech-dominant hemisphere) and speech functions supported by appropriate brain region.**

Speech test	Main function	Regions and tracts that can be mapped by the test		
		Frontal lobe	Temporal lobe	Parietal lobe
Naming of objects	Semantic processing [5]	Uncinate fasciculus [6]	Superior temporal gyrus [1, 6–8]; middle temporal gyrus [6, 9]; inferior temporal gyrus [7, 8]; pole of the temporal lobe [8, 9]; inferior longitudinal fasciculus [6]; inferior fronto-occipital fasciculus [1, 6]	Supramarginal gyrus [1, 6, 10]; postcentral gyrus [7]
Naming of actions	Syntactic processing [1, 5]	Inferior frontal gyrus [1]		Postcentral gyrus [7]
Repetition of pseudowords	Sensorimotor integration, initiation of motor implementation	Inferior frontal gyrus [1, 11]; primary, premotor, and supplementary motor cortex [6]; precentral gyrus [1, 6, 11]; anterior segment of arcuate fasciculus [1]	Long segment of arcuate fasciculus [1]	Posterior segment of arcuate fasciculus [1]
Sentence completion	Initiation of speech	Supplementary motor cortex [1, 12]; frontal aslant tract [1, 13]		
Syllable distinction	Phonological processing		Superior temporal gyrus [1]	
Word-picture matching	Integration of semantic and phonological information		Superior temporal gyrus [1, 8, 9]; inferior temporal gyrus [8, 9]; pole of the temporal lobe [8, 9]; inferior fronto-occipital fasciculus [1]	
Reading	Reading		Inferior longitudinal fasciculus [1, 6]	Supramarginal gyrus [1]; angular gyrus [1]

1. Battery of tests for intraoperative speech testing.

To facilitate the procedure and automate selection and presentation of speech tests, the «LIS» application (Linguistic Intraoperative Support) was developed (available in RuStore). The application allows for recording demographic data, selecting necessary tests depending on resection site and its proximity to white matter tracts and their terminals, selecting suitable tests during preoperative testing, presenting final intraoperative test with all technical features taken into account and maintaining surgical record (responses and error types, regions of speech errors for various stimulation points).

Tasks are presented to the participant on a tablet. Stimuli are presented automatically one after another in video format at 4-second intervals [13]. Each stimulus is always preceded by a sound signal (frequency 400 Hz, duration 0.5 s). At any time during test presentation, it is possible to stop or return to earlier trials. All speech stimuli were pre-recorded in a studio by a professional announcer.

1.1. Naming of objects and actions.

The object and action naming test [5] consists of 50 black-and-white drawings of objects or actions, respectively. Appropriate material was selected from standard databases «Stimulus library: verbs and actions» [14] and «Stimulus library: noun and object». We standardized drawings and nominations according to some psycholinguistic parameters specified in databases: for drawings — stability of nomination, familiarity with action/object, subjective complexity of drawing; for words — age of acquisition, representability, similarity of the image to the drawing, objective complexity, frequency, word length; for verbs — reflexivity, instrumentality and nominal correlation. To determine acceptable nominations, each drawing was named by one hundred neurologically healthy native Russian speakers. This made it possible to establish a list of possible nominations for each drawing [5, 14].

The patient's task is to respond to what is depicted in the drawing using the constructions: «This is...» + a noun in nominative case (e.g., «This is a cactus») and «Here...» + a verb in present simple (e.g., «They dance here»). These constructions distinguish speech arrest from anomia (inability to recall and name the desired word).

1.2. Repetition of pseudowords.

The patient is presented with a set of 50 stimuli taking into account phonetic patterns of Russian language. Stimuli vary in the number of syllables, stress and presence/absence of consonant clusters. Thus, 25 test stimuli consist of two syllables («zhigon»), other 25 — 3 syllables («monosha»). In each of these two groups, half of the stimuli con-

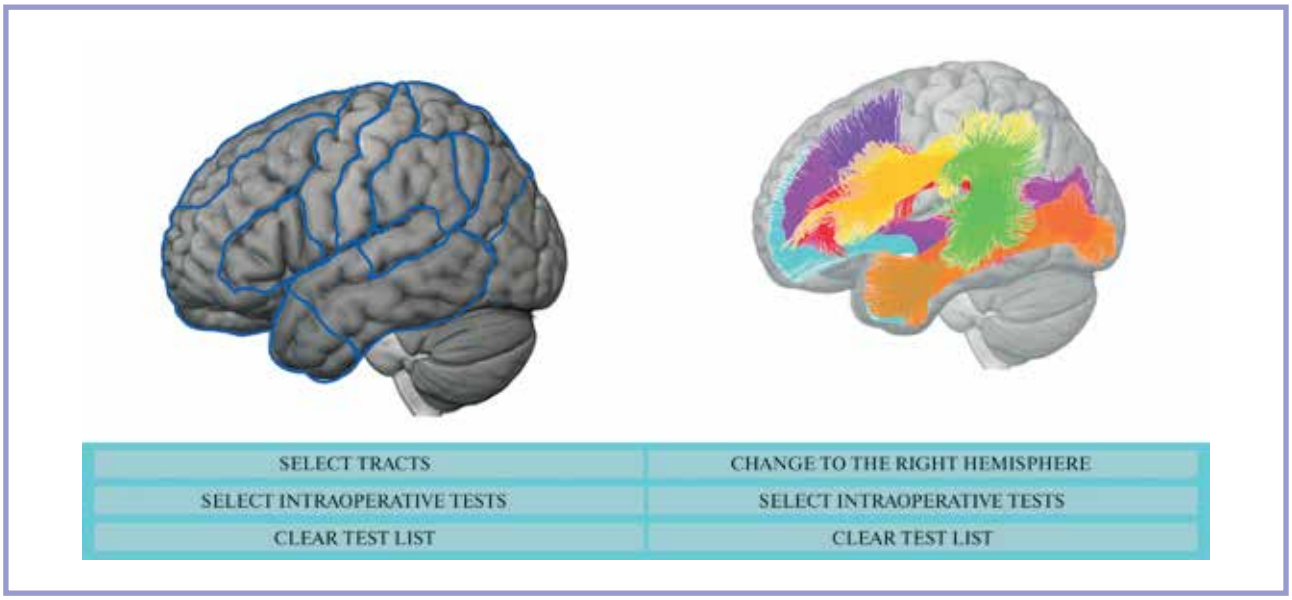

Figure. Selection of cortical representations and speech tracts within resection site using the LIS application.

tain consonant clusters («servet»), while the other half does not («chitatok»). In each subgroup (with and without clusters), an equal number of stimuli are presented with stress on the first («zhigon»), second («chitatok») or third («servet») syllable of the pseudoword. The patient's task is to repeat the pseudoword heard as accurately as possible.

1.3. Syllable distinction.

The patient is presented with a set of 100 pairs of syllables (50 ones are identical, and 50 differ in one consonant sound). Various pairs represent fundamental phonological contrasts of Russian language: voiced / voiceless («duf» — «tuf»), hard/soft («mas» — «myas»), as well as differences in method and location of consonant formation («kyl» — «khyl»). Differences are primarily in initial position. The patient should decide whether the stimuli heard are identical (answer «yes» or «no»).

1.4. Word-picture matching.

The patient is presented with one of 100 images of objects simultaneously with a Russian word that either exactly matches the object or differs from it by one sound. For half of the subjects, image and word are identical, while for the other half, the vowel or consonant sound differs. Stimulus material was selected from the «Stimuli Library: Noun and Object» database. Images were selected from the same database as for the naming tests. Therefore, psycholinguistic parameters were standardized in the same way. The patient's task is to determine whether the named word matches the image on the screen (answer «yes» or «no»).

1.5. Sentence completion.

In sentence completion test [13], the patient is presented with a set of 50 stimuli on the screen. Each one represents two-word beginning of sentence. The words are 1—2 syllables long allowing for presentation time of each trial (4 s). Stimulus sentences have a similar structure: animate subject (human in 25 sentences and animal in 25 sentences) and transitive verb (present simple in 25 sentences and past simple in 25 sentences) requiring a direct object to complete the sentence. The patient is required to read the beginning of the sentence and complete it with correct word (e.g., «A horse pulls a cart»).

1.6. Reading.

The patient is presented with a 416-word excerpt from the book «History of the Middle Ages» by Rodnikov I.A. The patient's task is to read the text aloud. Example excerpt: «...They sailed along the Mediterranean Sea to the ports of Syria and Egypt, as well as to the shores of the Black and Azov Seas...»

2. Intraoperative mapping procedure.

2.1 Test selection.

Neurosurgeons make decision regarding intraoperative awakening considering preliminary data on tumor location and size, proximity to speech pathways, the patient's willingness to cooperate during surgery, his / her emotional stability, as well as other medical indications. In consultation with the staff who will supervise awake surgery, this

decision is approved and included in surgical plan. This is crucial, as intraoperative tests (no more than three) relevant to speech function in at-risk area and accessible to the patient should be determined before surgery. These tests must be included in preoperative testing.

Selection of intraoperative tests is based on behavioral and neuroimaging data. To determine appropriate tests, the LIS application allows for selection of cortical representations and speech pathways near the lesion and resection site. The program generates a set of necessary intraoperative tests according to regions **(Figure)**.

2.2 Preoperative testing.

Preoperative testing immediately prior to surgery not only serves to establish speech status. It is also important preparation for intraoperative mapping. A standardized Russian aphasiological test [15] is used to determine speech skills. Testing with intraoperative tasks is valuable to select stimuli suitable for inclusion in intraoperative protocol. According to the protocol, each intraoperative test is performed twice. Tests named correctly both times are recorded in protocol while erroneous tests are excluded. Incorrect responses, no response and responses not meeting time limit (4 s) are erroneous. Excluded stimuli are not used during surgery. This approach reduces the number of false positive responses during mapping.

2.3 Intraoperative testing.

Staff members perform two main tasks during awake surgery: (1) intraoperative mapping of speech zones and maintaining intraoperative protocol, (2) intraoperative testing and maintaining contact with the patient. Immediately before surgery, a sequence of intraoperative tests is established according to the strategy determined by neurosurgeons.

After surgical approach, the patient is awakened from anesthesia. The tester assesses the patient's ability to speak and respond coherently to questions, engages in dialogue and conducts trial tests without stimulation. If the patient responds adequately, the tester signals neurosurgeons to begin mapping. Mapping is performed through direct stimulation with low currents using bipolar (on cerebral cortex) and monopolar (subcortical) electrodes. At the same time, the tester presents the patient with a speech task. Stimulus appears on the tablet screen for 4 seconds. A beep is then heard to synchronize presentation and stimulation, and surgeon moves the electrode to another point in surgical field. The tester verifies whether the test task is completed correctly or incorrectly (surgeons hear the tester's assessment). The staff member records the patient's responses in protocol (types of errors and speech pauses during cortical mapping and subsequent tumor resection, stimulation type (mono- or bipolar)). According to this information, various points involved in each speech function are determined. If errors are common during stimulation of the same point (for example, 2 out of 3), this region is involved in speech function.

As the lesion is resected, the tester follows a strategy agreed upon with surgeons and uses tests monitoring specific speech function supported by brain substrate within resection site. Between tests, the patient's speech status is controlled through conversation on pre-agreed topics. This interaction allows for continuous contact with the patient, assessment and support of emotional state and monitoring of potential speech disorders outside active testing phase.

Awake surgery ends when there is no further risk of damage to brain regions involved in speech function in neurosurgeons' opinion.

2.4 Postoperative testing.

After surgery, two control tests of speech skills are conducted using the Russian Aphasiological Test. The tester conducts postoperative testing at discharge and then 3-6 months after surgery to assess speech function recovery.

Conclusion

When selecting intraoperative tasks, one should consider many factors (location of cortical areas involved in specific speech functions within resection site, proximity of lesion to speech tract and accessibility of speech task for the patient). In this report, we presented selection of intraoperative tests for certain patient depending on tumor location and its proximity to conduction pathways, preparation of tests for speech mapping and awake surgery with linguistic support. The LIS (Linguistic Intraoperative Support) application will improve coordination between specialists conducting tests and surgical team, as well as simplify test selection and surgical protocol management.

Author contribution:
Concept and design of the study — Minnigulova A.Sh., Khudyakova M.V., Dragoy O.V.
Development of tests — Buklina S.B., Zyryanov A.S., Krabis A.V., Stupina E.A., Tolkacheva V.A., Dragoy O.V.
Writing the text — Dmitrova E.P., Gronskaya N.E., Krasilova E.S., Makarova I.V., Minnigulova A.Sh., Tasenko O.A., Untila K.V., Khodzhametova M.I., Khudyakova M.V.
Editing — all co-authors.

No conflict of interests to declare.

REFERENCES

1. Collée E, Vincent A, Visch-Brink E, De Witte E, Dirven C, Satoer D. Localization patterns of speech and language errors during awake brain surgery: a systematic review. *Neurosurgical Review*. 2023;46(1):38. https://doi.org/10.1007/s10143-022-01943-9
2. Duffau H. The onco-functional balance in diffuse gliomas: Evolution of the concept over the past decade — And the next steps. *Brain and Spine*. 2024;5:104170. https://doi.org/10.1016/j.bas.2024.104170
3. Ng S, Rigau V, Moritz-Gasser S, Gozé C, Darlix A, Herbet G, Duffau H. Long-term autonomy, professional activities, cognition, and overall survival after awake functional-based surgery in patients with IDH-mutant grade 2 gliomas: a retrospective cohort study. *The Lancet Regional Health — Europe*. 2024;46:101078. https://doi.org/10.1016/j.lanepe.2024.101078
4. Dmitrova EP, Krasilova ES, Makarova IV, Tasenko OA, Untila KV, Minnigulova ASh, Khudyakova MV, Dragoy OV. Intraoperative speech mapping during awake surgery. *SS Korsakov Journal of Neurology and Psychiatry*. 2025;125(4):35-41. (In Russ.). https://doi.org/10.17116/jnevro202512504135
5. Dragoy O, Chrabaszcz A, Tolkacheva V, Buklina S. Russian Intraoperative Naming Test: a Standardized Tool to Map Noun and Verb Production during Awake Neurosurgeries. *The Russian Journal of Cognitive Science*. 2016;3(4):4-25. https://doi.org/10.47010/16.4.1
6. Alexandratou A, Sefcikova V, Elmalem MS, Bisschop J, Huet SE, Samandouras GA, Nachev P. A probabilistic map of motor and cognitive functions: a meta-analysis of 4325 stimulation sites. *Brain Structure and Function*. 2025;230(9):178. https://doi.org/10.1007/s00429-025-03015-2
7. Piai V, Eikelboom D. Brain Areas Critical for Picture Naming: A Systematic Review and Meta-Analysis of Lesion-Symptom Mapping Studies. *Neurobiology of Language*. 2023;4(2):280-296. https://doi.org/10.1162/nol_a_00097
8. Shtyrov Y, Efremov A, Kuptsova A, Wennekers T, Gutkin B, Garagnani M. Breakdown of category-specific word representations in a brain-constrained neurocomputational model of semantic dementia. *Scientific Reports*. 2023;13(1):19572. https://doi.org/10.1038/s41598-023-41922-8
9. Kocsis Z, Jenison RL, Taylor PN, Calmus RM, McMurray B, Rhone AE, Sarrett ME, Deifelt Streese C, Kikuchi Y, Gander PE, Berger JI, Kovach CK, Choi I, Greenlee JD, Kawasaki H, Cope TE, Griffiths TD, Howard MA 3rd, Petkov CI. Immediate neural impact and incomplete compensation after semantic hub disconnection. *Nature Communications*. 2023;14(1):6264. https://doi.org/10.1038/s41467-023-42088-7
10. Verwoert M, Amigó-Vega J, Gao Y, Ottenhoff MC, Kubben PL, Herff C. Whole-brain dynamics of articulatory, acoustic and semantic speech representations. *Communications Biology*. 2025;8(1):432. https://doi.org/10.1038/s42003-025-07862-x
11. Yu L, Dugan P, Doyle W, Devinsky O, Friedman D, Flinker A. A left-lateralized dorsolateral prefrontal network for naming. *Cell Reports*. 2025; 44(5):115677. https://doi.org/10.1016/j.celrep.2025.115677
12. Bullock L, Forseth KJ, Woolnough O, Rollo PS, Tandon N. Supplementary motor area in speech initiation: A large-scale intracranial EEG evaluation of stereotyped word articulation. *iScience*. 2025;28(1):111531. https://doi.org/10.1016/j.isci.2024.111531
13. Dragoy O, Zyryanov A, Bronov O, Gordeyeva E, Gronskaya N, Kryuchkova, O, Klyuev E, Kopachev D, Medyanik I, Mishnyakova L, Pedyash N, Pronin I, Reutov A, Sitnikov A, Stupina E, Yashin K, Zhirnova V, Zuev A. Functional linguistic specificity of the left frontal aslant tract for spontaneous speech fluency: Evidence from intraoperative language mapping. *Brain and Language*. 2020;208:104836. https://doi.org/10.1016/j.bandl.2020.104836
14. Akinina Y, Malyutina S, Ivanova M, Iskra E, Mannova E, Dragoy O. Russian normative data for 375 action pictures and verbs. *Behavior Research Methods*. 2015;47(3):691-707. https://doi.org/10.3758/s13428-014-0492-9
15. Ivanova MV, Akinina YS, Soloukhina OA, Iskra EV, Buivolova OV, Chrabaszcz AV, Stupina EA, Khudyakova MV, Akhutina TV, Dragoy OV. The Russian Aphasia Test: The first comprehensive, quantitative, standardized, and computerized aphasia language battery in Russian. *PLoS ONE*. 2021;16(11):e0258946. https://doi.org/10.1371/journal.pone.0258946

Received 01.12.2025
Revised 17.04.2026
Accepted 07.05.2026

COMMENT

This article is of particular interest to neurosurgeons treating intracerebral tumors near speech areas. The authors present basic minimum linguistic knowledge a neurosurgeon must possess when evaluating results of speech-related surgeries. Historically, the first simple tests aimed at assessment of automated speech (for example, listing the days of the week or counting) were completely inadequate, as human speech is expressed according to the rules of logical and meaningful utterances. Phonetic testing is also essential for intraoperative survey.

The authors present speech assessment methodology for intraoperative electrophysiological mapping in awake craniotomy. Several targeted tests are selected for various aspects of speech depending on location of lesion. Thus, this approach is personalized for each patient.

Although awake surgery has long been used in English-speaking countries, it is impossible to directly adapt these tests to Russian-speaking population. In this regard, the authors conducted extensive preliminary work to standardize and validate intraoperative tasks in Russian. Pre-, intra- and postoperative testing is clearly described. Importantly, patients experience significant cognitive load while performing intraoperative tasks. This requires efficient use of intraoperative time, minimization of distractions and maintaining patient concentration. The authors implemented a clear and convenient method for presenting tests on a tablet with preset time parameters and audio signal. This allows for effective synchronization of surgeon's actions (touching the brain tissue with stimulator, presenting the task to the patient and communicating the stimulation results to the entire team).

A crucial component of original methodology is preoperative speech assessment. This is valuable for analysis of not only overall speech status but also ability to perform target intraoperative tasks. This aspect is essential for minimizing false-positive results. Thus, this report is a basis for awake surgery workflow and important for neurosurgeons, linguists, and neuropsychologists.

Kopachev D.N. (Moscow)

COMMENT

Significance of this study is determined by clear trend towards preserving the quality of life and minimizing the risk of neurological deterioration in patients with diffuse brain tumors.

The authors describe a battery of tests for preoperative testing and intraoperative speech mapping, present a step-by-step algorithm for selecting speech tests and discuss technical aspects of intraoperative awakening technique with its support by linguists.

Original application for intraoperative speech mapping is a significant contribution to work of neurosurgical team and awake surgery at all.

Reutov A.A. (Moscow)