Burdenko's Journal of Neurosurgery
2026, No. 4, pp. 75–83
https://doi.org/10.17116/neiro20269003175

Rapid ventricular pacing for induced hypotension in clipping of a large aneurysm of vertebrobasilar confluence

© R.S. Dzhindzhikhadze, V.S. Gadzhiagaev, A.V. Polyakov, A.I. Gvelesiani, S.N. Kavadin

Vladimirsky Moscow Regional Research Clinical Institute, Moscow, Russia

ABSTRACT

Background. Despite advances in endovascular technologies, microsurgical clipping is still a relevant treatment for cerebral aneurysms. Blood flow reduction techniques become necessary in some cases (no adequate proximal and distal blood flow control). Rapid ventricular pacing is a new effective technique for controllable hypotension and aneurysm sac relaxation.

Objective. To demonstrate successful rapid ventricular pacing in microsurgical clipping of a large aneurysm of vertebrobasilar confluence in acute period of SAH.

Material and methods. A 64-year-old patient with SAH from vertebrobasilar confluence aneurysm underwent successful microsurgical treatment.

The patient underwent surgery on the second day after hemorrhage. Surgery was performed through a right-sided retrosigmoid approach. Two episodes of rapid ventricular pacing were used to relax the aneurysm and reduce the risk of intraoperative rupture. The effect was achieved almost immediately after initiation with episodes lasting no more than 50 seconds. Controllable hypotension minimized bleeding. There were no postoperative neurological complications. CT angiography showed complete exclusion of aneurysm. The patient was discharged after 10 postoperative days.

Conclusion. Rapid ventricular pacing may be justified in the treatment of complex cerebral aneurysms when surgical blood flow control is difficult. Large-scale studies are needed to develop patient selection algorithms for this surgery.

Keywords: *aneurysm, clipping, rapid ventricular pacing, subarachnoid hemorrhage.*

INFORMATION ABOUT THE AUTHORS:
Dzhindzhikhadze R.S. — https://orcid.org/0000-0003-3283-9524
Gadzhiagaev V.S. — https://orcid.org/0000-0001-7661-4402
Polyakov A.V. — https://orcid.org/0000-0001-7413-1968
Gvelesiani A.I. — https://orcid.org/0009-0002-0027-8582
Kavadin S.N. — https://orcid.org/0009-0004-4043-787X
Corresponding author: Gadzhiagaev V.S. — e-mail: vgadzhiagaev@yandex.ru

TO CITE THIS ARTICLE:
Dzhindzhikhadze RS, Gadzhiagaev VS, Polyakov AV, Gvelesiani AI, Kavadin SN. Rapid ventricular pacing for induced hypotension in clipping of a large aneurysm of vertebrobasilar confluence. *Burdenko's Journal of Neurosurgery*. 2026;90(4):75–83. (In Russ.). https://doi.org/10.17116/neiro20269004175

Introduction

Optimal treatment for cerebral aneurysms is still a pressing issue. Endovascular techniques are preferable worldwide and in Russia. However, these techniques still carry certain risk of partial exclusion, as well as some limitations in acute period of subarachnoid hemorrhage (SAH) and complex aneurysm morphology. Therefore, microsurgical clipping is the primary option for many patients in acute period of SAH [1].

One of the main limitations in microsurgery for vertebrobasilar aneurysms is frequent lack of adequate proximal and distal blood flow control. This increases the risk of intraoperative rupture, uncontrolled bleeding, partial aneurysm exclusion and postoperative complications. This issue is particularly significant for large aneurysms. To overcome these risks, various techniques were proposed: adenosine-induced hypotension [2, 3], hypothermia [4] and combined surgeries in hybrid operating theater [5].

Rapid ventricular pacing (RVP) achieves temporary controllable hypotension via artificial ineffective cardiac output. It is a less common technique, but it was previously described for clipping of various carotid and vertebrobasilar aneurysms in international studies [6—8].

We describe the first case in our country of RVP for microsurgical clipping of large aneurysm of vertebral artery (VA) confluence in acute period of SAH.

A 64-year-old patient presented on the second day after spontaneous SAH. Clinical presentation included moderate impairment of consciousness, headaches and meningeal syndrome (Hunt-Hess grade II, hemorrhage Fisher grade III). CT angiography revealed a large eccentric-fu-

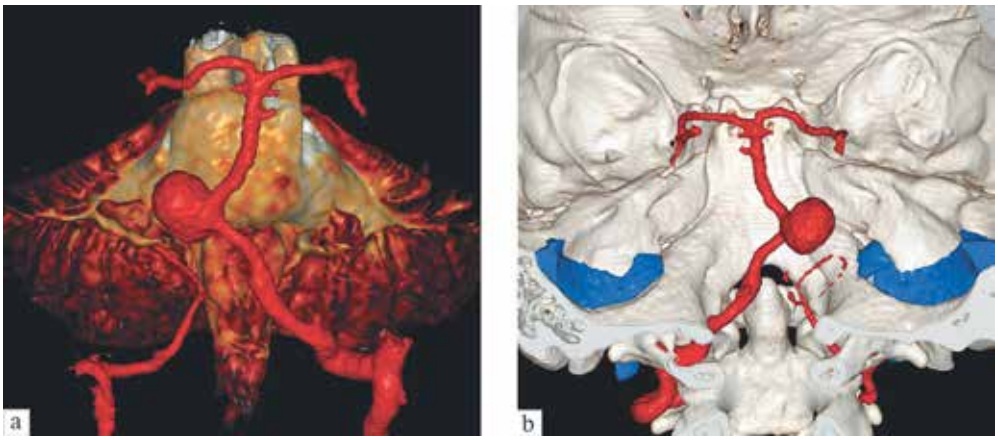

Fig. 1. **Relationship of aneurysm and arteries (red) with cerebellum and brainstem (a, anterior view), as well as skull base and sigmoid sinus (b, posterior view). Segmentation of structures is based on preoperative CT angiography.**

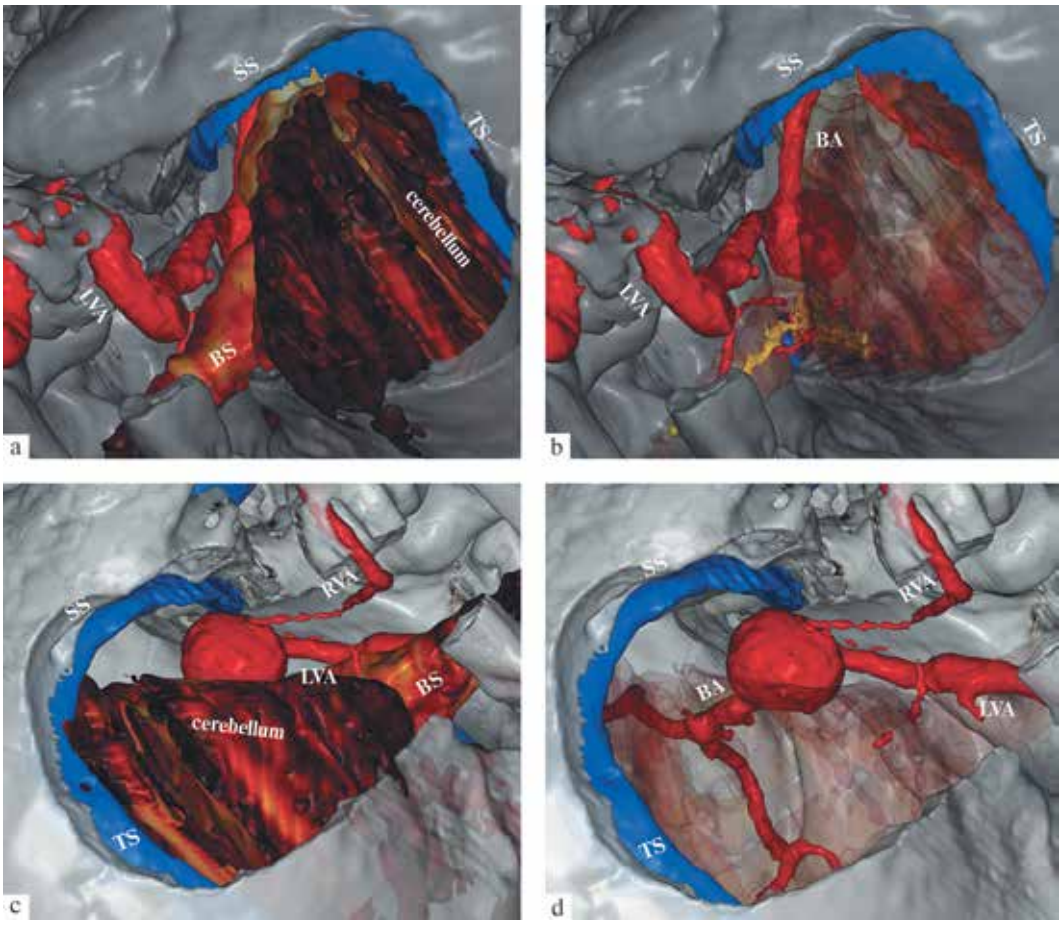

Fig. 2. **Simulation of left-sided (a, b) and right-sided (c, d) retrosigmoid approaches based on preoperative CT angiography. Left-sided approach provides early proximal control, while right-sided approach improves visualization of aneurysm.**
BA — basilar artery; LVA — left vertebral artery; RVA — right vertebral artery; TS — transverse sinus; BS — brainstem; SS — sigmoid sinus.



Fig. 3. **Patient positioning on the operating table and surgical marking.**

siform aneurysm of VA confluence. Angiographic features included smaller size of the right VA, no contrast enhancement distal to the orifice of the right posterior inferior cerebellar artery (PICA) and contralateral deviation of distal segment of the left VA **(Fig. 1)**.

Treatment strategy. The patient was discussed with endovascular surgeons. Non-linear course of the left VA near the aneurysm and impossible aneurysm exclusion without stent (with subsequent dual antiplatelet therapy) made open clipping reasonable. Open surgery implied the following factors. Left-sided retrosigmoid approach can provide early proximal and possibly distal blood flow control, but aneurysm will be obscured by the brainstem and difficult for clipping **(Fig. 2a, b)**. Right-sided approach improves visualization of aneurysm sac, but it is less likely to provide optimal proximal control **(Fig. 2c, d)**. After analysis of advantages and disadvantages of various techniques, we preferred open surgery through right-sided extended retrosigmoid approach with RVP for aneurysm sac relaxation and control of bleeding in case of intraoperative rupture. A 24-hour ECG monitoring and transthoracic echocardiography revealed no cardiac abnormalities.

RVP technique. Surgery was performed under combined endotracheal anesthesia. After intubation, the right internal jugular vein was catheterized with a 6F introducer under ultrasound guidance. A temporary pacemaker electrode was inserted into the right ventricle under ECG guidance. Invasive blood pressure sensor was inserted into the left radial artery. Maximum duration of RVP episodes was 50 seconds. This patient underwent two such episodes. After initiation, target heart rate (HR) and blood pressure were achieved within 1—2 s.

Surgical intervention. We have previously described surgical approach [9]. In the left lateral decubitus position **(Fig. 3)**, we performed a linear soft tissue incision in the right retroauricular region extending to the lateral surface of the neck to visualize lateral parts of posterior arch of C1 vertebra. After visualizing the asterion and occipitomastoid, we performed an extended retrosigmoid craniotomy through two burr holes. Sigmoid and transverse sinuses were exposed laterally and superiorly, respectively. The next step was resection of skull base structures, including foramen magnum edge. We also partially resected posterior arch of C1 vertebra for early visualization of VA, enlargement of surgical corridor, better brain relaxation and lower traction-induced damage.

After arcuate incision of dura mater, we exposed cisterna magna. After transection of dentate ligament, we visualized caudal group of cranial nerves **(Fig. 4a)**. The V4 segment of the right VA and the right PICA were also visualized. Caudal group of cranial nerves was dissected. Finally, we found fresh clots medial to caudal nerves near their entrance into jugular foramen. After aspiration, a large aneurysm was visualized. We mobilized the left VA caudal and ventral to this area for proximal blood flow control **(Fig. 4b)**. Further manipulations without blood flow control were associated with the risk of intraoperative rupture and severe bleeding.

To relax the aneurysm and prevent intraoperative rupture, we applied a temporary clip to the left VA proximal to the aneurysm. Simultaneous RVP resulted in heart rate 250 bpm and mean blood pressure 30—35 mm Hg **(Fig. 5)**. RVP time was 50 s. However, aneurysm dissection was followed by rupture despite relaxation. Bleeding was trivial. After partial exposure of aneurysm dome, we applied two straight clips to the ruptured area **(Fig. 4c, d)**. Short-term period of reperfusion (5 min) was followed by new temporary occlusion of the left VA and the second period of RVP. After final exposure of aneurysm, we repositioned the clips closer to the neck **(Fig. 4e)**. Proximal part of aneurysm neck was clipped with a third clip passed inferiorly from caudal nerves **(Fig. 4f)**. Indocyanine green video-angiography was used for blood flow control in VAs, right PICA, basilar artery and perforator vessels **(Fig. 4g, h)**. RVP scheme is presented in **Fig. 5**.

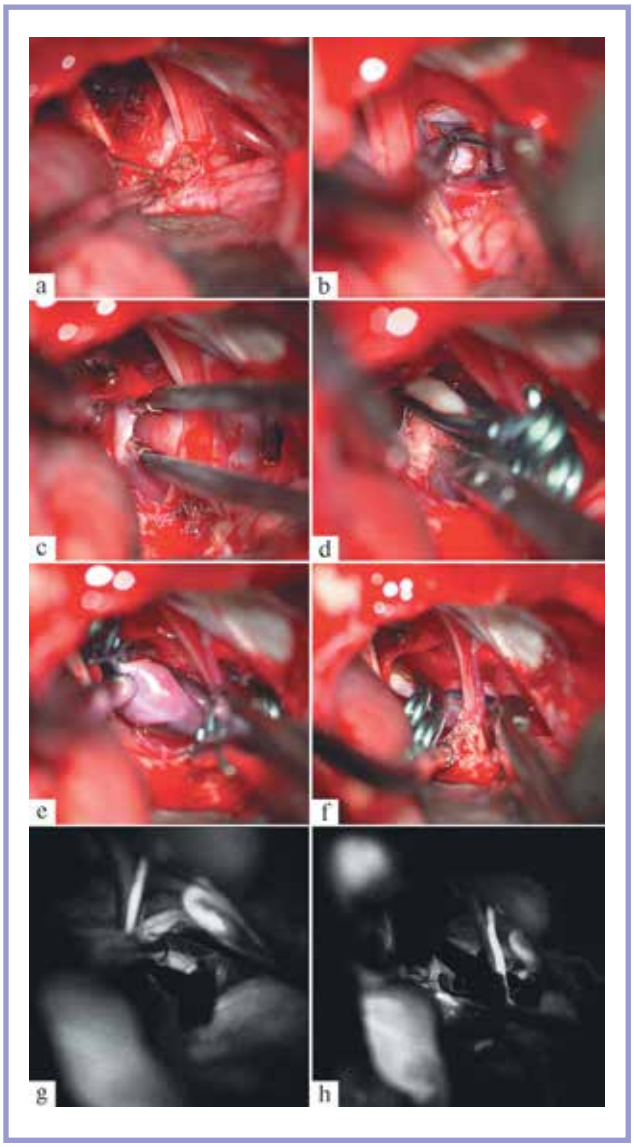

Fig. 4. **Microsurgical procedure.**
a — visualization of aneurysm near caudal nerves, initial stages of dissection; b — proximal control on the left vertebral artery; c — mobilization of aneurysm under RVP and proximal occlusion of the left vertebral artery; d — pilot aneurysm clipping for intraoperative rupture; e — clip repositioning after reperfusion period; f — exclusion of proximal part of aneurysm neck with a third clip; g, h — angiographic control of patent left vertebral artery, basilar artery, right posterior inferior cerebellar artery and perforator vessels.

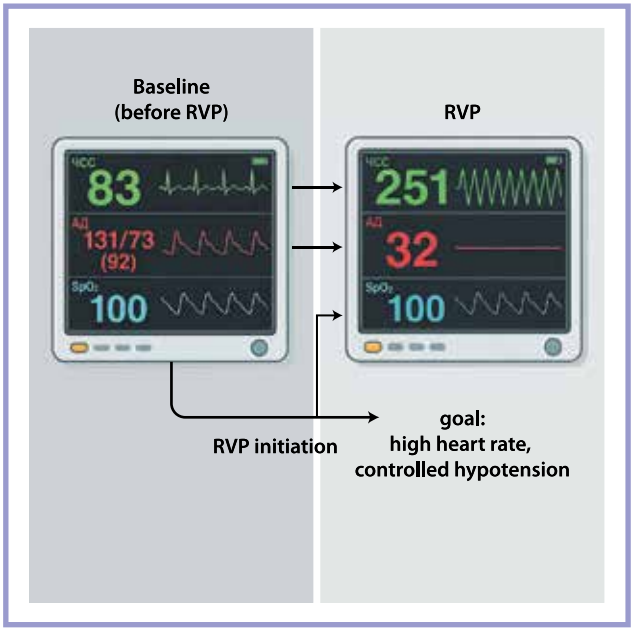

Fig. 5. **Hemodynamic parameters before and during rapid ventricular pacing.**

Subsequent surgical stages were standard. Hemostasis was followed by dura mater closure, fixation of bone flap with titanium cranial fixators and soft tissue suturing.

Postoperative period. Postoperative period was complicated by paroxysmal atrial fibrillation with spontaneous regression after 2—3 hours. A 24-hour monitoring found no abnormalities, and pacemaker was removed the day after surgery.

Postoperative CT found no complications. CT angiography confirmed complete aneurysm exclusion and patent VA, BA and PICA **(Fig. 6)**.

There were postoperative headache and weakness. Transcranial Doppler ultrasound was performed daily after surgery. Electrolyte, blood glucose, hemoglobin, troponin and laboratory parameters for inflammation in blood and lumbar cerebrospinal fluid were also controlled. The patient was discharged on the 10th postoperative day.

Discussion

Treatment of complex cerebral aneurysms, especially in acute phase of SAH, remains a pressing issue in vascular neurosurgery. Endovascular treatment currently demonstrates high efficacy and remains preferable for most vertebrobasilar aneurysms with excellent clinical and angiographic results. However, it still has some limitations, especially in acute period of SAH: 1) dual antiplatelet therapy after stent-assisted interventions and placement of flow-diverting stents increases the risk of hemorrhagic complications (including those following external ventricular drainage, repeated punctures/drainages and other invasive procedures); 2) stents are associated with the risk of thromboembolic complications, including stent thrombosis and occlusion of perforator vessels; 3) no widespread availability of consumables and high-tech implants that can limit the choice of optimal technique; 4) potential technical difficulties following VA tortuosity and complex aneurysm morphology with higher risk of intraoperative dissection / perforation of vessel, partial exclusion, as well as risk of recanalization and necessary repeated interventions in certain options of endovascular treatment. In such rare situations, microsurgical clipping remains relevant as an effective method.

Safe and total microsurgical aneurysm exclusion requires adequate visualization of aneurysm neck, parent

***Table*. Complication rates in various blood flow reduction techniques.**

Complication	Technique		
	RVP	Adenosine	Hypothermia
Myocardial injury, %	0.0	1.1	No data
Heart rhythm disturbances, %	6.4	1.9	No data
Neurological symptoms, %	4.0	14.1	45.5
Mortality, %	0.0	6.5	11.6
Disadvantages	Relatively high risk of tachyarrhythmias	1) dose-dependent effect; 2) less controllable effect; 3) intractable post-procedural hypotension; 4) cross-reactions with other drugs	1) high complication rate (neurological and systemic ones); 2) technical complexity of the procedure
Advantages	1) more controllable effect; 2) effect almost immediately after initiation	Relatively early effect	No advantages

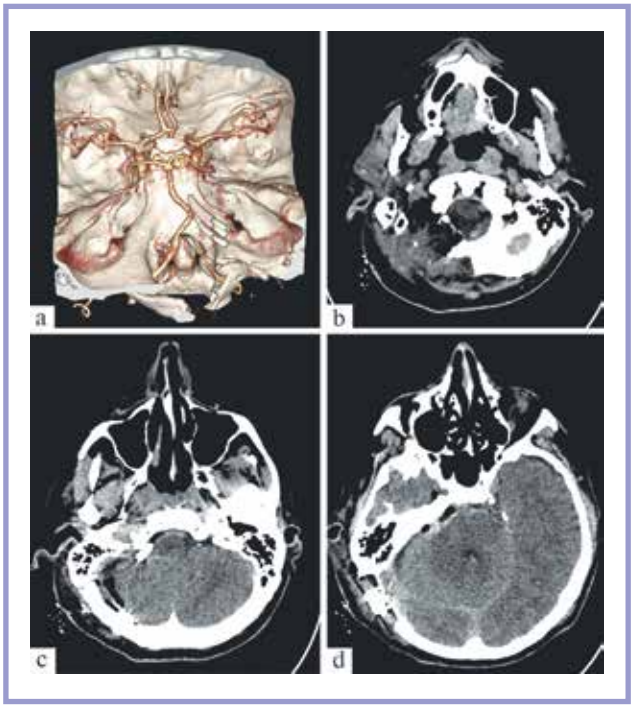

***Fig. 6*. Postoperative CT and CT angiography confirming complete aneurysm exclusion (a) and no ischemic foci in the brainstem at various levels (b—d).**

and perforator arteries, as well as proximal and distal blood flow control. This can be challenging to achieve with large, giant, deep and ruptured aneurysms.

Several intraoperative techniques were proposed in recent decades for controllable arterial hypotension without adequate surgical blood flow control: adenosine-induced hypotension, hypothermia and RVP [2, 4, 8].

Efficacy and safety of RVP. RVP was first used for cerebral aneurysms in 1971, but did not become widespread. It was later used in aortic surgery [10, 11]. The role of RVP in vascular neurosurgery was revised in 2011 [12]. Since then, 6 series of patients with aneurysms (n=131) have been published [7, 8, 12—15]. Intraoperative RVP was used for ruptured aneurysms (33.6%). Many patients had large or giant aneurysms. Grabert J. et al. [7] described mean aneurysm size 19.8±9.1 mm. The most common locations were internal carotid artery (42.0%), middle cerebral artery (32.1%) and anterior communicating artery (17.6%). Vertebrobasilar aneurysms included PICA, anterior inferior cerebellar artery and basilar artery bifurcation.

RVP carries the risk of myocardial injury and indirect risks of complications (primarily neurological) associated with systemic hypotension. The incidence of myocardial injury in available series was extremely low (increased serum troponin and ECG signs of myocardial ischemia in two studies) [14, 15]. In all cases, surgeries were performed in acute period of SAH, and it was not possible to associate these changes exclusively with RVP. Some patients experienced paroxysms of atrial fibrillation and ventricular tachycardia after RVP. These disorders regressed within 24 hours after surgery. The pooled incidence of neurological disorders was 4.0%. They were transient, and brain CT found no ischemic changes associated with RVP in any patient. In all studies, the authors noted high efficiency of RVP in aneurysm clipping. There were 8 RVP episodes per a patient (range 5—14). Effects were almost immediate after initiation. Significant aneurysm relaxation prevented intraoperative rupture or reduced severity of bleeding. RVP-assisted aneurysm exclusion rate reached 100% (mean 92.0%).

Alternative methods for blood flow reduction: hypothermia and adenosine-induced hypotension. Deep hypothermia (<15°C) has long been used to stop blood flow in cerebral aneurysms [16]. However, this approach is not widespread in recent years due to high risk of complications. Postoperative neurological deficit can occur in 45.5% of patients, and damage to other organs and systems is also possible.

In 1999, Groff M.W. et al. [17] first described adenosine-induced hypotension for aneurysm clipping, and appropriate reports on this issue have also appeared in recent years [2, 3]. Limiting factors of this method are the risk of intraoperative myocardial infarction (1.1% in the largest series) and postoperative neurological disorders (14.1%). Disadvantages of adenosine also include dose-dependent

effect, contraindications in patients with allergies and risk of treatment-resistant hypotension. Comparison of blood flow reduction techniques is presented in **Table.**

RVP in modern vascular neurosurgery. The role of RVP in neurosurgery is not limited to aneurysms. Indeed, this technique may be effective for resection of arteriovenous malformations and tumors with abundant blood supply and high risk of intraoperative bleeding.

Naturally, RVP cannot be routine. This technique is not without risks and requires patient preparation and appropriate surgical team. The primary method of intraoperative blood flow control is still temporary occlusion of afferent and efferent arteries. In our opinion, blood flow reduction techniques, including RVP, can only be used when proximal control is impossible at early stages of dissection.

A limitation of this study is its design (case report). Nevertheless, we present the first successful RVP in a patient with complex cerebral aneurysm in our country. This technique demonstrates high efficacy, reproducibility and low risk of complications.

Conclusion

Rapid ventricular pacing is an effective and relatively safe method for blood flow reduction. This procedure may be reasonable for complex cerebral aneurysms when surgical blood flow control (temporary proximal and distal clipping) is impossible. Large-scale studies are needed to develop the algorithms for selecting patients for surgeries under rapid ventricular pacing.

Author contribution:
Concept and design of the study — Dzhindzhikhadze R.S.
Collection and analysis of data — Gadzhiagaev V.S.
Writing the text — Dzhindzhikhadze R.S., Gadzhiagaev V.S.
Editing — Dzhindzhikhadze R.S., Gadzhiagaev V.S., Polyakov A.V., Gvelesiani A.I., Kavadin S.N.

No conflict of interests to declare.

REFERENCES

1. Zhu W, Ling X, Petersen JD, Liu J, Xiao A, Huang J. Clipping versus coiling for aneurysmal subarachnoid hemorrhage: a systematic review and meta-analysis of prospective studies. *Neurosurgical Review.* 2022;45(2):1291-1302. https://doi.org/10.1007/s10143-021-01704-0
2. Intarakhao P, Thiarawat P, Rezai Jahromi B, Kozyrev DA, Teo MK, Choque-Velasquez J, Luostarinen T, Hernesniemi J. Adenosine-induced cardiac arrest as an alternative to temporary clipping during intracranial aneurysm surgery. *Journal of Neurosurgery.* 2018;129(3):684-690. https://doi.org/10.3171/2017.5.JNS162469
3. Al-Mousa A, Bose G, Hunt K, Toma AK. Adenosine-assisted neurovascular surgery: initial case series and review of literature. *Neurosurgical Review.* 2019;42(1):15-22. https://doi.org/10.1007/s10143-017-0883-3
4. Schebesch KM, Proescholdt M, Ullrich OW, Camboni D, Moritz S, Wiesenack C, Brawanski A. Circulatory arrest and deep hypothermia for the treatment of complex intracranial aneurysms--results from a single European center. *Acta Neurochirurgica.* 2010;152(5):783-792. https://doi.org/10.1007/s00701-009-0594-9
5. Gmeiner M, Mazanec V, Sonnberger M, Gruber A. Experiences with and Practical Implications of Using a Hybrid Operating Room. *Acta Neurochirurgica Supplement.* 2025;136:153-156. https://doi.org/10.1007/978-3-031-89844-0_19
6. Henson JC, Rennert RC, Budohoski KP, Couldwell WT. Unstable ventricular tachycardia requiring defibrillation from rapid ventricular pacing during basilar apex aneurysm clipping. *Acta Neurochirurgica.* 2022;164(2):537-541. https://doi.org/10.1007/s00701-022-05125-w
7. Grabert J, Huber-Petersen S, Lampmann T, Eichhorn L, Vatter H, Coburn M, Velten M, Güresir E. Rapid Ventricular Pacing as a Safe Procedure for Clipping of Complex Ruptured and Unruptured Intracranial Aneurysms. *Journal of Clinical Medicine.* 2021;10(22):5406. https://doi.org/10.3390/jcm10225406
8. Wach J, Vychopen M, Weber F, Arlt F, Güresir E. Rapid ventricular pacing in cerebral aneurysm clipping: institutional workflow, systematic review, and single-arm meta-analysis. *Neurosurgical Review.* 2025;48(1):501. https://doi.org/10.1007/s10143-025-03668-x
9. Dzhindzhikhadze RS, Lazarev VA, Kambiev RL, Polyakov AV, Bogdanovich IO, Dreval ON, Ermolaev AYu, Chekhonatskiy VA. Extended retrosigmoid retrocondylar access in microsurgery of posterior inferior cerebellar artery aneurysms in the acute period of hemorrhage (clinical case). *Saratov Journal of Medical Scientific Research.* 2022;18(2):197-201 (In Russ.).
10. Rovit RL. Operative hypotension for intracranial vascular surgery using pacemaker-induced ventricular tachycardia. *Journal of Neurosurgery.* 1971;35(1):51-58. https://doi.org/10.3171/jns.1971.35.1.0051
11. Kahn RA, Marin ML, Hollier L, Parsons R, Griepp R. Induction of ventricular fibrillation to facilitate endovascular stent graft repair of thoracic aortic aneurysms. *Anesthesiology.* 1998;88(2):534-536. https://doi.org/10.1097/00000542-199802000-00036
12. Saldien V, Menovsky T, Rommens M, Van der Steen G, Van Loock K, Vermeersch G, Mott C, Bosmans J, De Ridder D, Maas AI. Rapid ventricular pacing for flow arrest during cerebrovascular surgery: revival of an old concept. *Neurosurgery.* 2012;70(2 Suppl Operative):270-275. https://doi.org/10.1227/NEU.0b013e318236d84a
13. Konczalla J, Platz J, Fichtlscherer S, Mutlak H, Strouhal U, Seifert V. Rapid ventricular pacing for clip reconstruction of complex unruptured intracranial aneurysms: results of an interdisciplinary prospective trial. *Journal of Neurosurgery.* 2018;128(6):1741-1752. https://doi.org/10.3171/2016.11.JNS161420
14. Saldien V, Schepens T, Van Loock K, Vermeersch G, Wildemeersch D, Van Hoof V, De Belder F, Bosmans J, Vercauteren M, Menovsky T. Rapid Ventricular Pacing for Neurovascular Surgery: A Study on Cardiac and Cerebral Effects. *World Neurosurgery.* 2018;119:e71-e77. https://doi.org/10.1016/j.wneu.2018.07.002
15. Ragulojan M, Krolczyk G, Al Aufi S, Wang AP, McIsaac DI, Hicks S, Sinclair J, Budiansky AS. Rapid Ventricular Pacing for Clipping of Intracranial Aneurysms: A Single-centre Retrospective Case Series. *Journal of Neurosurgical Anesthesiology.* 2025;37(3):288-295. https://doi.org/10.1097/ANA.0000000000000988
16. Uihlein A, Terry HR Jr, Payne WS, Kirklin JW. Operations on intracranial aneurysms with induced hypothermia below 15 degrees C. and total circulatory arrest. *Journal of Neurosurgery.* 1962;19:237-239. https://doi.org/10.3171/jns.1962.19.3.0237
17. Groff MW, Adams DC, Kahn RA, Kumbar UM, Yang BY, Bederson JB. Adenosine-induced transient asystole for management of a basilar artery aneurysm. Case report. *Journal of Neurosurgery.* 1999;91(4):687-690. https://doi.org/10.3171/jns.1999.91.4.0687

Received 30.12.2025
Revised 27.02.2026
Accepted 07.05.2026

COMMENT

Over the past 30 years, neurosurgical community has recognized the priority of endovascular techniques for vertebrobasilar aneurysms, including those in acute period of SAH. The authors describe open surgery for proximal basilar artery aneurysm in acute period of SAH in a 64-year-old patient. Rapid ventricular pacing was used to control systemic arterial pressure during aneurysm clipping. The authors emphasize high efficacy, reproducibility and low risk of complications. However, aneurysm clipping was accompanied by intraoperative rupture under artificial hypotension that exposed the patient to high risk of adverse outcome. Postoperative episode of atrial fibrillation should also be considered a complication. Furthermore, preoperative cardiac examination with a 24-hour ECG monitoring was necessary to rule out cardiac abnormalities. Does the patient have time for such an examination in acute period of SAH? Meanwhile, endovascular procedure is possible immediately upon admission. In describing such anatomical parameters of aneurysm and vertebrobasilar arteries as size and wide neck of aneurysm, vertebral artery tortuosity and hypoplasia of the V4 segment of the right vertebral artery distal to posterior inferior cerebellar artery, the authors erroneously state contraindications to endovascular treatment for this aneurysm. Such situations are common in vertebrobasilar anatomy and do not pose any significant obstacles to modern endovascular technologies. Endovascular aneurysm repair in this case could be performed according to the following scenarios:

1. Partial or subtotal occlusion of aneurysm with microcoils with or without balloon assistance immediately upon admission followed by stent-assisted total aneurysm occlusion with coils in cold period.
2. Stent-assisted aneurysm occlusion with coils in acute period of SAH using intraoperative therapeutic support.
3. Implantation of flow-diverting stent at the level of partially occluded aneurysm (point 1) in cold period.

These procedures are not unique. They are described in Russian and international literature and widely used in clinical practice. Furthermore, endovascular administration of calcium channel blockers in acute period of SAH allows for active treatment of cerebral vasospasm after potential recurrent SAH. Thus, endovascular treatment is a minimally invasive and effective method for treating vertebrobasilar aneurysms, including acute phase of rupture, with minimal risk of complications and various options for a personalized approach. The authors presented a casuistic case. Despite postoperative outcome, this technique cannot be routinely recommended in clinical practice.

Yakovlev S.B. (Moscow)

COMMENT

Rapid ventricular pacing was developed for cardiology in the 1970s as a method for terminating ventricular tachycardia. This technique implies controllable transient hypotension through high-frequency ventricular stimulation reducing cardiac output.

The first case of RVP in cerebral aneurysm surgery was published in 1971 [1]. The next report appeared only in 2012 [2]. In total, there are 7 reports (including this manuscript) describing treatment outcomes in 167 patients with cerebral aneurysms. Analysis of these data suggests safety of technique. However, these studies do not discuss complications following treatment of cardiac patients.

RVP-associated complications may be divided into mechanical/procedural ones related to placement and manipulation with lead, acute cardiac complications arising during or immediately after stimulation, adverse events related to vascular access, arrhythmic complications and several others.

Mechanical / procedural complications. A prospective study included 641 patients with temporary lead placement. Cardiac perforation occurred in 9.2% of patients. This complication can occur immediately after lead implantation, before, or after its removal [3]. Analysis of national US database (360.223 patients with temporary transvenous pacemakers) found that pericardial tamponade occurred in 0.6%, pneumothorax in 0.9%, and non-pericardial bleeding in 2.4% of cases. Pericardial tamponade was associated with a fivefold increase in the risk of in-hospital mortality.

Arrhythmia. The authors discussed arrhythmias. The incidence of arrhythmias following RVP is 6.4%. Wach J. et al. [4] reported a lower value (4.0%). However, Konczalla J. et al. [5] described intraoperative arrhythmia in 9.5% of cases (21 patients with unruptured aneurysm). The authors attributed this complication to RVP time (120 s). These complications did not arise after adjusting the protocol and shorter duration of ventricular pacing (100 s). Is this time sufficient in case of intraoperative aneurysm rupture? What should be done if it is not? Should RVP be continued with high risk of fatal arrhythmia? These issues require discussion. The question arises regarding heart rate. Why did the authors choose 250 bpm? In available reports, maximum heart rate was 220 bpm (mean 187.4) [4]. Explanation of this heart rate could provide important information for cardiologists and anesthesiologists and would increase practical value of the article.

Complications associated with electrode placement and manipulation. In the aforementioned report by Konczalla J. et al. [5], lead dislocation occurred in 19% of cases. This made RVP impossible and changed surgical strategy in 2 out of 3 cases (placement of flow-diverting stent; surgery under temporary arterial clipping). Description of such technical features is extremely important for neurosurgeon and anesthesiologist.

Conclusion

RVP in cerebral aneurysm surgery is described in international literature as case reports and small case series. Advisability of this method is limited to vertebrobasilar aneurysms in acute period of SAH when endovascular treatment is impossible. At present, there is no alternative to endovascular repair for basilar artery aneurysm. Regarding optimal method or combination of surgical methods for cerebral aneurysms, appropriate experience based on many thousands of patients at the Burdenko Neurosurgery Center was previously published in the journal «Problems of Neurosurgery» [6, 7].

RVP posing no less of a risk than direct microsurgical clipping of vertebrobasilar aneurysms cannot be recommended as an alternative to endovascular occlusion in neurosurgical practice.

Eliava Sh.Sh., Grebenev F.V. (Moscow)

REFERENCES

1. Rovit RL. Operative hypotension for intracranial vascular surgery using pacemaker-induced ventricular tachycardia. *Journal of Neurosurgery.* 1971;35(1):51-58. https://doi.org/10.3171/jns.1971.35.1.0051
2. Saldien V, Menovsky T, Rommens M, Van der Steen G, Van Loock K, Vermeersch G, Mott C, Bosmans J, De Ridder D, Maas AI. Rapid ventricular pacing for flow arrest during cerebrovascular surgery: revival of an old concept. *Neurosurgery.* 2012;70(2 Suppl Operative):270-275. https://doi.org/10.1227/NEU.0b013e318236d84a
3. Dwivedi SK, Sharma A, Chaudhary G, Chandra S, Bhandari M, Vishwakarma P, Pradhan A, Sethi R, Shukla A, Singh A, Sharma P, Tripathi U, Jain N. Incidence and predictors of temporary pacemaker implantation-induced cardiac perforation. *Heart Rhythm.* 2025;22(10):e1000-e1006. https://doi.org/10.1016/j.hrthm.2025.06.044
4. Wach J, Vychopen M, Weber F, Arlt F, Güresir E. Rapid ventricular pacing in cerebral aneurysm clipping: institutional workflow, systematic review, and single-arm meta-analysis. *Neurosurgical Review.* 2025;48(1):501. https://doi.org/10.1007/s10143-025-03668-x
5. Konczalla J, Platz J, Fichtlscherer S, Mutlak H, Strouhal U, Seifert V. Rapid ventricular pacing for clip reconstruction of complex unruptured intracranial aneurysms: results of an interdisciplinary prospective trial. *Journal of Neurosurgery.* 2018;128(6):1741-1752. https://doi.org/10.3171/2016.11.JNS161420
6. Éliava ShSh, Yakovlev SB, Shekhtman OD, Pilipenko IuV, Kheireddin AS, Konovalov AnN, Arustamian SR, Bocharov AV, Bukharin EIu, Okishev DN, Mikeladze KG, Tabasaranskiĭ TF, Kurdyumova NV. Principles of surgical treatment for patients with asymptomatic aneurysms and cerebral aneurysms in the cold period after spontaneous intracranial hemorrhages. *Burdenko's Journal of Neurosurgery.* 2018;82(4):8-14. (In Russ., In Engl.) https://doi.org/10.17116/neiro20188248
7. Éliava ShSh, Yakovlev SB, Belousova OB, Pilipenko IuV, Kheireddin AS, Shekhtman OD, Okishev DN, Konovalov AnN, Mikeladze KG, Arustamian SR, Bocharov AV, Bukharin EIu, Kurdyumova NV, Tabasaranskiĭ TF. The principles for choosing a surgical technique for patients with acute cerebral aneurysm rupture. *Burdenko's Journal of Neurosurgery.* 2016;80(5):15-21. (In Russ., In Engl.) https://doi.org/10.17116/neiro201680515-21

COMMENT

The authors comprehensively described successful open surgical treatment of a patient with basilar artery aneurysm in acute period of SAH.

As we know, winners are not judged, and I sincerely congratulate the authors with favorable treatment outcome. I could probably end here, but my role as a commentator prevents me from taking such a simple approach. So I decided to share with readers some questions and concerns.

I will begin with surgical intervention. As far as I know, endovascular surgery is undoubtedly dominant for basilar artery aneurysms. Appropriate advantages were repeatedly confirmed [1—7]. The authors' concern on high risk of hemorrhagic complications associated with dual antiplatelet therapy after stenting seems unconvincing to me [8].

Regarding the essence of the study, it is simple. RVP with a pacemaker was used to reduce pressure in aneurysm cavity. This raised some questions.

1. Was the patient examined by cardiologists prior to surgery, and what were the results of this examination (ECG, echocardiography, cardiac enzymes)? I don't think this is an idle question. Firstly, the patient could well have had underlying cardiovascular disease (age 64 years). Secondly, aneurysmal SAH is a severe cerebral catastrophe. However, it is often accompanied by selective myocardial damage, even leading to phenomenon of myocardial stunning [9—17].
2. Who implanted the pacemaker, and when? I hope these were certified cardiologists, not anesthesiologists, who have their own problems.
3. Perhaps, it would make sense to describe methodological aspects of pacing in more detail: pacemaker type, pacing mode and other «useful details» for those who decide to use this procedure.
4. Induced severe tachycardia is a priori a serious stress not only for myocardium but also the body as a whole.

As far as I recall, one of the «ancient» reports on this technique pointed out, in particular, phenomenon of extreme hyperglycemia. The last one is an unfavorable background for any ischemia (myocardial and cerebral).

5. In this regard, did the authors consider background pharmacological neurovegetative stabilization, for example, with ganglionic blockers or other drugs?
6. In discussion, the authors rightly consider various alternative methods for reducing pressure in aneurysm cavity and unfairly omit two others: temporary balloon occlusion of the parent vessel [18] and controlled arterial hypotension. The latter is not very suitable for patients undergoing surgery in acute period of SAH due to phenomenon of impaired cerebral blood flow autoregulation, but it is quite effective in cold period [19, 20].
7. As for deep hypothermia (more correctly called deep hypothermic circulatory arrest), this approach really poses a risk of serious problems with hemostasis simply because this technique involves circulatory arrest, cardiopulmonary bypass and anticoagulation with heparin [18].

Conclusion. This report is interesting and deserves publication in our journal.

Lubnin A. Yu. (Moscow)

REFERENCES

1. Usachev DYu, Eliava ShSh, Yakovlev SB, Belousova OB. eds. *Neurosurgery. National Guidelines. Vol. III. Vascular Neurosurgery.* M.: Burdenko Neurosurgical Center; 2023. (In Russ.).
2. Bi Y, Song X, Chen X, Tian Y, Ji W, Yang Z, Chen X, Zhou J. Endovascular treatment of ruptured basilar artery trunk aneurysms: complications and long-term outcomes. *Journal of Stroke and Cerebrovascular Diseases.* 2024;33(11):107957. https://doi.org/10.1016/j.jstrokecerebrovasdis.2024.107957
3. Srinivasan VM, Singh R, Karahalios K, Scherschinski L, Essibayi MA, Catapano JS, Winkler EA, Jadhav AP, Ducruet AF, Albuquerque FC. Endovascular Embolization of Basilar Artery Fenestration Aneurysms: A 21-Year Institutional Case Series. *Operative Neurosurgery.* 2023;25(6):521-528. https://doi.org/10.1227/ons.0000000000000882
4. Styczen H, Fischer S, Gawlitza M, Meyer L, Goertz L, Maurer C, Alexandrou M, Khanafer A, Lobsien D, Deuschl C, Klisch J, Kabbasch C, Fiehler J, Berlis A, Papanagiotou P, Henkes H, Maus V. Reconstructive endovascular treatment of basilar artery fenestration aneurysms: A multi-centre experience and literature review. *The Neuroradiology Journal.* 2022;35(3):319-328. https://doi.org/10.1177/19714009211042877
5. Yu J. Current research status and future of endovascular treatment for basilar artery aneurysms. *The Neuroradiology Journal.* 2024;37(5):571-586. https://doi.org/10.1177/19714009241242584
6. Zhang M, Gao K, Wu X, Wang X, Wang Z, Tong X. Open surgical treatment of basilar artery aneurysms in the interventional therapy era. *Acta Neurochirurgica.* 2024;166(1):275. https://doi.org/10.1007/s00701-024-06153-4
7. Jiang Z, Yang H, Gao X, Gao C, Jiang H, Xu L, Lei Y, Su J, Zhang X, Gu Y, Ni W. Endovascular Management of Basilar Artery Aneurysms: A Consecutive Series of 124 Patients. *World Neurosurgery.* 2024;191:e32-e40. https://doi.org/10.1016/j.wneu.2024.07.174
8. Edwards NJ, Jones WH, Sanzgiri A, Corona J, Dannenbaum M, Chen PR. Antiplatelet therapy for the prevention of peri-coiling thromboembolism in high-risk patients with ruptured intracranial aneurysms. *Journal of Neurosurgery.* 2017;127(6):1326-1332. https://doi.org/10.3171/2016.9.JNS161340
9. Ahmadian A, Mizzi A, Banasiak M, Downes K, Camporesi EM, Thompson Sullebarger J, Vasan R, Mangar D, van Loveren HR, Agazzi S. Cardiac manifestations of subarachnoid hemorrhage. *Heart, Lung and Vessels.* 2013;5(3):168-178.
10. Kim YW, Neal D, Hoh BL. Risk factors, incidence, and effect of cardiac failure and myocardial infarction in aneurysmal subarachnoid hemorrhage patients. *Neurosurgery.* 2013;73(3):450-7; quiz 457. https://doi.org/10.1227/NEU.0000000000000001
11. King C. Listening to the head and not the heart: subarachnoid haemorrhage associated with severe acute left ventricular failure. *BMJ Case Reports.* 2013;2013:bcr2013009877. https://doi.org/10.1136/bcr-2013-009877
12. Lwin TS, Mitrakrishnan RN, Farooq M, Alama M. ST-segment elevation myocardial infarction with normal coronary arteries secondary to anterior communicating cerebral artery aneurysmal rupture: a case report. *European Heart Journal — Case Reports.* 2021;5(5):ytab168. https://doi.org/10.1093/ehjcr/ytab168
13. Mustafa A, Hitt N, Smirlis E, Koranne K. ST Depression in the Setting of Subarachnoid Hemorrhage. *Cureus.* 2021;13(10):e19030. https://doi.org/10.7759/cureus.19030
14. Parr MJ, Finfer SR, Morgan MK. Reversible cardiogenic shock complicating subarachnoid haemorrhage. *BMJ.* 1996;313(7058):681-683. https://doi.org/10.1136/bmj.313.7058.681
15. Pinnamaneni S, Aronow WS, Frishman WH. Neurocardiac Injury After Cerebral and Subarachnoid Hemorrhages. *Cardiology in Review.* 2017;25(2):89-95. https://doi.org/10.1097/CRD.0000000000000112
16. Shimada M, Rose JD. Takotsubo cardiomyopathy secondary to intracranial hemorrhage. *Intercontinental Journal of Emergency Medicine.* 2014;7:33. https://doi.org/10.1186/s12245-014-0033-4
17. van der Velden LB, Otterspoor LC, Schultze Kool LJ, Biessels GJ, Verheugt FW. Acute myocardial infarction complicating subarachnoid haemorrhage. *Netherlands Heart Journal.* 2009;17(7-8):284-287. https://doi.org/10.1007/BF03086267
18. Budiansky AS, Polis T, Ma K. Temporary Intraoperative Cerebral Blood Flow Reduction to Facilitate Neurovascular Procedures. *Journal of Neurosurgical Anesthesiology.* 2025;37(4):335-340. https://doi.org/10.1097/ANA.0000000000001046
19. Kundra S, Mahendru V, Gupta V, Choudhary AK. Principles of neuroanesthesia in aneurysmal subarachnoid hemorrhage. *Journal of Anaesthesiology Clinical Pharmacology.* 2014;30(3):328-337. https://doi.org/10.4103/0970-9185.137261
20. Soghomonyan S, Stoicea N, Sandhu GS, Pasternak JJ, Bergese SD. The Role of Permissive and Induced Hypotension in Current Neuroanesthesia Practice. *Frontiers in Surgery.* 2017;4:1. https://doi.org/10.3389/fsurg.2017.00001