Burdenko's Journal of Neurosurgery
2026, No. 4, pp. 67–72
https://doi.org/10.17116/neiro20269003167

Atypical course of cutaneous schwannoma: a case report and literature review

© A.G. Fedyakov[1, 2], A.V. Gorozhanin[1, 2], Z.Kh. Plieva[2], E.I. Zakurdaev[1], Yu.A. Kozlova[1, 2], I.M. Silaev[1], M.S. Polichuk[1]

[1]Botkin Hospital, Moscow, Russia;
[2]Russian Medical Academy of Continuous Professional Education, Moscow, Russia

ABSTRACT

Background. Schwannomas are benign (WHO Grade I) tumors of peripheral nerves arising from Schwann cells. Discrepancies between biological behavior and histological characteristics of tumor may exist. We consider it appropriate to describe such a case and compare it with literature data.

Material and methods. A patient with subcutaneous schwannoma of the lower third of the right leg complicated by skin ulceration is presented. A review is devoted to data on atypical clinical course of schwannomas.

Results and discussion. A 55-year-old man presented with tumor in the lower third of the right leg and skin ulceration 3.5×3 cm. The tumor appeared 10 months ago and significantly enlarged. Open biopsy revealed WHO Grade 1 schwannoma. Atypical course of disease required an extended resection of tumor and simultaneous skin defect closure with split-thickness thigh skin flap. Two months after surgery, the wound healed via primary intention. There were no signs of tumor recurrence, and Karnofsky score was 100.

Conclusion. Atypical course of cutaneous schwannoma with ulcers complicates accurate and timely diagnosis, as well as complicates patient management, selection of primary specialist and surgical approach. Benign tumor verified by biopsy and clinical manifestations typical for soft tissue cancer can require early surgical intervention based on oncological principles.

Keywords: *schwannoma, benign peripheral nerve tumors, malignant skin tumors, sarcoma, squamous cell carcinoma.*

INFORMATION ABOUT THE AUTHORS:
Fedyakov A.G. — https://orcid.org/0000-0002-8807-3874
Gorozhanin A.V. — https://orcid.org/0000-0002-3593-7034
Plieva Z.Kh. — https://orcid.org/0000-0003-1297-1616
Zakurdaev E.I. — https://orcid.org/0000-0001-8613-9609
Kozlova Yu.A. — https://orcid.org/0000-0002-8026-5919
Silaev I.M. — https://orcid.org/0009-0001-3798-2998
Polichuk M.S. — https://orcid.org/0009-0005-2339-2152
Corresponding author: Fedyakov A.G. — e-mail: fedart@bk.ru

TO CITE THIS ARTICLE:
Fedyakov AG, Gorozhanin AV, Plieva ZKh, Zakurdaev EI, Kozlova YuA, Silaev IM, Polichuk MS. Atypical course of cutaneous schwannoma: a case report and literature review. *Burdenko's Journal of Neurosurgery*. 2026;90(4):67–72. (In Russ.). https://doi.org/10.17116/neiro20269004167

Introduction

Schwannomas are benign (WHO Grade I) tumors of the peripheral nerves arising from Schwann cells. They are usually isolated, slow-growing and encapsulated solitary tumors, except for patients with manifestations of schwannomatosis or neurofibromatosis type 1 [1]. Over 90% of schwannomas are sporadic and affect the peripheral nerves of the trunk and extremities. Annual incidence is low (0.6 per 100.000 people) [2, 3]. Sporadic peripheral schwannomas are not gender-specific and can occur at any age (most often between 40 and 60 years). There are several histological variants of schwannomas without differences in clinical manifestations or patient age at onset [2]. Malignant transformation of schwannomas is extremely rare. Only several cases of schwannoma degeneration into malignant peripheral nerve sheath tumors (MPNST) were described. Rapid tumor growth and severe pain are clinical predictors of malignant tumor transformation [4].

A discrepancy between biological behavior and histological characteristics of tumor is possible. In some, albeit rare, cases, benign schwannomas rapidly enlarge and demonstrate invasive growth into surrounding tissues. Relatively slow-growing MPNSTs are also encountered. Such situations represent complex cases associated with issues of ICD-10 coding, selection of a specialist for patient care and optimal treatment strategy.

The purpose of this study is to describe a patient with subcutaneous schwannoma of the lower third of the right leg and skin ulceration.

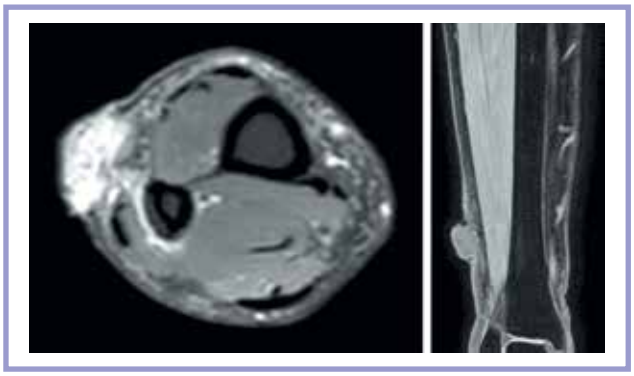

Fig. 1. **Appearance of tumor.**



Fig. 2. **Magnetic resonance imaging (MRI) of soft tissues of the right leg, PDW and mDIXON-W sequences.**

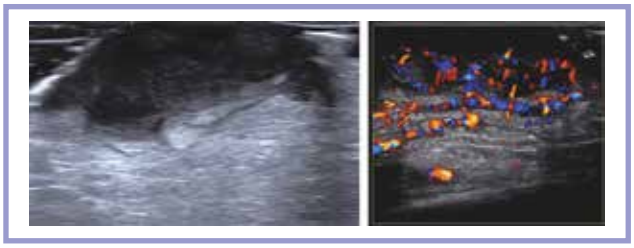

Fig. 3. **Doppler ultrasound of tumor.**

Results

In December 2025, a 55-year-old patient presented with complaints of tumor of the lower third of the right leg with bleeding. For approximately 15 years, the patient had subcutaneous mass on anterolateral surface of the lower third of the right leg with gradual enlargement. In February 2025, he first consulted a dermatologist. A non-pigmented, non-melanocytic, dome-shaped nodule up to 5 cm in diameter with central ulceration and suppuration was found. Squamous cell/basal cell carcinoma of skin was suspected that required ultrasound-guided biopsy. In March 2025, ultrasound revealed hypoechoic mass 38×24×32 mm with heterogeneous structure composed of anechoic fluid inclusions with clear, smooth margins. Doppler ultrasound demonstrated active peri- and intranodular blood flow that suggested lymphangioma. A core biopsy from the center of the nodule revealed schwannoma (immunohistochemical study was not performed), ICD-10 code D36.1 (benign neoplasm). Follow-up was recommended.

Subsequently, the patient noted tumor enlargement and prolapse through skin defect. The patient consulted a purulent surgeon. The last one suspected trophic ulcer of the leg/soft tissue malignant neoplasm and considered biopsy data to be inaccurate. Surgeon referred the patient for MRI with subsequent oncologist consultation.

In October 2025, MRI of the right leg without contrast enhancement (due to previous polyvalent allergies and atopic dermatitis) revealed a mass 17.5×29.6×28 mm in subcutaneous fat with heterogeneous structure and clear contours. No enlarged lymph nodes or bone destruction were detected at this level **(Fig. 1)**.

In December 2025, the patient consulted at the Botkin Hospital, and he was referred to neurosurgeon.

Upon examination, the neurosurgeon discovered a 3.5×3 cm skin defect in the lower third of the right leg. This defect contained a dense tumor mass covered with fibrinous coating. Bleeding followed any mechanical stress. Skin edges around defect were thickened into a 0.5 cm wide «ridge» with signs of inflammation (edema, hyperemia) **(Fig. 2)**. An expert-level ultrasound and redo biopsy with immunohistochemical examination were prescribed.

Ultrasound revealed oval hypoechoic lesion 3.13×1.2×2.7 cm protruding through a skin defect. There were uneven fuzzy edges and heterogeneous structure with solid component and areas of degeneration and cystic degeneration. Doppler ultrasound revealed vascular pedicle and high-velocity blood flow within the lesion and along its periphery. There were edema and vascularization of soft tissues around the lesion. No relationship between focal lesion and major nerves was confirmed **(Fig. 3)**.

In December 2025, open biopsy was performed. Findings were consistent with schwannoma, and immunohistochemical results (HMB45–, MelanA–, S100+, SOX10+, PanCK–) confirmed WHO Grade I schwannoma (ICD-10 code D36.1) **(Fig. 4)**.

According to oncologist, suspicions of basal cell/epithelial skin cancer remained despite morphological findings. On February 13, 2026, surgeons in collaboration with oncologists performed an extended excision of soft tissue mass on the right leg (in accordance with protocol for basal cell carcinoma) with simultaneous skin defect closure using a split-thickness thigh skin flap **(Fig. 5)**.

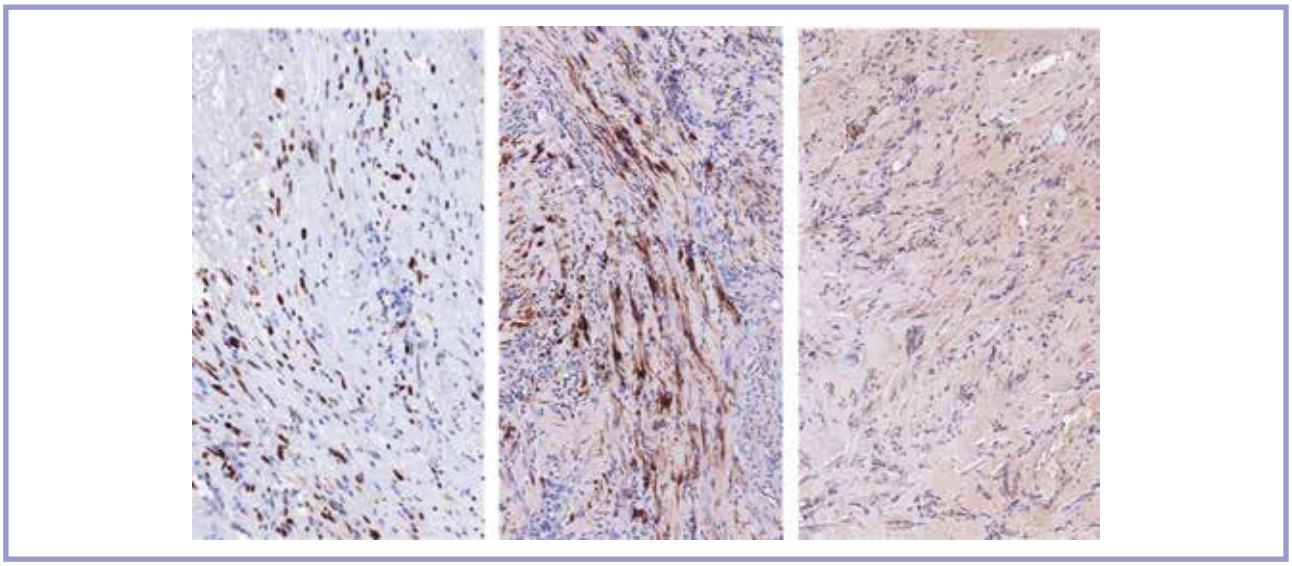

Fig. 4. **Immunohistochemical results: SOX10+, S100+, HMB45–.**



Fig. 5. **Surgical intervention: resection of tumor according to oncological principles (involving soft tissue over a distance of 1.5 cm), skin defect closure using a split-thickness thigh skin flap.**

Morphological analysis: a 4-cm round specimen with a 2-cm protruding grayish-brown mass in the center (gray in section) with unclear borders **(Fig. 6)**.

Histological examination of specimen revealed a large amount of hemosiderin that complicated differentiation with melanoma **(Fig. 7)**. Immunohistochemical results were consistent with previous biopsy (December 2025): expression of SOX10 and S100 without HMB45. This excluded malignancy and confirmed the diagnosis of schwannoma.

The follow-up period was 2 months. No signs of tumor recurrence were detected.

Discussion

Etiopathogenesis of cutaneous schwannomas is still unclear. In some cases, these tumors arise as a part of schwannomatosis or neurofibromatosis type 1. Our patient had no signs of phakomatosis. Cutaneous schwannomas typically appear as slow-growing solitary nodules ranging in size from 0.25 to 3 cm. They rarely reach large sizes (up to 14 cm). They may appear as solitary flesh-colored, pinkish-yellow or pink lesions (very rarely, pedunculated) or as dense intradermal or subcutaneous painful nodules.

Atypical cutaneous schwannomas are characterized by erythematous plaque with hemorrhagic-fibrinous discharge. Such schwannomas are most common in the head and neck (40%) and less commonly affect skin of extremities and trunk. Multiple lesions are observed in 8% of cases [5].

Hart J. et al. [6] described 58 cases of epithelioid schwannoma. Age of patients (31 men and 26 women) ranged from 14 to 80 years (median 38 years). Two patients had neurofibromatosis type 1. Tumors developed in dermis/subcutaneous tissue (n=56) or muscle (n=2) of the upper limb (34.5%), lower limb (34.5%), chest/abdomen/back (18%), and less common locations including scalp, neck,

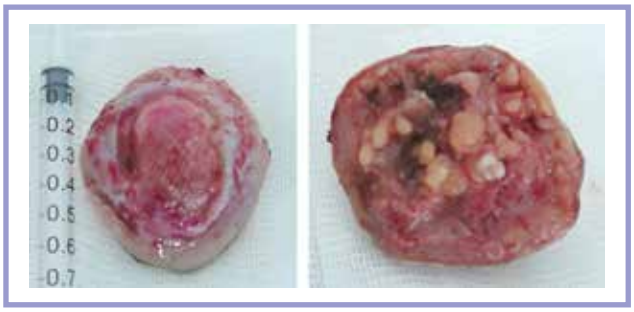

Fig. 6. **Biopsy: macroscopic structure of tumor.**

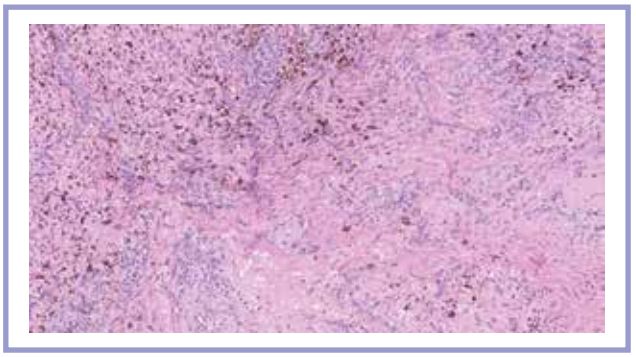

Fig. 7. **Microscopic specimen (hematoxylin and eosin staining): image of «old» schwannoma with cystic degeneration, erosive changes, hemosiderin deposits and hyalinized vessels.**

lip and breast. Tumor sizes ranged from 0.25 to 4.5 cm (median 2.0 cm). Epithelioid schwannomas, even with atypical clinical manifestations, are benign and characterized by favorable biological behavior compared to epithelioid MPNST usually localized in deeper tissues.

In typical manifestations, diagnosis of cutaneous schwannomas is straightforward. However, atypical schwannomas can be mistaken for other benign tumors and lesions (lipomas, epidermal cysts, pyogranulomas, vascular malformations) or malignant neoplasms (skin cancer, sarcoma). This requires patient referral according to appropriate clinical algorithms.

Diagnosis and treatment of malignant skin tumors are among the most pressing issues in modern oncology. Early diagnosis of these diseases is a priority for oncological care in the Russian Federation. These tumors are the third most common neoplasms among men (10.5%) and second among women (14.6%). Approximately 80.000 new cases of malignant skin tumors are registered annually in Russia [7]. Soft tissue sarcomas are malignant tumors arising from ligaments, tendons, muscles, and adipose tissue of primitive mesoderm [8]. MPNSTs account for 5–10% of all soft tissue sarcomas. Annual incidence is 1 case per 1 million population. About 50% of soft tissue sarcomas are complicated by metastases within 2 years after diagnosis [9]. Skin cancer (non-melanoma skin cancer) is a group of malignant skin neoplasms including basal cell carcinoma of skin (75–97%), squamous cell carcinoma (5–15%) and rare malignant tumors of skin appendages (Kaposi sarcoma, sebaceous gland cancer, and Merkel cell carcinoma) (1%) [10].

Differential diagnosis between malignant and benign tumors is based on clinical picture (tumor appearance), ultrasound and MRI data, but the main method is morphological, including immunohistochemical, examination.

A distinctive morphological feature of schwannomas is biphasic pattern of alternating Antoni areas A and B. Degenerative changes in tumor are observed in some cases (cystic degeneration, hyalinization, focal calcification, myxoid changes, consequences of hemorrhage and Verocai bodies) [11]. The main immunohistochemical criteria of schwannoma are extensive expression of S100 and SOX10, loss of INI1 expression (epithelioid schwannoma) or mosaic INI1 expression (syndrome-associated schwannoma). GFAP expression is less common and variable [12, 4].

Ultrasound is a primary diagnostic method for superficial soft tissue tumors. Schwannomas appear as clearly defined, encapsulated, hypoechoic lesions located eccentrically relative to the nerve. US signs of tumor malignancy are structural heterogeneity, hypoechogenic nature, unclear borders and severe perifocal edema. Doppler ultrasonography of malignant tumors reveals abundant blood flow with high velocity [13].

Contrast-enhanced MRI is the gold standard for evaluating peripheral nerve tumors. Diffusion tensor imaging with tractography allows for in-depth differential diagnosis between schwannomas, neurofibromas and MPNST [10]. However, MRI and ultrasound do not always clearly determine malignant nature of tumor. PET CT allows for more effective differentiation of soft tissue malignancy, as it provides both anatomical and metabolic data.

If malignancy is suspected, ultrasound-guided core biopsy or open biopsy is indicated [14]. Advisability of biopsy should be carefully considered, taking into account the risk of nerve damage and the need for early and accurate verification of tumor [15]. Histological heterogeneity of soft tissue tumors always poses a risk of false-positive and false-negative results [2].

Accurate histological diagnosis determines adequate treatment for soft tissue tumors, especially in malignant neoplasms. In recent years, auxiliary methods such as immunohistochemistry, molecular methods (fluorescence hybridization in situ and next-generation sequencing) were introduced to improve diagnostic accuracy. However, not all laboratories have access to these methods, and these techniques imply specialized knowledge [16]. Ogura K. et al. [17] analyzed agreement between histological diagnoses of bone and soft tissue tumors between primary hospitals and a specialized sarcoma center. Diagnostic agreement was 64.2% of all cases, and some differences were observed in other 35.8%. Importantly, this diagnostic adjustment changes treatment in 40% of such cases.

Discrepancies between clinical presentation and morphological diagnosis, as well as potential errors in the last one, sometimes lead to significant delays in specialized care. This is especially critical for malignant neoplasms. Thus, delayed diagnosis and treatment of soft tissue sarcomas

are a very common problem with significant prognostic, legal and psychosocial implications [18]. Surgical treatment for soft tissue tumors with signs of malignancy should be performed according to the principles of surgical oncology taking into account anatomical location of tumor, histological variant and functional consequences of resection [14].

In our case, extended resection of tumor was performed due to suspected malignant cells in thickened skin edges. We do not consider this unnecessary, as dimensions of excised tumor and surrounding tissues were 4 cm, and fibrous skin edges could not be aligned. Defect closure was necessary in any case. This surgical approach allowed patient recovery.

Conclusion

Atypical course of cutaneous schwannoma with ulceration complicates accurate and timely diagnosis, routing, selection of specialist and surgical strategy. Clinical data indicating malignant course of soft tissue tumor necessitate early surgical intervention according to oncological principles despite biopsy data on benign tumor. Final morphological diagnosis in this case is based on examination of the entire tumor after resection.

Author contribution:
Concept and design of the study — Fedyakov A.G., Gorozhanin A.V.
Collection and analysis of data — Plieva Z.Kh., Silaev I.M., Kozlova Yu.A., Polichuk M.S.
Morphological examination — Zakurdaev E. I.
Writing the text — Fedyakov A.G., Silaev I.M., Polichuk M.S., Kozlova Yu.A.
Editing — Gorozhanin A.V., Plieva Z.Kh.

No conflict of interests to declare.

REFERENCES

1. Makashova ES, Zolotova SV, Absalyamova OV, Galkin MV, Petrokovskaya AV, Kozlov AV, Golanov AV. New classification and approaches to the treatment of schwannomatosis. *Burdenko's Journal of Neurosurgery.* 2023;87(5):104-109. (In Russ.). https://doi.org/10.17116/neiro202387051104
2. Kim C, Chung YG, Jung CK. Diagnostic conundrums of schwannomas: two cases highlighting morphological extremes and diagnostic challenges in biopsy specimens of soft tissue tumors. *Journal of Pathology and Translational Medicine.* 2023;57(5):278-283. https://doi.org/10.4132/jptm.2023.07.13
3. Rai P, Bathla G, Soni N, Desai A, Rao D, Vibhute P, Agarwal A. Classification of schwannomas and the new naming convention for "neurofibromatosis-2": Genetic updates and international consensus recommendation. *The Neuroradiology Journal.* 2025;38(5):533-542. https://doi.org/10.1177/19714009251313510
4. Pellerino A, Verdijk RM, Nichelli L, Andratschke NH, Idbaih A, Goldbrunner R. Diagnosis and Treatment of Peripheral and Cranial Nerve Tumors with Expert Recommendations: An EUropean Network for RAre CANcers (EURACAN) Initiative. *Cancers.* 2023;15(7):1930. https://doi.org/10.3390/cancers15071930
5. Saad EA, Sati H, Boueri M, Nasr L, Fawaz A, Emmanuel M. Cutaneous Schwannomas: Clinical Manifestations, Diagnosis and Management: A Review. *Current Dermatology Reports.* 2024;13:103-114. https://doi.org/10.1007/s13671-024-00429-9
6. Hart J, Gardner JM, Edgar M, Weiss SW. Epithelioid Schwannomas: An Analysis of 58 Cases Including Atypical Variants. *The American Journal of Surgical Pathology.* 2016;40(5):704-713. https://doi.org/10.1097/PAS.0000000000000589
7. Merabishvili VM, Demidov LV, Belyaev AM, Gafton GI, Samoylenko IV, Perelygin VV. The state of oncological care in Russia: malignant skin neoplasms (C44). Part 1. Prevalence, quality of registration, age-related characteristics, localization and histological structure (a clinical and population-based study). *Formulas of Pharmacy.* 2024;6(4):18-33. (In Russ.). https://doi.org/10.17816/phf641606
8. *Sarkomy myagkikh tkaney: klinicheskie rekomendatsii [Soft tissue sarcomas: clinical guidelines].* Moscow: Republican Center for Healthcare Development; 2025. (In Russ.).
9. Konovalov NA, Korolishin VA, Asiutin DS, Timonin SIu, Shults MA, Solenkova AV, Zakirov BA, Batyrov AA. Treatment of malignant peripheral nerve sheath tumors: case reports and a literature review. *Burdenko's Journal of Neurosurgery.* 2019;83(3):64-72. (In Russ.). https://doi.org/10.17116/neiro20198303164
10. Vavrinchuk AS, Marochko AYu. Skin cancer: risk factors, epidemiology in Russia and worldwide. *Modern Problems of Science and Education.* 2015;6. (In Russ.).
11. Majumder A, Ahuja A, Chauhan DS, Paliwal P, Bhardwaj M. A clinicopathological study of peripheral schwannomas. *Medicine and Pharmacy Reports.* 2021;94(2):191-196. https://doi.org/10.15386/mpr-1708
12. Baranova IB, Slavnova EN, Petrov AN. Cytological diagnosis of schwannoma: three clinical observations. *News of Clinical Cytology of Russia.* 2023;2. (In Russ.).
13. Shirodkar K, Hussein M, Reddy PS, Shah AB, Raniga S, Pal D, Iyengar KP, Botchu R. Imaging of Peripheral Intraneural Tumors: A Comprehensive Review for Radiologists. *Cancers.* 2025;17(2):246. https://doi.org/10.3390/cancers17020246
14. Hayes AJ, Nixon IF, Strauss DC, Seddon BM, Desai A, Benson C, Judson IR, Dangoor A. UK guidelines for the management of soft tissue sarcomas. *British Journal of Cancer.* 2025;132(1):11-31. https://doi.org/10.1038/s41416-024-02674-y
15. Vincitorio F, Bradaschia L, Bue EL, Antico A, Titolo P, Battiston B, Garbossa D, Cofano F. The Role of Pre-Operative Biopsy in Malignant Peripheral Nerve Sheath Tumours: A Review and Retrospective Series with a Management Algorithm from a Single-Center Experience. *Neurology International.* 2025;17(9):132. https://doi.org/10.3390/neurolint17090132
16. Kawai A, Araki N, Ae K, Akiyama T, Ozaki T, Kawano H, Kunisada T, Sumi M, Takahashi S, Tanaka K, Tsukushi S, Naka N, Nishida Y, Miyachi M, Yamamoto N, Yoshida A, Yonemoto T, Yoshida M, Iwata S. Japanese Orthopaedic Association (JOA) clinical practice guidelines on the management of soft tissue tumors 2020 — Secondary publication. *Journal of Orthopaedic Science.* 2022;27(3):533-550. https://doi.org/10.1016/j.jos.2021.11.023
17. Kawai A, Yoshida A, Shimoi T, Kobayashi E, Yonemori K, Ogura K, Iwata S, Toshirou N. Histological diagnostic discrepancy and its clinical impact in bone and soft tissue tumors referred to a sarcoma center. *Cancer Science.* 2024;115(8):2831-2838. https://doi.org/10.1111/cas.16211
18. Fernández JÁ, Gómez B, Díaz-Gómez D, López I, Lozano P, Muñoz P, Muñoz-Casares FC, Olivares-Ripoll V, Vasques H, Asencio-Pascual JM. Diagnostic Delay in Soft Tissue Sarcomas: A Review. *Cancers.* 2025;17(11):1861. https://doi.org/10.3390/cancers17111861

Received 27.04.2026
Accepted 07.05.2026

COMMENT

Diagnostic algorithms for surgeons in verifying malignant tumors are obviously important. Regarding peripheral nerve lesions, this determines extent of resection, severity of intraoperative nerve injury and, consequently, postoperative disability, as well as advisability of immediate or delayed nerve reconstruction.

According to various studies, approximately 13% of benign diagnoses based on baseline biopsy are incorrect due to tumor heterogeneity (as malignant cells may be confined to only a small part of tumor). Conversely, specimens are often sent for morphological examination with designation «probable malignancy» in the absence of biopsy according to solely preoperative examination and macroscopic intraoperative findings. In such cases, up to 30% of results are favorable thanks to immunohistochemical analysis, and malignancy is not confirmed. In redo surgeries, malignant peripheral nerve sheath neoplasm is verified in 50% of cases after resection of recurrence of primarily benign tumor or tumor remnants.

This article describes the opposite situation, when benign nature of tumor was questionable despite histological and immunohistochemical data. Extended resection was inspired by macroscopic features of tumor and involvement of surrounding soft tissues. This approach appears to be highly controversial. Indeed, extended resection did not result in neurological deficit solely because the tumor arose from terminal cutaneous nerve.

Shtok A.V. (Moscow)