Burdenko's Journal of Neurosurgery
2026, No. 4, pp. 61–64
https://doi.org/10.17116/neiro20269003161

Subdural hematoma without subarachnoid hemorrhage caused by ruptured traumatic distal aneurysm of anterior cerebral artery

© D.N. Kopachev, Zh.B. Semenova, S.V. Meshcheryakov, O.V. Karaseva, N.A. Knyazeva, A.G. Gagloev

Research Institute of Emergency Pediatric Surgery and Traumatology, Moscow, Russia

ABSTRACT

Objective. To describe a rare complication of non-penetrating traumatic brain injury.

Material and methods. We present a 16-year-old patient with multiple skeletal lesions and mild traumatic brain injury (TBI). Two weeks after injury, clinical status suddenly worsened due to large subdural hematoma without signs of subarachnoid hemorrhage despite normal neuroimaging data at baseline.

Results. Examination revealed pericallosal artery aneurysm. Microsurgical intervention with aneurysm excision was performed. Histological examination revealed thrombotic masses containing fibrin and no vascular walls of aneurysm. Therefore, the aneurysm was regarded as traumatic false aneurysm resulting from detachment of small artery. There were no neurological disorders at discharge.

Conclusion. Acute subdural hematoma in delayed period after TBI requires CT angiography to rule out traumatic aneurysm.

Keywords: *subdural hematoma without subarachnoid hemorrhage, traumatic aneurysm.*

INFORMATION ABOUT THE AUTHORS:
Kopachev D.N. — https://orcid.org/0000-0002-5501-9062
Semenova Zh.B. — https://orcid.org/0000-0002-2018-050X
Meshcheryakov S.V. — https://orcid.org/0000-0003-3701-4628
Karaseva O.V. — https://orcid.org/0000-0001-9418-4418
Knyazeva N.A. — https://orcid.org/0009-0004-0771-6922
Gagloev A.G. — https://orcid.org/0009-0009-1621-5659
Corresponding author: Kopachev D.N. — e-mail: dmkopachev@gmail.com

TO CITE THIS ARTICLE:
Kopachev DN, Semenova ZhB, Meshcheryakov SV, Karaseva OV, Knyazeva NA, Gagloev AG. Subdural hematoma without subarachnoid hemorrhage caused by ruptured traumatic distal aneurysm of anterior cerebral artery. *Burdenko's Journal of Neurosurgery.* 2026; 90(4):61–64. (In Russ.). https://doi.org/10.17116/neiro20269004161

Introduction

Posttraumatic aneurysm of anterior cerebral artery is a relatively rare complication of non-penetrating traumatic brain injury (TBI) [1]. Clinical and radiographic manifestation as subdural hematoma without subarachnoid hemorrhage is even less expected event [2].

The purpose of this study was to present an adolescent with multiple injuries where brain injury was classified as mild TBI (GCS score 14-15). In subacute period, the patient developed subdural hematoma without signs of SAH caused by a ruptured false aneurysm of pericallosal artery.

A 16-year-old patient sustained severe concomitant trauma with predominant spinal and skeletal injuries after a fall from the 5th floor. He admitted to the primary hospital diagnosed with blunt TBI, mild brain and pulmonary contusion, bilateral pneumothorax, sternal fracture, complicated unstable fracture of LIV with total spinal stenosis, multiple uncomplicated stable compression fractures of thoracic and lumbar vertebrae, closed fracture of the forearm bones with bilateral displacement, closed fracture of both tibia bones with bilateral displacement. CT of the head on the day of injury revealed no intracranial abnormalities or skull fracture. MRI of the brain was not performed due to lower limb external fixation. After 5 days, the patient was delivered to our hospital for further surgical treatment after stabilization of clinical status. CT of the head upon admission revealed no pathology **(Fig. 1a)**. In 7 days after injury, patient underwent surgery for LIV fracture (LIV laminectomy, LIII partial laminectomy, microsurgical meningoradiculolysis, anterior decompression, LIV fracture repositioning and transpedicular LIII–LIV fixation). Severe damage to dura mater was intraoperatively detected. We performed dura mater repair and lumbar drainage (removed after 5 days). In 6 days after surgery and 13 days after injury, the patient was transferred from intensive care unit to traumatology department for further treatment of extremity injuries.

Headache and diplopia developed in 15 days after injury. Examination revealed clear consciousness (GCS score 15)

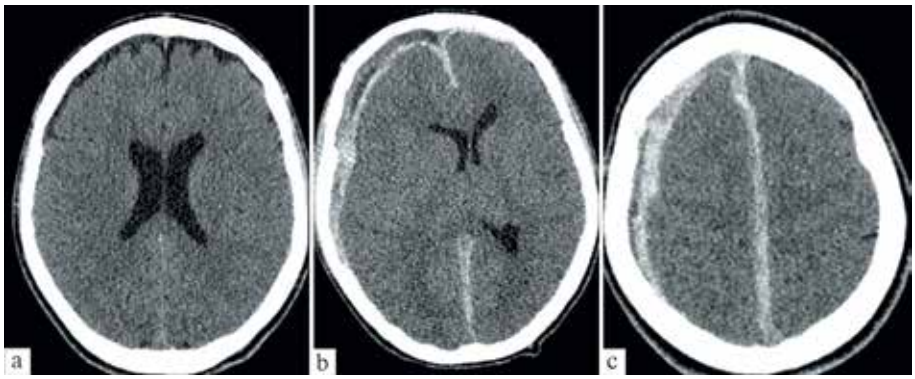

Fig. 1. **CT of the head.**
a — upon admission; b, c — clinical deterioration in 15 days after TBI, 8 days after admission: subdural hematoma in the right frontal convexital region and interhemispheric fissure, brain dislocation to the left.

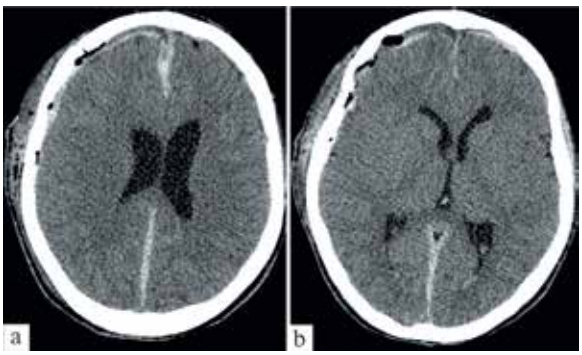

Fig. 2. **CT of the head after primary debridement of subdural hematoma in the right frontal lobe.**

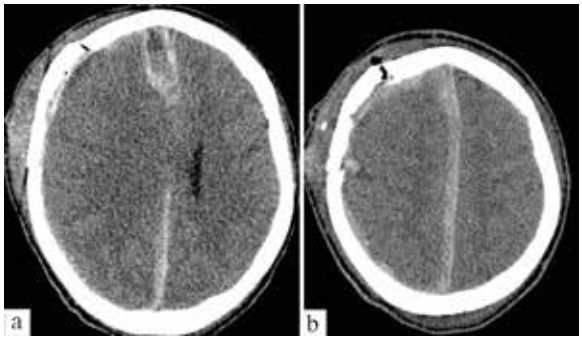

Fig. 3. **CT of the head at clinical deterioration. Recurrent subdural hematoma in the right frontal lobe three days after surgery, progressive edema and right-sided dislocation of hemisphere.**

and right oculomotor nerve palsy. CT revealed subdural hematoma over the right hemisphere and blood in interhemispheric fissure without signs of SAH **(Fig. 1b**, c). We recognized subdural hematoma as a result of CSF over-drainage through lumbar drain. Considering initial signs of dislocation, we performed craniotomy in frontal convexital region on the right and removed dense clots of subdural hematoma. There was no brain protrusion, and we sutured dura mater with subsequent bone repositioning **(Fig. 2)**. The patient was weaned from ventilator. Neurological status corresponded to preoperative data.

Three days later, clinical status and consciousness worsened (GCS score 9). CT revealed enlargement of hematoma in interhemispheric fissure without SAH **(Fig. 3)**. The patient was delivered to the operating theater. Previous craniotomy was expanded. We partially removed hematoma in interhemispheric fissure and repaired dura mater. There was no bone flap repositioning. Consciousness remained abnormal after surgery. Over the next few days, consciousness improved with subsequent mutism and gradual recovery of speech. CT angiography revealed a narrow-necked aneurysm diagnosed as a pericallosal artery aneurysm **(Fig. 4)**.

We established the need for aneurysm clipping and simultaneous skull defect closure with autologous bone. After interhemispheric approach, we revealed aneurysmal sac fused to the falx and disconnected from pericallosal arteries. Dissection revealed a small branch extending from pericallosal artery to aneurysm. We cauterized and resected this branch along with aneurysm **(Fig. 5)**. Skull defect was simultaneously closed with autologous bone. Histological examination revealed fibrinous and thrombotic masses with no evidence of vascular wall. Thus, we classified this finding as a false aneurysm. Clinical status improved, and oculomotor nerve palsy regressed. Follow-up CT revealed no intracranial abnormalities **(Fig. 6)**. After final intramedullary osteosynthesis and primary rehabilitation, the patient was discharged. There was GCS score 5 at discharge (good recovery).

Discussion

Among all intracranial aneurysms, traumatic ones account for 1% of all intracranial aneurysms with predom-

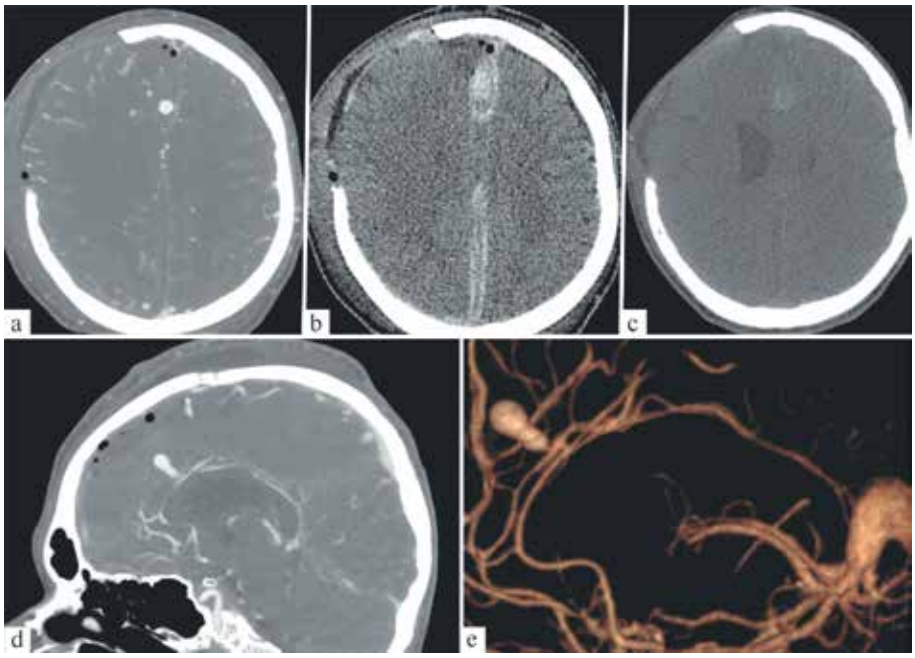

Fig. 4. **CT angiography and CT of the head.**
a, d, e – a narrow-necked aneurysm in projection of pericallosal artery; b – hypodense rounded zone in projection of aneurysm on native scans; c – hyperdense zone in projection of aneurysm.

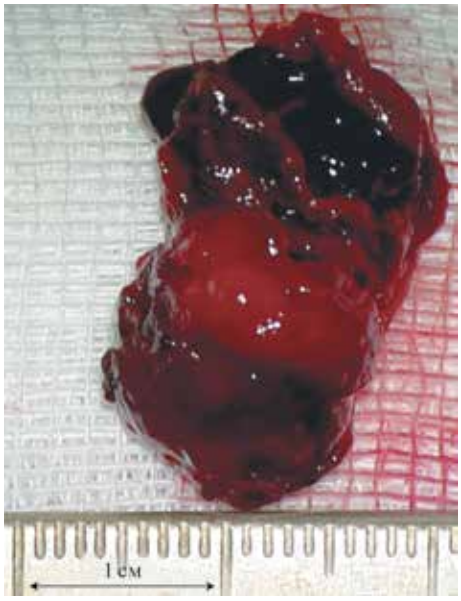

Fig. 5. **Excised false aneurysm.**

inance in pediatric population (primarily in boys) [1]. They are more common in penetrating TBI, although cases of mild trauma were also described. Aneurysm follows mechanical impact of bone or meninges on arterial wall in various locations. Distal aneurysms of anterior cerebral artery are associated with damage to vascular wall by falx. Histologically, these are false aneurysms, when blood from the damaged parent vessel enters the hematoma. According to the literature, hemorrhage from traumatic false aneurysm manifests as a sudden clinical deterioration on average 21 days after TBI. It is associated with 50% mortality rate [1].

The most common cause of acute subdural hematoma is TBI followed by rupture of cortical veins. However, this factor was excluded in our patient. In very rare cases, acute subdural hematoma without signs of SAH may be an atypical manifestation of ruptured intracranial aneurysm [3]. Some authors note a tendency for distal aneurysms of anterior cerebral artery occurring in 5% of cases to present as a subdural hematoma without SAH. They account for 25% of cases described in the literature [3]. There are other causes of non-traumatic subdural hematoma: coagulopathy, hemorrhage into a tumor or arteriovenous malformation [4]. Acute subdural hematoma can also be a consequence of intracranial hypotension, including after damage to dura mater during spinal surgery [5]. Among other things, we considered dura mater rupture and CSF drainage through a lumbar drain in our patient as a possible cause of subdural hematoma. However, subsequent events excluded this mechanism of intracranial hemorrhage.

Despite mild brain injury not accompanied by structural CT changes, multiple severe damage to musculoskeletal system indicates high kinetic energy acting on brain tissue with possible detachment of small vessel from falx. The last one is immobile relative to the skull. In this re-

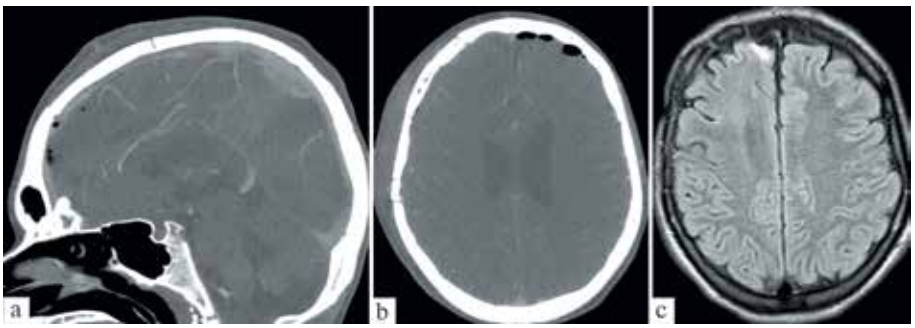

Fig. 6. **CT angiography after resection of false aneurysm and skull defect closure with autologous bone (a, b); c — MRI in 6 months after surgery: no changes of brain signal.**

gard, our case coincides with that described by Suhara S. et al. [2] in terms of nature of injury and clinical presentation. Their patient with combined injury and normal CT data developed subdural hematoma without SAH due to rupture of pericallosal artery false aneurysm a month later. Other authors also described delayed enlargement of acute subdural hematoma due to traumatic aneurysm rupture [6].

To date, there is no consensus regarding optimal treatment of traumatic pericallosal artery false aneurysms (parent artery occlusion with glue or aneurysm cavity with coils, microsurgical clipping, vessel cauterization, extra-intra- and intra-intracranial microvascular anastomoses) [1]. Aneurysm closure with microcoils while preserving the parent vessel does not completely exclude aneurysm enlargement and rupture [7]. Direct intervention was preferable in our case. Indeed, anatomy of aneurysm allowed excision, and cauterization of small parent artery did not lead to any complications **(Fig. 6c)**.

Conclusion

A few reports on posttraumatic cerebral aneurysms in children and adults, along with our own experience, demonstrate that spontaneous intracranial hemorrhage, especially in patients with mild-to-moderate TBI, is an absolute indication for CT angiography to rule out posttraumatic cerebral aneurysm. The last one is an indication for surgical treatment.

No conflict of interests to declare.

REFERENCES

1. Grin EA, Palla A, Rutledge C, Sharashidze V, Chung C, Baranoski JF, Riina HA, Shapiro M, Raz E, Nossek E. Traumatic intracranial aneurysms: A contemporary review in the endovascular era. *Interventional Neuroradiology.* 2025:15910199251394556. https://doi.org/10.1177/15910199251394556
2. Suhara S, Wong AS, Wong JO. Post-traumatic pericallosal artery aneurysm presenting with subdural haematoma without subarachnoid haemorrhage. *British Journal of Neurosurgery.* 2008;22(2):295-297. https://doi.org/10.1080/02688690701687678
3. Yamazaki M, Aoki T, Matano F, Murai Y. Ruptured distal anterior cerebral artery aneurysm presenting with acute subdural hematoma without subarachnoid hemorrhage. *Journal of Surgical Case Reports.* 2025;2025(1):rjae843. https://doi.org/10.1093/jscr/rjae843
4. Gabay S, Bergman L, Niry D, Budylev A, Gonen L, Kempfner A, Agur A, Haim O. Spontaneous acute subdural hematoma: Etiologic spectrum, diagnostic approach, and clinical correlates. *Clinical Neurology and Neurosurgery.* 2026;265:109370. https://doi.org/10.1016/j.clineuro.2026.109370
5. Oktay K. Subdural Hematoma Related to Dural Tear During Lumbar Spine Surgery: A Case Report and Review of the Literature. *Neurology India.* 2020;68(4):903-905.\ https://doi.org/10.4103/0028-3886.293459
6. Sugii M, Okada K, Ikeda S, Hara Y, Yokobori S. Clinical features and risk factors for delayed rupture of traumatic cerebral aneurysm: A case series. *Acute Medicine & Surgery.* 2024;11(1):e70000. https://doi.org/10.1002/ams2.70000
7. Lefevre E, Fawaz R, Premat K, Lenck S, Shotar E, Degos V, Kalamarides M, Boch AL, Carpentier A, Clarençon F, Nouet A. Delayed traumatic intracranial aneurysms: literature review and case series. *Neurosurgical Review.* 2024;47(1):355. https://doi.org/10.1007/s10143-024-02586-8

Received 30.01.2026
Revised 05.04.2026
Accepted 07.05.2026