Burdenko's Journal of Neurosurgery
2026, No. 4, pp. 52–58
https://doi.org/10.17116/neiro20269003152

Contralateral venous thrombosis and intracerebral hemorrhage after resection of parasagittal meningioma: a case report and systematic review

© D.S. Sheshin[1], A.B. Kadasheva[1], A.I. Belov[1], An.N. Konovalov[1], Yu.A. Kozlova[2, 3], M.V. Galkin[1], K.A. Kuldashev[4], A.V. Kozlov[1, 4], D.Yu. Usachev[1—3]

[1]Burdenko Neurosurgical Center, Moscow, Russia;
[2]Botkin Hospital, Moscow, Russia;
[3]Russian Medical Academy of Continuous Professional Education, Moscow, Russia;
[4]Andijan State Medical Institute, Andijan, Uzbekistan

ABSTRACT

Background. Preservation of venous structures and prevention of cortical trauma during resection of parasagittal meningioma are key factors ensuring high quality after surgery. However, venous circulatory disorders are possible despite these principles.

Objective. To describe contralateral cerebral venous thrombosis and compare own findings with literature data on cerebral venous thrombosis in parasagittal meningioma.

Results and discussion. A 53-year-old man with parasagittal meningioma of posterior third of superior sagittal sinus bordering the middle third on the right developed local thrombosis of sinus and parietal vein, as well as contralateral secondary intracerebral hemorrhage in 9 days after surgery. We did not remove tumor remnant inside the sinus. Superior sagittal sinus was not opened. Meningioma matrix coagulation was performed using direct spray mode. Enoxaparin sodium (subsequently switched to rivaroxaban) and citicoline were prescribed. The Karnofsky score recovered to 90 points after 3 months.

In accordance with the PRIZMA recommendations, we reviewed the PubMed and Google Scholar databases using the keywords «parasagittal AND meningioma AND venous AND thrombosis». We found 12 and 2.540 manuscripts, respectively. Analysis of all abstracts in PubMed database and 200 most relevant papers in Google Scholar database identified 3 eligible reports. Clearly, such complications are extremely rare.

Conclusion. Contralateral thrombosis of bridging vein after resection of parasagittal meningioma is unique and deserves attention. Timely diagnosis and anticoagulation can lead to complete regression of neurological symptoms.

Keywords: *cerebral venous thrombosis, venous infarction, parasagittal meningioma.*

INFORMATION ABOUT THE AUTHORS:
Sheshin D.S. — https://orcid.org/0009-0007-5301-769X
Kadasheva A.B. — https://orcid.org/0000-0003-1416-6936
Belov A.I. — https://orcid.org/0000-0003-0269-2138
Konovalov An.N. — https://orcid.org/0000-0002-0932-4752
Kozlova Yu.A. — https://orcid.org/0000-0002-8026-5919
Galkin M.V. — https://orcid.org/0000-0002-1436-0010
Kuldashev K.A. — https://orcid.org/0000-0003-4544-3537
Kozlov A.V. — https://orcid.org/0000-0002-3181-6470
Usachev D.Yu. — https://orcid.org/0000-0002-9811-9442
Corresponding author: Sheshin D.S. — e-mail: zamaratel@gmail.com

TO CITE THIS ARTICLE:
Sheshin DS, Kadasheva AB, Belov AI, Konovalov AnN, Kozlova YuA, Galkin MV, Kuldashev KA, Kozlov AV, Usachev DYu. Contralateral venous thrombosis and intracerebral hemorrhage after resection of parasagittal meningioma: a case report and systematic review. *Burdenko's Journal of Neurosurgery.* 2026;90(4):52–58. (In Russ.). https://doi.org/10.17116/neiro20269004152

Introduction

Cushing identified parasagittal meningiomas (PSM) as a separate group due to specific nature of resection associated with superior sagittal sinus (SSS) and variable venous structures in this area [1]. In the second half of the 20th century, the need for total resection of PSM was postulated. Today, the primary goal of surgery is maximum possible resection while maintaining or improving health-related quality of life. Reasonable limitations in total resection taking into account the capabilities of radiotherapy became standard for patients with meningiomas at the Burdenko Neurosurgery Center [2].

The main cause of progressive neurological symptoms after resection of PSM, along with damage to cerebral cortex in patients without clear boundaries of tumor, is impaired venous outflow following lesion of parasagittal veins and venous collaterals in walls of partially patent SSS. These collaterals are present in most cases even

if SSS appears completely blocked by tumor. In the 21st century, bilateral disruptions and even fatal outcomes resulting from forced or elective ligation of patent SSS became uncommon in elective neurosurgery.

Venous outflow disruptions and cortical lesion, if they occur, are confined to surgery side, and neurological symptoms correspond to appropriate area [2]. Bilateral disruptions are possible in case of bilateral PSM or ligation of patent SSS. We found no descriptions of contralateral venous thrombosis after surgery for PSM or ipsilateral neurological symptoms.

Material and methods

We present a 53-year-old man with right-sided PSM of posterior third of SSS. There was thrombosis of SSS and parietal vein, as well as secondary contralateral intracerebral hemorrhage. In accordance with the PRISMA (Preferred Reporting Items for Systematic Reviews and Meta-Analyses) guidelines, we screened the PubMed and Google Scholar databases using the keywords «parasagittal» AND «meningioma» AND «venous» AND «thrombosis.» As of April 1, 2026, 12 and 2.540 manuscripts were identified, respectively. Analysis of all abstracts from PubMed and 200 most relevant articles from Google Scholar database identified 3 articles as relevant to the issue **(Fig. 1)**. Such complications are extremely rare, and informing colleagues of their possibility is important.

Results

The patient admitted to the Burdenko Neurosurgery Center on December 10, 2024. Headaches occurred one year ago. Pain worsened in the morning. Six months later, he developed difficult distinguishing road signs. Ophthalmologist revealed bilateral decrease in visual acuity to 0.4 and congestive optic discs. Head MRI and neurological examination were advised.

MRI found right-sided PSM of posterior third of SSS with mild peritumoral brain edema **(Fig. 2)**.

PSM was verified at the Scientific Advisory Department of the Burdenko Neurosurgery Center. The patient was consulted by a radiologist due to small tumor size. However, peritumoral edema and intracranial hypertension made radiotherapy inappropriate at that time. Resection followed by decision on radiosurgery or radiotherapy depending on extent of resection and histological data was recommended.

Upon admission, the patient complained of headaches worsening in the morning without nausea or vomiting and unrelated to head position, as well as decreased vision. Neurological examination revealed no abnormalities. Visual acuity was 0.3 on the right and 0.4 on the left, visual fields were normal. Optic discs were hyperemic and protruding into the vit-

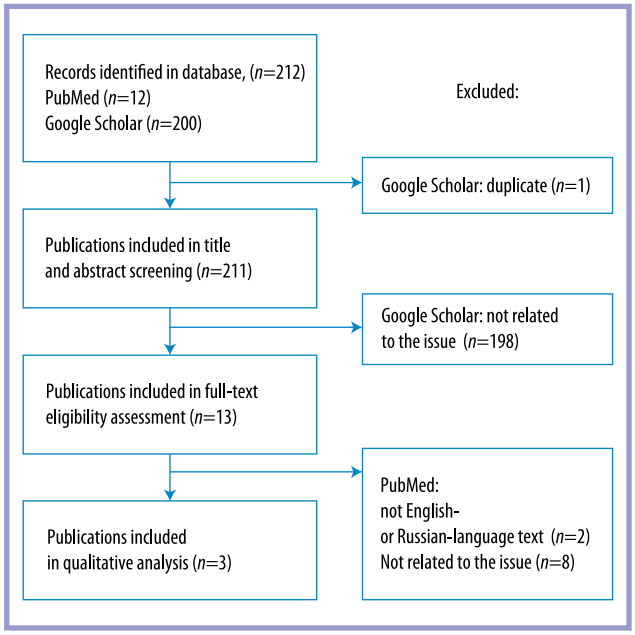

Fig. 1. **Study flowchart.**

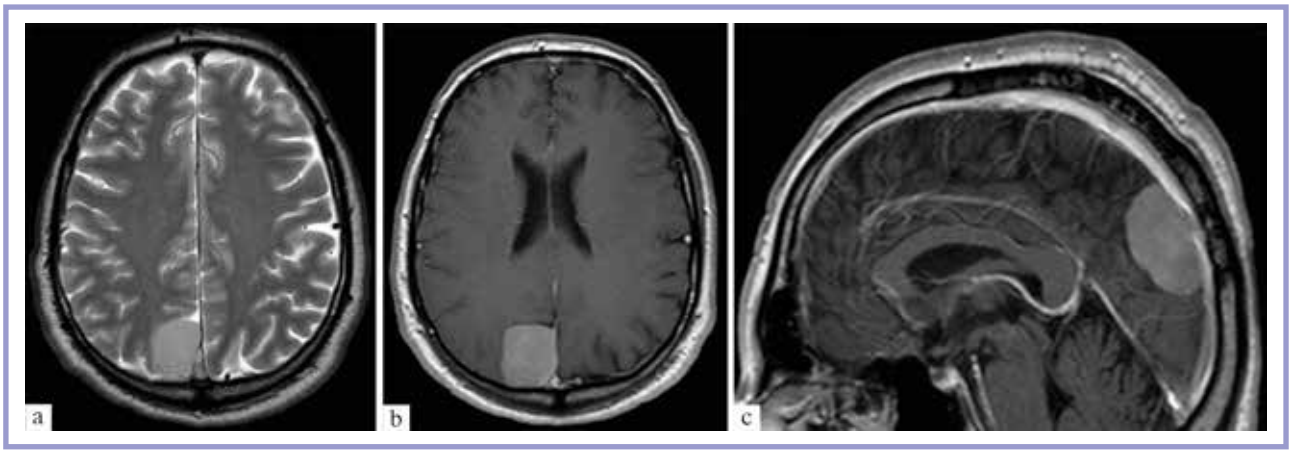

Fig. 2. **Preoperative MRI.**
a — axial T2WI; b — contrast-enhanced axial T1WI; c — contrast-enhanced sagittal T1WI.



Fig. 3. **Axial CT scan on the first postoperative day.**

reous; their margins were blurred. There were enlargement and plethora of veins.

Physical examination revealed hypertension and no other comorbidities. Serum D-dimer was 186 ng/ml (reference range 0—500 ng/ml). Perioperative therapy included dexamethasone 8 mg in the morning and omeprazole 20 mg twice daily.

On December 11, 2024, surgery was performed under combined intravenous anesthesia with fentanyl, propofol and muscle relaxants, as well as locoregional anesthesia with bupivacaine. In patient semi-sitting position, linear skin incision and osteoplastic craniotomy in the right posterior parieto-occipital region were performed with medial edge of bone defect along the right angle of SSS. We additionally resected the lower parts of the diploë and internal bone plate above SSS with a burr. There was no venous bleeding from bone above or near SSS. Dura mater near posterior third of SSS was hypervascularized, but its outer layer was clearly not affected by tumor. Internal bone plate was macroscopically intact. Dura mater was moderately tense. We dissected dura mater via crossbow incision with its base towards SSS. We discovered a tumor edge extending from interhemispheric fissure onto the cortex. It was a gray-blue meningioma attached to the right angle of SSS. Meningioma infiltrated pia mater, and the last one formed pial «capsule» around the tumor. A thinned layer of occipital cortex (1—2 mm) was displaced laterally. Visible tumor «capsule» was cauterized and incised. We removed internal components of tumor using rongeurs and ultrasonic aspirator. Meningioma was dense with poor vascularization. After excision of internal parts of meningioma, we mobilized its peripheral parts from edematous brain matter. Tumor size was 4×3×3 cm. There was bleeding from tumor matrix within its attachment to the angle and lateral wall of SSS in posterior third. In addition to standard bipolar coagulation, we used monopolar contactless coagulation («direct spray»). Considering localization of PSM and no signs of complete block of SSS, we did not open its angle and walls. Intrasinusoidal part of PSM was left (Simpson type 4 resection).

The patient awoke after surgery, quickly and correctly followed instructions. He was weaned from ventilator within an hour without complaints. Fourteen hours later, the patient was transferred to clinical department. There were no neurological changes compared to preoperative data (i.e., decreased visual acuity, otherwise normal).

Head CT the day after surgery revealed postoperative changes in the right occipital region, including air bubbles and hemorrhagic impregnation of hemostatic materials in tumor bed **(Fig. 3)**.

Histological examination revealed Grade I meningotheliomatous meningioma.

On the seventh postoperative day, the patient was discharged without neurological changes. Headaches regressed, and he was satisfied with treatment outcome.

On the second day after discharge (i.e., the ninth postoperative day), the patient developed seizures in the fingers of the right hand spreading to the forearm and shoulder, as well as head rotation to the right. Speech was impaired (he could only utter prepositions). This episode lasted no more than 2 minutes. There may have been a brief loss of consciousness. Parietal and occipital headache unrelated to the time of day developed after seizures. Localization of pain differed from preoperative data.

Head MRI on the 6th day after discharge and the 13th day after surgery revealed hemorrhage in the left frontoparietal region and SSS thrombosis at the level of intrasinusoidal part of tumor, as well as thrombosis of the left bridging vein **(Fig. 4, 5)**. EEG with hyperventilation testing found no ictal activity. In view of clinical and MR data, factor Xa antagonists, levetiracetam 500 mg twice daily and citicoline 1000 mg once daily were recommended.

The patient admitted to the local neurology hospital and received enoxaparin sodium and other medications. Clinical status improved after 3 days. Headaches regressed, in-hospital epileptic seizures recurred twice, and there were no further seizures.

A follow-up MRI on May 26, 2025 revealed minimal postoperative surgical site changes, almost complete resorption of blood-soaked hemostatic materials in tumor bed and regression of peritumoral brain edema. There was a small PSM fragment inside SSS. Blood flow through SSS in this segment was visible. There were MR signs of thrombosis of bridging posteroparietal vein of the left cerebral hemisphere. Intracerebral hematoma in the left parietal region almost completely regressed **(Fig. 6)**.

As of March 2026, there were no complaints and neurological abnormalities.

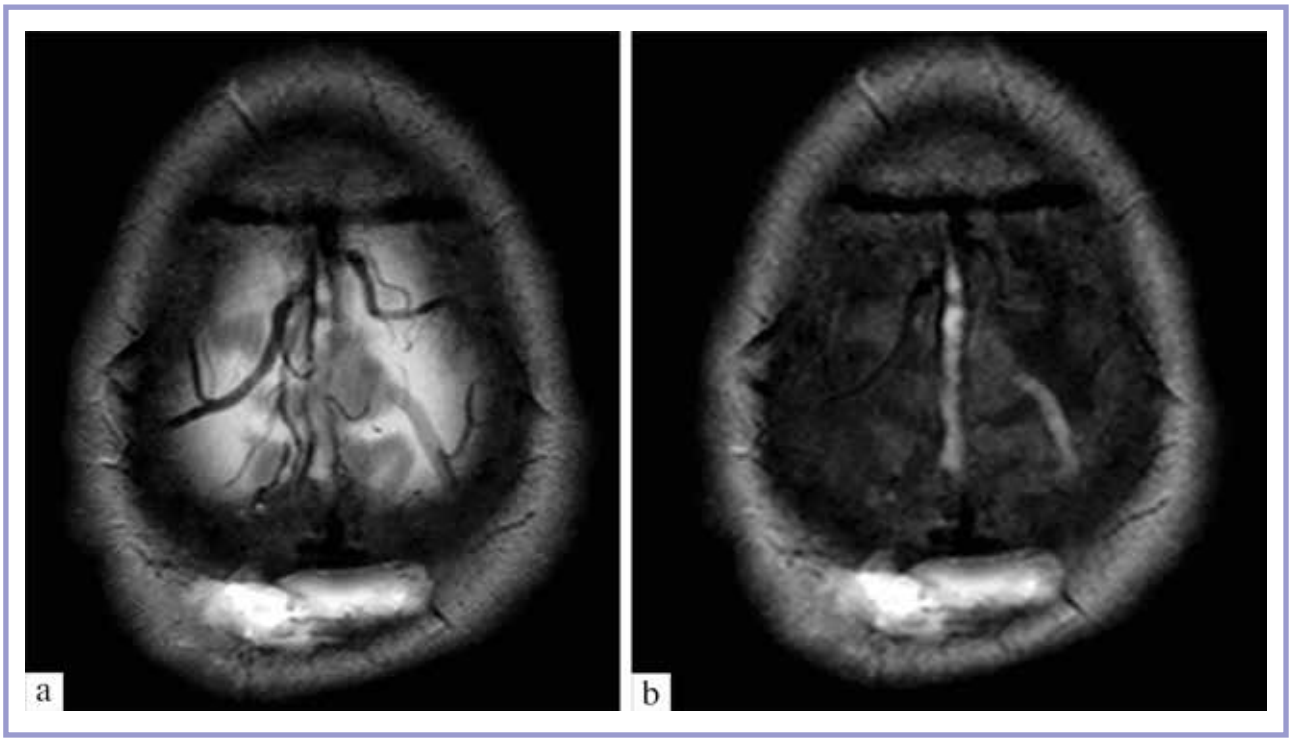

Fig. 4. **MRI on the 13th day after surgery.**
a — axial T2WI; b — axial FLAIR scan.

Results and discussion

In 1825, Ribes M. first described cerebral venous thrombosis (CVT) in a 45-year-old patient with headache, seizures and delirium. The diagnosis was confirmed by autopsy (thrombosis of SSS and transverse sinus). In 1828, Abercrombie J. first described postpartum CVT in a 24-year-old patient; autopsy revealed thrombosis of SSS and bridging veins [3]. SSS is the largest cerebral venous collector and most frequently affected by meningiomas [4].

Annual incidence of CVT not associated with PSM varies from 0.3 to 1.3 per 100.000 population [5]. Variable statistical indicators are likely due to different diagnostic methods. According to Gunes H.N. et al. [6], CVT is 5 times more common in women. In majority of cases (up to 78%), CVT develops in patients younger 50 years.

Among patients with PSM, CVT is rare before surgery, but can occur after surgery [4]. Some authors consider SSS invasion as a contraindication to total resection due to the risk of venous outflow disturbances with some complications and even death. Meningioma-induced total SSS blockade verified by neuroimaging does not guarantee safe resection, since venous collaterals are usually preserved in SSS walls [7].

Most often (45—70% of cases), PSMs affect the middle third (parietal part) of SSS as the longest part, less frequently (15—34%) — anterior third. Lesion of posterior third occurred in 9—30% of cases. It is generally recognized that resection of even partially patent SSS

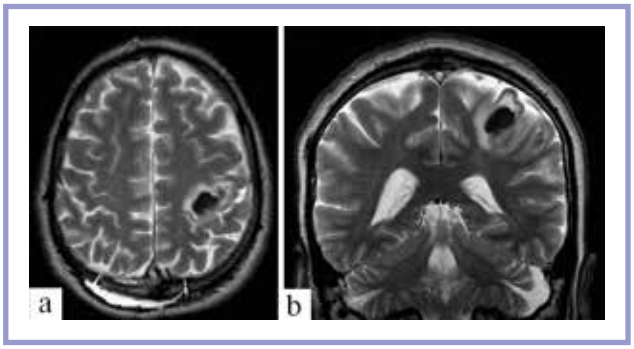

Fig. 5. **MRI on the 13th day after surgery.**
a — axial T2WI; b — coronal T2WI.

in the middle and posterior thirds is unjustified, as it usually leads to CVT and associated complications. Ligation of completely or partially patent SSS in anterior third (frontal part, anterior to the orifices of the anterior Rolandic veins) is acceptable, but undesirable, since it sometimes also leads to venous outflow obstruction and frontal lobe infarction [8].

The complication rate in PSM surgery varies from 15% to 30%. The main risk factors are perifocal brain edema and severity of SSS invasion according to Sindou classification [9]. These conclusions seem questionable, as they are based on small sample size (212 Chinese patients with catastrophic 2.8% mortality rate). Furthermore, Sindou classification is complex and subject to ambiguous interpretation. It was created to justify the possibility of resec-

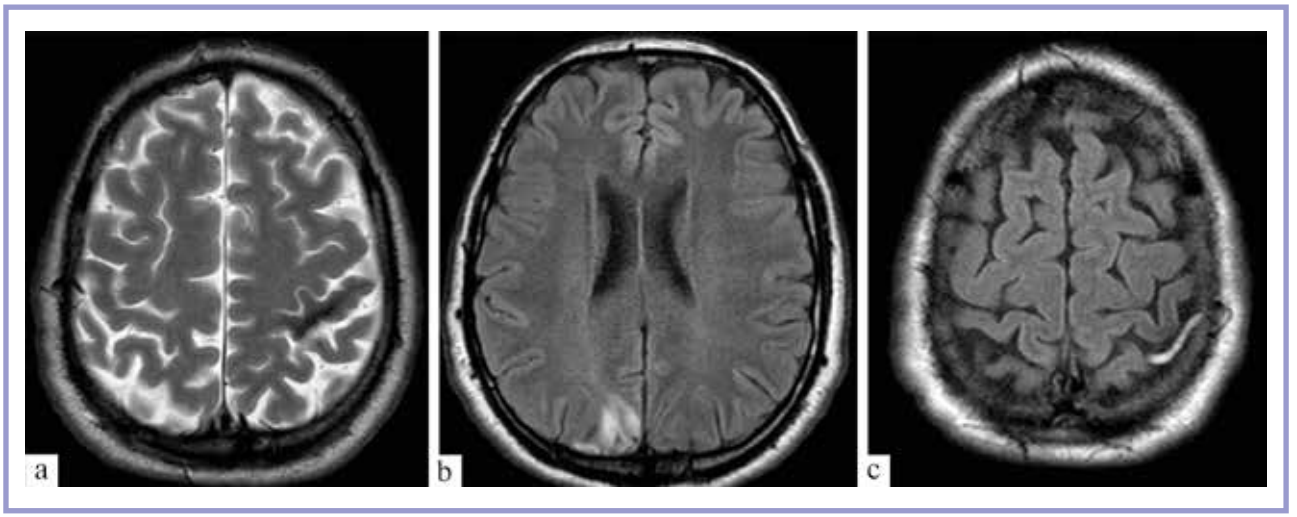

Fig. 6. **MRI on May 26, 2025.**
a — axial T2WI; b, c — axial FLAIR scan.

tion or repair of SSS that is no longer relevant today with development of radiotherapy.

Radiotherapy is currently optimal for small PSMs without symptoms, mass effect or peritumoral cerebral edema [2]. However, current EANO guidelines [10] mention this approach only for skull base meningiomas. Available experience clearly indicates the need to expand the role of radiotherapy for PSM. Objections from neurosurgeons concerned about lower income should be rejected in interests of patients.

However, risk of radiation-induced reactions and complications is significantly higher in patients with large meningiomas and/or peritumoral cerebral edema. Therefore, surgery is indicated for such meningiomas. The goal should be to minimize tumor size and disconnect its remnants from adjacent brain structures without QoL impairment. This prevents the entry of vascular endothelial growth factor, metalloproteases and other substances causing peritumoral edema into the brain, likely due to disruption of glymphatic system. Radiotherapy is administered after tumor shrinkage. Elective repair of SSS or its veins is not currently discussed in neuro-oncology.

At the Burdenko Neurosurgery Center, we adopted a policy of taking into account the interests of every patient, including those with neuro-oncology. For this purpose, we use all possible methods to preserve or improve QoL and maximize life expectancy. This approach was applied in this case. However, extremely rare complication (contralateral venous infarction) prompted in-depth analysis of situation and available literature data.

We found no similar descriptions in the PubMed and Google Scholar databases.

According to literature data, CVT is associated with age (mean age 46 years) and SSS thrombosis (55% of cases) [11]. Symptoms of CVT are usually mild with gradual progression, unlike other strokes. They do not clinically manifest until 48 hours after CVT. This complicates timely diagnosis (mean period between manifestation and diagnosis — 7 days). Much less frequently, CVT manifests with thunderclap headache or subarachnoid hemorrhage (<5%) or acute focal neurological symptoms (5%) [12, 13].

Headache is the most common symptom of CVT (89%). Seizures (39%), paresis of muscles innervated by cranial or spinal nerves (37%) and mental disorders are less common [14]. Pathogenesis of symptoms is due to focal brain damage in the area of venous stroke, mass effect of hematoma or ischemic edema, and intracranial hypertension [13].

Intracranial hemorrhage occurs in 30—40% of patients with CVT [14], coma — in 20% [13].

Epileptic seizures at the onset of CVT occur in 39—46% of patients, and status epilepticus develops in 6—7% [3].

CT or MR signs of CVT can include (1) direct visualization of thrombus, (2) no venous blood flow in appropriate structures and (3) visualization of consequences of venous ischemia (venous infarction, edema and hemorrhagic transformation, intracranial hypertension and hydrocephalus) [13].

Basic therapy for CVT implies emergency anticoagulation to prevent progression of CVT, to allow thrombolysis through natural mechanisms with suppression of thrombogenic factors and to prevent thromboembolic events [3].

Previous AHA/ASA and ESO guidelines for treating CVT recommend emergency fractionated low molecular weight heparin followed by warfarin [13]. This protocol is likely determined by low cost of warfarin compared to modern, more effective and less toxic oral factor Xa antagonists [15, 16]. Insurance companies in Europe and the USA are obviously not interested in costs and recommend cheaper medications. For developing countries, this is naturally better than drugs that are unaffordable for population, but we believe this recommendation is outdated and unreliable. At the Burdenko Neurosurgery Center, fractionat-

ed heparin followed by oral factor Xa inhibitors (apixaban or rivaroxaban) is routinely prescribed for CVT.

About 15% of patients with CVT die or remain disabled [14]. Outcomes are favorable in other cases. However, no physical impairment does not mean improvement or even preservation of preoperative QoL. Chronic symptoms may persist and even worsen [13]. Their assessment implies standard scales that are not adapted to patients with PSM. This complicates analysis of factors influencing neurological and QOL-related postoperative outcomes.

Our patient had preoperative signs of intracranial hypertension, likely due to impaired venous outflow through SSS affected by tumor. After uneventful early postoperative period, CVT developed on the 9th day after surgery. Clinical symptoms were completely consistent with literature data [13]. The only difference was late manifestation (much later than 48 hours after surgery) [13]. All complications corresponded to that described by Chen W.W. et al. [9], where 11.8% of patients developed venous infarction or cerebral edema after resection of PSM, 6.6% — intracerebral hematoma, 3.3% — new-onset epilepsy.

A possible cause of delayed thrombosis of SSS and bridging vein was monopolar cauterization of tumor matrix. Obviously, «direct spray» mode provides only superficial effect on tissue. However, this method is operator-dependent and can lead to deeper effects on tissues. Nevertheless, deep cauterization of intrasinusoidal tumor could be followed by early postoperative thrombosis. However, we found neither clinical nor CT signs of thrombosis **(Fig. 3)** at discharge.

Anticoagulation improved clinical status and ultimately recovered Karnofsky score (90 points). In modern literature, indications and timing for oral anticoagulants in acute period of CVT are not established [3].

CVT is characterized by better prognosis compared to other types of cerebrovascular accidents. The International Study on Cerebral Vein and Dural Sinus Thrombosis (ISCVT) identified factors associated with adverse outcomes: male gender, age >37 years, GCS score <9 upon admission, deep vein thrombosis, hemorrhagic lesions, central nervous system infections, and malignancies [14]. In our report, we found only the first two factors, and they are far from unique. This fact raises doubts about their prognostic significance.

Conclusion

Local SSS thrombosis within intrasinusoidal part of tumor, contralateral bridging vein thrombosis and intracerebral hemorrhage are possible even without attempts to resect intrasinusoidal part of parasagittal meningioma. Anticoagulation with direct and then oral factor Xa antagonists at manifestation of cerebrovascular thrombosis resulted in venous blood flow recovery and complete regression of neurological symptoms. Contralateral bridging vein thrombosis after resection of parasagittal meningioma is unique and deserves attention.

No conflict of interests to declare.

REFERENCES

1. Cushing H. *The meningiomas (dural endotheliomas): their source and favoured seats of origin (Cavendish Lecture)*. Brain. 1922;45:282-316.
2. Galkin MV, Golanov AV, Antipina NA, Danilov GV, Kozlov AV. Hypofractionated irradiation for intracranial meningiomas. *Burdenko's Journal of Neurosurgery*. 2025;89(6-2):21-28. (In Russ., In Engl.) https://doi.org/10.17116/neiro20258906221
3. Ramazanov GR, Korigova KhV, Petrikov SS. Diagnostics and Treatment of Cerebral Venous Thrombosis. *Russian Sklifosovsky Journal «Emergency Medical Care»*. 2021;10(1):122-134. https://doi.org/10.23934/2223-9022-2021-10-1-122-134
4. Orlov EA, Polunina NA. Cerebral venous revascularization in meningioma surgery. *Russian journal of neurosurgery*. 2023;25(2):130-139. (In Russ.). https://doi.org/10.17650/1683-3295-2023-25-2-130-139
5. Coutinho JM, Zuurbier SM, Aramideh M, Stam J. The incidence of cerebral venous thrombosis: a cross-sectional study. *Stroke*. 2012;43(12):3375-3377. https://doi.org/10.1161/STROKEAHA.112.671453
6. Gunes HN, Cokal BG, Guler SK, Yoldas TK, Malkan UY, Demircan CS, Yon MI, Yoldas Z, Gunes G, Haznedaroglu IC. Clinical associations, biological risk factors and outcomes of cerebral venous sinus thrombosis. *Journal of International Medical Research*. 2016;44(6):1454-1461. https://doi.org/10.1177/0300060516664807
7. Alzughaibi RA, Almuhammadi GA, Alasmari SS, Khoja MM, Almashni AA. Challenging Resection of Bilateral Parasagittal and Falcine Meningioma Involving Both Anterior Third and Middle Third of the Superior Sagittal Sinus: A Case Report and Literature Review. *Cureus*. 2024;16(7):e64865. https://doi.org/10.7759/cureus.64865
8. Aguiar PHP, Dos Santos RRP, Marson FAL, Dezena RA, Rampazzo ACMR. What is the ideal grade of resection for parasagittal meningiomas with the invasion of superior sagittal sinus? Simpson I or Simpson II resection? A retrospective observational study. *Surgical Neurology International*. 2022;13:423. https://doi.org/10.25259/SNI_436_2022
9. Chen WW, Wang Y, Hu YC, Zhao YL. Analysis of the common complications and recurrence-related factors of superior parasagittal sinus meningioma. *Frontiers in Surgery*. 2023;9:1023021. https://doi.org/10.3389/fsurg.2022.1023021
10. Goldbrunner R, Stavrinou P, Jenkinson MD, Sahm F, Mawrin C, Weber DC, Preusser M, Minniti G, Lund-Johansen M, Lefranc F, Houdart E, Sallabanda K, Le Rhun E, Nieuwenhuizen D, Tabatabai G, Soffietti R, Weller M. EANO guideline on the diagnosis and management of meningiomas. *Neuro-Oncology*. 2021;23(11):1821-1834. https://doi.org/10.1093/neuonc/noab150
11. Afifi K, Bellanger G, Buyck PJ, Zuurbier SM, Esperon CG, Barboza MA, Costa P, Escudero I, Renard D, Lemmens R, Hinteregger N, Fazekas F, Conde JJ, Giralt-Steinhauer E, Hiltunen S, Arauz A, Pezzini A, Montaner J, Putaala J, Weimar C, Schlamann M, Gattringer T, Tatlisumak T, Coutinho JM, Demaerel P, Thijs V. Features of intracranial hemorrhage in cerebral venous thrombosis. *Journal of Neurology*. 2020;267(11):3292-3298. https://doi.org/10.1007/s00415-020-10008-0
12. Ferro JM, Canhão P, Stam J, Bousser MG, Barinagarrementeria F, Massaro A, Ducrocq X, Kasner SE; ISCVT Investigators. Delay in the diagnosis of cerebral vein and dural sinus thrombosis: influence on outcome. *Stroke*. 2009;40(9):3133-3138. https://doi.org/10.1161/STROKEAHA.109.553891
13. Saposnik G, Bushnell C, Coutinho JM, Field TS, Furie KL, Galadanci N, Kam W, Kirkham FC, McNair ND, Singhal AB, Thijs V, Yang VXD; American Heart Association Stroke Council; Council on Cardiopulmonary, Critical Care, Perioperative and Resuscitation; Council on Cardiovascular and Stroke Nursing; and Council on Hypertension. Diagnosis and Management

of Cerebral Venous Thrombosis: A Scientific Statement From the American Heart Association. *Stroke*. 2024;55(3):e77-e90. https://doi.org/10.1161/STR.0000000000000456

14. Moraes Junior AAA, Conforto AB. Cerebral venous thrombosis. *Arquivos de Neuro-Psiquiatria*. 2022;80(5 Suppl 1):53-59. https://doi.org/10.1590/0004-282X-ANP-2022-S108

15. Baranich AI, Sychev AA, Savin IA, Kudrina VG, Kozlov AV. Correction of the effect of vitamin K antagonists and antiplatelet agents in hemorrhagic stroke. *Burdenko's Journal of Neurosurgery*. 2024;88(6):103-109. (In Russ., In Engl.). https://doi.org/10.17116/neiro202488061103

16. Baranich AI, Sychev AA, Savin IA, Kudrina VG, Kozlov AV. Correction of the effect of direct oral and parenteral anticoagulants in hemorrhagic stroke. *Burdenko's Journal of Neurosurgery*. 2025;89(1):109-115. (In Russ., In Engl.). https://doi.org/10.17116/neiro202589011109

Received 20.12.2025
Revised 06.05.2026
Accepted 07.05.2026

COMMENT

Contralateral venous thrombosis and intracerebral hemorrhage are extremely rare complications after resection of parasagittal meningioma and certainly deserve publication in appropriate journal to attract the attention of neurosurgeons. Literature data confirm unique nature of this complication.

Zaitsev A.M. (Moscow)