Burdenko's Journal of Neurosurgery
2026, No. 3, pp. 107–112
https://doi.org/10.17116/neiro202690031102

Odontoidectomy: a systematic review

© I.V. Chernov[1], A.N. Shkarubo[1, 2], D.A. Konyashin[1, 3], M.A. Kutin[1, 4], D.V. Fomichev[1], O.I. Sharipov[1], D.N. Andreev[1], A.D. Donskoy[1], P.L. Kalinin[1]

[1]Burdenko Neurosurgical Center, Moscow, Russia;
[2]Russian Medical Academy of Continuous Professional Education, Moscow, Russia;
[3]Burdenko Voronezh State Medical University, Voronezh, Russia;
[4]Russian Biotechnology University, Moscow, Russia

ABSTRACT

There is extensive experience of odontoidectomies for various lesions of craniovertebral junction worldwide. Various approaches including those through natural anatomical openings (transoral and transnasal), as well as transcervical one is used.

Objective. To compare the outcomes of odontoidectomies through various approaches according to literature data.

Material and methods. A systematic review was conducted in accordance with the PRISMA (Preferred Reporting Items for Systematic Reviews and Meta-Analyses) guidelines. We reviewed the PubMed, Medline and Google Scholar databases using the keyword «odontoidectomy».

Results. Analysis included 128 studies describing treatment outcomes in 688 patients. Transoral approach was used in 446 patients, transnasal — in 192, transcervical approach — in 50 patients.

Conclusion. Surgical approach for odontoidectomy significantly impacts surgery time, complication rates, initiation of oral feeding and length of hospital-stay.

Keywords: *odontoidectomy, basilar impression, transoral approach, transnasal approach.*

INFORMATION ABOUT THE AUTHORS:
Chernov I.V. — https://orcid.org/0000-0002-9789-3452
Shkarubo A.N. — https://orcid.org/0000-0003-3445-3115
Konyashin D.A. — https://orcid.org/0000-0003-1748-5668
Kutin M.A. — https://orcid.org/0000-0002-6520-4296
Fomichev D.V. — https://orcid.org/0000-0002-5323-1000
Sharipov O.I. — https://orcid.org/0000-0003-3777-5662
Andreev D.N. — https://orcid.org/0000-0001-5473-4905
Donskoy A.D. — https://orcid.org/0000-0002-0719-5168
Kalinin P.L. — https://orcid.org/0000-0001-9333-9473
Corresponding author: Chernov I.V. — e-mail: ichernov@nsi.ru

TO CITE THIS ARTICLE:
Chernov IV, Shkarubo AN, Konyashin DA, Kutin MA, Fomichev DV, Sharipov OI, Andreev DN, Donskoy AD, Kalinin PL. Odontoidectomy: a systematic review. *Burdenko's Journal of Neurosurgery.* 2026;90(3):107–112. (In Russ.). https://doi.org/10.17116/neiro202690031107

Introduction

Some degenerative, infectious and traumatic lesions of craniovertebral junction (CVJ) are accompanied by anterior compression of the brainstem and upper cervical spinal cord by dystopic odontoid process. Progression of conduction and bulbar disorders necessitates brainstem decompression. This can be performed either posteriorly (resection of squama occipitalis and posterior hemiring of C1 vertebra combined with distraction and various fusion options (occipitospondylodesis, CI–CII/III fixation)) or anteriorly (odontoidectomy combined with fusion) [1—2]. Despite the declining role of odontoidectomy in the treatment of patients with odontoid process invagination, in some cases (primarily when distraction is impossible) odontoid process resection is the only treatment option [3]. Ventral approaches are the most common for this procedure (through natural anatomical openings (transoral and transnasal) and via transcervical approach). Posterior midline approach was also described [4—8]. Each of these approaches has its own advantages and disadvantages.

The purpose of our study was to compare the outcomes of odontoidectomy via different approaches.

Material and methods

A systematic review was conducted in accordance with the PRISMA (Preferred Reporting Items for Systematic Reviews and Meta-Analyses) guidelines.

Table 1. **Disease-adjusted distribution of patients.**

Disease	Patients, *n*
Infections	19
CII and odontoid process hypertrophy	2
Craniovertebral junction malformations	329
Os odentoideus	6
Atlanto-axial dislocation	42
Trauma	59
Rheumatoid arthritis	59
Basilar impression	172
Total number	688

We selected studies in accordance with the PICO (Population, Intervention, Comparison, Outcomes) guidelines. The study included reports describing treatment of patients with brainstem compression by odontoid process due to non-neoplastic diseases (Population — P) who underwent odontoidectomy (Intervention — I) through various approaches (Comparison — C). The primary outcome (Outcome — O) was postoperative morbidity, secondary endpoints — neurological outcomes.

We reviewed the PubMed, Medline, and Google Scholar databases using the keyword «odontoidectomy.» Primary (titles and abstracts) and secondary (full text) screening was performed using the Rayyan QCRI web application.

Exclusion criteria: unavailable full-text article, no data on surgical approach, surgical features, postoperative complications, and neurological status over time (before and after treatment). Statistical analysis was performed using Statistica 10.0 (StatSoft Inc., USA). Pearson's χ^2 test or Fisher's exact test was used to compare qualitative variables, while Mann–Whitney test was used for quantitative variables. The null hypothesis was rejected at $p<0.05$. Means are presented with standard deviation (M±SD).

Results

After full-text analysis, we enrolled 128 studies between 1990 and 2025 **(Fig. 1)**. They describe treatment outcomes in 688 patients (394 men and 294 women, mean age 44.2±21.7 years) who underwent odontoidectomy for various casues.

Diseases causing anterior brainstem compression by odontoid process are presented in **Table 1**.

Symptoms included local pain (98.5% of patients), movement disorders (64.5%), bulbar (21.3%) and pelvic dysfunction (9.3%). Syringomyelia was observed in 3.9% of cases.

Odontoidectomy was performed through the following approaches:

— transoral (including modifications involving incision of the mandible, tongue or hard palate);
— transnasal;
— transcervical (anterolateral, posterolateral and posteromedial).

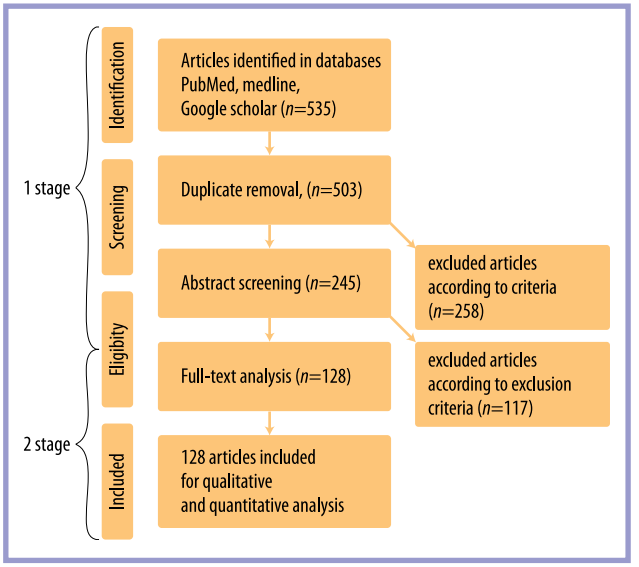

Fig. 1. **PRISMA flow chart.**

Transcervical approaches are performed along diagonal trajectory with mobilization of cervical neurovascular bundles and exposure of C1—C2 vertebral complex from anterolateral or retrolateral position.

The largest group consisted of patients who underwent transoral odontoidectomy (446 patients, group 1). Transnasal and transcervical odontoidectomy was carried out in 192 (group 2) and 50 patients (group 3), respectively.

Baseline data are presented in **Table 2**. There were between-group differences in diseases complicated by brainstem compression and incidence of clinical disorders.

Technical aspects of odontoidectomy through various approaches are widely described in the literature. Tracheostomy was performed in 9.6%, 2.6% and 2% of patients undergoing transoral, transnasal and transcervical odontoidectomy, respectively. In other cases, surgery was performed under oro/nasotracheal intubation.

CVJ fusion was performed in 553 patients (simultaneous procedure in 363 cases, before or after odontoidectomy in 190 cases). There was no fusion in 135 patients.

Anterior brainstem decompression was achieved in all cases. Neurological outcomes were assessed in late postoperative period (⩾ 1month). In overall group, complete regression of symptoms was observed in 11.9% of patients, partial regression — 77.3%, no improvement — 9%, deterioration — 1.8%. Dynamics of neurological status depending on surgical approach is presented in **Table 3**.

We could not analyze data on individual syndromes, as studies did not specify postoperative changes of specific component in neurological status.

Surgery time was reported in only 12 studies (232 patients). Transoral odontoidectomy proved to be the longest. Mean time in this group was 373.4±126 min, in the second group — 283±4.24 min, in the third group — 171.9±71.9 min. Transoral surgeries took significantly longer than other options ($p<0.05$, Mann–Whitney test).

Table 2. **Baseline data.**

Variable	Group 1 — transoral odontoidectomy (*n*=446)	Group 2 — transnasal odontoidectomy (*n*=192)	Group 3 — transcervical odontoidectomy (*n*=50)	*p-value*
Age, years	38.71±22.87	48.64±21.71	45.60±23.49	>0.05
Basilar impression, *n* (%)	60 (13.5)	62 (32.3)	32 (64)	<0.001
Basilar impression, *n* (%) + CVJ malformation, *n* (%)	253 (56.7)	72 (37.5)	4 (8)	<0.001
Trauma, *n* (%)	69 (15.5)	18 (9.4)	6 (12)	1 vs 2: <0.05 1 vs 3: >0.05 2 vs 3: >0.05
Degenerative diseases, *n* (%)	6 (1.3)	–	–	>0.05
Rheumatoid arthritis, *n* (%)	25 (5.6)	31 (16.1)	3 (6)	1 vs 2: <0.001 1 vs 3: >0.05 2 vs 3: >0.05
Others (chondrocalcinosis, *Os odentoideus*), *n* (%)	33 (7.4)	9 (4.7)	5 (10)	>0.05
Incidence of movement disorders, *n* (%)	254 (57)	150 (78.1)	27 (54)	1 vs 2: <0.001 1 vs 3: >0.05 2 vs 3: <0.001
Incidence of bulbar disorders, *n* (%)	75 (16.8)	63 (32.8)	4 (8)	<0.05
Incidence of pelvic disorders, *n* (%)	40 (9)	20 (10.4)	2 (4)	>0.05
Syringomyelia, *n* (%)	19 (4.3)	7 (3.6)	–	>0.05

Blood loss was presented in 10 studies. Mean blood loss for all groups was 234.2±138.2 ml (group 1: 280.8±138.4 ml; group 2: 185.5±135.39 ml; group 3: 327.5±55.25 ml). The difference was significant between groups 1 and 2, as well as between groups 2 and 3 ($p<0.05$, Mann–Whitney test).

Each approach is characterized by specific complications with various on postoperative quality of life.

The overall complication rate was 23%. Incidence and structure of complications are presented in **Fig. 2** and **Table 4**.

Local infectious complications were the most common in all groups (wound site inflammation, sinusitis). The pathogen was known in only two cases—methicillin-resistant Staphylococcus aureus.

Wound revision was required in 4% of cases after transoral odontoidectomy. Indications for re-intervention included: posterior pharyngeal wall defect closure, suspected diastasis of wound edges, wound debridement or additional resection of odontoid process. In the 2nd group, redo surgery was performed in 5.2% of cases for suture dehiscence on posterior pharyngeal wall and nasal cerebrospinal fluid leakage. In patients with cerebrospinal fluid leakage who did not undergo revision, this complication was managed using external lumbar drainage. There were no wound revisions in the 3rd group.

After transoral odontoidectomy, mean time to oral feeding was 4.07±2.33 days, and decannulation was performed after 10.3±3.65 days. After transnasal odontoidectomy, oral feeding was initiated after 3 postoperative days. In the 3rd group, this period was 1 day.

Length of hospital-stay was reported in 56 studies. Mean period until discharge was 16.85 days. Hospital-stay was significantly longer after transoral odontoidectomy (39.39±39.54 days, $p<0.05$, Mann–Whitney test). In groups 2 and 3, mean hospital-stay was 13.30±9.91 and 12.76±9.15 days, respectively ($p>0.05$, Mann–Whitney test).

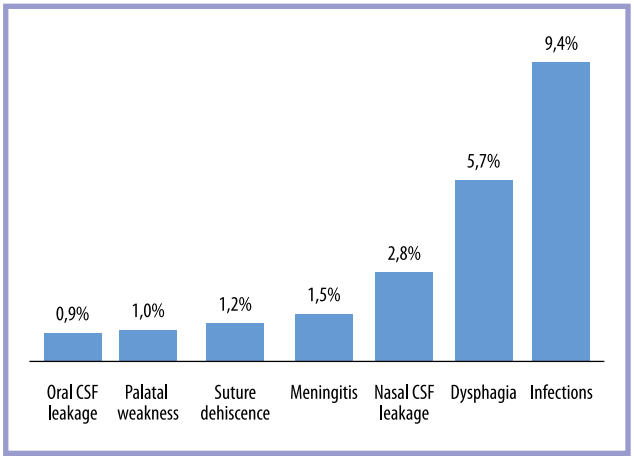

Fig. 2. **Incidence of complications in the overall patient group (*n*=688).**

The incidence of delayed complications was 4.9% (34 patients). They were more common in the 1st group (5.6%, 25 patients). There were infections, cerebrospinal fluid leakage, and autonomic dysfunction among late complications.

The overall mortality rate was 2.2% (mean follow-up 17.3 months). The causes were infectious complications and progression of neurological deficit secondary to the underlying malformation. There were no significant between-group differences in mortality.

Discussion

According to the WFNS Spine Committee recommendations (2025) [1], the role of odontoidectomy gradually diminishes as experience in treating patients with various

Table 3. **Clinical status depending on surgical approach.**

Group Dynamics	Group 1 — transoral odontoidectomy (*n*=446)	Group 2 — transnasal odontoidectomy (*n*=192)	Group 3 — transcervical odontoidectomy (*n*=50)	*p*-value
Complete regression, *n* (%)	43 (9.8)	32 (16.7)	6 (12)	1 vs 2: <0.05 1 vs 3: >0.05 2 vs 3: >0.05
Improvement, *n* (%)	339 (76)	138 (71.9)	42 (84)	>0.05
No changes, *n* (%)	44 (9.9)	15 (7.8)	2 (4)	>0.05
Deterioration, *n* (%)	8 (1.8)	4 (2.1)	0 (0)	>0.05
Mortality, *n* (%)	12 (2.7)	3 (1.6)	0 (0)	>0.05

CVJ pathologies accumulates. Distraction and fusion surgeries are more popular. However, resection is sometimes the only option for anterior brainstem decompression resulting from odontoid process displacement. We compared the results of odontoidectomy through various approaches in patients with various non-neoplastic diseases of CVJ.

The choice of approach for odontoidectomy depends on anatomical features of odontoid process, height of process above hard palate, degree of oral opening, planning of fusion surgery and preferable technique in a certain hospital. Transoral approach, as expected, turned out to be the most common that was anatomically justified. This access provides direct approach to pathological focus without contact with great vessels and cranial nerves. It is also convenient for microsurgical bimanual technique. However, postoperative features typical for transoral surgery (the need for tracheostomy or dissection of the lower jaw and tongue, delayed enteral nutrition and prolonged hospital-stay) became significant factors in favor of alternative approaches. In this regard, transoral odontoidectomy is significantly inferior to other options for odontoid process resection. Since 2005, transnasal approach has become preferable for odontoid process positioned high above the hard palate line [9]. Various transcervical approaches are also common (anterolateral, posterolateral retropharyngeal, posterior median one). Clinical outcomes of odontoidectomy through different approaches were comparable with clinical improvement in 89.2% of cases. Higher rate of complete recovery after transnasal odontoidectomy is most likely due to lower number of patients with CVJ injuries and malformations in this group. At the same time, surgical approach significantly impacts other perioperative parameters. Although transnasal odontoidectomy is significantly faster (283±4.24 min for transnasal versus 373.4±126 min for transoral procedure) and allows for earlier initiation of oral feeding and discharge of patients, the complication rate is twice as high as with transoral odontoidectomy (35.9 vs. 17.9%), and 3.5 times higher compared to transcervical odontoidectomy (35.9 vs. 10%). The main complications are local (including sinusitis) and generalized (meningitis) infections.

A typical complication of transoral neurosurgical interventions is suture dehiscence on posterior pharyngeal wall. According to our analysis, the incidence of such complications (1.3%) is lower compared to literature data including treatment of CVJ tumors (up to 8.2%) [8, 10]. This is most likely due to baseline intact posterior pharyngeal wall tissues in non-neoplastic CVJ lesions.

Table 4. **Incidence and structure of complications.**

	Group 1 — transoral odontoidectomy (*n*=446)	Group 2 — transnasal odontoidectomy (*n*=192)	Group 3 — transcervical odontoidectomy (*n*=50)	*p*-value
Oral cerebrospinal fluid leakage, *n* (%)	6 (1.3)	–	–	–
Nasal cerebrospinal fluid leakage, *n* (%)	–	19 (9.9)	–	–
Meningitis, *n* (%)	4 (0.9)	6 (3.1)	0	>0.05
Divergence of sutures on posterior pharyngeal wall, *n* (%)	6 (1.3)	2 (1)	0	>0.05
Local infection, *n* (%)	39 (8.7)	22 (11.5)	4 (8)	>0.05
Dysphagia, *n* (%)	19 (4.3)	19 (9.9)	1 (4)	1 vs 2: <0.05 1 vs 3: >0.05 2 vs 3: >0.05
Palatal weakness, *n* (%)	6 (1.3)	1 (0.5)	–	>0.05
Total number of complications, *n* (%)	80 (17.9)	69 (35.9)	5 (10)	1 vs 2: <0.05 1 vs 3: >0.05 2 vs 3: <0.05

Nasal complications are common in transnasal approach. Unfortunately, our analysis was unable to determine their incidence (other than infectious complications, including sinusitis). According to the literature, the incidence of complications such as nosebleeds and acute rhinosinusitis is 1.4% and 2%, respectively. Adhesions occur in 7.5% of cases, nasal septal perforation — in 2.2%, and up to 18.9% of patients require treatment for nasal crusting [11].

Transcervical approaches were the safest with overall complication rate of only 10% in this group. Surgical efficacy was comparable to classical odontoidectomy, and hospital-stay was the shortest.

The Burdenko Neurosurgery Center also has experience in transoral and transnasal odontoidectomies [12]. Our results and impressions from both approaches are consistent with those obtained in this study in virtually all respects. A significant difference was preferential tracheostomy in transoral procedures. Foreign colleagues prefer to expand transoral approach by incising the mandible, tongue, and hard palate instead of tracheostomy to avoid complications associated with this procedure. Furthermore, enlargement of transoral approach significantly reduces wound depth and improves convenience of all surgical stages, as well as orientation. In classic transoral approach, many factors influence midline perception in a narrow deep wound, including patient position on the table, head rotation, table tilt and position of surgeon relative to the patient. Consequently, deviation of even a few degrees can lead to error, especially due to altered anatomy complicating identification of classic midline landmarks such as tubercle on anterior semi-ring of CI vertebra and neck of odontoid process. Final stages of surgery, including posterior pharyngeal wall closure, are equally important. Enlargement of transoral approach allows for more effective tissue alignment that impacts suture dehiscence rate (8.3% in our experience versus 1.3% in the literature). However, traumatic nature of such procedures, in our opinion, remains a subject of debate.

Conclusion

The choice of approach for odontoidectomy significantly impacts surgery time, complication rates, time to oral feeding and hospital-stay. Results of transcervical approaches are interesting. They are followed by comparable clinical outcomes with the lowest complication rates and shorter hospital-stay. However, they have not been widely used for unclear reasons. The most common transoral approach is associated with low complication rate, but it is more difficult for patients and significantly increases hospital-stay without better clinical outcomes. A minimally invasive transnasal approach appears to be a reasonable and modern alternative to other options. However, high incidence of infectious complications requires further research regarding their prevention.

Author contribution:
Concept and design of the study — Chernov I.V., Shkarubo A.N., Kalinin P.L.
Collection and analysis of data — Chernov I.V., Konyashin A.D.
Data analysis — Kutin M.A., Fomichev D.V., Sharipov O.I., Andreev D.N., Donskoy A.D.
Writing the text — Chernov I.V.
Editing — Shkarubo A.N., Kalinin P.L., Kutin M.A., Fomichev D.V.

The authors declare no conflicts of interests.

REFERENCES

1. Botelho RV, Alves OL, Sá Carneiro G, Chen Z, Yaman O, Parthiban J, Visocchi M, Klekamp J, Goel A, Zileli M. Surgical Treatment of Basilar Invagination: WFNS Spine Committee Recommendations. *Spine.* 2025;50(11):751-759. https://doi.org/10.1097/BRS.0000000000005282
2. Alijani B, Namin AK, Emamhadi M, Chabok SY, Behzadnia H, Haghani Dogahe M. Endoscopic Endonasal Approach to the Craniovertebral Junction Lesions: A Case Series of 18 Patients. *Journal of Neurological Surgery Part B: Skull Base.* 2023;84(15):499-506. https://doi.org/10.1055/a-1924-8268
3. Chandra PS. Editorial: Are there any indications of transoral odontoidectomy today? *Neurosurgical Focus: Video.* 2020;3(1):V7. https://doi.org/10.3171/2020.4.FocusVid.20332
4. Rennert RC, Stephens ML, Palmer AW, Rodriguez A, Kazemi N, Morris TW 3rd, Pait TG, Day JD. Basilar decompression via a far lateral transcondylar approach: technical note. *Acta Neurochirurgica.* 2022;164(10):2563-2572. https://doi.org/10.1007/s00701-022-05312-9
5. Ariffin MH, Mohd-Mahdi SN, Baharudin A, M Tamil A, Abdul-Rhani S, Ibrahim K, Ng BW, Tan JA. Transtubular Transoral Approach for Irreducible Ventral Craniovertebral Junction Compressive Pathologies: Surgical Technique and Outcome. *Malaysian Orthopaedic Journal.* 2023;17(2):35-42. https://doi.org/10.5704/MOJ.2307.006
6. Ye J, Liu B, Li J, Zheng G, Duan K, Gao L, Zhang C, Huang J, Tang Y. Full-endoscopic uniportal retropharyngeal odontoidectomy: A preliminary case report. *Frontiers in Surgery.* 2023;9:973064. https://doi.org/10.3389/fsurg.2022.973064
7. Chen Z, Bi Z, Liu D, Deng B, Lu M, Zeng Y, Zhang X, Lin T. Endoscopic transnasal and transoral resection of the odontoid process and C1 combined with occipitocervical fusion for osteoradionecrosis of the upper cervical spine: a case report and literature review. *BMC Neurology.* 2024;24(1):421. https://doi.org/10.1186/s12883-024-03928-1
8. Zainudin NA, Muhamad Ariffin MH. A Transoral Approach to Decompression Odontoidectomy With Posterior Wiring and Fusion for Pediatric Platybasia With Chiari Malformation. *Cureus.* 2024;16(6):e62754. https://doi.org/10.7759/cureus.62754
9. Kassam AB, Snyderman C, Gardner P, Carrau R, Spiro R. The Expanded Endonasal Approach: A Fully Endoscopic Transnasal Approach and Resection of the Odontoid Process: Technical Case Report. *Neurosurgery.* 2005;57(1 Suppl):E213; discussion E213. https://doi.org/10.1227/01.NEU.0000163687.64774.E4
10. Chernov IV, Shkarubo AN, Konyashin DA, Andreev DN. Transoral approach in surgery for chordomas extending into craniovertebral junction: a systematic review of the literature. *Burdenko's Journal of Neurosurgery.* 2024;88(3):111-119. (In Russ., In Engl.). https://doi.org/10.17116/neiro202488031111

11. Gstrein NA, Zwicky S, Serra C, Hugelshofer M, Regli L, Soyka MB, Holzmann D, Meerwein CM. Rhinologic outcome of endoscopic transnasal-transsphenoidal pituitary surgery: an institutional series, systematic review, and meta-analysis. *European Archives of Oto-Rhino-Laryngology.* 2023;280(9):4091-4099. https://doi.org/10.1007/s00405-023-07934-w

12. Shkarubo AN, Nazarenko AG, Chernov IV, Andreev DN, Kuleshov AA, Konovalov NA, Lisyanskiy IN, Sinelnikov ME. Comparative analysis of endoscopic transnasal and microsurgical transoral odontoidectomy: Literature review and own experience. *N.N. Priorov Journal of Traumatology and Orthopedics.* 2023;30(1):41-62. (In Russ, In Engl.). https://doi.org/10.17816/vto321930

Received 16.10.2025
Revised 18.12.2025
Accepted 12.03.2026

COMMENT

This article analyzes international experience in odontoidectomy for various diseases. The authors conducted a thorough and in-depth analysis. References are systematized according to surgical approach that allowed for a detailed analysis of advantages and disadvantages of each approach. Analysis of literature data is highly scientifically valuable allowing for examination of appropriate problem from multiple perspectives. The manuscript is distinguished by clear structure and significant data, as well as reflects current trends in neurosurgery. This report will undoubtedly be of interest to professional neurosurgical community.

Cherebillo V. Yu. (St. Petersburg)