Burdenko's Journal of Neurosurgery
2026, No. 3, pp. 102–105
https://doi.org/10.17116/neiro202690031102

Extradural angiolipoma of the thoracic spine: a case report and literature review

© N.D. Shmelev[1], N.A. Konovalov[1], E.S. Brinyuk[1], S.V. Kaprovoi[1], R.A. Onoprienko[1], B.A. Zakirov[1], L.R. Gabrielyan[1], K.V. Kuzmina[2]

[1]Burdenko Neurosurgical Center, Moscow, Russia
[2]Sechenov First Moscow State Medical University, Moscow, Russia

ABSTRACT

Background. Spinal angiolipomas (SA) are rare primary tumors accounting for 0.14—1.2% of all spinal cord and spine tumors and approximately 3% of extradural spinal neoplasms (<0.1% of all primary CNS tumors). Histologically, SA consists of mature adipocytes and abnormally developed vessels. Clinical presentation of this tumor is due to severe spinal cord compression.

Material and methods. The authors present a 33-year-old patient with severe spinal cord compression who underwent resection of Th6-Th8 spinal angiolipoma. The Pubmed, Medline, EMBASE, Cochrane Library and eLibrary databases were screened using appropriate keywords.

Results and discussion. Extradural tumor > 5 cm causing severe dural sac compression was excised. In early postoperative period, there were complete regression of preoperative lower spastic paraparesis and gait improvement.

Conclusion. SAs are extremely rare, and their total resection with preservation or improvement of neurological status is possible in a specialized hospital.

Keywords: *extradural tumors, spinal angiolipomas, surgical treatment.*

INFORMATION ABOUT THE AUTHORS:
Shmelev N.D. — https://orcid.org/0009-0005-7058-902X
Konovalov N.A. — https://orcid.org/0000-0002-9976-948X
Brinyuk E.S. — https://orcid.org/0000-0001-6184-7481
Kaprovoi S.V. — https://orcid.org/0000-0001-8813-2793
Onoprienko R.A. — https://orcid.org/0000-0002-8637-9079
Zakirov B.A. — https://orcid.org/0000-0002-8782-850X
Gabrielyan L.R.— https://orcid.org/0009-0003-6787-9136
Kuzmina K.V. — https://orcid.org/0009-0006-3903-0954
Corresponding author: Shmelev N.D. — e-mail: shmelevnd@nsi.ru

TO CITE THIS ARTICLE:
Shmelev ND, Konovalov NA, Brinyuk ES, Kaprovoi SV, Onoprienko RA, Zakirov BA, Gabrielyan LR,Kuzmina KV. Extradural angiolipoma of the thoracic spine: a case report and literature review. *Burdenko's Journal of Neurosurgery.* 2026; 90(3):102–105. https://doi.org/10.17116/neiro202690031102

Abbreviations

SA — spinal angiolipoma

Introduction

SA is an extremely rare benign tumor accounting for 0.14—1.2% of all spinal cord and spine tumors and approximately 3% of extradural spinal neoplasms [1]. Histologically, SA consists of mature adipocytes and abnormally developed vessels. Symptoms of this tumor are caused by spinal cord compression with neurological disorders depending on level of lesion [2]. According to national and foreign literature, SAs are more common in thoracic spine (78%) and much less common in lumbar (10%), cervical and sacral (< 1%) segments [3]. To expand the global database, we present successful total resection of extradural angiolipoma Th6–Th8 in a 33-year-old female patient.

A 33-year-old patient presented with complaints of pain in thoracic and lumbar spine radiating to legs, as well as weakness and numbness in legs.

Interscapular pain first appeared three months ago. This was followed by weakness in legs with subsequent lower spastic paraparesis (grade 3), conduction-type hypoesthesia below Th6, thoracalgia, bilateral lumbosciatica and gait disturbance. At presentation, the patient was walking with great difficulty and required support.

Contrast-enhanced MRI of the thoracic spine revealed extradural tumor 5.35×2.18×1.49 cm at the level of ThVI–ThVIII vertebrae with severe spinal cord compression **(Fig. 1)**. After standard preoperative management, the patient underwent microsurgical resection of extradural tumor under neurophysiological monitoring.

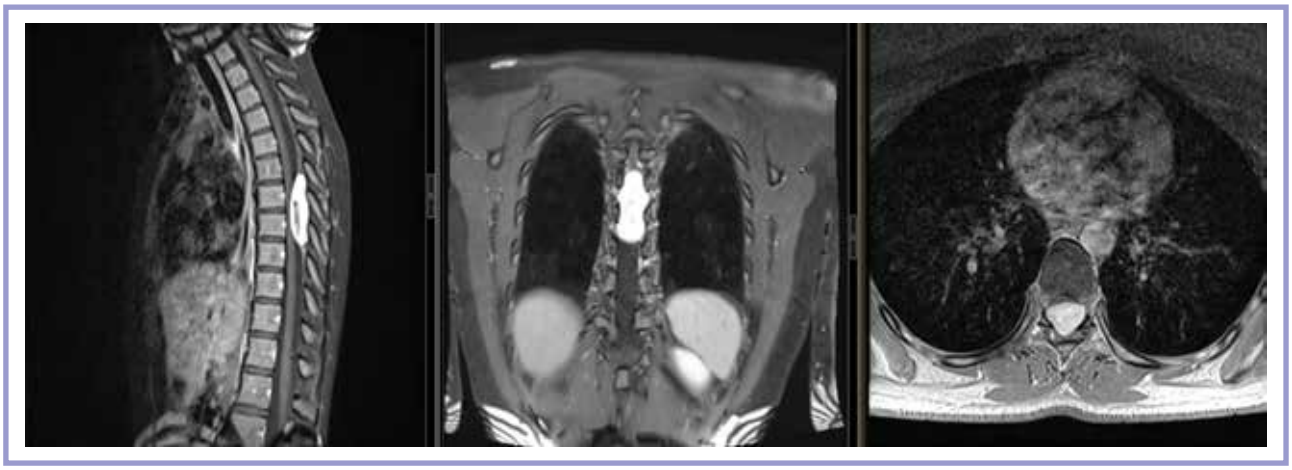

Fig. 1. **Preoperative contrast-enhanced MRI of the thoracic spine.**



Fig. 2. **Intraoperative image of extradural angiolipoma ThVI–ThVIII.**

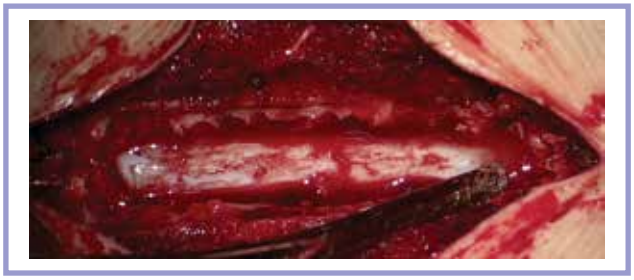

Fig. 3. **Intraoperative image of tumor bed after total resection.**

Surgical treatment

Surgery was performed under endotracheal anesthesia with total intravenous anesthesia and mechanical ventilation in prone position. After radiographic markings based on image intensifier, we performed linear skin incision along the midline in projection of ThVI–ThVIII vertebrae. Then, laminectomy ThVI–ThVIII was performed under microscope guidance using pistol-type nippers and high-speed burr. We visualized and resected the ligamentum flavum along bone window contour. Immediately beneath this ligament, we found a dark cherry-colored vascularized tumor compressing dura mater and spinal cord. The tumor occupied almost the entire lumen of spinal canal. Blood supply was through epidural vessels. We gradually cauterized and transected these vessels. Next, we mobilized the upper and lower tumor poles using microsurgical equipment **(Fig. 2)** with subsequent en bloc removal of neoplasm **(Fig. 3)**. Dural sac pulsation recovered after this maneuver. There was intraoperative monitoring of motor evoked potentials from lower extremity muscles. At baseline, transcranial motor evoked potentials were not recorded. Motor evoked potentials from muscles of the right leg occurred throughout tumor resection, from muscles of the left leg – at the end of surgery.

Morphological data

The tumor is represented by various-sized predominantly thin-walled vessels with mature adipocytes between them. There were also focal larger vascular cavities surrounded by hyalinized stroma. Morphological appearance is consistent with angiolipoma **(Fig. 4)**.

Postoperative period

There was favorable perioperative period. Three hours after surgery, partial regression of sensory disturbances in legs was noted. The patient was able to stand upright the day after surgery. Lower paraparesis gradually regressed within the next three days. The patient was discharged on the fourth postoperative day. Postoperative wound healed via primary intention without signs of inflammation. At discharge, she was walking independently, and gait fully recovered.

Discussion

We reviewed the PubMed, MEDLINE, EMBASE, Cochrane Library, and eLibrary databases using appropriate keywords.

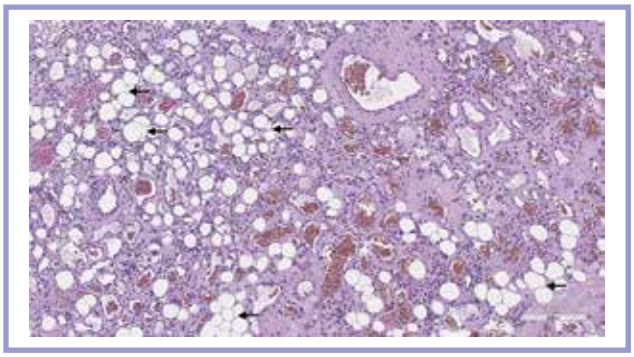

Fig. 4. **Microscopic appearance of tumor: vascular component with groups of adipocytes (black arrows). Stained with hematoxylin and eosin, ×100.**

SA was first described by Berenbruch in 1890 [4–6], and the term «spinal angiolipoma» was introduced in 1961 by Howard and Helwig [7]. Benvenutti-Regato M. et al. [8] reported 178 cases of SA in the world literature up to 2015. Lee S.H. et al. [9] additionally described 51 patients with SA between 2016 and 2023 that increased the total number to 229.

In 1974, Lin J.J. et al. [10] proposed a new classification of angiolipomas and divided them into two subtypes. The first most common type is an encapsulated angiolipoma without infiltration of surrounding tissues. Prognosis of surgical treatment is favorable. The second subtype is much less common (up to 20% of all angiolipomas) [11]. It is a non-encapsulated angiolipoma invading adjacent tissues all the way to spinal cord. Localization of angiolipomas is important in differentiating these subtypes. Almost all encapsulated angiolipomas are located in dorsal or dorsolateral space of spinal canal, while infiltrating angiolipomas invade surrounding tissues, including bones and spinal cord. SAs are most common in female patients (ratio 1:1.9) and usually manifest in the 4th or 5th decade of life [12].

Neurological symptoms caused by SA are not pathognomonic and correspond to typical signs of spinal cord lesion at certain level. Weakness in lower extremities, decreased sensitivity and numbness are the main manifestations. Progression of symptoms can vary significantly from back pain to acute lower paraplegia. According to some data, spine and spinal cord injuries, excess body weight and intake of hormonal medications contribute to SA growth [13]. Obesity and pregnancy can trigger SA due to hormonal changes stimulating proliferation of adipose tissue.

MRI is the «gold standard» in diagnosis of SA. This tumor is isointense on T1-weighted images, unlike other spinal tumors, and slightly hyperintense on T2-weighted images. Because SAs are highly vascularized and contain many fragments of adipose tissue, they are capable of accumulating contrast agent with hyperintense appearance on contrast-enhanced T1WI. Hyperintense pattern on contrast-enhanced T1WI indicates high vascularization.

Differential diagnosis should include lipoma, hemangioma, lymphoma, nerve sheath tumors, chronic extradural hematoma, metastases and epidural meningioma [12].

Histologically, SAs consist of mature adipocytes and blood vessels, and ratio of fat cells to vessels varies from 1:3 to 2:3. Tumors with abundant smooth muscle proliferation are classified as angiomyolipomas. A thin-walled capsule surrounding the tumor is found in many cases.

Conclusion

Spinal angiolipoma is an extremely rare benign slow-growing tumor composed of fat cells and blood vessels. In this case, we found an encapsulated non-infiltrating type of tumor. Total resection was followed by complete regression of neurological symptoms.

Author contribution:
Concept and design of the study — Konovalov N.A., Brinyuk E.S.
Collection and analysis of data — Brinyuk E.S., Shmelev N.D., Kaprovoy S.V.
Writing the text — Shmelev N.D., Kuzmina K.V.
Editing — Konovalov N.A., Onoprienko R.A., Brinyuk E.S.
The authors declare no conflicts of interests.

REFERENCES

1. Gelabert-González M, García-Allut A. Spinal extradural angiolipoma: report of two cases and review of the literature. *European Spine Journal.* 2009;18(3):324-335. https://doi.org/10.1007/s00586-008-0858-8
2. Kang HI, Kim TW, Kim EJ, Park KH. Angiolipoma on the Lumbar Spine. *Korean Journal of Spine.* 2017;14(3):112-114. https://doi.org/10.14245/kjs.2017.14.3.112
3. Rkhami M, Kedous MA, Achoura S, Zehani A, Bahri K, Zammel I. Epidural angiolipoma: A rare cause of spinal cord compression. *International Journal of Surgery Case Reports.* 2018;45:72-76. https://doi.org/10.1016/j.ijscr.2018.03.005
4. Berenbruch K. *Ein fall von multiplen angiolipomen kombiniert mit eniem angiom des ruckenmarks* [A case of multiple angiolipomas combined with an angioma of the spinal cord]. Tübingen: Lupp; 1890. (In Germ.).
5. Maduri R, Belouaer A, Brouland JP, Ecker T, Messerer M. Spinal angiolipomas in pregnancy: Natural history and surgical treatment. *Clinical Neurology and Neurosurgery.* 2019;178:25-30. https://doi.org/10.1016/j.clineuro.2019.01.015
6. Tseng SC, Hsieh CT, Chang CJ. Lumbar epidural angiolipoma: A rare case report. *Fu-Jen Journal of Medicine.* 2017;15:203-208. https://doi.org/10.3966/181020932017121504004
7. Howard WR, Helwig EB. Angiolipoma. *Archives of Dermatology.* 1960;82:924-931. https://doi.org/10.1001/archderm.1960.01580060078011
8. Benvenutti-Regato M, De la Garza-Ramos R, Caro-Osorio E. Thoracic epidural spinal angiolipoma with coexisting lumbar spinal stenosis: Case report and review of the literature. *International Journal of Spine Surgery.* 2015;9:67. https://doi.org/10.14444/2067

9. Lee SH, Bock MS, Sheen SH, Han I, Sohn S. Thoracic spinal angiolipoma: A case report and literature review. *The Nerve.* 2023;9(2):167-173. https://doi.org/10.21129/nerve.2023.00360

10. Lin JJ, Lin F. Two entities in angiolipoma. A study of 459 cases of lipoma with review of literature on infiltrating angiolipoma. *Cancer.* 1974;34(3):720-727. https://doi.org/10.1002/1097-0142(197409)34:3<720::aid-cncr2820340331>3.0.co;2-k

11. Kang JH, Lee HS, Jung DW, Ha DJ, Kwak JY, Kim UC. Infiltrating epidural angiolipoma involving lumbar spine. *Journal of the Korean Orthopaedic Association*. 2015;50(2):148-153. https://doi.org/10.4055/jkoa.2015.50.2.148

12. Benhayoun O, Makhchoune M, Jehri A, Yassine Haouas M, Hilmani S, Lakhdar A. Spinal extradural angiolipomas: A case report. *Annals of Medicine and Surgery.* 2021;65:102289. https://doi.org/10.1016/j.amsu.2021.102289

13. Guzey FK, Bas NS, Ozkan N, Karabulut C, Bas SC, Turgut H. Lumbar extradural infiltrating angiolipoma: a case report and review of 17 previously reported cases with infiltrating spinal angiolipomas. Spine J. 2007 Nov-Dec;7(6):739-44. https://doi.org/10.1016/j.spinee.2006.08.014. Epub 2007 Jan 3

Received 10.02.2026
Accepted 12.03.2026