Burdenko's Journal of Neurosurgery
2026, No. 3, pp. 94–99
https://doi.org/10.17116/neiro20269003194

Dural arteriovenous fistula of the craniovertebral junction with perimedullary venous drainage

© G.Yu. Evzikov, V.N. Argylova, A.Yu. Egorov

Sechenov First Moscow State Medical University, Moscow, Russia

ABSTRACT
This article presents definition, clinical course and distinctive features of dural fistulas of the craniovertebral junction. Anatomical and pathogenetic aspects of this pathology are discussed. The authors present a rare case of dural fistula of the craniovertebral junction. The article discusses diagnostic and treatment methods for dural fistulas of the craniovertebral junction. The most significant and favorable treatment options are described.

Keywords: *craniovertebral junction, dural arteriovenous fistula.*

INFORMATION ABOUT THE AUTHORS:
Evzikov G.Yu. — https://orcid.org/0000-0002-6715-6021
Argylova V.N. — https://orcid.org/0000-0003-1394-7773
Egorov A.Yu. — https://orcid.org/0009-0000-4608-923X
Corresponding author: Argylova V.N. — e-mail: argylova_v_n@staff.sechenov.ru

TO CITE THIS ARTICLE:
Evzikov GYu, Argylova VN, Egorov AYu. Dural arteriovenous fistula of the craniovertebral junction with perimedullary venous drainage. *Burdenko's Journal of Neurosurgery*. 2026;90(3):94–99. (In Russ.). https://doi.org/10.17116/neiro20269003194

Abbreviations

DAVF — dural arteriovenous fistula
CVJ — craniovertebral junction
SAH — subarachnoid hemorrhage
VHM — venous hypertensive myelopathy

DAVFs are acquired abnormal arteriovenous shunts in dura mater connecting meningeal arteries with dural sinuses and/or meningeal veins [1]. DAVFs can occur in various areas of dura mater of craniospinal cavity. CVJ lesion is very rare (<2% of DAVFs) [2].

Introduction

Pathogenesis of these fistulas is still unclear. Clinical manifestations of DAVFs are primarily related to venous outflow and cortical or perimedullary venous reflux [3, 4].

A special type of DAVF forms in CVJ. These fistulas can drain blood intracranially and into the spinal canal. This is due to the fact that the key anatomical components of CVJ are marginal sinus surrounding the margin of the foramen magnum and condylar venous complex (confluence of anterior and lateral condylar veins) around occipital condyle. These structures communicate extensively with inferior petrosal sinus, internal jugular vein bulb, basilar venous plexus and vertebral venous plexuses. This allows them to drain blood into intracranial venous system and spinal canal veins **(Fig. 1)** [5—7].

We present a rare case of DAVF at the craniovertebral junction with perimedullary venous drainage and focal venous hypertensive myelopathy at the level of cervical and upper thoracic spine. We were unable to find similar descriptions in Russian-language literature.

In September 2025, a 66-year-old patient presented with complaints of weakness in legs, numbness in lower abdomen and thighs, tingling sensation in toes, urinary retention and constipation. Clinical manifestation occurred in February 2023 with weakness in legs following long walks. He gradually developed unsteadiness while walking, tingling and pain in feet after walking. In April 2024, numbness in thighs developed, 2—4 months later — numbness in lower abdomen and sphincter dysfunction, including urinary retention and constipation. Another 2—3 months later, weakness and numbness in legs followed walking >200 m along with periodic tingling sensation in hands unrelated to physical exertion, deterioration of fine motor skills in hands.

Upon admission, there was clear consciousness and orientation in place and time. The patient actively communicated with physicians. There were no meningeal symptoms. Cranial innervation was normal. Muscle strength in the upper extremities was 5 points proximally

and distally. Lower extremities were characterized by spastic paraparesis up to 4 points proximally and distally. Muscle tone in lower extremities was increased. Tendon reflexes in the upper extremities: normal symmetrical carporadial ones, enhanced symmetrical biceps and triceps reflexes. There were high symmetrical reflexes from the lower extremities. The Babinski sign was positive on both sides. The upper Rossolimo's sign was positive on the left. Coordination tests demonstrated mild disorders. Superficial sensitivity was impaired in L3-L4 dermatomes (hypoesthesia along anterior surface of the left thigh, hyperesthesia along anterior surface of the middle third of both legs). Vibration sensitivity was decreased below iliac bones. Proprioceptive sensitivity in legs was impaired. The patient was unstable in the Romberg position. Pelvic dysfunction included intermittent urinary retention alternating with imperative urges and intermittent constipation. The patient was fully capable of self-care, but unable to perform professional activities (farmer) due to sensory ataxia, intermittent claudication and difficulties in fine hand movements.

MRI of the cervical and thoracic spine dated July 25, 2024 **(Fig. 2a, b)** revealed multiple hypointense areas in subarachnoid space on predominantly posterior surface of the spinal cord along its entire length («flow voids» phenomenon). There was a large focus of CVII-ThV myelopathy (enhanced signal on T2WI) without significant cross-sectional enlargement of spinal cord. MRI of the lumbar spine revealed abnormal tortuous vein at the level of conus and among the roots of the cauda equina (Th11-Th12) **(Fig. 2c)**.

Considering MR and clinical data, we established VHM at the cervical and upper thoracic levels, spinal dural arteriovenous fistula (?).

Selective digital spinal arteriography was performed on October 1, 2025. Considering spread of «flow voids» to the cervical spine and spinal cord, as well as localization of VHM within CVJ, we examined vertebral, occipital and ascending pharyngeal arteries to search for a high-lying DAVF.

There was abnormal filling of perimedullary veins through a fistula, whose afferent vessel arose from the right vertebral artery at the junction of segments V3 and V4. Sagittal flat-detector CT angiography revealed filling of superficial veins of dorsal surface of spinal cord. This was typical for spinal DAVF without signs of perimedullary fistula in anterior spinal artery **(Fig. 3)**.

On October 6, 2025, MRI of the cervical spine, spinal cord and CVJ was performed including thin-slice T2-weighted imaging for accurate localization of drainage vein exit site. Multiplanar reconstruction revealed an area suspicious for drainage vein located dorsolateral to the right relative to the brain at the level of CVJ **(Fig. 4)**.

The patient underwent surgery on October 9, 2025 (C1 laminectomy with resection of the right half of the arch and lower squama of the occipital bone on the right 3×3 cm). We dissected dura mater using semi-oval incision with the base to the right. After opening the arachnoid membrane, we examined lateral surface of the spinal cord at the level of C1 segment and lower part of medulla oblongata. There was a drainage vein passing into vascular conglomerate on lateral surface of the brain. The last one was represented by veins filled with arterial blood. Fistula in dura mater was localized dorsolaterally at the level of lateral surface of the right cerebellar tonsil. In addition to patent drainage vein, we observed a thrombosed sclerotic vein with a rounded aneurysmal enlargement. This vein passed onto posterolateral surface of the brain immediately below the tonsil **(Fig. 5a)**. We transected the sclerosed vein, mobilized from arachnoid adhesions, cauterized and transected patent drainage vein **(Fig. 5b-d)**. After transecting the drainage vein, the veins forming vascular conglomerate on lateral surface of the brain changed color and became deserted. Posterior radiculae of the right C2 root became clearly visible in the wound **(Fig. 5d)**. Dura mater suturing was followed by wound closure in layer-by-layer fashion. Postoperative period was uneventful. There was postoperative regression of paresthesia in the upper extremities, improvement of proprioceptive sensitivity in the lower extremities and gait. The wound healed via primary intention.

On the 11th day after surgery, the patient was transferred to the rehabilitation department. Under rehabilitation measures, further improvement of sensitivity, walking stability and exercise tolerance was noted. We objectively clinical status using international scales. Upon admission, functional status corresponded to mRS grade III–IV and ASIA grade D. The total JOA score for spinal myelopathy was 10 points. At discharge after surgery and rehabilitation, mRS score improved to grade II, ASIA grade

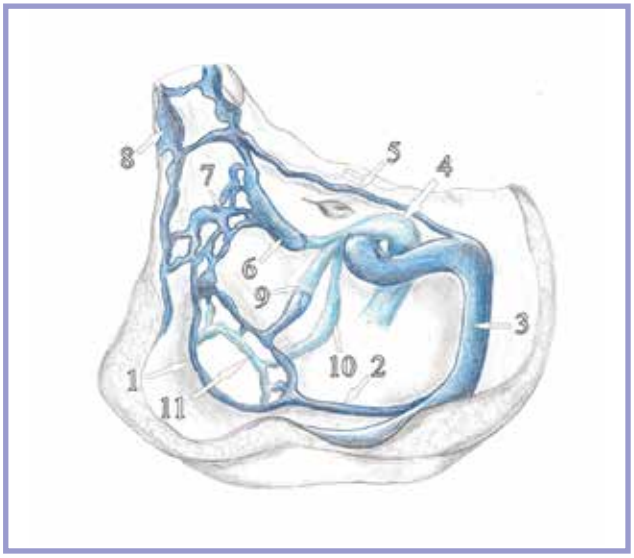

Fig. 1. **Skull base sinuses and veins associated with craniovertebral junction.**
1 — marginal sinus; 2 — occipital sinus; 3 — right transverse sinus; 4 — internal jugular vein bulb; 5 — superior petrosal sinus; 6 — inferior petrosal sinus; 7 — basilar venous plexus (venous plexus of Blumenbach clivus); 8 — posterior parts of cavernous sinuses; 9 — anterior condylar vein; 10 — lateral condylar vein; 11 — epidural venous plexus of spinal canal.



Fig. 2. **Sagittal T2WIs.**
a — CVJ, cervical and upper thoracic spine. Multiple flow voids are visible throughout the entire region of interest on posterior surface of the brain; focal myelopathy (enhanced MR signal) is visible at the level of CVII-ThV in spinal cord tissue without significant cross-sectional enlargement of spinal cord; b — thoracic spine. Multiple flow voids are visible throughout the study area; c — lumbosacral spine. A dilated tortuous vein is visible at the level of Th11-Th12.

D was stable, and JOA score increased to 14 points. These data corresponded to good recovery according to the Hirabayashi criteria (approximately 55% of baseline deficit).

Discussion

Marginal sinus is the main venous structure of CVJ. It is an important structure forming connections between intracranial sinuses and vertebral venous plexuses. Blood drainage from adjacent DAVFs can occur both intracranially and into spinal canal, including perimedullary venous plexus. Importantly, internal and external venous spinal plexuses form a valveless bidirectional blood flow system with low peripheral resistance. Therefore, connection of plexuses with marginal sinus allows for blood outflow into spinal canal and perimedullary veins, even from low-flow fistulas at the level of the foramen magnum [5—7].

Highly variable structure of valveless epidural venous network of the spinal canal and its connection with perimedullary venous plexus of the spinal cord determines different patterns of venous drainage through the plexuses and variable clinical manifestations of spinal cord damage in DAVFs of CVJ [5, 6].

Arterial afferents for DAVF of CVJ usually arise from meningeal branches of ascending pharyngeal artery, meningeal branches of occipital artery and segments V3—V4 of vertebral artery [8, 9]. Venous outflow from such fistulas can be via the jugular vein and/or vertebral plexus or accompanied by retrograde venous reflux into intracranial dural sinuses. Venous outflow from DAVF can also include blood drainage into cortical or perimedullary veins through the bridging or radicular veins (bypassing the sinuses) and retrogradely through dural sinuses and veins draining into the sinuses. Blood outflow into perimedullary veins of the spinal cord is unfavorable regarding clinical course. It is associated with the risk of VHM and progressive neurological impairment [1, 4, 8, 10].

To stratify the risk of various complications of DAVF, specialists use the classifications by J.A. Borden (1995) [3, 11] and C. Cognard (1995) [4, 11]. These grading systems are based on patterns of venous outflow/reflux and venous ectasia.

The classification by J.A. Borden includes the following grades:

I — blood outflow into dural sinus or meningeal veins without cortical venous reflux;
II — blood outflow into dural sinuses with retrograde reflux into cortical veins;
III — direct cortical venous outflow (without sinus involvement).

Direct outflow into perimedullary veins is possible for CVJ [2].

The classification by C. Cognard includes the following grades:

I — antegrade blood outflow through the sinuses;
IIa — retrograde sinus reflux;
IIb — outflow into the sinus with cortical venous reflux;
IIa+b — combination of retrograde sinus reflux and blood backflow into cortical veins;

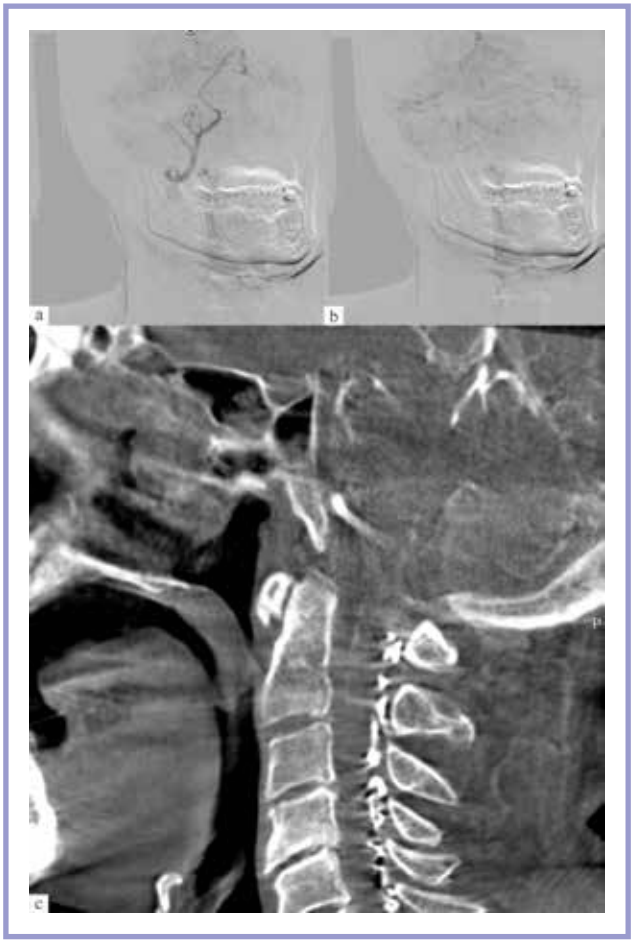

Fig. 3. **Angiography.**
a — selective contrast enhancement of the right vertebral artery; blood drainage into dilated and tortuous veins of perimedullary plexus is visible; b — delayed phase; no contrast enhancement of the artery with stable contrast enhancement of perimedullary venous plexus; c — FD CT angiography in delayed phase; contrast enhancement of dilated veins of perimedullary plexus is visible only along posterior surface of spinal cord..

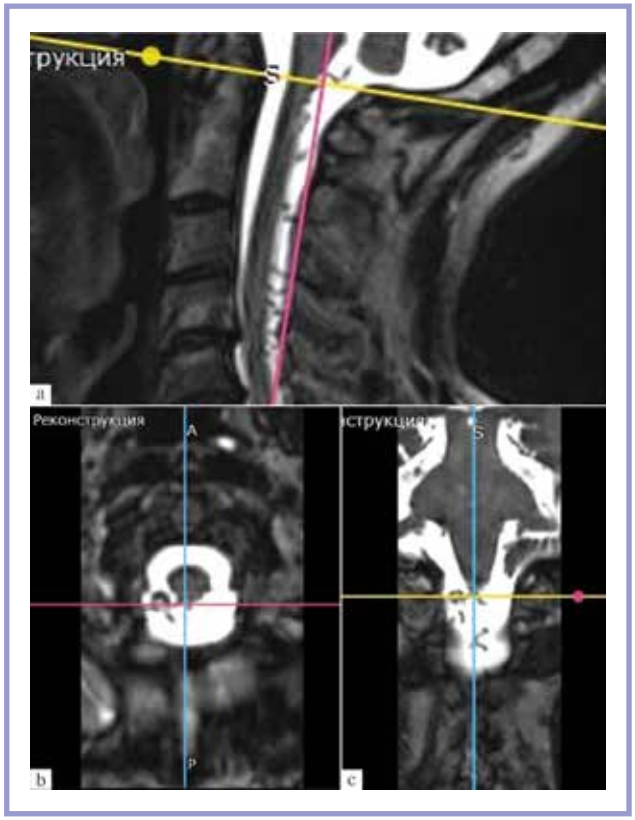

Fig. 4. **Thin-slice MRI (T2WI) of CVJ, multiplanar reconstruction.**
a — slice plane projection (yellow line) shows that this vessel is located precisely in projection of the foramen magnum; b, c — axial and frontal scans demonstrate a region suspected of the right drainage vein.

III — direct cortical outflow;
IV — direct cortical outflow with venous ectasia;
V — perimedullary venous outflow (spinal type).

Borden type III and Cognard type IV / V are associated with the highest risk of severe focal neurological symptoms due to venous hypertension and decreased brain perfusion. Clinical manifestation of fistulas through SAH is almost always associated with cortical outflow and dilation of superficial cerebral veins (Cognard type IV) [8].

In case of perimedullary outflow from CVF fistulas, venous hypertension manifests with clinical signs of damage to medulla oblongata and/or cervical and upper thoracic spinal cord segments. Neurological status includes gait disturbance due to sensory ataxia, tetraparesis with spasticity in legs, sensory disturbances corresponding to focal myelopathy and bulbar syndrome including various manifestations of dysphagia, dysphonia and dysarthria associated with venous dyscirculation in medulla oblongata.

Our patient had fistula Borden type III and Cognard type V, i. e. unfavorable clinical course associated with direct arteriovenous outflow into perimedullary veins of the spinal cord. Importantly, direct outflow into cerebral veins and/or perimedullary plexus is quite common in patients with DAVFs of CVJ. This emphasizes high risk for patients with these fistulas [2].

Unlike CVJ fistulas, «classic» spinal DAVFs are usually located at the lower thoracic and/or lumbar level. Arteriovenous fistula occurs in the area of dural root sleeve. Blood outflow occurs into perimedullary venous plexus of the lower thoracic spinal cord and veins of the cauda equina. Focal VHM forms in lower part of the thoracic spinal cord, lumbar enlargement and conus [12]. Clinical manifestations include intermittent claudication, lower paraparesis, sphincter dysfunction, and sensory disturbances predominantly in legs.

In our patient, high localization of fistula was accompanied by distal arm involvement. This is atypical for spinal dural fistulas.

DAVFs of CVJ require active surgical approach. Spontaneous closure of arteriovenous fistula was described only for fistulas with antegrade outflow (type I). This justifies follow-up for eligible patients without neurological symptoms [9].

The primary goal of treating DAVF is total disruption of abnormal venous outflow through open or endovascular occlusion of arteriovenous fistula.

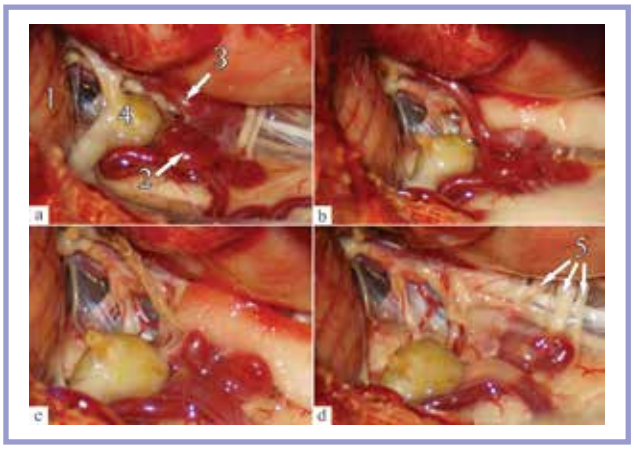

Fig. 5. **Intraoperative images. Surgery in ParkBench position on the left side.**
a — after opening the dura mater, we visualized inferior margin of the right tonsil (1), ascular tangle on lateral surface of the brain in projection of C1–C2 segments (2), drainage vein (3), empty sclerotic vein with aneurysmal dilation extending from the fistula (4); b — empty sclerotic vein is transected; drainage vein is mobilized from arachnoid adhesions, and a cotton wool pad is placed under it; c — drainage vein is cauterized; d — drainage vein is transected; vascular tangle of veins is collapsed and empty; posterior radiculae of the C2 root are exposed in the wound (5).

Transvenous embolization is the first-line treatment for CVJ lesions with blood flow into condylar venous complex and accessible venous route (usually through internal jugular vein bulb). This method ensures high rate of endovasal occlusion with low incidence of perioperative complications [9].

Transarterial embolization is preferable in patients without safe venous route or as a component of hybrid strategy. Modern embolic materials include ethylene vinyl alcohol copolymers (EVOH: Onyx, Squid) and *n*-butyl cyanoacrylate (*n*-BCA). Cohort studies of cranial DAVFs demonstrated a tendency towards more stable occlusion with Onyx compared to *n*-BCA [13]. There are no similar studies for CVJ fistulas due to their rarity.

A multiple-center comparative study of DAVFs of CVJ demonstrated the advantage of microsurgical disconnection regarding stable occlusion and lower need for repeat procedures compared to endovascular approach alone [14, 15].

Exclusion (transection or clipping) of drainage vein of the fistula is optimal surgical treatment in case of predominant drainage into perimedullary venous network. This intervention eliminates perimedullary reflux, normalizes venous pressure in spinal cord vessels and relieves VHM. A far lateral suboccipital approach is proposed to access the drainage vein near CVJ [16]. We performed only lateral suboccipital craniotomy without mobilization of vertebral artery. This also allowed for full visualization of drainage vein from its exit from dura mater to posterolateral surface of the spinal cord at its transition into perimedullary plexus.

Complex angioarchitecture of DAVF can require a combined treatment including transarterial embolization at the first stage and surgical disconnection at the second one.

Stereotactic radiosurgery is considered a reserve method for DAVF (including residual fistulas). This approach is not used as a routine first-line treatment for perimedullary outflow due to long period between irradiation and occlusion, as well as aggressive course of most DAVFs of CVJ [10].

Analysis of treatment outcomes in patients with DAVFs of CVJ demonstrate that perimedullary outflow with gradual development of neurological symptoms is associated with slower and more incomplete regression of neurological deficit. At the same time, SAH at the onset of disease is often accompanied by better functional recovery after closure of fistula [17].

Conclusion

Dural arteriovenous fistulas of craniovertebral junction are a rare group of fistulas with difficult diagnosis and prognosis of clinical course. These fistulas can cause blood flow into venous collectors of the brain and/or spinal cord. Blood flow into perimedullary venous plexus of the spinal cord in these fistulas is a risk factor of unfavorable clinical course. It is associated with high risk of venous hypertensive myelopathy with damage to medulla oblongata and cervical spinal cord. «Flow voids» throughout the spinal cord complicate searching for arterial afferents of the fistula. Indeed, as the vast majority of spinal DAVFs are located in the lower thoracic and lumbar regions of the spinal cord, endovascular surgeons often focus on finding the afferent artery in this region. Despite the rarity of fistulas with perimedullary drainage near craniovertebral junction, angiographic examination of vertebral, occipital and ascending pharyngeal arteries is mandatory when searching for afferent artery in patients with venous hypertensive myelopathy and flow voids extending into cervical spinal cord.

When choosing treatment strategy, it is important to consider that transection of drainage vein is a technically simple and effective procedure eliminating pathological blood flow from fistula into spinal venous system.

Author contribution:
Concept and design of the study — Evzikov G.Yu.
Collection and analysis of data — Argylova V.N., Egorov A.Yu.
Statistical analysis — Argylova V.N.
Writing the text — Argylova V.N., Egorov A.Yu.
Editing — Evzikov G.Yu.

The authors declare no conflicts of interests.

REFERENCES

1. Alkhaibary A, Alnefaie N, Alharbi A, Alammar H, Arishy AM, Alshaya W, Khairy S. Intracranial dural arteriovenous fistula: a comprehensive review of the history, management, and future prospective. *Acta Neurologica Belgica*. 2023;123(2):359-366. https://doi.org/10.1007/s13760-022-02133-6
2. Qedair J, Sankarappan K, Mirahmadi Eraghi M, Gersey ZC, Agarwal P, Anand SK, Palmisciano P, Blackwell M, Maroufi SF, Aoun SG, El Ahmadieh TY, Cohen-Gadol AA, Bin-Alamer O. Dural arteriovenous fistulas at the craniocervical junction: a systematic review and meta-analysis. *Neurosurgical Review*. 2024;47(1):812. https://doi.org/10.1007/s10143-024-03018-3
3. Borden JA, Wu JK, Shucart WA. A proposed classification for spinal and cranial dural arteriovenous fistulous malformations and implications for treatment. *Journal of Neurosurgery*. 1995;82(2):166-179. https://doi.org/10.3171/jns.1995.82.2.0166
4. Cognard C, Gobin YP, Pierot L, Bailly AL, Houdart E, Casasco A, Chiras J, Merland JJ. Cerebral dural arteriovenous fistulas: clinical and angiographic correlation with a revised classification of venous drainage. *Radiology*. 1995;194(3):671-680. https://doi.org/10.1148/radiology.194.3.7862961
5. Hiramatsu M, Ozaki T, Tanoue S, Mizutani K, Nakamura H, Tokuyama K, Sakata H, Matsumaru Y, Nakahara I, Niimi Y, Fujinaka T, Kiyosue H. Detailed anatomy of bridging veins around the foramen magnum: a multicenter study using three-dimensional angiography. *Clinical Neuroradiology*. 2024;34(1):67-74. https://doi.org/10.1007/s00062-023-01327-6
6. Ozaki T, Hiramatsu M, Nakamura H, Niimi Y, Tanoue S, Mizutani K, Nakahara I, Matsumaru Y, Matsumoto Y, Krings T, Fujinaka T. Classification, angioarchitecture and treatment outcomes of medullary bridging vein-draining dural arteriovenous fistulas in the foramen magnum region: a multicenter study. *Neuroradiology*. 2025;67:213-225. https://doi.org/10.1007/s00234-024-03478-w
7. Hiramatsu M, Ozaki T, Aoki R, Oda S, Haruma J, Hishikawa T, Sugiu K, Date I. Non-sinus-type dural arteriovenous fistula at the foramen magnum: a review of the literature. *Journal of Neuroendovascular Therapy*. 2025;19(1):ra.2023-0019. https://doi.org/10.5797/jnet.ra.2023-0019
8. Hu Y, Qian D, Leng B. Unfavorable neurological outcomes after treatment of craniocervical junction arteriovenous fistulas. *J Neurosurg*. 2024;141(3):760–768. https://doi.org/10.3171/2023.11.JNS232265
9. Su H, Yu J. Treatment of high cervical arteriovenous fistulas in the craniocervical junction region. *Frontiers in Neurology*. 2023;14:1164548. https://doi.org/10.3389/fneur.2023.1164548
10. Raki C, Davies L, Munasinghe T, Holona N, Lai L. Treatment outcomes for cranial dural arteriovenous fistulas: systematic review and meta-analysis of microsurgical, endovascular, and radiosurgical monotherapy. *J Clin Neurosci*. 2025;132:110942. https://doi.org/10.1016/j.jocn.2025.110942
11. Song Z, Ma Y, Wang Y, He C, Li G, Zhang P, Hong T, Sun L, Hu P, Ye M, Zhang H. Arteriovenous fistulas in the craniocervical junction region: with vs. without spinal arterial feeders. *Frontiers in Surgery*. 2023;9:1076549. https://doi.org/10.3389/fsurg.2022.1076549
12. Krings T, Geibprasert S. Spinal dural arteriovenous fistulas. American *Journal of Neuroradiology*. 2009;30(4):639-648. https://doi.org/10.3174/ajnr.A1485
13. Murai S, Hishikawa T, Hiramatsu M, Haruma J, Sugiu K, Iihara K, Imamura H, Ishii A, Matsumaru Y, Sakai C, Satow T, Yoshimura S, Sakai N; Japanese Registry of Neuroendovascular Therapy Investigators; JR-NET2 Study Group:; JR-NET3 Study Group:; JR-NET4 Study Group:. Thirteen-Year Trends and Advancements of Endovascular Therapy for Dural Arteriovenous Fistulas in Japan: Insights from a Nationwide Study of 6470 Procedures. *American Journal of Neuroradiology*. 2025;46(11):2273-2278. https://doi.org/10.3174/ajnr.A8840
14. Musmar B, Roy JM, Orscelik A, Koduri S, Karadimas S, Sizdahkhani S, Atallah E, Tjoumakaris SI, Gooch MR, Zarzour H, Ghosh R, Schmidt RF, Rosenwasser RH, Jabbour P. Comparative outcomes of endovascular vs. surgical treatment in craniocervical junction dural arteriovenous fistulas: A systematic review and meta-analysis. *Journal of the Neurological Sciences*. 2025;470:123402. https://doi.org/10.1016/j.jns.2025.123402
15. Iampreechakul P, Wangtanaphat K, Wattanasen Y, Hangsapruek S, Lertbutsayanukul P, Siriwimonmas S. Dural arteriovenous fistula of the craniocervical junction along the first cervical nerve: A single-center experience and review of the literature. *Clinical Neurology and Neurosurgery*. 2023;224:107548. https://doi.org/10.1016/j.clineuro.2022.107548
16. Wang Y, Ma Y, Song Z, Yang C, Tu T, Yang K, He C, Li G, Hu P, Sun L, Ye M, Zhang H. Clinical and prognostic features of venous hypertensive myelopathy from craniocervical arteriovenous fistulas: a retrospective cohort study. *Journal of Neurosurgery*. 2023;139(3):687-697. https://doi.org/10.3171/2022.11.JNS221959
17. Ma Y, Song Z, Wang Y, Wang J, He C, Li G, Zhang P, Hong T, Sun L, Hu P, Ye M, Zhang H. Clinical features, treatment strategies and outcomes of craniocervical junction arteriovenous fistulas: a cohort study of 193 patients. *Stroke and Vascular Neurology*. 2024;9(1):18-29. https://doi.org/10.1136/svn-2023-002436

Received 08.12.2025
Accepted 12.03.2026