Burdenko's Journal of Neurosurgery
2026, No. 3, pp. 86–91
https://doi.org/10.17116/neiro20269003186

Multidisciplinary approach to the treatment of aggressive growth hormone releasing adenoma: a case report

© G.D. Gabaidze[1], L.G. Ebanoidze[1], D.V. Lisina[1], L.K. Dzeranova[1], E.A. Pigarova[1], E.G. Przhiyalkovskaya[1], A.Yu. Grigoriev[1], M.A. Perepelova[1], A.A. Kolomeytseva[2], L.I. Astafyeva[3], T.M. Alexeeva[4], G.L. Kobyakov[3, 5], M.A. Kutin[3], A.P. Kononykhina[3]

[1]Endocrinology Research Centre, Moscow, Russia;
[2]Herzen Moscow Oncology Research Institute, Moscow, Russia;
[3]Burdenko Neurosurgical Center, Moscow, Russia;
[4]Endocrinology Dispensary, Moscow, Russia;
[5]Botkin Hospital, Moscow, Russia

ABSTRACT

Background. Despite available modern therapeutic options for acromegaly, resistant and aggressive forms of growth hormone releasing adenoma remain a significant clinical challenge with unsatisfactory outcomes.

Material and methods. The authors present a young patient with invasive growth hormone releasing adenoma characterized by aggressive growth, high proliferation index and previously unreported TP53 gene mutation, PD-L1 and VEGF expression, resistance to somatostatin analogues and no disease control despite combined therapy including growth hormone receptor antagonist.

Results. A patient with aggressive somatotropinoma experienced tumor growth despite previous neurosurgical interventions, radio- and chemotherapy, as well as targeted therapy. External beam radiation therapy is recommended as the only treatment option. The authors also examine aspects of multidisciplinary approach, results of antiangiogenic, chemo- and immunotherapy with immune checkpoint inhibitors when neurosurgery, traditional medications, and radiotherapy are ineffective.

Conclusion. This case underscores the necessity of extended immunohistochemical profiling and molecular genetic sequencing of pituitary tumors to facilitate development of personalized therapeutic strategies for aggressive somatotropinomas refractory to standard treatment modalities.

Keywords: *acromegaly, aggressive pituitary adenoma, somatotropinoma, first-generation somatostatin analogues, growth hormone receptor antagonist, chemotherapy, anti-VEGF, immune checkpoint inhibitor, TP53 gene mutation.*

INFORMATION ABOUT THE AUTHORS:
Gabaidze G.D. — https://orcid.org/0009-0007-6576-3876
Ebanoidze L.G. — https://orcid.org/0009-0002-3625-6289
Lisina D.V. — https://orcid.org/0000-0002-1006-6068
Dzeranova L.K. — https://orcid.org/0000-0002-0327-4619
Pigarova E.A. — https://orcid.org/0000-0001-6539-466X
Przhiyalkovskaya E.G. — https://orcid.org/0000-0001-9119-2447
Grigoriev A.Yu. — https://orcid.org/0000-0002-9575-4520
Perepelova M.A. — https://orcid.org/0000-0001-5824-6490
Kolomeytseva A.A. — https://orcid.org/0000-0002-6762-9511
Astafyeva L.I. — https://orcid.org/0000-0003-4480-1902
Alexeeva T.M. — https://orcid.org/0000-0003-0066-845X
Kobyakov G.L. — https://orcid.org/0000-0002-7651-4214
Kutin M.A. — https://orcid.org/0000-0002-6520-4296
Kononykhina A.P. — https://orcid.org/0000-0002-6043-3575
Corresponding author: Gabaidze G.D. — e-mail: mrkingdom444@gmail.com

TO CITE THIS ARTICLE:
Gabaidze GD, Ebanoidze LG, Lisina DV, Dzeranova LK, Pigarova EA, Przhiyalkovskaya EG, Grigoriev AYu, Perepelova MA, Kolomeytseva AA, Astafyeva LI, Alexeeva TM, Kobyakov GL, Kutin MA, Kononykhina AP. Multidisciplinary approach to the treatment of aggressive hormone releasing adenoma: a case report and literature review. *Burdenko's Journal of Neurosurgery*. 2026;90(3):86—91. (In Russ.). https://doi.org/10.17116/neiro20269003186

Introduction

Acromegaly is a slowly progressive disabling neuroendocrine disorder caused by chronic hypersecretion of growth hormone (GH) and, consequently, elevated levels of insulin-like growth factor 1 (IGF-1). In most patients with complete physiological growth, the cause of this disease is GH-releasing pituitary adenoma [1].

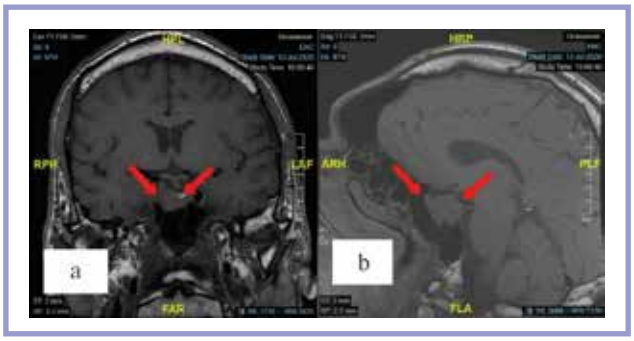

Fig. 1. **Brain magnetic resonance imaging.**
a — coronal T1WI; b — sagittal T1WI. Cystic-solid lesion (with predominant cystic component) 16×22×17 mm is visualized. The lesion deforms the medial wall of the right cavernous sinus.

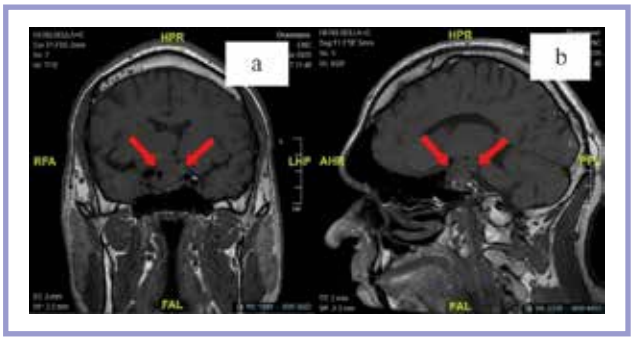

Fig. 2. **MRI of the brain.**
a — coronal T1WI; b — sagittal T1WI. Heterogeneous cystic-solid tumor 48×32×56 mm with sedimentation line in the area of cystic component (likely due to hemorrhage).

The prevalence of GH-releasing pituitary adenomas among aggressive pituitary tumors ranges from 4.5% to 31%. Such a wide variability in epidemiological data is explained by the lack of specific biomarkers and standardized criteria for assessing the aggressiveness of pituitary neuroendocrine tumors [2].

According to current international guidelines, transnasal transsphenoidal adenomectomy is the first-line treatment for patients with active acromegaly. The effectiveness of surgical treatment is 75—90% for microadenomas (<10 mm) and 40—60% for macroadenomas (⩾10 mm) [3].

Drug therapy (second-line therapy) is used if surgery is impossible or ineffective.

First-generation long-acting somatostatin analogues (ACC-1, octreotide/lanreotide) provide biochemical control of disease in 30—50% of patients and contribute to tumor shrinkage in 70% of cases [4]. The growth hormone antagonist pegvisomant demonstrates the highest efficacy (62—73%). However, pegvisomant monotherapy does not eliminate the risk of continued adenomatous tissue growth [5].

Radiotherapy (third-line), primarily stereotactic radiosurgery, is recommended without remission of acromegaly after drug and neurosurgical treatment. However, treatment is associated with risk of hypopituitarism, neurological complications and secondary brain tumors.

Antiangiogenic and chemotherapy, as well as oncoimmunotherapy with immune checkpoint inhibitors (ICIs) are perspective for stable biochemical remission of acromegaly, as well as reduction or stabilization of size of aggressive GH-releasing pituitary adenomas [6].

In 2019, a 36-year-old patient first admitted to the Dedov Endocrinology Research Center with active acromegaly.

There was family history of tall stature. Three brothers and paternal great-grandfather were over 200 cm tall, and the patient's grandfather was 190 cm tall. The patient himself reached 207 cm by 20 years.

Examination results: IGF-1 — 960.3 ng/ml (82.0—283.0), GH — 28.20 ng/ml (0.02—1.23), prolactin — 395 mIU/l (78—380). Contrast-enhanced MRI of the brain revealed pituitary macroadenoma 24×37×28 mm with suprasellar, infrasellar and parasellar extension (Knosp IV). Ophthalmological examination revealed partial optic nerve atrophy and secondary strabismus (inferior oblique muscle paresis). Perimetry revealed no visual field loss.

In December 2019, transnasal transsphenoidal adenomectomy was performed at the Burdenko Neurosurgery Center. Morphological examination revealed pituitary tumor fragments consisting of solid cells with chromophobe cytoplasm and 1 mitosis figure.

Immunohistochemical data were consistent with sparsely granulated GH-releasing pituitary adenoma: weak cytoplasmic staining of a few tumor cells with antibodies to GH and low-molecular-weight cytokeratin (CAM 5.2) (in two studies). Pit-1 expression was observed in most tumor cells. There was no expression of prolactin (IRS score 0) or somatostatin receptors subtype 2 (CCP-2). We found weak expression of somatostatin receptors subtype 5 (CCP-5) on membrane of a few tumor cells (IRS score 1). High Ki-67 index (17.0%) was observed.

In April 2020, therapy with long-acting octreotide 30 mg once every 28 days was initiated due to no remission after neurosurgical treatment (IGF-1 584.4 ng/ml (96.4—227.8)). MRI in July 2020 revealed residual tumor tissue 16×22×17 mm with endo-, supra-, latero- (D, Knosp II) and infrasellar spread **(Fig. 1)**.

Laboratory testing in July 2020 revealed no acromegaly remission: IGF-1 549.5 ng/ml (82.0—283.0). Brain MRI demonstrated a solid lesion 23×19×11 mm. Since August 2020, octreotide has been replaced with long-acting lanreotide 120 mg once every 28 days. In addition, persistent course of disease necessitated pegvisomant 10 mg with subsequent dosage increase to 15 mg daily after 2 months.

Redo transnasal transsphenoidal adenomectomy was performed at the Dedov Endocrinology Research Center in April 2021 due to ineffective neurosurgical treatment, continued growth of pituitary tumor and resistance to drug therapy. Intraoperative characteristics of tumor (significant tissue bleeding, invasion into the right cavernous sinus and close contact of suprasellar component with anterior cerebral artery) justified partial resection of adenoma. Morphological

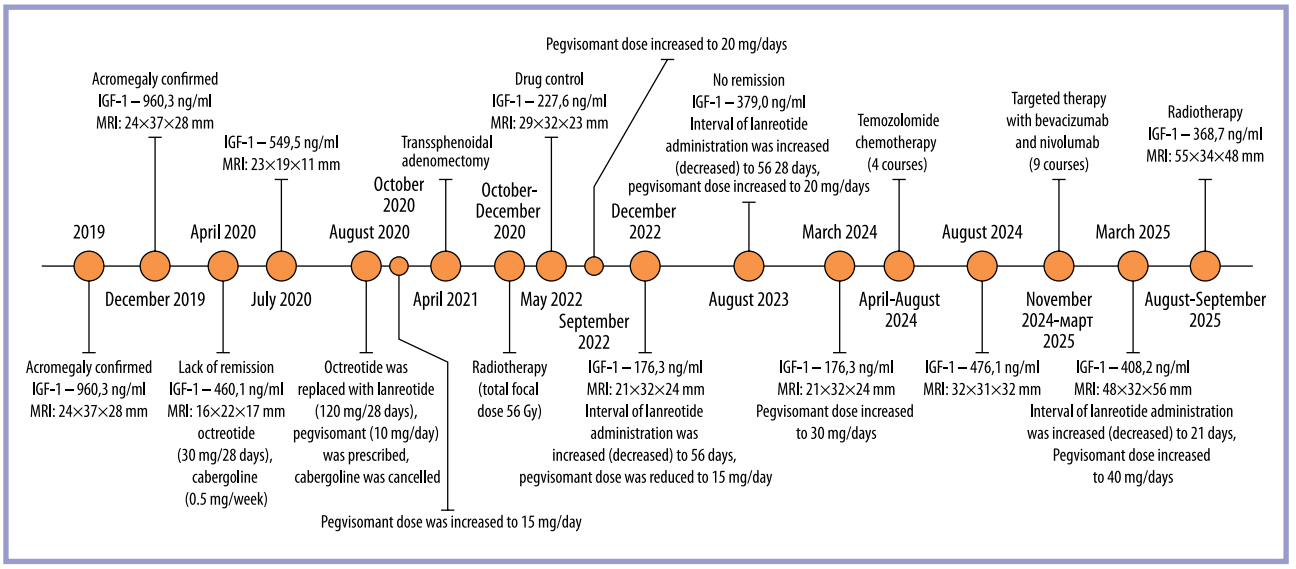

Fig. 3. **Course of acromegaly between 2019 and 2025.**

examination verified fragments of solid basophilic pituitary tumor and fibrous tissue containing embedded tumor cells.

Considering histological and structural features of pituitary tumor, as well as impossible total endoscopic resection, the patient underwent external beam radiation therapy from October to December 2021 (TrueBeam system, Varian Medical Systems, USA) with total focal dose 56 Gy.

In March 2022, genomic sequencing (paired-end read method (150×2)) revealed a previously undescribed variant (HG38, chr7:83963266T>A, c.993+167C>T) in intron 9 of the TP53 gene (NM 000546.6) in heterozygous state with a coverage depth of 247×(rs1054907742). This was assessed as a mutation of uncertain clinical significance.

In December 2022, pegvisomant therapy (15 mg) resulted in acromegaly control: IGF-1 176.3 ng/ml (81.0—283.0). Brain MRI revealed tumor shrinkage up to 21×32×24 mm with partial transformation of solid component into cystic one, regression of the right temporal lobe compression and partial regression of the right frontal lobe compression. The period of lanreotide administration was increased to every 56 days.

In March 2024, the patient noted headache, feeling of eye pressure and diplopia. Brain MRI showed tumor enlargement to 32×32×24 mm. IGF-1 increased to 441.4 ng/ml (62.0—230.0). Ophthalmological examination revealed no evidence of chiasmal syndrome. Considering aggressive course of disease, oncology team recommended to increase pegvisomant dose to 30 mg per day and temozolomide chemotherapy 150 mg/m^2/day orally on days 1—5 every 28 days (therapy initiation date: April 2024). Three months later, repeat brain MRI was performed due to deterioration of neuro-ophthalmological symptoms. Progressive tumor growth to 34×25×32 mm was observed.

In September 2024, additional IHC study revealed PD-L1 and VEGF expression in 70—80% of tumor tissue. Therefore, the patient was consulted by oncologist at the Burdenko Neurosurgery Center, who recommended therapy with antiangiogenic agents and ICIs. There were 9 courses of bevacizumab 5 mg/kg and nivolumab 240 mg intravenously every other week between November 2024 and March 2025. In November 2024, discontinuation of pegvisomant therapy was followed by IGF-1 increase to 672.8 ng/ml (62.0—230.0). Therefore, pegvisomant therapy was resumed in December 2024.

In March 2025, there was persistence of disease with IGF-1 408.2 ng/ml (62.0—230.0). Brain MRI revealed tumor enlargement to 48×32×56 mm **(Fig. 2)**.

A team of specialists recommended higher dose of pegvisomant (40 mg/day) and shorter interval of lanreotide 120 mg administration (every 21 days). Two courses of oncoimmunotherapy were recommended with subsequent decision on further treatment without clinical deterioration or tumor progression.

There was no remission of acromegaly in August 2025 with IGF-1 368.7 ng/mL (62.0—230.0). According to brain MRI, tumor size was stable (55×34×48 mm). Considering previous neurosurgical interventions, radio- and chemotherapy, targeted therapy, we prescribed external beam radiation therapy (classical fractionation 1.8—2.0 Gy 5 times per week) for the left frontal lobe tumor as the only alternative treatment. The patient is currently undergoing radiotherapy under supervision of endocrinologist, neurosurgeon, oncologist and ophthalmologist. Activity of disease over time is presented in **Fig. 3**.

Discussion

Aggressive pituitary neuroendocrine tumors, primarily macroadenomas, are characterized by invasive growth into sphenoid sinus with destruction of sella turcica and cavernous sinuses. This is associated with high-

er risk of partial resection and recurrence [7]. In our case, a 36-year-old patient was diagnosed with pituitary macroadenoma (24×37×28 mm) with supra-, infra-, and para(D) sellar extension (Knosp IV) that required multiple surgical interventions and confirmed the correlation between young age and aggressive course of disease.

Early studies defined aggressive pituitary neuroendocrine tumors by the following histological criteria: elevated Ki-67 index (⩾3%), high mitotic activity, and p53 protein expression [8]. In 2022, Burman P. et al. analyzed a cohort of 171 patients (121 with aggressive pituitary tumors and 50 with metastatic carcinomas). Ki-67 ⩾3% was found in 80% of cases (74/93) and ⩾10% in 41% (38/93). The median Ki-67 was 6% for aggressive tumors and 10% for metastatic tumors. Importantly, this index exceeded 10% in 18 out of 49 patients after redo surgery (median follow-up 6 years). In our case, morphological examination revealed high Ki-67 proliferation index (17.0%) and mitoses. These findings significantly exceed the median values described in the literature and directly related to extremely aggressive tumor phenotype.

Regarding molecular basis of aggressive pituitary adenomas, whole-genome sequencing is of significant interest. This method revealed a previously undescribed mutation in the TP53 gene.

The TP53 tumor suppressor gene regulates cell cycle control and apoptosis. It is one of the most frequently mutated genes in malignant neoplasms. Perez-Rivas L.G. et al. [9] analyzed mutational status of the TP53 gene in 86 patients with corticotropinomas including 24 cases of aggressive pituitary tumors. Pathogenic variants were verified in 9 cases and demonstrated association with unfavorable aggressive course of disease. Molecular analysis confirmed mutation at the early diagnostic stages. These results allow us to consider TP53 gene mutations as a predictor of tumor progression and perspective biomarker for early risk stratification of aggressive neuroendocrine tumors and pituitary carcinomas.

Somatotropinomas are morphologically subdivided into densely and sparsely granulated ones. They differ in density of secretory GH-containing granules and cytoplasmic distribution of low-molecular-weight cytokeratin CAM 5.2. Tumors with higher risk of recurrence and invasive growth associated with acromegaly also include plurihormonal Pit-1-positive tumor [10]. In our case, IHC confirmed a sparsely granulated variant of somatotropinoma (weak staining for GH and CAM 5.2, Pit-1 expression) that was fully consistent with its aggressive phenotype.

According to the literature, GH-releasing pituitary adenomas in most cases demonstrate expression of CCP-2 and CCP-5 subtypes [11]. In this case, aggressive somatotropinoma was characterized by low expression of CCP-2 and CCP-5 that largely determined resistance to ACC-1 and ACC-2 therapy. Thus, pegvisomant was added. This agent ensures IGF-1 normalization regardless of CCP. Stepwise daily dose escalation to 40 mg was used to achieve tumor control as demonstrated by Russian trials [12] indicating comparable efficacy and safety profile.

Temozolomide is an oral alkylating chemotherapeutic agent. It has been used for aggressive pituitary neuroendocrine tumors since 2006. Mechanism of action is based on DNA methylation inducing irreversible damage to genetic material and tumor cell death. According to the literature, temozolomide results in radiological response rate of 41% and biochemical remission in 53% of patients with aggressive pituitary neuroendocrine tumors, primarily corticotropin- and prolactin-releasing tumors. Administration of temozolomide in our case was reasonable and consistent with recommendations [13].

Extensive IHC analysis identified PD-L1 and VEGF expression, as well as justified an innovative approach including antiangiogenic therapy (bevacizumab) and nivolumab.

Vascular endothelial growth factor (VEGF) is a key mediator of endothelial cell proliferation, angiogenesis and vascular permeability. Bevacizumab (anti-VEGF) is a humanized IgG1 monoclonal antibody blocking VEGF binding and suppressing tumor vascularization. Burman P. et al. [14] analyzed 19 patients with aggressive neuroendocrine tumors and pituitary carcinomas. Bevacizumab monotherapy (n=12) resulted in partial response in 2 patients and tumor stabilization in 6 patients. This therapy demonstrates clinical efficacy. It is currently considered as a promising option for patients with exhausted standard approaches and failed to achieve remission after treatment with temozolomide.

Nivolumab is a humanized IgG4 monoclonal antibody selectively binding to the programmed cell death receptor 1 (PD-1) on T lymphocyte surface and blocking its interaction with ligands PD-L1 and PD-L2. Pharmacological action is based on inhibition of PD-1/PD-L1 signaling pathway that leads to functional restoration of cytotoxic T lymphocytes, their proliferation and cytokine secretion. Clinical efficacy of nivolumab with improved overall and disease-free survival was demonstrated in multiple-center, randomized, controlled phase III trials in various solid tumors, including melanoma, non-small cell lung cancer, renal cell carcinoma and other malignancies [15].

In a systematic analysis, Burman P. et al. [14] analyzed the results of ICI therapy in 27 patients with aggressive tumors and pituitary carcinomas (12 and 15, respectively). The study cohort included 18 cases of corticotropinoma and 9 Pit-1 tumors (primarily prolactinomas). Patients received monotherapy (nivolumab, ipilimumab, or pembrolizumab) or combination of nivolumab and ipilimumab. Significant clinical effect (complete/partial regression or stabilization for ⩾6 months) was recorded in 9 out of 15 patients with carcinomas and in 2 out of 12 ones with aggressive pituitary adenomas. This confirms the feasibility of ICIs.

Conclusion

Aggressive growth hormone-releasing pituitary tumors are one of the most complex and important issues in mod-

ern neuroendocrinology. This is due to impossible stable control of disease following severe resistance to standard treatment methods.

The overcoming of resistance of aggressive growth hormone-secreting tumors is associated with interdisciplinary strategies, including innovative targeted and oncoimmunological drugs, optimization of diagnostic protocols using advanced immunohistochemical profiling and genome-wide molecular analysis. Implementation of these approaches will open up new opportunities for personalized treatment, significantly improve tumor control, minimize the risk of life-threatening complications, improve the quality of life and life expectancy in patients with aggressive acromegaly.

Author contribution:
Concept and design of the study — Dzeranova L.K., Przhiyalkovskaya E.G., Mokrysheva N.G.
Collection and analysis of data — Gabaidze G.D., Ebanoidze L.G., Lisina D.V., Perepelova M.A., Kononykhina A.P.
Writing the text — Gabaidze G.D., Ebanoidze L.G., Lisina D.V., Perepelova M.A.
Editing — Dzeranova L.K., Przhiyalkovskaya E.G., Kolomeytseva A.A., Astafieva L.I., Alekseeva T.M., Kobyakov G.L., Kutin M.A., Mokrysheva N.G.

The authors declare no conflicts of interests.

REFERENCES

1. Przhiyalkovskaya EG, Mokrysheva NG, Troshina EA, Melnichenko GA, Dedov II, Antsiferov MB, Astafieva LI, Bardymova TP, Belaya ZhE, Vagapova GR, Vorotnikova SYu, Grigoriev AYu, Grineva EN, Dzeranova LK, Ilovaiskaya IA, Kalinin PL, Lapshina AM, Lutsenko AS, Mamedova EO, Marova EI, Perepelova MA, Pigarova EA, Pronin VS, Rozhinskaya LYa, Trunin YuYu, Shutova AS. Guidelines on diagnostics and treatment of acromegaly (draft). *Obesity and metabolism*. 2024;21(2):215-249. (In Russ.). https://doi.org/10.14341/omet13153
2. Dekkers OM, Karavitaki N, Pereira AM. The epidemiology of aggressive pituitary tumors (and its challenges). *Reviews in Endocrine and Metabolic Disorders*. 2020;21(2):209-212. https://doi.org/10.1007/s11154-020-09556-7
3. Shimon I, Cohen ZR, Ram Z, Hadani M. Transsphenoidal surgery for acromegaly: endocrinological follow-up of 98 patients. *Neurosurgery*. 2001;48(6):1239-1243; discussion 1244-1245. https://doi.org/10.1097/00006123-200106000-00008
4. Colao A, Auriemma RS, Pivonello R, Kasuki L, Gadelha MR. Interpreting biochemical control response rates with first-generation somatostatin analogues in acromegaly. *Pituitary*. 2016;19(3):235-247. https://doi.org/10.1007/s11102-015-0684-z
5. Haberbosch L, Strasburger CJ. Efficacy and Safety of Pegvisomant in the Treatment of Acromegaly. *Archives of Medical Research*. 2023;54(8):102884. https://doi.org/10.1016/j.arcmed.2023.102884
6. Astafieva LI, Kalinin PL, Kobyakov GL, Trunin YuYu, Ryzhova MV. Aggressive pituitary tumors and carcinomas: modern classification, advances and prospects in treatment. *Burdenko's Journal of Neurosurgery*. 2024;88(3):103-110. (In Russ., In Engl.). https://doi.org/10.17116/neiro202488031103
7. Di Ieva A, Rotondo F, Syro LV, Cusimano MD, Kovacs K. Aggressive pituitary adenomas--diagnosis and emerging treatments. *Nature Reviews Endocrinology*. 2014;10(7):423-435. https://doi.org/10.1038/nrendo.2014.64
8. Tatsi C, Stratakis CA. Aggressive pituitary tumors in the young and elderly. *Reviews in Endocrine and Metabolic Disorders*. 2020;21(2):213-223. https://doi.org/10.1007/s11154-019-09534-8
9. Perez-Rivas LG, Simon J, Albani A, Tang S, Roeber S, Assié G, Deutschbein T, Fassnacht M, Gadelha MR, Hermus AR, Stalla GK, Tichomirowa MA, Rotermund R, Flitsch J, Buchfelder M, Nasi-Kordhishti I, Honegger J, Thorsteinsdottir J, Saeger W, Herms J, Reincke M, Theodoropoulou M. TP53 mutations in functional corticotroph tumors are linked to invasion and worse clinical outcome. *Acta Neuropathologica Communications*. 2022;10(1):139. https://doi.org/10.1186/s40478-022-01437-1
10. Casar-Borota O, Burman P, Lopes MB. The 2022 WHO classification of tumors of the pituitary gland: An update on aggressive and metastatic pituitary neuroendocrine tumors. *Brain Pathology*. 2025;35(1):e13302. https://doi.org/10.1111/bpa.13302
11. Albarel F, Cuny T, Graillon T, Dufour H, Brue T, Castinetti F. Preoperative Medical Treatment for Patients With Acromegaly: Yes or No? *Journal of the Endocrine Society*. 2022;6(9):bvac114. https://doi.org/10.1210/jendso/bvac114
12. Przhyalkovskaya EG, Filkina EE, Perepelova MA, Pronin EV, Ilovayskaya IA, Kukushkina YuA, Mikhailova DS, Dzeranova LK, Pigarova EA, Belaya ZhE, Antsiferov MB, Alekseeva TM, Mokrysheva NG. A retrospective multicenter study of pegvisomant use in acromegaly within Russian Federation. *Obesity and metabolism*. 2025;22(2):97-110. (In Russ.). https://doi.org/10.14341/omet13259
13. Raverot G, Burman P, Abreu AP, Heaney AP, van Hulsteijn L, Lin AL, Marcus H, McCormack A, Minniti G, Petersenn S, Popovic V, Theodoropoulou M, Trouillas J, Dekkers OM. Revised European Society of Endocrinology Clinical Practice Guideline for the management of aggressive pituitary tumours and pituitary carcinomas. *European Journal of Endocrinology*. 2025;192(6):R45-R78. https://doi.org/10.1093/ejendo/lvaf100
14. Burman P, Casar-Borota O, Perez-Rivas LG, Dekkers OM. Aggressive Pituitary Tumors and Pituitary Carcinomas: From Pathology to Treatment. *The Journal of Clinical Endocrinology & Metabolism*. 2023;108(7):1585-1601. https://doi.org/10.1210/clinem/dgad098
15. Provencio M, Nadal E, González-Larriba JL, Martínez-Martí A, Bernabé R, Bosch-Barrera J, Casal-Rubio J, Calvo V, Insa A, Ponce S, Reguart N, de Castro J, Mosquera J, Cobo M, Aguilar A, López Vivanco G, Camps C, López-Castro R, Morán T, Barneto I, Rodríguez-Abreu D, Serna-Blasco R, Benítez R, Aguado de la Rosa C, Palmero R, Hernando-Trancho F, Martín-López J, Cruz-Bermúdez A, Massuti B, Romero A. Perioperative Nivolumab and Chemotherapy in Stage III Non-Small-Cell Lung Cancer. *The New England Journal of Medicine*. 2023;389(6):504-513. https://doi.org/10.1056/nejmoa2215530

Received 22.10.2025
Revised 15.01.2026
Accepted 12.03.2026

COMMENT

This article addresses the issue of resistant and aggressive forms of somatotropinomas posing a significant challenge for endocrinologists, neurosurgeons, neuro-oncologists, and radiologists.

This case highlights the need for multidisciplinary approach, extensive immunohistochemical testing and molecular genetic sequencing of pituitary lesions to develop personalized treatment strategies for aggressive drug-resistant somatotropinomas.

This manuscript is of practical interest to various specialists treating acromegaly and hormonally active pituitary adenomas.

Pavlova M.G. (Moscow)