Burdenko's Journal of Neurosurgery
2026, No. 3, pp. 80–84
https://doi.org/10.17116/neiro20269003128

# Breast cancer metastasis to parasagittal meningioma: a case report and literature review

© V.N. Shimansky[1], I.I. Isazade[1], M.V. Kolycheva[2], G.P. Snigireva[1], M.V. Ryzhova[1], V.V. Karnaukhov[2]

[1]Burdenko Neurosurgical Center, Moscow, Russia;
[2]Pirogov Russian National Research Medical University, Moscow, Russia

**ABSTRACT**

**Introduction.** Tumor-to-tumor metastasis is a rare phenomenon, and meningiomas are the most frequent recipient in these cases. The most common donor tumors are breast and lung cancers.

**Objective.** To describe a rare clinical case of breast adenocarcinoma metastasis to meningioma, problems of diagnosis and treatment.

**Material and methods.** A 67-year-old patient presented with breast cancer. Neuroimaging revealed parasagittal intracranial tumor. Resection of tumor was followed by histological and immunohistochemical examination of specimens. There was postoperative radiotherapy (CyberKnife). The authors present a rare case of breast cancer metastasis to parasagittal meningioma and reviewed 152 available cases in the literature.

**Results.** Histological examination revealed two components: benign transitional meningioma (Grade I) and invasive breast adenocarcinoma metastasis (positive expression of AE1/AE3 CK). Tumor stabilization was achieved after resection and subsequent radiotherapy.

**Conclusion.** This rare case demonstrates the need for a more detailed neuroradiological examination in patients with previously diagnosed malignancies referred for surgical treatment of intracranial meningiomas.

**Keywords:** *parasagittal meningioma, breast cancer metastasis.*

**INFORMATION ABOUT THE AUTHORS:**
Shimansky V.N. — https://orcid.org/0000-0002-3816-847X
Isazade I.I. — https://orcid.org/0009-0007-3778-7213
Kolycheva M.V. — https://orcid.org/0000-0002-7741-6616
Snigireva G.P. — https://orcid.org/0000-0002-2584-802X
Ryzhova M.V. — https://orcid.org/0000-0001-7206-6365
Karnaukhov V.V. — https://orcid.org/0000-0002-2581-8648
**Corresponding author:** Isazade I.I. — e-mail: IsazadeII@nsi.ru

**TO CITE THIS ARTICLE:**
Shimansky VN, Isazade II, Kolycheva MV, Snigireva GP, Ryzhova MV, Karnaukhov VV. Breast cancer metastasis to parasagittal meningioma: a case report and literature review. *Burdenko's Journal of Neurosurgery*. 2026;90(3):80–84. (In Russ.). https://doi.org/10.17116/neiro20269003180

## Introduction

Metastatic tumors are the most common intracranial neoplasms. They can be found in various areas of medulla, meninges and ventricular system. Meningiomas, in turn, are among the most common primary brain tumors. These benign neoplasms arise from the meninges. They are often richly vascularized and therefore a potential target for other metastatic cancers [1].

Since Fried B.M. has published the first case of metastasis from bronchogenic carcinoma to meningioma in 1930, articles describing «tumor-to-tumor» phenomenon (metastasis of one tumor to tumor of another histological structure) have become increasingly common in neuro-oncology and pathology [1—5]. The most common recipient tumors in such cases are meningiomas, pituitary adenomas, gliomas, schwannomas, and hemangioblastomas [1, 6—10]. The most common cause of metastases is breast or lung carcinoma [1, 3, 4]. There were also reports on metastases from renal cell carcinoma, prostate carcinoma, thyroid carcinoma and rectal carcinoma [1, 11—13].

In 2020, Turner N. et al. [1] analyzed 124 articles describing 152 cases of malignant tumor metastasis to intracranial meningioma. Mean age of patients was 62.21±10.8 years; 65.9% of all metastases were registered in women. The most common cause of metastases was breast and lung cancer, as well as kidney, prostate, and gastrointestinal cancers. No clear primary tumor was found in 36.69% of cases. In almost 60% of known cases, cancer was considered to be in remission for at least 1 year. The authors found no relationship between this phenomenon and location, histological structure or molecular subtype of meningioma. Finally, it was concluded that phenomenon of metastases to meningioma should be considered in patients in the 6$^{th}$—8$^{th}$ decades of life with newly diagnosed symptomatic or progressive meningioma. Particular attention should be paid to pa-

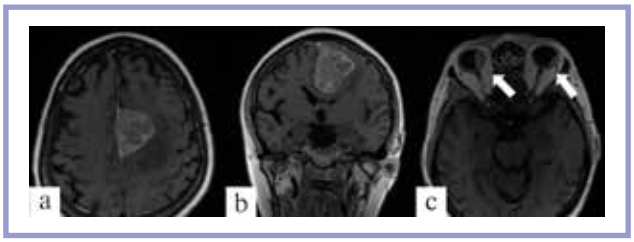


***Fig. 1.*** **Brain MRI upon admission.**
Contrast-enhanced axial (a) and coronal (b) T1WIs demonstrate a large parasagittal tumor adjacent to the middle third of superior sagittal sinus and falx. Contrast enhancement of adjacent falx is visible (typical for meningeal tumor). However, both images show non-enhanced area of destruction that is atypical for meningioma. Axial contrast-enhanced T1WI at the level of the orbits (c). Focal contrast-enhanced lesions are visible in both orbits, likely metastatic ones (arrows).

tients with a combination of previously diagnosed cancer and newly diagnosed meningioma [1].

There are descriptions of metastases to benign tumors in Russian-language literature too. In 2002, Evzikov G. Yu. et al. [6] described clear cell renal cell carcinoma metastasis to the matrix of a previously excised meningioma. In 2020, Andreev D.N. et al. [14] described metastasis of breast adenocarcinoma to a giant hormonally inactive pituitary adenoma.

A 67-year-old patient admitted on June 7, 2022. There was resection of the left ovarian cyst with uterine resection in 2014, left breast cancer (T2N2aM0), mastectomy in 2015 and chemotherapy in 2016 immediately after surgery. She had a family history of stomach cancer in her mother.

Since the spring of 2021, the patient has noticed coordination disorders, constant anxiety, tremor and palpitations. She was treated by a psychotherapist for anxiety disorder. Neurologist recommended MRI. Neuroimaging before hospitalization revealed parasagittal tumor in the left frontal lobe extending into adjacent falx. There were uneven tumor enhancement and signs of severe peritumoral edema **(Fig. 1)**.

Neuro-ophthalmological examination revealed visual acuity OD=OS=1.0. Perimetry revealed hemianopsia with visual field defects in temporal and superior halves on the right, severe narrowing in nasal and temporal halves on the left. Ophthalmoscopy revealed pink optic discs with clear borders, and no signs of intracranial hypertension. Areas of high retinal detachment extending to the periphery are detected in macular regions of both eyes. Eye ultrasound revealed focal lesions protruding into the vitreous (upper-inner quadrants on the right and the outer half on the left) with retinal detachment. Thus, visual field disorders were due to concomitant lesions (damage to visual pathways in the left hemisphere (tumor) and bilateral metastatic choroidal lesions).

On June 8, 2022, the patient underwent resection of tumor in the left frontal-parasagittal region under neurophysiological monitoring and ultrasound navigation. Intraoperatively, the tumor had heterogeneous structure and moderate density (more likely metastatic tumor) **(Fig. 2a)**. Resection was accompanied by moderate venous-arterial bleeding. There was falx involvement **(Fig. 2b)**. At this site, the tumor most closely resembled meningioma. Subtotal resection was performed; the infiltrated area of the falx was coagulated without excision. Intraoperative neurophysiological monitoring included mapping of motor pathways and motor zone, as well as monitoring of transcranial motor evoked potentials. Resection of posterior tumor pole near motor cortex of posterior precentral gyrus was followed by impairment of evoked potentials from the right leg. We left a small tumor fragment in this area due to the risk of severe motor disorders.

There was postoperative right-sided hemiparesis with reduced muscle strength in the limbs to 3 scores. Rehabilitation measures were followed by gradual regression of hemiparesis to 4 scores, and the patient moved around the department using a walker.

In 8 postoperative days, MRI revealed a small residual tumor in posterior part of surgical cavity **(Fig. 3a)**.

The patient was discharged on the 9$^{th}$ postoperative day.

### Histological and immunohistochemical examination

There were 2 components in specimen. The first component consisted of meningothelial cells with «salt-and-pepper» nuclei forming vortex structures (mixed-type meningioma, Grade I). The second component was an invasively growing epithelial tumor composed of polymorphic

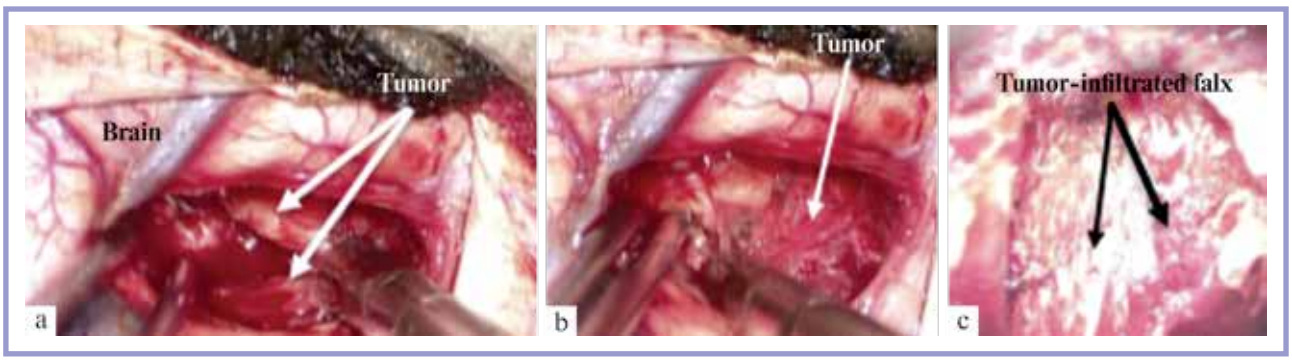


***Fig. 2.*** **Surgical stages. Resection of tumor after craniotomy in the left frontal-parasagittal region and corticotomy (a, b). There is heterogeneous tumor structure (b). Tumor-infiltrated falx is visualized after tumor removal (c).**

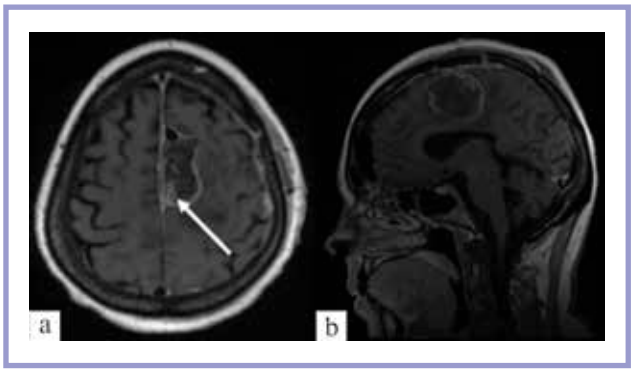


***Fig. 3.*** **MRI on the 8th postoperative day.**
Axial (a) and sagittal (b) contrast-enhanced T1WIs demonstrate postoperative cavity in the left frontal-parasagittal region, as well as a small tumor remnant near the motor area (a, arrow).

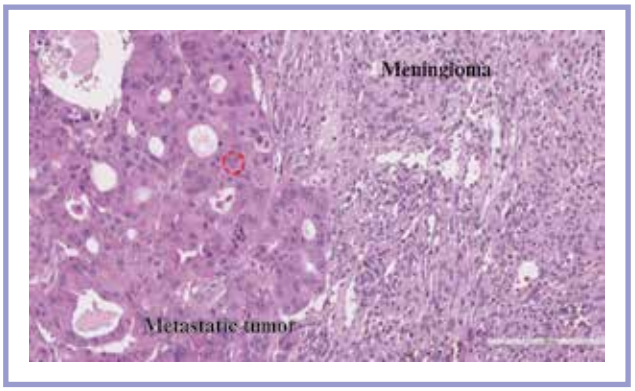


***Fig. 4.*** **Histological specimen, hematoxylin and eosin staining, ×400.**
Metastatic tumor is composed of large polymorphic cells. Some cells contain multiple transparent nuclei with visible nucleoli, and cytoplasm is richly eosinophilic (red dotted line). Meningioma is closely adjacent to metastatic tumor with visible border. Meningioma with transitional structure forms round cell complexes with elongated nuclei. Meningioma cells are smaller compared to metastatic tumor.

cells with tubular structures, numerous mitoses, and pathological forms. Immunohistochemistry revealed positive expression of cytokeratins AE1/AE3 in epithelial component, but no mammaglobin expression. Thus, morphological appearance and immunophenotype along with anamnestic data were consistent with breast adenocarcinoma metastasis to transitional meningioma (Grade I) **(Fig. 4)**.

**Radiotherapy**

The patient underwent a course of hypofractionated stereotactic radiotherapy (CyberKnife) between July 18, 2022 and August 5, 2022. Treatment was administered alongside steroid therapy (dexamethasone 4 mg/day) and included three phases:

1. Tumor bed irradiation (July 18, 2022—July 22, 2022): a dose of 26.6 Gy (single focal dose 6.0 Gy) was delivered to residual tumor bed in the left frontal lobe (CTV with 2 mm coverage, initial dimensions 4.7×3.6 cm, volume 32.1—51 cm³) over 5 sessions at 79% isodose curve. Mean dose was 30.04 Gy, maximum dose — 33.67 Gy.
2. Irradiation of the left eye (July 19, 2022—July 27, 2022): a dose of 31.25 Gy (single focal dose 5.0 Gy) was delivered to metastatic lesion of posterior pole (volume 7.24 cm³) over 7 sessions at 79% isodose curve. Mean dose was 35.04 Gy, maximum dose — 39.37 Gy.
3. Irradiation of the right eye (July 28, 2022—August 5, 2022): a dose of 31.2 Gy (single focal dose 5.0 Gy) was delivered to metastatic lesion of posterior pole (volume 7.06 cm³) over 7 sessions at 80% isodose curve. Mean dose was 35.05 Gy, maximum dose — 39.0 Gy.

Doses to critical structures did not exceed tolerable values at all stages.

Subsequently, progression of cancer was followed by metastases to lungs and brain, as well as recurrent choroidal lesions. Chemotherapy and repeated radiotherapy were administered in May 2023 and March 2024. Despite progression, she led an active lifestyle and did housework until the fall of 2024. She died suddenly in November 2024 from pulmonary embolism.

## Discussion

High vascularity and high incidence make meningioma the most likely recipient tumor. It accounts for more than three-quarters of registered cases of such metastases. For a tumor to be classified as a tumor-to-tumor metastasis, the following criteria should be met. Donor metastasis must be partially surrounded by benign primary tumor, and primary carcinoma must be verified [1].

Diagnosis of metastases of one tumor to another is extremely difficult. Indeed, it is almost impossible to differentiate typical meningioma and meningioma with metastasis using clinical and neuroimaging data. Without surgical intervention, meningioma with metastasis may be suspected only with very low probability in patients with previous cancer, especially metastases in other organs. Fast neurological deterioration, uneven tumor enhancement with signs of destruction and severe peritumoral edema may raise suspicion of this phenomenon.

In our case, the diagnosis of metastasis was clear, as the patient had clear signs of disease generalization with bilateral choroidal metastases confirmed by ophthalmoscopy and ultrasound. However, it was not possible to verify metastasis specifically in meningioma tissue before surgery. This was only established after histological and immunohistochemical examination of specimen.

## Conclusion

This is a rare case of breast cancer metastasis to parasagittal meningioma. This report highlights the role of a comprehensive approach to patient management

in neuro-oncology including careful clinical monitoring, timely surgical intervention and mandatory pathological examination. Surgical strategy for metastasis in meningioma is the same. Primary goal is total resection while maintaining the patient's quality of life. Postoperative multidisciplinary management is mandatory to determine further treatment.

Early diagnosis deserves a special attention. Preoperative diagnosis of metastases in meningioma is extremely difficult, but specialists should be particularly attentive when managing patients with previous cancer. This necessitates an extended screening in high-risk groups and comprehensive cancer screening (CT, MRI, positron emission tomography, scintigraphy) to detect malignant tumors.

**Author contribution:**
Concept and design of the study — Shimansky V.N., Isazade I.I., Karnaukhov V.V., Ryzhova M.V.
Collection and analysis of data — Isazade I.I., Karnaukhov V.V., Snigireva G.P.
Writing — Isazade I.I., Karnaukhov V.V.
Editing — Shimansky V.N., Kolycheva M.V.

**The authors declare no conflicts of interests.**

## REFERENCES

1. Turner N, Kaye AH, Paldor I. Metastases to meningioma-review and meta-analysis. *Acta Neurochirurgica.* 2021;163(3):699-709. https://doi.org/10.1007/s00701-020-04661-7
2. Fried BM. Metastatic Inoculation of a Meningioma by Cancer Cells from a Bronchiogenic Carcinoma. *The American Journal of Pathology.* 1930;6(1):47-52.1.
3. Ding L, Chen B, Zhou Z, Mei Z, Cao K, Lu X, Chen W. Exploring the genetic correlation and causal relationships between breast cancer and meningioma using bidirectional Mendelian randomization. *Scientific Reports.* 2025;15(1):4271. https://doi.org/10.1038/s41598-025-88829-0
4. Sayegh ET, Burch EA, Henderson GA, Oh T, Bloch O, Parsa AT. Tumor-to-tumor metastasis: breast carcinoma to meningioma. *Journal of Clinical Neuroscience.* 2015;22(2):268-274. https://doi.org/10.1016/j.jocn.2014.07.002
5. Syed S, Karambizi DI, Baker A, Groh DM, Toms SA. A Comparative Report on Intracranial Tumor-to-Tumor Metastasis and Collision Tumors. *World Neurosurgery.* 2018;116:454-463.e2. https://doi.org/10.1016/j.wneu.2018.04.109
6. Andreev DN, Kim DS, Shishkina LV, Kalinin PL, Astafieva LI, Tropinskaya OF, Voronina IA, Turkin AM, Nazarov VV, Kadashev BA. Breast cancer metastasis into a giant hormone-inactive pituitary adenoma adenoma. (Clinical case and literature review). *Burdenko's Journal of Neurosergery.* 2020;84(1):55-61. (In Russ.). https://doi.org/10.17116/neiro20208401155
7. Saliba J, Buckwalter NR, Reisian N, Mastrodimos B, Cueva RA. Tumor-to-Tumor Metastasis From a Breast Carcinoma to a Vestibular Schwannoma. *Otology & Neurotology.* 2019;40(1):e66-e68. https://doi.org/10.1097/MAO.0000000000002066
8. Di Lorenzo S, Farese S, Balbo C, Melisi F, Scrima M, Pasquale LS, Laudato MP, Peluso T, Solari D, Ronchi A, Accardo M, Franco R, Addeo R, Somma T, Pirozzi M, Ciardiello F, Caraglia M, Fasano M. The First Case Report of a Solitary Pulmonary Metastasis of a Transitional Meningioma and Literature Review. *International Journal of Molecular Sciences.* 2025;26(14):6868. https://doi.org/10.3390/ijms26146868
9. Tomoto K, Watanabe K, Ogawa T, Sano H, Suetsugu H, Wachi R, Tanaka M, Murayama Y, Tanaka T. Tumor-to-Tumor Metastasis in a Patient With Hemangioblastoma Unrelated to von Hippel-Lindau Disease: A Case Report and Review of the Literature. *Cureus.* 2025;17(6):e86881. https://doi.org/10.7759/cureus.86881
10. Wang T, Liu L, Rampisela D, Dong X, Keith KA, Benardete EA, Shan FY. A Cerebellar Tumor-to-Tumor Metastasis in a Patient With Von Hippel-Lindau Disease. *Applied Immunohistochemistry and Molecular Morphology.* 2024;32(5):244-248. https://doi.org/10.1097/PAI.0000000000001197
11. Huang B, Liang J, Tang X, Zhu Y, Gao L, Fu D, Wei C, Li Y, Ke C, Zhang H, Luo OJ. Single-cell transcriptomic analysis reveals metastatic and immunosuppressive characteristics in meningioma brain-tumor interface. *Journal of Translational Medicine.* 2025;23(1):930. https://doi.org/10.1186/s12967-025-06935-z
12. Gowda KK, Bal A, Agrawal P, Verma R, Das A. Tumor-to-tumor metastasis: Small cell carcinoma lung metastasising into a follicular adenoma of the thyroid. *Indian Journal of Pathology and Microbiology.* 2017;60(1):133-135. https://doi.org/10.4103/0377-4929.200037
13. Chang HF, Maimaitiaili N, Huo JF, Sun ZL. Clinical and pathological characteristics of pulmonary meningioma: a case report and literature review. *Journal of International Medical Research.* 2025;53(2):3000605241293675. https://doi.org/10.1177/03000605241293675
14. Evzikov GYu, Baranova OV, Pevzner KB. Metastases of cancer to primary tumors of the brain and its meninges (review of the literature and a case report). *Neurological Journal.* 2003;8(5):21 (In Russ).
15. Hamadi R, Karam I, Khan S, Homsy S, Luhrs C. Tumour-To-Tumour Metastasis: A Rare Case of Prostate Cancer Metastasising to Primary Lung Adenocarcinoma. *European Journal of Case Reports in Internal Medicine.* 2024;11(8):004579. https://doi.org/10.12890/2024_004579
16. Manini C, Provenza C, Andrés L, Imaz I, Guarch R, Nunziata R, López JI. Tumor-to-Tumor Metastases Involving Clear Cell Renal Cell Carcinomas: A Diagnostic Challenge for Pathologists Needing Clinical Correlation. *Clinics and Practice.* 2023;13(1):288-296. https://doi.org/10.3390/clinpract13010026
17. Li X, Jing M, Dai Y, Xing X. Tumor-to-tumor metastasis: A case report of metastasis of nasopharyngeal carcinoma to meningioma and review of the literature. *Medicine.* 2023;102(15):e33500. https://doi.org/10.1097/MD.0000000000033500
18. Takido N, Saito R, Okada K, Kanai N, Shono Y, Mitsugashira H, Matsumura M, Sasaki K, Miyazawa K, Fujio A, Tokodai K, Murakami K, Sasano H, Unno M, Ishida T, Kamei T. Tumor-to-Tumor Metastasis of Medullary Thyroid Carcinoma to Paraganglioma in a Multiple Endocrine Neoplasia Type 2B Patient: A Case Report and Literature Review. *The Tohoku Journal of Experimental Medicine.* 2023;261(1):75-81. https://doi.org/10.1620/tjem.2023.J058
19. Gawlik C, Lane J, Horattas M. Tumor-to-tumor spread: a case report and literature review of renal cell carcinoma metastasis into thyroid cancer. *World Journal of Surgical Oncology.* 2023;21(1):362. https://doi.org/10.1186/s12957-023-03220-5
20. Gvazava N, Stevens TM, Rader RK. A Case of Tumor-to-Tumor Metastasis: Breast Carcinoma Metastatic to Oncocytic Carcinoma of Thyroid. *Kansas Journal of Medicine.* 2025;18(2):46-48. https://doi.org/10.17161/kjm.vol18.23026
21. Clara U, Rossella DF, Giulio R, Gabriele M, Virginia L. Tumor-to-Tumor Metastasis: Lung Typical Carcinoid Metastatic to Follicular Variant of Papillary Thyroid Carcinoma. *Endocrine Pathology.* 2022;33(2):330-332. https://doi.org/10.1007/s12022-022-09706-4
22. Mei W, Zhang D. Unraveling Tumor-to-Tumor Metastasis: Insights into Pathogenesis, Diagnostic Challenges, and Treatment Modalities. *Biologics.* 2025;19:43-58. https://doi.org/10.2147/BTT.S505950
23. Joe WH, Lee CY, Kim CH, Ko YS, Kim SP, Kwon SM. Breast Cancer to Meningioma: A Rare Case of Tumor-to-Tumor Metastasis. *Brain Tumor Research and Treatment.* 2023;11(1):73-78. https://doi.org/10.14791/btrt.2022.0042
24. Zhang H, Li X, Jiang Y. Multicentric primary ectopic meningiomas involving lung and cranial bone barrier: A rare case report. *Medicine.* 2025;104(5):e41294. https://doi.org/10.1097/MD.0000000000041294

25. Braunstein Z, Pullen J, Shilo K, Madrigal A, Tinoco G. A Case of Primary Pulmonary Meningioma With Genetic Characterization and Literature Review. *Case Reports in Oncological Medicine.* 2025;2025:6077936. https://doi.org/10.1155/crom/6077936

26. He R, Zhong P, Hu J, Guo G, Xiao H, Lei L, Liu Y, Geng M, Ma J. Meningeal malignant solitary fibrous tumor with multiple recurrence, extracranial extension, cervical lymph node metastases: case report and review of the literature. *Discover Oncology.* 2025;16(1):732. https://doi.org/10.1007/s12672-025-02441-2

27. Yang J, Feng J, Duan Z, Liu X, Zhang H, Zhang M, Ma Z, Hu Z, Xiang L, Qi X. Brain metastases lung adenocarcinoma patients with BRG1 loss have a grim prognosis, featuring unique morphological and methylation characteristics. *Clinical & Experimental Metastasis.* 2025;42(3):20. https://doi.org/10.1007/s10585-025-10337-2

28. Liu Q, Luo S, Guo M. Primary pulmonary meningioma: a case report and literature review. *Frontiers in Oncology.* 2025;15:1601698. https://doi.org/10.3389/fonc.2025.1601698

29. De Boos J, Bruyneel M, Bold I. Solitary metastasis in the internal auditory canal from non-small cell lung carcinoma: A case report. *Respiratory Medicine Case Reports.* 2025;53:102175. https://doi.org/10.1016/j.rmcr.2025.102175

30. Adelnia P, Heidarpour M. Tumor-to-Tumor Metastasis: An Uncommon Case of Metastatic Breast Carcinoma to Pheochromocytoma. *Iranian Journal of Pathology.* 2025;20(3):326-329. https://doi.org/10.30699/ijp.2025.2049764.3396

31. Borni M, Kolsi F, Ben Fradj S, Dammak I, Souissi B, Saguem I, Boudawara MZ. Solitary brain metastasis mimicking meningioma as the initial presentation of concurrent pulmonary and breast sarcomatoid carcinoma in a male patient: A rare entity with literature review. *Radiology Case Reports.* 2025;20(9):4245-4251. https://doi.org/10.1016/j.radcr.2025.05.016

Received 02.10.2025
Revised 19.12.2025
Accepted 12.03.2026