Burdenko's Journal of Neurosurgery
2026, No. 3, pp. 73–77
https://doi.org/10.17116/neiro20269003173

Asymmetric sliding knots for microsutures for skull base defect repair after transnasal endoscopic surgery

© M.A. Kutin[1, 2], E.V. Shelesko[1], D.V. Fomichev[1], O.I. Sharipov[1], D.N. Andreev[1], I.V. Chernov[1], N.A. Azarova[1], Yu.V. Strunina[1], A.D. Donskoy[1], O.A. Rastvorova[4], D.Sh. Adueva[4], D.A. Konyashin[3], G.G. Maksyutova[4], P.L. Kalinin[1]

[1]Burdenko Neurosurgical Center, Moscow, Russia;
[2]Russian Biotechnological University, Moscow, Russia;
[3]Burdenko Voronezh State Medical University, Moscow, Russia;
[4]Sechenov First Moscow State Medical University, Moscow, Russia

ABSTRACT

The advantage of asymmetrical sliding knot is that it is tightened by pulling only one «main» end of suture, while the other «wrapped» end is inserted into the wound. This method eliminates the need for additional instruments or devices to insert the knot into a narrow and deep wound.

Objective. To evaluate feasibility of asymmetrical sliding knots for microsutures in transnasal endoscopic skull base repair.

Material and methods. Asymmetric sliding suture was used to attach free autofascial flap to dura mater edges in 25 cases of transnasal endoscopic surgeries with intraoperative cerebrospinal fluid leakage. Craniopharyngiomas were resected in 19 cases, pituitary adenoma in 1 case, meningocele in 1 case, sinonasal carcinomas in 2 cases, chondrosarcoma in 1 case and chordoma in 1 case.

Results. Postoperative cerebrospinal fluid leakage was not observed in any case.

Conclusion. We confirmed feasibility of asymmetric sliding knots to form microsutures in transnasal endoscopic skull base repair. The key technical parameters of necessary sutures, specifics of needle insertion through the dura mater and free autofascial flap, limitations and difficulties encountered by the authors are described. Sliding interrupted microsutures can be recommended to form dense layer of autologous tissues in transnasal endoscopic skull base repair.

Keywords: *microsutures, skull base defect repair, transnasal endoscopic surgery.*

INFORMATION ABOUT THE AUTHORS:
Kutin M.A. — https://orcid.org/0000-0002-6520-4296
Shelesko E.V. — https://orcid.org/0000-0002-8249-9153
Fomichev D.V. — https://orcid.org/0000-0002-5323-1000
Sharipov O.I. — https://orcid.org/0000-0003-3777-5662
Andreev D.N. — https://orcid.org/0000-0001-5473-4905
Chernov I.V. — https://orcid.org/0000-0002-9789-3452
Azarova N.A. — https://orcid.org/0000-0002-4895-233X
Strunina Yu.V. — https://orcid.org/000-0001-5010-6661
Donskoy A.D. — https://orcid.org/0000-0002-0719-5168
Rastvorova O.A. — https://orcid.org/0000-0003-2820-9124
Adueva D.Sh. — https://orcid.org/0009-0003-1915-8107
Konyashin D.A. — https://orcid.org/0000-0003-1748-5668
Maksyutova G.G. — https://orcid.org/0009-0008-2006-0197
Kalinin P.L. — https://orcid.org/0000-0001-9333-9473
Corresponding author: Kutin M.A. — e-mail: Kutin@nsi.ru

TO CITE THIS ARTICLE:
Kutin MA, Shelesko EV, Fomichev DV, Sharipov OI, Andreev DN, Chernov IV, Azarova NA, Strunina YuV, Donskoy AD, Rastvorova OA, Adueva DSh, Konyashin DA, Maksyutova GG, Kalinin PL. Asymmetric sliding knots for microsutures for skull base defect repair after transnasal endoscopic surgery. *Burdenko's Journal of Neurosurgery*. 2026;90(3):73–77. (In Russ.). https://doi.org/10.17116/neiro20269003173

Introduction

Effective, hermetic and durable closure of skull base defect is essential for safe transnasal resection of various tumors. This is especially important in surgeries followed by large defects of bones and dura mater. Failed repair can result in meningitis or redo interventions in case of nasal cerebrospinal fluid leakage.

The gold standard for closure of such defects is a multilayer «sandwich» of various patient-derived tissues and artificial materials [1]. Autologous fascia is a versatile, accessible, and most popular autologous material. Additionally, adipose

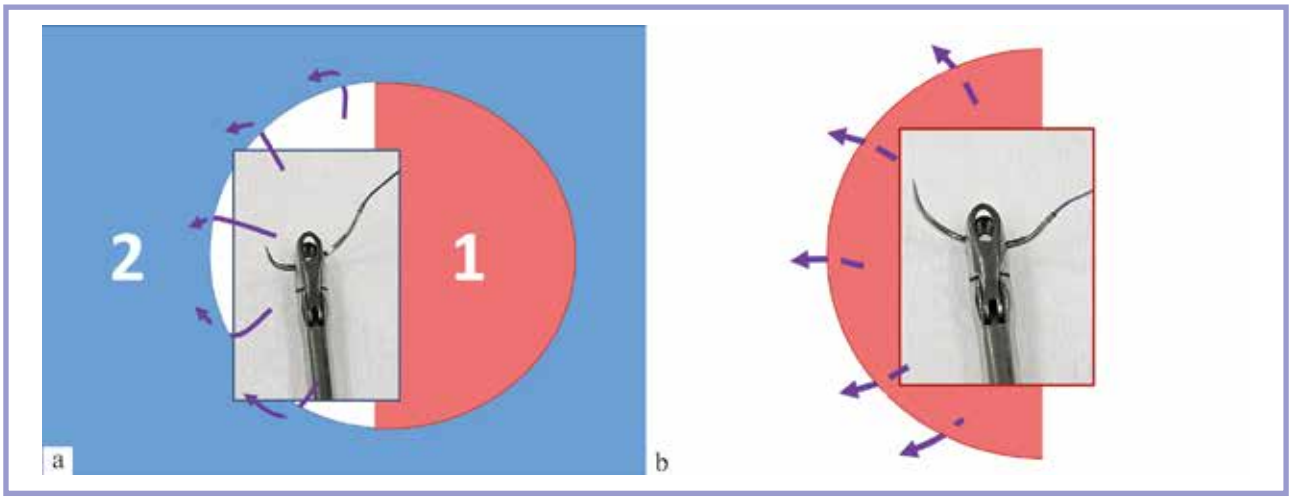

Fig. 1. **Needle holding and direction of insertion through the edge of dura mater (a) and fascial flap (b).**
a — needle insertion to dura mater edge «from the inside». The needle is directed at acute angle towards the surgeon; b — needle insertion to fascial flap edge «inward» (from sphenoid sinus towards cranial cavity). The needle is directed at obtuse angle away from the surgeon. 1 — fascial flap; 2 — dura mater. Purple arrows indicate possible suture locations on the example of dura mater edge on the right side of surgical wound.

tissue and autologous bone (usually nasal septum) are used [1]. Vascularized mucoperiosteal flaps decreased the incidence of postoperative CSF leakage from 40–70% to 5% [1]. Such a flap is typically placed as one of the final layers.

There are several options for fixing the fascial flap. The most common method («gasket seal») involves nasal septum bone for defect closure and fixation of fascia [2]. There are rare studies on fixing the fascial graft with various clips (Chorath K. 2019; Teramoto S. 2020; Gardner P. 2008). Microsutures were also described for bringing the edges of dura mater together and fixing the autologous fascial flap (Hara T. 2022; Liu Z. 2022; Sakamoto N. 2013; Gardner P. 2008, Shkarbuo A.N. 2023). Some authors suggest clips to fix the knot of suture (Shkarubo A.N. 2023).

In the Burdenko Neurosurgery Center, we have long used the interrupted microsutures requiring a specially developed instrument developed by Shkarubo A.N. We found no reports with large samples describing the results of microsutures.

The purpose of this study was to evaluate the feasibility of asymmetrical sliding knots to form microsutures in transnasal endoscopic skull base repair.

Material and methods

We have performed 25 transnasal endoscopic surgeries through anterior and posterior extended approaches between May 2022 and March 2024. Free autologous fascial flap was fixed to dura mater edges using asymmetrical sliding microsutures without additional instruments. Age of patients ranged from 2.1 to 60 years. There were 16 women and 9 men. Resection of craniopharyngioma was performed in 19 cases, pituitary adenoma — 1, meningocele — 1, sinonasal carcinoma — 2, chondrosarcoma — 1, chordoma — 1 case.

Four patients underwent anterior skull base defect closure (meningocele, sinonasal carcinomas and chondrosarcoma). There were central skull base defects in 20 cases (sella turcica and posterior sphenoid bone after resection of craniopharyngioma and pituitary adenoma) and clivus defect associated with chordoma in 1 case.

Dimensions of anterior skull base defects (4 surgeries) ranged from 6×11 (in 1 case) to 20×25 mm (in 3 cases). Dimensions of central skull base defects (21 surgeries) ranged

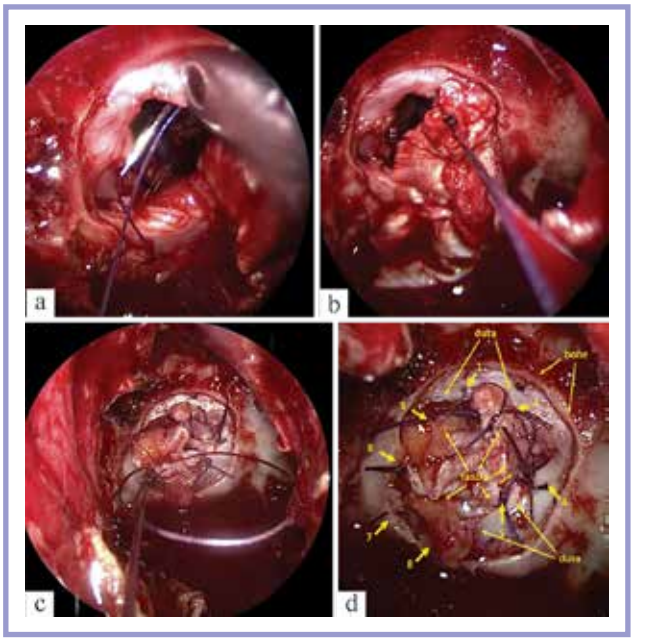

Fig. 2. **Microsuture placement in multilayer skull base defect closure after transnasal resection of craniopharyngioma.**
a—c — interrupted microsuture placement near anterior wall and tubercle of sella turcica; d — free fragment of autologous fascia sutured into dura mater defect. The numbers indicate sequence of suture placement. Bone — edge of trephine window near anterior wall of sella turcica and lower parts of tubercle of sella turcica formed for resection of tumor; dura — dura mater edge; fascia — free fascial flap with small fragments of autologous fat tissue fixed to dura mater edge with interrupted sutures.

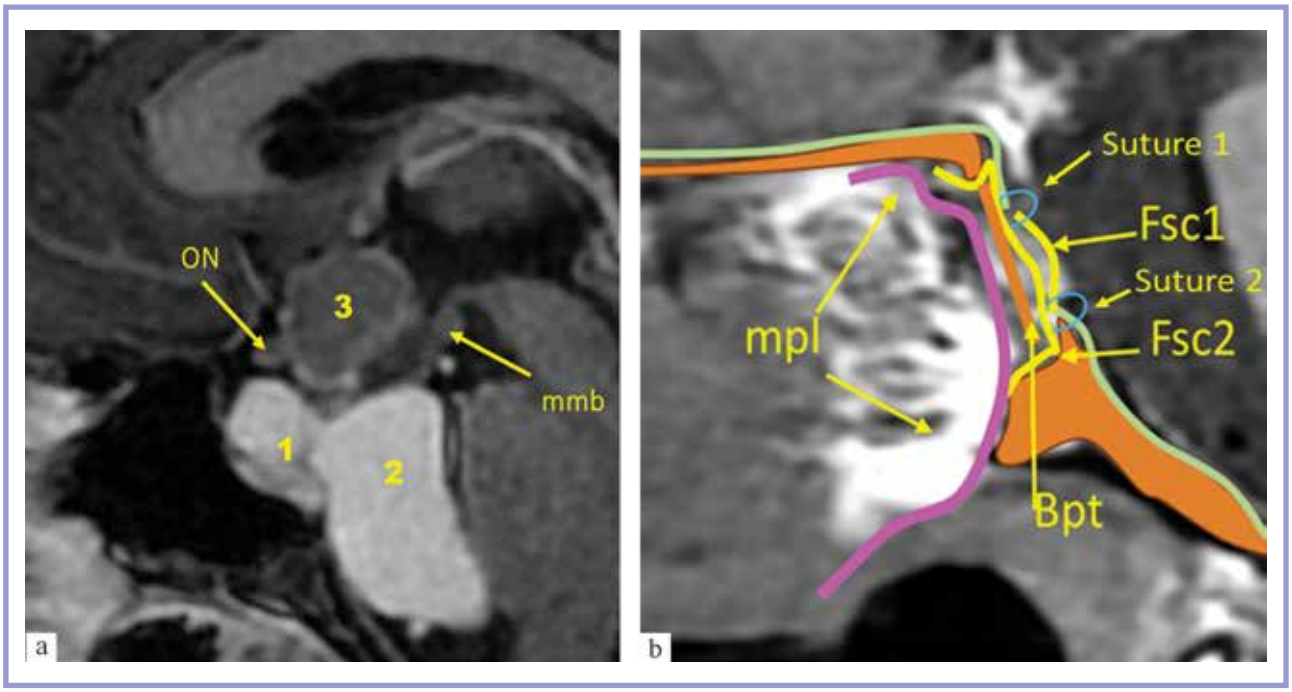

Fig. 3. **Microsutures in multilayer skull base defect closure after transnasal resection of craniopharyngioma.**
a — preoperative MRI. Multilocular cystic craniopharyngioma; 1–3 — tumor cysts; ON — optic chiasm; mmb — mamillary bodies; b — scheme of multilayer reconstruction. Green line is dura mater. Bone plate and skull base bones are colored orange, free fragment of autologous fascia – yellow lines, microsutures – blue rings; Suture — microsuture; Fsc — autologous fascia; Bpt — free bone plate; mpl — mucoperiosteal flap.

from 6×8 mm (in one case) to 10×14 mm (in 3 cases). Dura mater defect accounted for 30—80% of bone defect area.

All surgeries were performed using 4 mm rigid endoscopes. We performed skull base defect closure using a previously described multilayer technique. The last one ensures low risk of postoperative cerebrospinal fluid leakage (no more than 7%). The first layer was free autologous fascial flap. Microsutures were used to fix this fascia to dura mater edges. In 3 cases, the second layer was nasal septum autograft tucked behind the bone defect edges. The third layer was mucoperiosteal flap. We sealed reconstruction with fibrin-thrombin glue. Mucoperiosteal flap was not used for multilayer repair in only three cases of anterior skull base defect closure. This was due to septal tissue lesion. Autologous fascial flap was 30—50% larger than dura mater defect. The purpose of microsutures was fixation of the first layer of repair at the dura mater level so that materials of other layers (fascia, bone plate and mucoperiosteal flap) could be placed. In case of small bone defect (<10 mm) and available bone plate, we found no need to place more than one microsuture. In such cases, microsuture was placed at the highest point of dura mater defect (at 12 o'clock). This allowed us to retain autologous fascia within dura mater defect. Lateral and lower fascial edges were fixed with bone plate («gasket seal» technique).

In other cases, we were able to place 2—8 interrupted sutures. In one patient with large dura mater defect in anterior cranial fossa, we fixed fascial flap with two continuous sutures.

To place the suture, we clamped the needle in standard BLAKESLEY rongeurs (Karl Storz, Germany) that served as a needle holder. Direction of needle varied depending on «insertion» and «extraction» **(Fig. 1)**. Fascial flap fixation during suturing required additional instruments (small curettes, dissecting tools, and suction devices). Assistant used this instrument.

We tried various needle sizes and threads. Needles with 7—0 and 8—0 thread were difficult to use due to small size. They were used for anterior skull base defect closure in a 2.1-year-old child after resection of meningocele. In all other cases, we used a 12 mm 3/8» atraumatic needle with 5-0 thread. We did not alter the needle's configuration during insertion. We did not create additional bends or kinks, but sometimes increased curvature.

After passing the thread through the fascial flap and dura mater edge, the end of the thread with the needle was fixed in the surgeon's hand. Free end of suture was wrapped around this thread after forming a loop. After 3—4 turns around the fixed thread, the free end of the thread was passed through the loop. The surgeon began to pull on the «main» end of the thread with the needle. The loop and the turns of the free end of the thread, wrapped around the «main» end, began to descend along the «main» thread into the wound. Once tissues to be brought together were reached, the knot was tightened. Both ends of suture were cut with microscissors. Examples of suture placement are presented in **Fig. 2, 3**, scheme of suture – in **Fig. 4b**.

Results

Microsutures required skill, time and patience. The first few sutures took up to 40 min per a suture. We were able to do this without specialized instruments. In all 25 cases, sliding knot

technique was followed by hermetic skull base defect closure without postoperative cerebrospinal fluid leakage. Meningitis developed in one case. Twelve patients had high lumbar cerebrospinal fluid pressure (up to 200—250 mm H2O) according to early postoperative lumbar puncture. In 2 patients, this value was 400 mm H2O. However, there was no postoperative cerebrospinal fluid leakage.

In addition to 25 successful closures, we encountered 4 cases where suturing was impossible. In the first case, no accessible free edge of dura mater remained in the wound after resection of large clival chordoma. In the second case (resection of ventricular craniopharyngioma), tumor-inflated hypothalamic infundibulum descended to the level of sella turcica and remained pressed against the dura mater after tumor resection leaving no edge free of brain tissue. In the third case, supraclinoid segments of internal carotid arteries were close to dura mater edge after resection of craniopharyngioma. This made needle insertion risky. In the fourth case, resection of clival chordoma resulted in so deep and narrow bone wound that the needle could be inserted into the wound and dura mater, but safe rotation for subsequent extraction was impossible. Multilayer repair in these patients was performed according to the previously described principles, and no postoperative nasal cerebrospinal fluid leakage was observed.

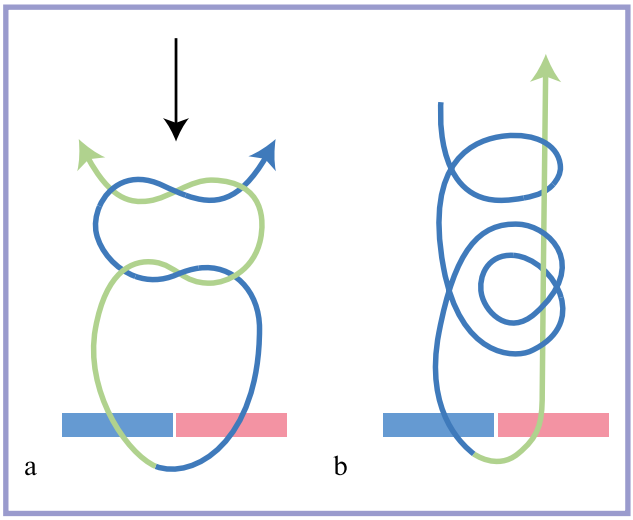

Fig. 4. **Symmetrical complex (a) and asymmetrical sliding (b) surgical knots. Schemes are based on drawings from the monograph by I.V. Sleptsov and R.A. Chernikov (2000).**
Two ends of a single thread are marked in green and blue; arrows indicate thread tension direction during knotting. Blue rectangle — dura mater edge, pink rectangle — edge of autologous fascia flap. White arrow indicates direction of necessary movement of the knot loop when inserting into a narrow deep wound. Various instruments can be used for this purpose, such as a U-shaped instrument (Shkarubo A.N. et al., Patent No. 2144326 C1, Russian Federation, IPC A61B 17/04, A61B 17/00, A61B 17/03. Instrument for guiding and shaping knots in a narrow, deep wound, 1999).

Discussion

Symmetrical knots consisting of 2—3 loops with various numbers of entanglements in each are the most common in surgery **(Fig. 4a)**. To tie a knot securely, both ends of the thread must be pulled taut. Depending on complexity of the first loop, it either holds thread tension itself or must be pressed down with instrument or finger (Sleptsov I.V., Chernikov R.A. Knots in surgery. 2000). Additional instruments are necessary to insert the knot into a deep wound. For such insertion, Professor A.N. Shkarubo developed a special U-shaped instrument (Shkarubo A.N. et al. Patent No. 2144326 C1 Russian Federation, IPC A61B 17/04, A61B 17/00, A61B 17/03. Instrument for guiding and shaping knots in narrow and deep wound, 1999). The main advantage of this instrument is available insertion of any number of loops into the wound when forming a knot (2—3—4). This enables formation of effective, symmetrical and complex knots with uniform and controlled tension. Unfortunately, neither national nor foreign medical industries have mastered production of such a simple, yet highly sought-after instrument.

In addition to symmetrical knots with both halves of suture moving during tightening, there is a group of «sliding» knots. The last ones involve movement of one half of suture, intricately wrapped around the other stationary half **(Fig. 4b)**. Tension and movement of one «main» end of suture are sufficient to tighten a sliding knot. The second «wrapped» end is inserted into the wound to form the knot itself. This knot is tightened by tensioning only one end of the suture. Free end may be short that significantly saves suture material in deep wounds. These knots do not involve additional loops that makes them less dense but prone to unraveling under traction on elastic tissues they hold together (Sleptsov I.V., Chernikov R.A. Knots in surgery, 2000). The main advantage of such knots is insertion into deep wounds without additional instruments.

We successfully mastered asymmetric sliding sutures in transnasal endoscopic skull base defect closure. Our experience demonstrates that fascial flap fixation with microsutures improves the quality of skull base defect repair in extended endoscopic approaches. Single asymmetric sliding sutures do not provide complete sealing, they are clearly less effective than symmetrical complex knots. However, these sutures ensure adequate fascial fixation and foundation for other layers of repair. Unfortunately, decision-making on microsutures for fixation may only intraoperative. To preserve dura mater for subsequent microsutures, we recommend a diamond burr for bone resection. This burr can also be used to enlarge trephine defect at the end of surgery for visualization of dura mater edge and suturing.

In our opinion, the sample consisting of 25 cases appears insufficient to conclude that original method of fascial flap fixation definitively eliminates the risk of postoperative cerebrospinal fluid leakage. However, certain trend allows for further data collection for subsequent statistical analysis.

Conclusion

This small series confirmed the feasibility and reliability of asymmetrical sliding knots to form microsutures in transnasal endoscopic skull base repair. We described the key techni-

cal parameters of sutures, specifics of needle insertion through the dura mater and free fascial flap, as well as limitations and difficulties encountered during the implementation of this technique. Sliding interrupted microsutures can be recommended for forming a strong layer of autologous tissues in multilayer skull base defect repair after transnasal endoscopic surgery.

Interrupted microsutures in transnasal endoscopic surgeries may be imposed without additional instrumentation. Microsutures for fascial fixation in skull base defect closure not only do not eliminate the need for multilayer reconstruction but also complement it. Microsutures are possible in case of appropriate anatomical and intraoperative conditions in surgical wound and adequate surgical experience. Multilayer reconstruction supplemented with microsutures has high mechanical strength that is important for patients with a tendency to increased intracranial pressure before and especially after surgery.

Author contribution:
Concept and design of the study — Kutin M.A., Kalinin P.L., Shelesko E.V.
Data collection — Kutin M.A., Kalinin P.L., Shelesko E.V., Fomichev D.V., Sharipov O.I., Andreev D.N., Chernov I.V., Chernikova N.V.
Statistical analysis — Kutin M.A., Sharipov O.I., Strunina Yu.V.
Editing — Rastvorova O.A., Adueva D.Sh., Konyashin D.A., Maksyutova G.G.

The authors declare no conflicts of interests.

REFERENCES

1. Khan DZ, Ali AMS, Koh CH, Dorward NL, Grieve J, Layard Horsfall H, Muirhead W, Santarius T, Van Furth WR, Zamanipoor Najafabadi AH, Marcus HJ. Skull base repair following endonasal pituitary and skull base tumour resection: a systematic review. *Pituitary*. 2021;24(5):698-713 https://doi.org/10.1007/s11102-021-01145-4
2. Albonette-Felicio T, Martinez-Perez R, Vankoevering K, Hardesty DA, Otto BA, Carrau RL, Prevedello DM. Soft Gasket Seal Reconstruction After Endoscopic Endonasal Transtuberculum Resection of Craniopharyngiomas. *World Neurosurg*. Jun 2022;162:e35-e40 https://doi.org/10.1016/j.wneu.2021.12.058
3. Rao KN, Arora RD, Sharma A, Mehta R, Satpute S, Dange P, Nagarkar NM. Endoscopic Sellar Defect Reconstruction with Avascular Modified Gasket Seal Technique for Sellar Tumors. *Indian J Surg Oncol*. Mar 2024;15(1):71-77 https://doi.org/10.1007/s13193-023-01826-5
4. Teramoto S, Tahara S, Hattori Y, Morita A. Skull Base Dural Closure Using a Modified Nonpenetrating Clip Device via an Endoscopic Endonasal Approach: Technical Note. *Neurol Med Chir (Tokyo)*. 2020;60(10):514-519, https://doi.org/10.2176/nmc.tn.2020-0103
5. Gardner P, Kassam A, Snyderman C, Mintz A, Carrau R, Moossy JJ. Endoscopic endonasal suturing of dural reconstruction grafts: a novel application of the U-Clip technology. Technical note. *J Neurosurg*. 2008;108(2):395-400 https://doi.org/10.3171/JNS/2008/108/2/0395
6. Hara T, Akutsu H, Tanaka S, Kino H, Miyamoto H, Ii R, Takano S, Ishikawa E. Risk Factors for Postoperative Cerebrospinal Fluid Leak after Graded Multilayer Cranial Base Repair with Suturing via the Endoscopic Endonasal Approach. *Neurol Med Chir (Tokyo)*. 2022;63(2):48-57 https://doi.org/10.2176/jns-nmc.2022-0132
7. Liu Z, Zhao L, Wang Y, Dai K, Lu A, Zhao P. Application of dural suturing in the endoscopic endonasal approach to the sellar region. *Front Surg*. 2022;9 https://doi.org/10.3389/fsurg.2022.9446
8. Sakamoto N, Akutsu H, Takano S, Yamamoto T, Matsumura A. Useful 'sliding-lock-knot' technique for suturing dural patch to prevent cerebrospinal fluid leakage after extended transsphenoidal surgery. *Surg Neurol Int*. 2013;4, https://doi.org/10.4103/2152-7806.10754
9. Shkarubo AN, Andreev DN, Chernov IV, Yegorovich SM. Surgical Correction of a Clivus Cerebrospinal Fluid Fistula: A Technical Report. World Neurosurg. Aug 2021;152:114-120 https://doi.org/10.1016/j.wneu.2021.06.061
10. Slepczov IV, Chernikov RA. Uzly` v xirurgii. SPb: Salit-Medkniga; 2000.

Received 07.10.2025
Accepted 12.03.2026

COMMENT

The authors present literature data and own experience on cerebrospinal fluid space sealing after resection of skull base tumors. Postoperative cerebrospinal fluid leakage, as well as inflammatory complications as often concomitant events, is a significant factor impairing postoperative quality of life. Complete and high-quality closure of intracranial space and elimination of postoperative cerebrospinal fluid leakage are undoubtedly important.

Original asymmetrical sliding knots for graft fixation are an interesting neurosurgical solution. While they do not provide 100% sealing, these sutures minimize «incorrect» graft positioning and reduce the risk of cerebrospinal fluid leakage. Larger samples and comparison with other methods are clearly needed. The same is true guidelines and recommendations for cases where this technique is indispensable for completing surgery. Perhaps, the problem of defect closure in the future will be linked to other technologies (more convenient and hermetic adhesives than those currently available worldwide). At this stage, graft fixation with various sutures is a promising surgical solution for endoscopic skull base neurosurgery.

A similar analysis is rare in the literature. Original method is innovative. Considering obvious difficulties of sealing, this report allows for a fresh look at this problem and development of new surgical options.

Cherebillo V.Yu. (Saint Petersburg)