Burdenko's Journal of Neurosurgery
2026, No. 3, pp. 58–64
https://doi.org/10.17116/neiro20269003158

Sagittal balance parameters in choice of surgical strategy for degenerative lumbosacral spinal stenosis

© D.I. Shtadler[1, 2], V.D. Shtadler[1—3], G.A. Fukalov[1], M.S. Staroverov[1, 3, 4], E.M. Balakina[1], D.D. Khirevich[1], N.A. Vdovina[1], A.A. Grin[3, 5]

[1]Perm City Clinical Hospital No.4, Perm, Russia;
[2]Wagner Perm State Medical University, Perm, Russia;
[3]Pirogov Russian National Research Medical University, Moscow, Russia;
[4]Federal Brain and Neurotechnology Center, Moscow, Russia;
[5]Sklifosovsky Research Institute for Emergency Care, Moscow, Russia

ABSTRACT

Objective. To determine the indications for surgical correction of lumbar lordosis in patients with multilevel degenerative lumbosacral spinal stenosis.

Material and methods. A prospective pilot study was conducted at the Perm City Clinical Hospital No. 4 between 2022 and 2025. Patients with multilevel degenerative lumbosacral spinal stenosis presenting with clinical manifestations of compressive syndromes, as well as persistent back pain refractory to conservative treatment, were enrolled. All patients underwent the following additional examinations: pain assessment (VAS scores), functional status (the Oswestry Disability Index and the Roland—Morris Disability Questionnaire), standing full-spine radiography with calculation of sagittal balance parameters.

Results. The study group consisted of 22 patients with multilevel lumbar spinal stenosis at the following levels: L3—L4—L5 in 6 (27.3%) patients, L4—L5—S1 in 13 (59.1%) patients, and L2—L3—L4—L5 in 3 (13.6%) patients. Mean pathological reduction of lumbar lordosis relative to individual normative value was 17.8° (min 8.3°, max 22.6°). All patients underwent surgical intervention. After 3 postoperative months, standing radiographs demonstrated achievement of target lumbar lordosis along with regression of neurological symptoms in all patients. VAS score of pain decreased by 2.8 times (95% CI 1.7—4.2). Disability according to the Roland-Morris questionnaire improved by 3.3 times (95% CI 2.1—4.7). Quality of life across various domains assessed by the Oswestry Disability Index improved by 3.1 times (95% CI 1.1—3.8).

Conclusion. In patients with multilevel degenerative lumbosacral spinal stenosis (Schizas grade C or D) accompanied by compressive syndromes and drug-resistant back pain, surgical interventions are indicated for reduced lumbar lordosis and impairment of at least one sagittal balance parameter, including pelvic angle, pelvic tilt, ThI pelvic angle, sagittal vertical axis. Correction of lumbar lordosis in this patient population results in significant reduction of back pain and QoL improvement.

Keywords: *degenerative spine disease, lumbar lordosis, pelvic angle, pelvic tilt, ThI pelvic angle, sagittal vertical axis, spinal deformity, selection algorithm for lumbar lordosis correction.*

INFORMATION ABOUT THE AUTHORS:
Shtadler D.I. — https://orcid.org/0000-0001-5222-0628
Shtadler V.D. — https://orcid.org/0000-0002-7584-3083
Fukalov G.A. — https://orcid.org/0000-0003-1744-492X
Staroverov M.S. — https://orcid.org/0000-0002-7341-797X
Balakina E.M. — https://orcid.org/0000-0002-1475-858X
Khirevich D.D. — https://orcid.org/0000-0002-0000-244X
Vdovina N.A. — https://orcid.org/0009-0000-8624-4134
Grin A.A. — https://orcid.org/0000-0003-3515-8329
Corresponding author: Shtadler V.D. — e-mail: vladislav.shtadler@gmail.com

TO CITE THIS ARTICLE:
Shtadler DI, Shtadler VD, Fukalov GA, Staroverov MS, Balakina EM, Khirevich DD, Vdovina NA, Grin AA. Sagittal balance parameters in choice of surgical strategy for degenerative lumbosacral spinal stenosis. *Burdenko's Journal of Neurosurgery*. 2026;90(3):58—64. (In Russ.). https://doi.org/10.17116/neiro20269003158

Introduction

Degenerative lumbosacral spinal stenosis with compression syndromes is often accompanied by lumbar hypolordosis and subsequent drug-resistant back pain [1—3]. Underestimation of this deformity in sagittal plane when choosing surgical treatment can lead to poor clinical outcomes [4]. However, such assessment is currently not widely used in clinical practice.

The purpose of this study was to determine the indications for surgical correction of lumbar lordosis in patients with multiple-level degenerative lumbosacral spinal stenosis.

Table 1. **Normal LL depending on PI [1].**

PI, °	LL, °
28–37.9	46.7–59.9
38–47.9	47.5–63.5
48–57.9	53.1–69.9
58–67.9	63.2–73.4
68–77.9	68.1–81.7
78–87.9	67.7–84.4

Table 2. **Reference sagittal balance parameters depending on age [5].**

Age, years	PT, °	PI–LL, °	LL–TK, °	SVA, mm	TPA, °
	Upper limit	Upper limit	Lower limit	Upper limit	Upper limit
<35	13.2	1.8	24.5	5	9.8
35–44	17	5.9	17.6	27.6	15
45–54	19.7	8.8	12.6	44	18.8
55–64	22.2	11.5	8.2	58.5	22.2
65–74	24.6	14.1	3.8	72.8	25.5
>74	27.1	16.9	–1	88.2	29.1

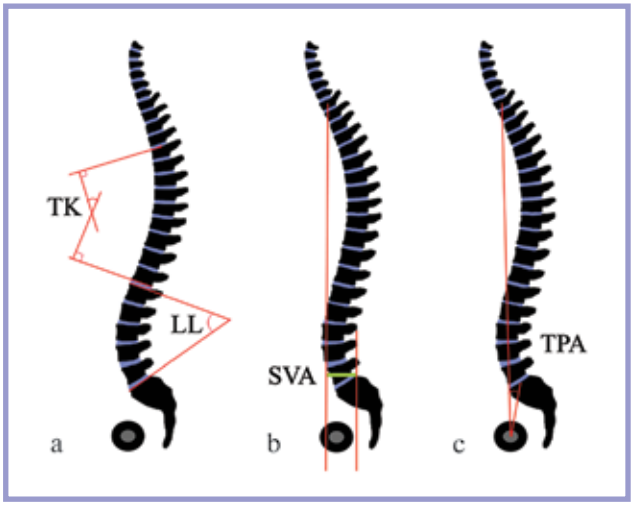

Fig. 1. **Scheme of sagittal balance parameters of the spine.**
a — lumbar lordosis (LL) — angle between LI superior endplate and SI endplate, thoracic kyphosis —angle between Th4 superior endplate and Th12 inferior endplate; b — SVA — horizontal distance between a plumb line dropped from the center of the C7 vertebra and a plumb line dropped from posterior edge of SI endplate (green segment); c — Th1 pelvic angle (TPA) — angle between the line from the femoral head axis to the center of the T1 vertebra and the line from the femoral head axis to the center of the superior S1 endplate.

Material and methods

A prospective pilot study was conducted at the Perm City Clinical Hospital No. 4 in 2022—2025. There were patients with MRI-verified multiple-level degenerative spinal stenosis (MRI within 1 month before baseline examination, stenosis Schizas class C or D for each level) and compression syndromes, as well as drug-resistant back pain.

Each patient underwent the following in-hospital examinations:

1. VAS, ODI and RMDQ scores.
2. Vertical spinal radiography in a standing position after 10-minute walking to exclude silent «dynamic» pelvic retroversion followed by assessment of lumbar lordosis **(Fig. 1a)**. In case of hypolordosis, we analyzed 5 sagittal balance parameters associated with quality of life [4—6] **(Table 1, 2)**:

— pelvic tilt (PT) **(Fig. 2b)**;
— difference between pelvic incidence (PI) and lumbar lordosis (PI—LL);
— difference between lumbar lordosis and thoracic kyphosis (TK) (LL—TK) **(Fig. 1a)**;
— sagittal vertical axis (SVA) **(Fig. 1b)**;
— ThI pelvic angle (TPA) **(Fig. 1c)**.

Inclusion criteria:

1) VAS score >5;
2) LL below reference values **(Table 1)**;
3) at least one abnormal sagittal balance parameter **(Table 2)**.

Exclusion criteria:

1) decompensated comorbidities;
2) obesity grade II/III;
3) age >70 years;
4) previous lumbosacral spine surgery;
5) no informed consent for surgery.

Repair of each level included transpedicular screw placement, arcotomy, flavotomy, bilateral facetectomy, partial resection of spinous processes, transforaminal disc removal followed by cage placement in ventral position to achieve maximum angulation. Correction was achieved by maximal screw head contraction (approximately 5—7° at one level).

We assessed neurological status and VAS scores of pain in early postoperative period (3—4 days after surgery). After 3 postoperative months, assessment of VAS, ODI and RMDQ scores was accompanied by vertical spine radiography in standing position after 10-minute walk with analysis of sagittal balance parameters.

Results

Over the entire period, there were 243 patients with multiple-level degenerative lumbosacral spinal stenosis verified by MRI and symptoms of compression syndromes, as well as drug-resistant back pain.

We distinguished the following groups after vertical radiography with assessment of lumbosacral spine deformity:

— patients with normal LL (n=146, 60.1%);
— patients with reduced LL and abnormal sagittal balance parameters (n=31, 12.7%);
— patients with reduced LL and normal sagittal balance parameters (n=43, 17.7%);
— patients with increased LL (n=23, 9.5%).

Twenty-eight (11.5%) patients were eligible. Subsequently, 6 patients were withdrawn according to exclusion criteria.

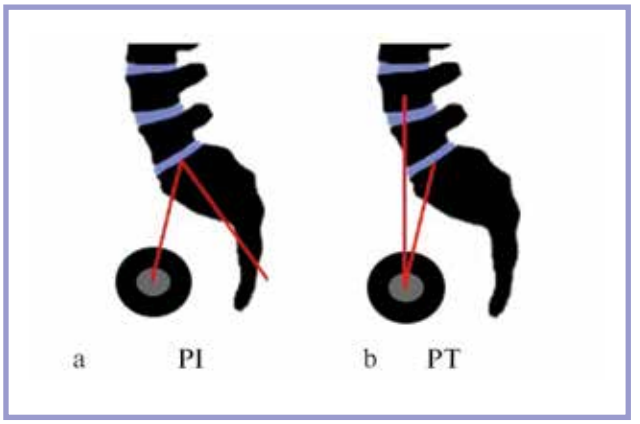

Fig. 2. **Pelvic parameters of sagittal balance.**
a — pelvic incidence (PI) —angle between the line connecting the center of the femoral heads with the middle of the SI endplate and the line perpendicular to the SI endplate; b — pelvic tilt (PT) — angle between the vertical line passed through the center of the femoral heads and the line connecting the middle of the SI endplate with the center of the femoral heads.

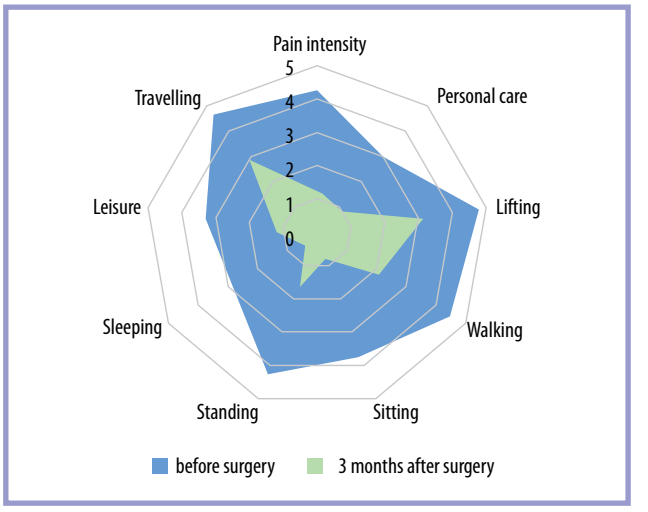

Fig. 3. **Outcomes of lumbosacral spinal decompression with subsequent LL correction (ODI). Scores are indicated on the axis (*n*=22).**

Therefore, the study group consisted of 22 (9.1%) patients. There were 14 (63.6%) women and 8 (36.4%) men. Mean age was 59.7 [min 48, max 68] years.

MRI of the lumbosacral spine revealed multiple-level spinal stenosis at the following levels:
— LIII—LIV—LV — 6 patients (27.3%);
— LIV—LV—SI — 13 patients (59.1%);
— LII—LIII—LIV—LV — 3 patients (13.6%).

Mean LL decrease from individual norm was 17.8° [min 8.3°, max 22.6°]. Mean VAS score was 8.3 [min 6, max 10], ODI score — 76.3% [min 60%, max 100%], RMDQ score — 15.3 [min 12, max 24].

All patients underwent surgical decompression and correction. Extent of osteotomy and transforaminal discectomy followed by cage placement in ventral position was standardized for each level. Extent of transpedicular fixation corresponded to the affected segments.

Postoperative examination revealed regression of neurological symptoms in all cases. Mean VAS score was 3.1 [min 2, max 5], postoperative hospital-stay — 13.3 days [min 10, max 21]. Patients were discharged after wound healing and removal of sutures.

Three months after surgery, we observed target LL and sagittal balance parameters along with regression of neurological symptoms in all patients. VAS scores decreased by 2.8 times [95% CI 1.7—4.2], RMDQ score improved by 3.3 times [95% CI: 2.1—4.7], ODI score — by 3.1 times [95% CI: 1.1—3.8] **(Fig. 3)**.

Algorithm for assessing sagittal spinal deformity in patients with degenerative lumbosacral stenosis

We can align 4 groups of patients with multiple-level degenerative lumbosacral stenosis depending on changes in LL and sagittal balance parameters:
1) patients with normal LL;
2) patients with reduced LL and impaired sagittal balance parameters;
3) patients with reduced LL and normal sagittal balance parameters;
4) patients with increased LL.

In turn, all surgical interventions for degenerative spinal stenosis can be divided into four strategies with decreasing surgical aggression **(Fig. 4)**:
1) lumbosacral spine decompression with LL correction;
2) lumbosacral spine decompression and fusion without LL correction — in situ fixation;
3) lumbosacral spine decompression (a — open, b — endoscopic);
4) interventional treatment or therapy for pain syndromes.

The 1st and 4th groups with normal or increased LL do not require corrective interventions. Therefore, any strategy can be selected depending on morphology and severity of degenerative process, with the exception of the 1st strategy involving correction.

The 1st surgical strategy is preferable in patients with decreased LL and at least one abnormal sagittal balance parameter **(Table 2)**. Indeed, correction of deformity in this case improves postoperative outcomes and reduces the incidence of adjacent-level disease. Furthermore, spinal fusion without normal LL is unacceptable in such patients and leads to poor clinical outcomes **(Fig. 5)** [7, 8]. Open or endoscopic decompressive intervention, interventional treatment or therapy (strategy 3 or 4) depending on morphology and severity of degenerative process are preferable in patients with decompensated comorbidities, high anesthetic risks, severe obesity and other contraindications to lumbosacral spine reconstruction.

Patients with reduced LL and normal sagittal balance parameters (group 3) do not require corrective intervention due to no clear data on the impact of such deformity on quality of life. The studies with data on correlation between LL and QoL impairment comprised patients with concomitant disorders of sagittal balance parameters [1—6]. These patients are prioritized for decompres-

less aggressive treatment

1 strategy	decompression + LL correction
2 strategy	decompression + fixation *in situ*
3a strategy	open (endoscopic) decompression
36 strategy	endoscopic decompression
4 strategy	interventional treatment / therapy

Fig. 4. **Treatment strategies for degenerative lumbosacral spine stenosis.**

sive procedures, interventional treatment or therapy (strategies 3 or 4). The feasibility of in situ fixation (strategy 2) for these patients remains unresolved. In our opinion, such interventions can lead to breakdown of natural compensatory mechanisms and adjacent-level syndrome **(Fig. 6)**.

A 60-year-old patient complained of back pain (VAS score 8) radiating to legs, as well as leg weakness after walking short distances (<100 m). These symptoms occurred 2 years ago and worsened over time. Objective examination revealed neurogenic claudication and decreased patellar and Achilles reflexes on both sides. MRI of the lumbosacral spine revealed spinal stenosis LIII—LIV and LIV—LV, as well as LIV anterolisthesis **(Fig. 7a, b)**. Spinal radiography in standing position revealed LL decrease to 49.3° (individual norm 63.2—73.4°) **(Table 1)** and imbalance of sagittal balance parameters with PT increase to 28.3° — retroversion (individual norm <22.2°) and TPA increase to 24° (individual norm <22.2°) **(Table 2)**. This may be considered an error in calculations **(Fig. 7c)**.

The patient underwent arcotomy, flavotomy, bilateral facetectomy LIII—LIV—LV, partial resection of spinous processes at the same levels and transforaminal removal of LIII—LIV—LV discs. LL correction implied transpedicular system and ventrally positioned cages LIII—LIV—LV with maximum angle at these levels.

Three months later, we observed complete regression of back pain and neurological symptoms with LL 60.3° and PT 20° **(Fig. 8)**.

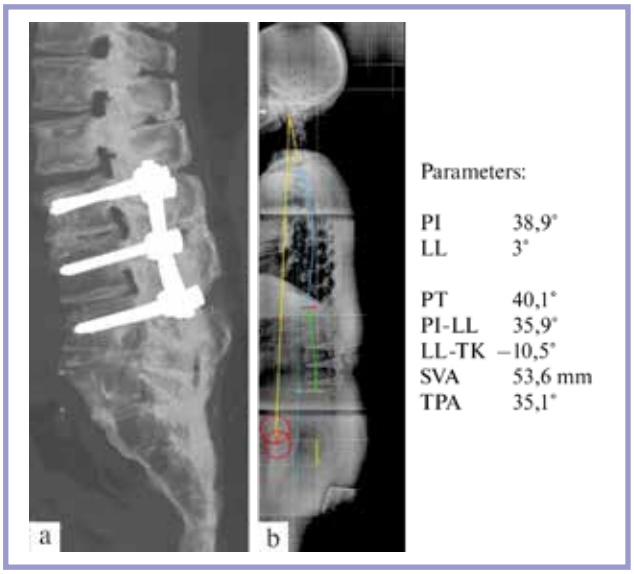

Fig. 5. **A 69-year-old patient with complaints of severe back pain and walking with additional support. Examination confirmed artificial LIII–LV block after intracanal neurovascular decompression and transpedicular fixation at these levels in malposition.**
a — CT of the lumbosacral spine; b — standing spinal column X-ray image with analysis of sagittal balance parameters.

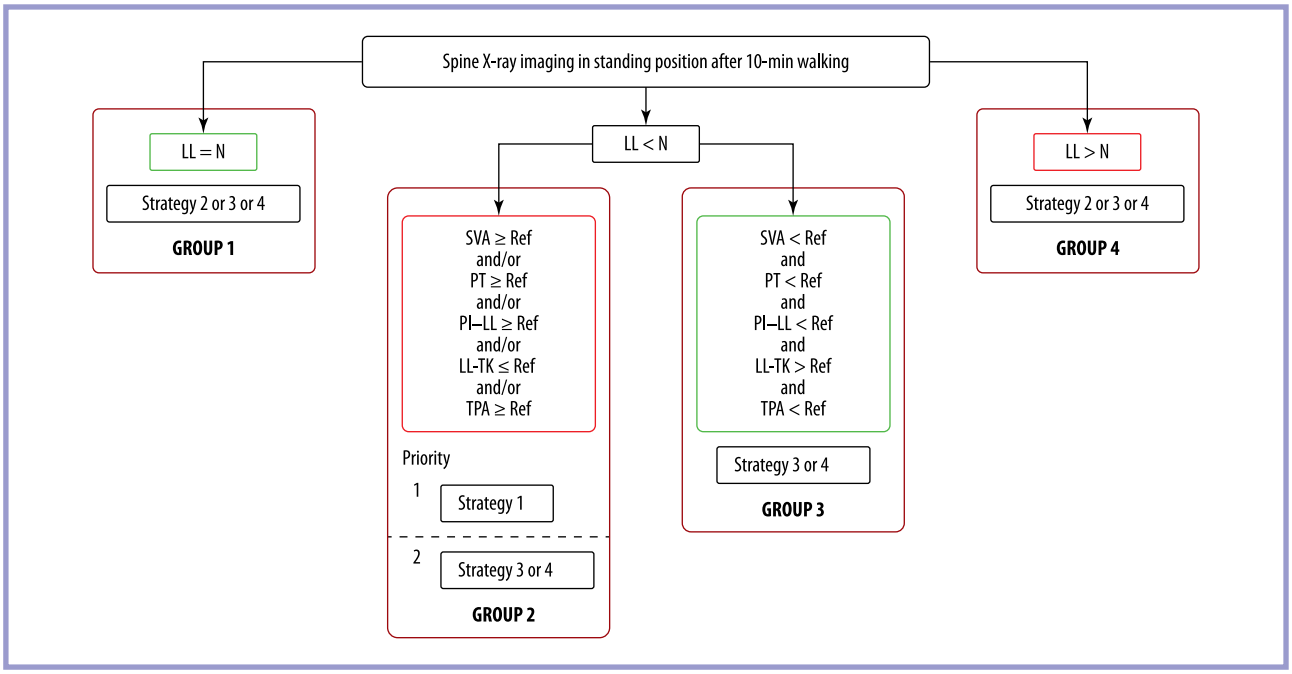

Fig. 6. **Algorithm for surgical strategy depending on sagittal balance parameters.**
Ref — reference sagittal balance parameters depending on age.

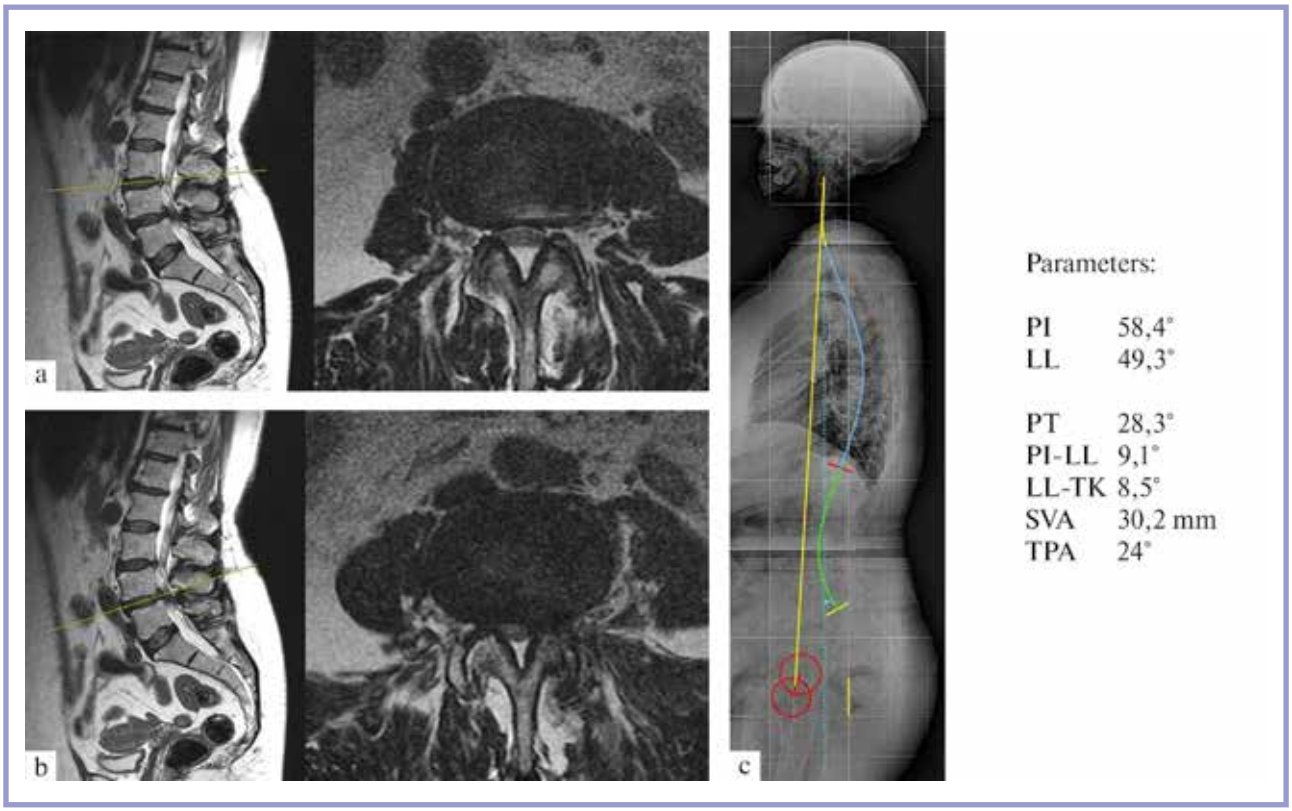

Fig. 7. **Preoperative examination.**
a — MRI of the lumbosacral spine, sagittal scan at the level of LIII–LIV. Combined spinal stenosis; b — sagittal scan at the level of LIV–LV. Combined spinal stenosis, LIV anterolisthesis; c — spine X-ray imaging *n* standing position with calculation of sagittal balance parameters.

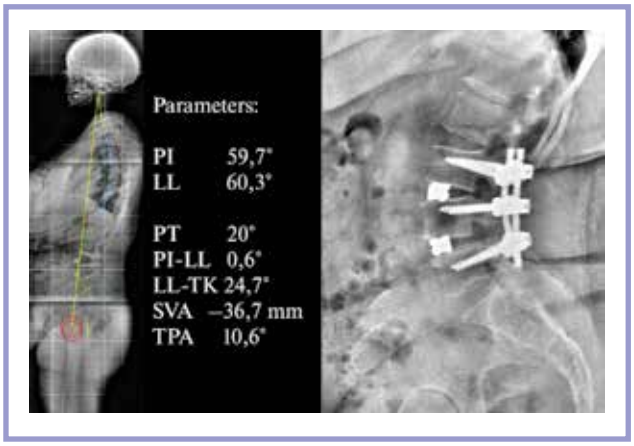

Fig. 8. **Spinal radiography in standing position with analysis of sagittal balance parameters three months after surgery.**

Discussion

Patient selection for spine decompression and fusion is difficult due to complex biomechanics of upright posture and multiple factors influencing back pain, including modifiable and non-modifiable lifestyle factors.

In 2019, the International Spine Study Group proposed the MISDEF2 (Minimally Invasive Spinal Deformity Surgery) patient selection algorithm for reconstructive interventions. This algorithm primarily assesses stability of deformity. The last one implies analysis of sagittal balance parameters in supine and standing positions. Correction is recommended in case of fixed deformity and impaired parameters [9]. In our opinion, the limitations of this study are no assessment of muscular function and personalized selection of sagittal balance reference values depending on age and congenital PI. The last one does not change throughout life since it is an individual constant for each patient [1].

A unified and validated approach to treating symptomatic lumbosacral spinal stenosis is one of the main challenges in modern vertebrology. This issue requires multiple-center studies involving personalized patient rehabilitation in addition to surgical treatment.

Conclusion

Patients with multiple-level degenerative lumbosacral spinal stenosis (Schizas class C or D) and compression syndromes, as well as drug-resistant back pain with decreased lumbar lordosis and at least one abnormal sagittal balance parameter (PT, PI—LL, LL—TK, SVA and TPA) are recommended to undergo decompressive and fusion surgery. These procedures are aimed at re-

storing normal LL in addition to decompression. Correction of lumbar lordosis in these patients leads to back pain relief and QoL improvement.

Author contribution:
Concept and design of the study— Shtadler D.I., Shtadler V.D., Grin A.A.
Collection and analysis of data — Fukalov G.A., Staroverov M.S., Balakina E.M., Khirevich D.D., Vdovina N.A.
Statistical analysis — Shtadler V.D.
Writing the text — Shtadler V.D., Fukalov G.A.
Editing — Shtadler D.I., Grin A.A.
The authors declare no conflicts of interests.

REFERENCES

1. Barrey C, Jund J, Noseda O, Roussouly P. Sagittal balance of the pelvis-spine complex and lumbar degenerative diseases. A comparative study about 85 cases. *European Spine Journal*. 2007;16(9):1459-1467. https://doi.org/10.1007/s00586-006-0294-6
2. Sarkar R, Sarkar S, Keswani S, Sah AK, Bhattacharjee S. Correlation of Sagittal Spinopelvic Alignment Parameters With Pain and Functional Disability in Chronic Non-specific Low Back Pain. *Cureus*. 2025;17(10):e95747. https://doi.org/10.7759/cureus.95747
3. Teraguchi M, Hashizume H, Asai Y, Oka H, Nagata K, Ishimoto Y, Iwasaki H, Tsutsui S, Takami M, Tanaka S, Yoshida M, Yoshimura N, Yamada H. Association between modic changes, disc degeneration, and pelvic incidence-lumbar lordosis mismatch in a large population based cohort: the Wakayama spine study. *European Spine Journal*. 2023. https://doi.org/10.1007/s00586-023-07702-8
4. Klimov VS, Vasilenko II, Evsyukov AV, Amelina EV. Impact of sagittal balance parameters on life quality in elderly and senile patients after surgery for degenerative lumbar spine stenosis. *Burdenko's Journal of Neurosurgery*. 2017;81(2):56-66. (In Russ., In Engl.). https://doi.org/10.17116/neiro201781256-66
5. Lafage R, Schwab F, Challier V, Henry JK, Gum J, Smith J, Hostin R, Shaffrey C, Kim HJ, Ames C, Scheer J, Klineberg E, Bess S, Burton D, Lafage V; International Spine Study Group. Defining Spino-Pelvic Alignment Thresholds: Should Operative Goals in Adult Spinal Deformity Surgery Account for Age? *Spine*. 2016;41(1):62-68. https://doi.org/10.1097/BRS.0000000000001171
6. Singh M, Kuharski MJ, Abdel-Megid H, Balmaceno-Criss M, Knebel A, Daher M, Nassar JE, Basques B, Kuris EO, Diebo BG, Daniels AH. Impact of Segmental Lordosis Restoration During Degenerative Spinal Fusion on Two-year Adjacent Segment Disease and Revision Rates. *Spine*. 2025;50(17):1219-1224. https://doi.org/10.1097/BRS.0000000000005161
7. Varol E. Influence of Spinopelvic Alignment on the Clinical Outcomes Following Decompression Surgery for Lumbar Stenosis. *Cureus*. 2023;15(10):e46302. https://doi.org/10.7759/cureus.46302
8. Mummaneni PV, Park P, Shaffrey CI, Wang MY, Uribe JS, Fessler RG, Chou D, Kanter AS, Okonkwo DO, Mundis GM, Eastlack RK, Nunley PD, Anand N, Virk MS, Lenke LG, Than KD, Robinson LC, Fu KM; International Spine Study Group (ISSG). The MISDEF2 algorithm: an updated algorithm for patient selection in minimally invasive deformity surgery. *Journal of Neurosurgery. Spine*. 2019;32(2):221-228. https://doi.org/10.3171/2019.7.SPINE181104

Received 23.07.2024
Revised 26.01.2026
Accepted 12.03.2026

COMMENT

Surgical treatment of spine and spinal cord diseases is one of the most difficult in modern vertebrology. Improving surgical treatment for degenerative spinal diseases is currently a priority in spinal neurosurgery, traumatology, and orthopedics. Lumbar spine degeneration is especially important due to high incidence. Degenerative spinal diseases are the leading cause of all orthopedic diseases in adults (>40%), and 81% of these lesions are localized in lumbosacral segments. Currently, surgical treatment is preferable for severe lumbar spine degeneration. Primary goals of surgery are spinal cord decompression and prevention of spinal motion segment instability, including stabilization systems if necessary. There is a risk of unsatisfactory long-term results despite successful fusion. Sagittal imbalance, spinopelvic alignment disorders, length of metal implant and the need for LL correction are widely discussed in modern literature. However, significance of these factors is still unclear. Furthermore, correlation between clinical and radiographic findings is not established.

This study is important considering 230% increase in the incidence of surgical interventions for degenerative spinal stenosis in elderly patients over the past 10 years. Annual incidence of surgical interventions for spinal stenosis in general population ranges from 3 to 11.5 per 100.000. Thousands and even hundreds of thousands of lumbar spine decompression and fusion procedures are performed annually worldwide. Importantly, the number of appropriate specialists is also increasing. Thanks to national healthcare program, the number of federal centers with available high-tech spinal surgeries is also increasing. However, there is a stable problem of complications in patients with multiple-level degenerative spinal stenosis. To address this, one group of surgeons refuse fusion and perform only multiple-level microdecompression with favorable results including spontaneous correction of sagittal balance. Another group of surgeons (authors of this article) is attempting to assess the shortcomings and underestimations of spinal sagittal balance correction (spine-pelvic relationships, lumbar lordosis, etc.) in decompression and fusion procedures.

This report is written in rather complex language. The authors use numerous terms and calculations. Of course, it is impossible to explain this terminology in a few words. However, this terminology is understand-

able for specialists involved in surgical treatment of degenerative spinal lesions.

The authors excluded patients over 70 years old, but this is a primary age group requiring surgical treatment for spinal stenosis. The authors most likely excluded this group due to comorbidities and severe concomitant diseases, including osteoporosis. According to authors' data, LL correction in patients with multiple-level degenerative lumbosacral spinal stenosis, drug-resistant symptoms and impaired sagittal balance reduces back pain and improves quality of life. Three months after correction of lumbar lordosis and sagittal balance parameters, the authors noted target spinal-pelvic parameters and regression of neurological symptoms in all patients.

Of course, this study needs to be evaluated over longer periods (after 1, 2 or more years), and postoperative rehabilitation period should be taken into account for these patients. A unified treatment algorithm for these patients requires a multiple-center study.

Konovalov N.A., Brinyuk E.S. (Moscow)