Burdenko's Journal of Neurosurgery
2026, No. 3, pp. 43–47
https://doi.org/10.17116/neiro20269003143

Sectoral schwannomatosis of the lower extremities

© A.V. Gorodnina, D.A. Sitovskaya, A.Yu Orlov

Polenov Russian Research Neurosurgical Institute, Saint-Petersburg, Russia

ABSTRACT

Introduction. Sectoral schwannomatosis is a rare disease with damage to one nerve of the limb by multiple tumors without pathological foci in other anatomical areas. Surgery is the optimal treatment for segmental schwannomatosis and progression of clinical manifestations.

Objective. To present our own experience in surgical treatment of patients with segmental schwannomatosis of the sciatic nerve and its branches over the past 5 years.

Material and methods. The authors present 3 patients with sectoral schwannomatosis of the sciatic nerve who underwent surgical treatment. All patients underwent total nerve-sparing resection of tumors.

Conclusion. Management of sectoral schwannomatosis is individual, although surgical treatment involving total nerve-sparing tumor resection is preferable. Further data collection is necessary for a more detailed analysis of segmental schwannomatosis.

Keywords: *schwannomatosis, sciatic nerve, sectoral schwannomatosis, segmental schwannomatosis, peripheral nerve tumor, schwannoma.*

INFORMATION ABOUT THE AUTHORS:
Gorodnina A.V. — https://orcid.org/0000-0002-4431-375X
Sitovskaya D.A. — https://orcid.org/0000-0001-9721-3872
Orlov A.Yu. — https://orcid.org/0000-0001-6597-3733
Corresponding author: Gorodnina A.V. — e-mail: angelinagorodnina@gmail.com

TO CITE THIS ARTICLE:
Gorodnina AV, Sitovskaya DA, Orlov AYu. Sectoral schwannomatosis of the lower extremities. *Burdenko's Journal of Neurosurgery*. 2026;90(3):43–47. (In Russ.). https://doi.org/10.17116/neiro20269003143

Introduction

Schwannomas are benign tumors arising from Schwann cells. These tumors can affect peripheral nerves and/or spinal roots [1, 2].

Solitary schwannomas are a common disease accounting for 29-34% of all peripheral nerve tumors [3]. Multiple schwannomas affecting one of the main nerves of the limb are called «segmental schwannomatosis». These lesions are rare [4].

The purpose of this report was to present our experience in surgical treatment of patients with segmental schwannomatosis of sciatic nerve over the past 5 years.

Material and methods

The article presents 3 patients who underwent surgical treatment for multiple tumors of sciatic nerve and its branches between 2021 and 2025.

Case # 1

A 37-year-old patient presented with severe pain (BAS score 10) in the left leg, specifically in popliteal region, lower thigh and upper leg. She underwent the first surgery for tumor of the left foot at 17 years old. No histological examination was performed.

According to ultrasound data, the left sciatic nerve was not clearly visible beneath the piriformis and gluteus maximus muscles. There were no lesions in its projection. Thigh ultrasound revealed multiple ovoid-shaped nerve lesions with clear, even contours, heterogeneous structure and unevenly reduced echogenicity. Doppler ultrasound revealed vascularization of these lesions. Between the lower and middle thirds of the thigh, dimensions of lesion #1 were 37×30×25 mm. In popliteal region, focal lesion 44×23×18 mm was adjacent to popliteal vein with partial compression. Below sciatic nerve bifurcation, the left tibial nerve had uneven thickness along entire length. At the middle third of the leg, this nerve contained ovoid-shaped lesions 3x4x3 and 5x3x3 mm with clear even contours, heterogeneous structure and unevenly reduced echogenicity. Doppler ultrasound revealed their vascularization. At the level of medial malleolus 10 mm proximal to nerve bifurcation, there was the 3rd lesion 22x22x17 mm. The peroneal nerve was intact. MRI revealed multiple space lesions along sciatic nerve in the lower third of the thigh and popliteal region with spread to tibial nerve **(Fig. 1)**.



Fig. 1. **Case #1. Magnetic resonance imaging, T2WI. a — coronal scan; b — sagittal scan.**

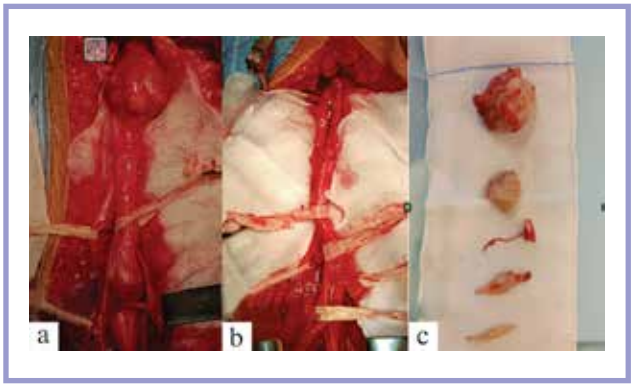

Fig. 2. **Case #1. Intraoperative images. a — multiple sciatic nerve tumors; b — sciatic nerve after resection of tumor; c — tumor nodules after excision.**

Electroneuromyography (ENMG) revealed no conduction disturbances.

There was drug-resistant pain syndrome. Palpation revealed sharply tender, rounded, dense nodules in popliteal region. The Tinel sign was positive. There were no cutaneous manifestations of neurofibromatosis.

Microsurgical resection of tumors of the left sciatic and tibial nerves was performed under ENMG monitoring. A total of five tumors were excised. Sciatic nerve and its branches were intact as evidenced by responses following nerve stimulation **(Fig. 2)**. There was postoperative regression of pain and no movement disorders.

Histological examination revealed benign, biphasic, encapsulated solid tumor with moderate cellularity, alternating fascicular areas, Verocay bodies (Antoni pattern A) and loosely arranged cells with rounded lymphocyte-like nuclei and optically empty cytoplasm (Antoni pattern B) **(Fig. 3)**.

The patient was discharged on the 8th postoperative day.

Case # 2

A 35-year-old patient was diagnosed with focal lesions of the left sciatic nerve and its branches after examination following previous knee injury. Upon admission, there was moderate pain (VAS score 6). Palpation revealed a round, dense, mobile mass in the lower third of the thigh. There was no family history of neurofibromatosis, and no skin manifestations such as café au lait spots were detected. MRI revealed multiple mass lesions in the left sciatic nerve (more in tibial and peroneal parts) at the level of the lower third of the thigh with clear smooth contours.

ENMG revealed no conduction disturbances.

Resection of tumor was performed along the peroneal and tibial nerves without damage to sciatic nerve and its portions **(Fig. 4)**. Motor responses were intact after direct nerve stimulation. A total of 3 large tumors and more than 10 small nodules were excised.

There was postoperative regression of pain with intact muscle strength. Peroneal neuropathy with paresthesias regressed by the fifth postoperative day. Histological examination revealed benign biphasic solid tumor with moderate-to-high cellular density consisting of elongated bipolar cells with oval nuclei (Antoni pattern A). There were small reticular foci consisted of loosely arranged cells with rounded lymphocyte-like nuclei and optically empty cytoplasm (Antoni pattern B). Severe degenerative polymorphism and nuclear hyperchromatosis, epithelioid cell clusters, tumor stromal fibrosis, moderate angiomatosis, severe hyalinosis of vascular walls and hemosiderin depositions were found. No necrosis or mitotic figures were noted. There was focal lymphocytic infiltration. The patient was discharged on the 6th postoperative day.

Case # 3

A 33-year-old patient complained of pain in the left lower leg and popliteal induration. Clinical presentation included severe pain (VAS score 8) and positive Tinel sign. Palpation revealed a round painful firm tumor in the upper third of the lower leg.

MRI revealed multiple solid, rounded and well-defined soft tissue tumor of the middle and lower thirds of the leg and popliteal fossa of the left lower extremity along tibial nerve.

Total resection of 3 tumors was performed under ENMG monitoring while preserving the nerve **(Fig. 5)**.

Pain completely regressed after surgery, while neurological data remained the same.

Histological examination revealed biphasic tumor with moderate cellularity, alternating areas of hypercellularity, rhythmic structures similar to Verocay bodies (Antoni A pattern). There were large reticular foci consisted of loosely arranged cells with rounded lymphocyte-like nuclei and optically empty cytoplasm (Anthony B pattern) with myxoid areas. We found moderate degenerative polymorphism and nuclear hyperchromatosis along with mild formation of collagen and «grated carrot» structures. Moderate angiomatosis and hyalinosis of vascular walls were present. There was no necrosis or mitosis. The tumor was enclosed in thin fibrous capsule.

The patient was discharged on the sixth postoperative day.

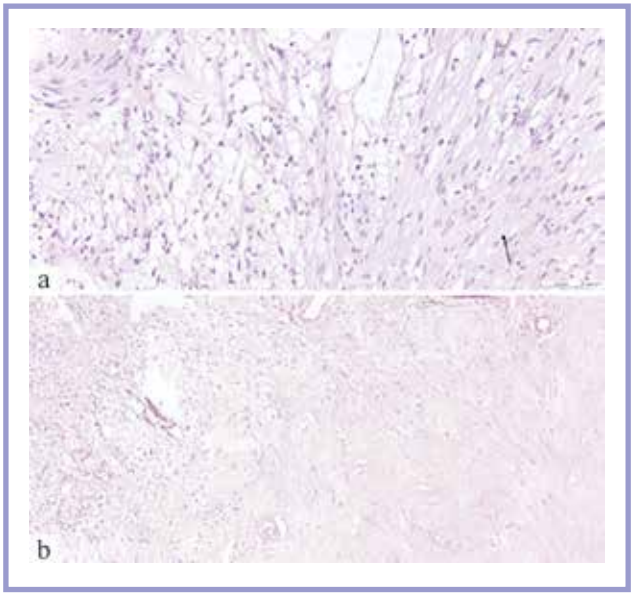

Fig. 3. **Case # 1. Histological data. Hematoxylin and eosin staining.**
a — benign biphasic peripheral nerve sheath tumor characterized by foci of reticular and compact (arrowed) structure, ×200; b — massive stromal sclerosis (*), angiomatosis with hyalinosis of vascular walls, ×100.

Discussion

According to the WHO classification (2021), schwannoma is a benign tumor of cranial and spinal nerves [5]. Segmental or sectoral schwannomatosis is a rare lesion by multiple tumors of one of the main nerves of the limb, half of the body or five adjacent spinal segments without similar lesions in other areas of the body [6, 7]. The incidence of segmental schwannomatosis is 0.58 cases per million people [10].

The term «segmental schwannomatosis» was first proposed in 1973 and used in 1984 in a report devoted to multiple schwannomas without signs of neurofibromatosis [8].

Some authors classify segmental schwannomatosis as neurofibromatosis type 3. In our opinion, this is incorrect, since histological type of tumor, molecular genetic data, clinical manifestations and neuroimaging features differ from neurofibromatosis [9].

The etiology and pathogenesis of schwannomatosis are still unclear. To date, it is clear that all target genes associated with schwannomatosis are located on chromosome 22 [11, 12]. In 2005, MacCollin M. et al. [13] proposed diagnostic criteria for schwannomatosis based on presence/absence of vestibular and intradermal tumors and presence of isolated segmental tumor pools. All three cases in our sample met possible criteria for schwannomatosis.

Clinical presentation of segmental schwannomatosis is primarily pain progressing with tumor growth. At the onset of disease, patients report firm rounded palpable nodules. Tumor enlargement is followed by severe drug-resistant pain [14]. Movement disorders are extremely rare in segmental schwannomatosis and were not described in the literature over the past 10 years.

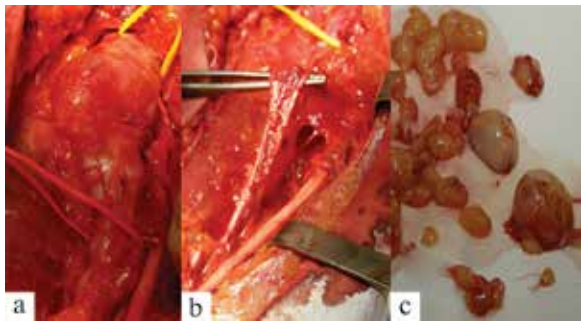

Fig. 4. **Case #2. Intraoperative images.**
a — tumors inside the nerve; b — sciatic nerve after tumor resection (divided into portions); c — excised tumor nodules.



Fig. 5. **Case # 3. Intraoperative image. Tibial nerve tumors.**

Segmental schwannomatosis differs from neurofibromatosis by the absence of cutaneous manifestations, namely, café-au-lait spots and cutaneous neurofibromas [14, 15].

A retrospective analysis of database at the Polenov Russian Research Institute revealed that sectoral schwannomatosis of peripheral nerves predominantly affects women.

Eccentric tumors are typical for schwannomas, while central nodules indicate neurofibroma. Contrast enhancement demonstrates homogeneous pattern for a single schwannoma, while multiple schwannomas in segmental schwannomatosis may enhance heterogeneously [15]. Features of imaging and differences in contrast enhancement do not affect surgical treatment.

ENMG is mandatory for any peripheral nerve lesion to clarify the level of damage and involvement of nerves proximal and distal to damage site, as well as to confirm the diagnosis. In our sample, ENMG found no disturbances. This was most likely due to the absence of motor impairments.

ENMG is mandatory for surgical intervention. Direct nerve stimulation allows for differentiation of branches potentially involved in tumor capsule, avoiding their resection with subsequent nerve dysfunction. In our sample,

all patients underwent ENMG-guided surgery with favorable functional outcomes in all cases [16].

Currently, ultrasound is one of the primary diagnostic methods for patients with peripheral nerve lesions. Preoperative ultrasound may be used in patients with contraindications to MRI. Intraoperative ultrasound is valuable for marking of surgical approach, analysis of tumor localization and visualization of nerve segments above and below surgical site, pathological foci in its structure not visualized by MRI [17, 18].

Conclusion

Segmental schwannomatosis may be asymptomatic for a long time. Subsequent severe pain is associated with tumor enlargement. Surgical treatment is optimal and effective for complete regression of pain syndrome. Intraoperative neurophysiological monitoring is necessary. Our cases demonstrate total resection of multiple tumors of sciatic nerve and its branches without nerve dysfunction.

Author contribution:
Concept and design of the study — Gorodnina A.V.
Collection and analysis of data — Gorodnina A.V., Sitovskaya D.A.
Statistical analysis — Gorodnina A.V.
Writing the text — Gorodnina A.V., Sitovskaya D.A.
Editing — Orlov A.Yu.

The authors declare no conflicts of interest.

REFERENCES

1. Matsko MV, Matsko ED. Neuro-oncology, 2021. Brief analysis of the new World Health Organization classification of tumors of the central nervous system. *Vestnik of Saint Petersburg University. Medicine.* 2022;17(2):88-100. (In Russ.). https://doi.org/10.21638/spbu11.2022.202
2. Kwon NY, Oh HM, Ko YJ. Multiple lower extremity mononeuropathies by segmental schwannomatosis: a case report. *Annals of Rehabilitation Medicine.* 2015;39(5):833-837. https://doi.org/10.5535/arm.2015.39.5.833
3. Belakhoua SM, Rodriguez FJ. Diagnostic pathology of tumors of peripheral nerve. *Neurosurgery.* 2021;88(3):443-456. https://doi.org/10.1093/neuros/nyab021
4. Warade A, Roy R, Pattankar S, Pasricha P, Desai K. Segmental schwannomatosis of the lower extremity — a case series. *Neurology India.* 2022;70(5):2132-2136. https://doi.org/10.4103/0028-3886.359176
5. WHO Classification of Tumours Editorial Board. *Central nervous system tumours*. 5th ed. Lyon (France): International Agency for Research on Cancer; 2021. (WHO Classification of Tumours; vol. 6).
6. Andreani L, Ipponi E, Ruinato AD, Falcinelli F, De Franco S, D'Arienzo A, Capanna R. Peripheral schwannomas of the tibial nerve: surgical results in a case series. *Acta Biomedica.* 2022;93(1):e2022085. https://doi.org/10.23750/abm.v93i1.11782
7. Shaterian A, Ozyurekoglu T. A linear variant of segmental schwannomatosis socalized to the upper extremity. *Journal of Hand and Microsurgery.* 2020;14(2):160-162. https://doi.org/10.1055/s-0040-1715424
8. Shishiba T, Niimura M, Ohtsuka F, Tsuru N. Multiple cutaneous neurilemmomas as a skin manifestation of neurilemmomatosis. *Journal of the American Academy Dermatology*. 1984;10(5 Pt 1):744-754. https://doi.org/10.1016/s0190-9622(84)70089-2
9. Ferner RE. Neurofibromatosis 1 and neurofibromatosis 2: a twenty first century perspective. *The Lancet Neurology.* 2007;6(4):340-351. https://doi.org/10.1016/S1474-4422(07)70075-3
10. Erdoğan F, Say F, Barış YS. Schwannomatosis of the sciatic nerve: a case report. *British Journal of Neurosurgery.* 2023;37(1):100-103. https://doi.org/10.1080/02688697.2021.1950628
11. Plotkin SR, Messiaen L, Legius E, Pancza P, Avery RA, Blakeley JO, Babovic-Vuksanovic D, Ferner R, Fisher MJ, Friedman JM, Giovannini M, Gutmann DH, Hanemann CO, Kalamarides M, Kehrer-Sawatzki H, Korf BR, Mautner VF, MacCollin M, Papi L, Rauen KA, Riccardi V, Schorry E, Smith MJ, Stemmer-Rachamimov A, Stevenson DA, Ullrich NJ, Viskochil D, Wimmer K, Yohay K; International Consensus Group on Neurofibromatosis Diagnostic Criteria (I-NF-DC); Huson SM, Wolkenstein P, Evans DG. Updated diagnostic criteria and nomenclature for neurofibromatosis type 2 and schwannomatosis: An international consensus recommendation. *Genetics in Medicine.*2022;24(9):1967-1977. https://doi.org/10.1016/j.gim.2022.05.007
12. Makashova ES, Zolotova SV, Absalyamova OV, Galkin MV, Petrokovskaya AV, Kozlov AV, Golanov AV. New classification and approaches to the treatment of schwannomatosis. *Burdenko's Journal of Neurosurgery.* 2023;87(5):104-109. (In Russ.). https://doi.org/10.17116/neiro202387051104
13. MacCollin M, Chiocca EA, Evans DG, Friedman JM, Horvitz R, Jaramillo D, Lev M, Mautner VF, Niimura M, Plotkin SR, Sang CN, Stemmer-Rachamimov A, Roach ES. Diagnostic criteria for schwannomatosis. *Neurology.* 2005;64(11):1838-1845. https://doi.org/10.1212/01.WNL.0000163982.78900.AD
14. Alaidarous A, Parfait B, Ferkal S, Cohen J, Wolkenstein P, Mazereeuw-Hautier J. Segmental schwannomatosis: characteristics in 12 patients. *Orphanet Journal of Rare Diseases.* 2019;14(1):207. https://doi.org/10.1186/s13023-019-1176-4
15. Pilavaki M, Chourmouzi D, Kiziridou A, Skordalaki A, Zarampoukas T, Drevelengas A. Imaging of peripheral nerve sheath tumors with pathologic correlation: pictorial review. *European Journal of Radiology*. 2004;52(3):229-239. https://doi.org/10.1016/j.ejrad.2003.12.001
16. Guzzi G, Ricciuti RA, Della Torre A, Lo Turco E, Lavano A, Longhini F, La Torre D. Intraoperative Neurophysiological Monitoring in Neurosurgery. *Journal of Clinical Medicine.* 2024;13(10):2966. https://doi.org/10.3390/jcm13102966
17. Simfukwe K, Iakimov I, Sufianov R, Borba L, Mastronardi L, Shumadalova A. Application of Intraoperative Ultrasound Navigation in Neurosurgery. *Frontiers in Surgery.* 2022;9:900986. https://doi.org/10.3389/fsurg.2022.900986
18. Hannaford A, Vucic S, Kiernan MC, Simon NG. Review Article «Spotlight on Ultrasonography in the Diagnosis of Peripheral Nerve Disease: The Evidence to Date». *International Journal of General Medicine.* 2021;14:4579-4604. https://doi.org/10.2147/IJGM.S295851

Received 08.07.2025
Accepted 12.03.2026

COMMENT

This article discusses surgical treatment of multiple schwannomas (schwannomatosis) of peripheral nerves. Solitary (single) schwannomas are usually not associated with genetic syndrome. In contrast, multiple schwannomas with similar histological nature are associated with mutations in the SMARCB1 or LZTR1 genes. Because of this, schwannomatosis is sometimes incorrectly classified as neurofibromatosis type III.

The authors present own experience in surgical treatment of schwannomatosis in 3 patients with multiple sciatic nerve lesions. Clinical manifestations, modern diagnostic methods and surgical treatment are discussed. The authors compare own clinical data with results of international studies to assess compliance of findings with current global trends.

The authors' results are generally consistent with other data on this issue. However, studies on peripheral nerve tumors over the past decade note that schwannomas have more affinity for sensory fibers of peripheral nerves. They can also affect only motor fibers, but in a smaller percentage of cases.

In this regard, it seems appropriate to suggest that the authors examine in more detail the hypothesis of more common lesions of sensory fibers in patients with peripheral nerve tumors. Accordingly, motor function will be intact or affected to a lesser extent after surgical treatment. This should be considered when assessing surgical risks of schwannomatosis. However, this in no way diminishes the need for microsurgical techniques and intraoperative monitoring as a part of mandatory algorithm for such interventions.

Shtok A.V. (Moscow)