Burdenko's Journal of Neurosurgery
2026, No. 3, pp. 37–41
https://doi.org/10.17116/neiro20269003137

Causes and microbiological spectrum of brain abscesses: modern data

© A.I. Baranich[1, 2], A.A. Sychev[1], I.A. Savin[1], N.V. Kurdyumova[1], M.V. Sukhorukova[1], Z.Sh. Veliev[1], D.S. Korotkov[1], K.O. Kakurin[3], V.G. Kudrina[3, 4]

[1]Burdenko Neurosurgical Center, Moscow, Russia;
[2]Plekhanov Russian University of Economics, Moscow, Russia;
[3]Pirogov Russian National Research Medical University, Moscow, Russia;
[4]Russian Medical Academy of Continuous Professional Education, Moscow, Russia

ABSTRACT

Brain abscesses are relatively rare, yet they are life-threatening infections with high risk of persistent neurological impairment in survivors. Effectiveness of therapy depends on understanding the range of probable pathogens. This enables optimal empirical therapy avoiding broad-spectrum combinations and associated risks of drug-drug interactions. Available Russian literature predominantly contains case reports and reviews resulting in a lack of up-to-date epidemiological data on brain abscesses.

Objective. To analyze current etiological and epidemiological data in a cohort of patients with verified brain abscesses.

Material and methods. A single-center retrospective study enrolled 41 patients with primary brain abscesses between 2022 and 2025. The diagnosis was confirmed by contrast-enhanced MRI and/or intraoperative findings. Exclusion criteria: extracranial abscess, concomitant intracranial or head soft tissue infection and recurrent abscesses.

Results. Abscesses occurred as complications of neurosurgery in 16 (39%) out of 41 patients, ENT diseases — in 4 (9.8%) cases. Odontogenic route of infection was established in 4 (9.8%) cases, and 2 (4.9%) patients had previous traumatic brain injury. Etiology was unknown in 36.6% of cases. Gram-positive cocci prevailed: Staphylococcus spp. (26.8%) and Streptococcus spp. (19.5%).

Conclusion. These data highlight the need for regular updating of local epidemiological data on brain abscesses. A thorough analysis of anamnestic data in these patients can enable informed and timely prescription of appropriate empirical antimicrobial therapy. Choice of this therapy depends crucially on spectrum of probable pathogens, especially in the absence of microbiological verification.

Keywords: *brain abscesses, CNS infections, Staphylococcus spp., infectious complications.*

INFORMATION ABOUT THE AUTHORS:
Baranich A.I. — https://orcid.org/0000-0002-1167-0742
Sychev A.A. — https://orcid.org/0000-0002-0038-1005
Savin I.A. — https://orcid.org/0000-0003-3874-4147
Kurdyumova N.V. — https://orcid.org/0000-0002-9741-0692
Sukhorukova M.V. — https://orcid.org/0000-0002-1168-2356
Veliev Z.Sh. — https://orcid.org/0009-0004-4545-8215
Korotkov D.S. — https://orcid.org/0000-0002-2204-4480
Kakurin K.O. — https://orcid.org/0009-0003-6439-8070
Kudrina V.G. — https://orcid.org/0000-0002-4329-1165
Corresponding author: Baranich A.I. — e-mail: anastasia.baranich@gmail.com

TO CITE THIS ARTICLE:
Baranich AI, Sychev AA, Savin IA, Kurdyumova NV, Sukhorukova MV, Veliev ZSh, Korotkov DS, Kakurin KO, Kudrina VG. Causes and microbiological spectrum of brain abscesses: modern data. *Burdenko's Journal of Neurosurgery.* 2026;90(3):37–41. (In Russ.). https://doi.org/10.17116/neiro20269003137

Introduction

Brain abscesses are relatively rare (0.9—1.3 cases per 100.000) and life-threatening infections with high risk of persistent neurological impairment in survivors [1—3]. Although management of these patients has significantly changed over the past decade, timely and adequate antimicrobial therapy is still a key factor for successful treatment. Its effectiveness depends on knowledge of range of likely pathogens. This enables optimal empirical therapy avoiding broad-spectrum combinations and associated risks of drug-drug interactions [4].

In available Russian-language literature, one can predominantly find case reports and reviews. This means insufficient up-to-date epidemiological data on pathogens causing brain abscesses [5, 6].

The purpose of the study was to analyze current etiological and epidemiological data in a cohort of patients with brain abscesses.

Material and methods

The study design implied a retrospective analysis of medical records of patients with primary brain abscesses hospitalized for surgical treatment between January 2022 and December 2025. The diagnosis was verified by contrast-enhanced MRI and/or intraoperative findings. Exclusion criteria were extracranial abscesses (spinal, peritoneal end of shunt, etc.), concomitant intracranial or soft tissue infection of the head, recurrent abscesses. According to standard protocol, we intraoperatively harvested material from the abscess for subsequent microbiological examination, including aerobic and anaerobic microorganisms.

Monitoring and data completeness

To ensure completeness of sample, we used data from infectious complication monitoring system of the Burdenko Neurosurgery Center. This system has been in place since 2022 and based on analysis of antibacterial prescriptions. If an infection was suspected, the attending physician consulted with antibacterial therapy team. This fact was described in medical record with appropriate data on diagnosis and treatment. Monthly auditing of all antibacterial prescriptions allowed for assessment of clinical and epidemiological indicators, as well as dynamics of in-hospital infection patterns. All cases of in-hospital abscesses were analyzed throughout the study period thanks to this system.

Results

Between January 2022 and December 2025, 64 patients with abscesses admitted in clinical departments of the Burdenko Neurosurgery Center. We excluded 23 patients with extracranial abscesses, abscesses secondary to meningitis and osteomyelitis, as well as recurrent abscesses.

Therefore, there were 41 patients with brain abscesses including 5 children aged 1—10 years. Mean age of adults was 56.1 years (range 28—78). There were 19 women and 17 men.

According to anamnestic data, 16 (39%) out of 41 patients developed abscess as a complication of neurosurgery, 4 (9.8%) — ENT disease, 4 (9.8%) — dental infection, 2 (4.9%) — traumatic brain injury (TBI). The cause was unclear in 15 (36.6%) cases, but odontogenic or otogenic genesis could not be excluded. In pediatric patients (n=5), etiologic factors were previous ENT infections (n=3), complication of neurosurgery (n=1) and unspecified cause (n=1).

Among adults and children, gram-positive cocci were the most common: Staphylococcus spp. (26.8% including 36.4% of S. aureus) and Streptococcus spp. (19.5%) **(Fig. 1)**. In some cases, these microorganisms were isolated in association with anaerobes.

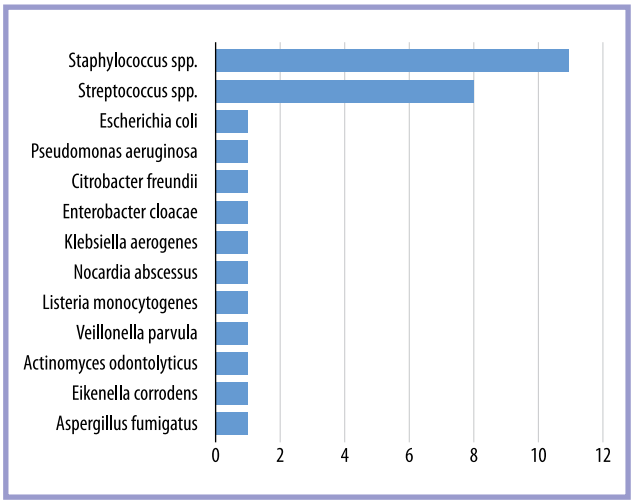

Fig. 1. **Microbiological data on brain abscesses.**

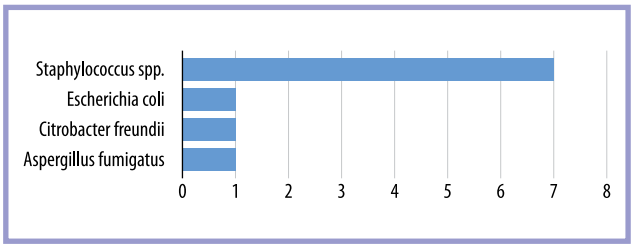

Fig. 2. **Microbiological data of postoperative brain abscesses.**

Among gram-negative microorganisms, Enterobacter cloacae, Pseudomonas aeruginosa, Citrobacter freundii, Escherichia coli, and Klebsiella aerogenes were identified in 12.2% (5/41) of patients.

Anaerobic pathogens included Eikenella corrodens, Actinomyces odontolyticus, and Veillonella parvula. Nocardia abscessus and Listeria monocytogenes were also isolated (one case each). In one case, postoperative abscess had fungal etiology (Aspergillus fumigatus).

In 31.7% of cases, cultures revealed no microbial growth. There were no patients with HIV infection. Six patients had recent radiotherapy.

Spectrum of pathogens can be largely determined by etiologic factor.

The main pathogens of postoperative abscesses were gram-positive cocci, primarily Staphylococcus spp. (7/41, 43.8%). Of these, S. aureus comprised 12.5% that describes typical pattern of nosocomial surgical infections **(Fig. 2)**. Gram-negative flora (C. freundii and E. coli) was rarer. One patient had postoperative abscess caused by Aspergillus fumigatus. Microbiological analysis found no pathogens in 6 cases that may be explained by previous empirical antibiotic therapy or technical difficulties of sampling.

In subgroup of post-traumatic abscesses, gram-negative non-fermentative bacteria and enterobacteria (P. aeruginosa and E. cloacae) prevailed. This is consistent with

general trend of identifying such flora in patients with TBI complicated by extracranial infectious processes.

Microbiological profile of odontogenic abscesses was completely consistent with oral microbiota and characterized by polymicrobial composition with aerobic and anaerobic microorganisms. There were streptococci representing normal oral flora (S. intermedius), methicillin-sensitive S. aureus and obligate anaerobes typical for periodontal lesions (V. parvula, E. corrodens, A. odontolyticus).

Among abscesses following ENT infection, microbiological analysis identified causative agent in only one case (Streptococcus intermedius).

There was cryptogenic etiology of abscess in 15 (36.6%) cases. Possible causes are anaerobic infection complicating microbiological analysis, asymptomatic chronic foci in oral cavity and previous low-symptom or undiagnosed ENT infections. Among causative agents in this subgroup, flora typical for oropharynx predominated: Streptococcus spp. (n=6) and methicillin-susceptible Staphylococcus aureus (MSSA, n=3), in association with anaerobes in one case. Klebsiella aerogenes (n=1), Nocardia abscessus, and Listeria monocytogenes (one case each) were also isolated.

Discussion

A meta-analysis by Brouwer M.C. et al. [7] covered the period between 1970 and 2013. According to their data, Streptococcus spp. (34% of all isolates) previously dominated as pathogens responsible for brain abscesses, primarily members of the viridans group (S. mitis, S. mutans, S. salivarius, S. sanguinis, S. constellatus). Staphylococcus spp. (18%) (with predominating Staphylococcus aureus) were the second most common bacteria. Gram-negative enterobacteria (Proteus spp., Klebsiella spp., Escherichia coli, etc.) accounted for 15% of all microorganisms. Prevalence of this group demonstrated geographic variability: representatives of Proteus were the cause in 7—10% of cases in Europe, Asia, and Africa versus 1.7% in North America. Klebsiella species were particularly typical for Asian region. Regarding etiologic factors, the key one (86%) was contact foci of infection including otogenic and odontogenic sources, as well as meningitis. Many abscesses (33%) were results of hematogenous metastatic processes. Abscesses as complications of TBI (14%) or neurosurgical interventions (9%) were rarer. In 19% of cases, the etiology was unknown.

Cai Y. et al. [8] analyzed 120 patients and also found Streptococcus spp. to be predominant pathogen (50% of cases). These were followed by Escherichia coli (12.9%), Fusobacteria (11.4%), Klebsiella pneumoniae (5.71%), Enterococci (4.29%), Pseudomonas aeruginosa (2.86%), and Staphylococcus spp. (2.86%). Epidemiological structure of these cases was not provided.

In contrast to these epidemiological data, our cohort demonstrated another etiological structure. The study included only patients without concomitant intracranial infections, soft tissue infections of the head or recurrent disease.

Postoperative abscess was the most common cause (39%). Otogenic or odontogenic infection was identified in 19.6% of patients, post-traumatic - in 4.9%. Etiology was unclear in 36.6% of cases, but odontogenic or otogenic source could be ruled out.

Gram-positive Staphylococcus spp. were the most common (26.8%). Prevalence of this flora is consistent with the fact that postoperative abscesses are the leading etiologic group in our cohort. This is consistent with typical pattern of surgical infections. Lange N. et al. [9] analyzed 44 patients with postoperative abscesses over a 9-year period. Staphylococcus species were isolated from 61.4% of patients. Of these, 46% had Staphylococcus aureus. In 11% of patients, microbiological examination of abscess revealed no pathogen. Streptococcus spp. more typical for otogenic and odontogenic infection routes were detected in 19.5% of cases.

Gram-negative microorganisms included Enterobacter cloacae, Pseudomonas aeruginosa, Citrobacter freundii, Escherichia coli, and Klebsiella aerogenes (12.2%). These pathogens demonstrated a clear association with infection routes: E. cloacae and P. aeruginosa were isolated in patients with post-traumatic abscesses (TBI), C. freundii and E. coli - in case of postoperative complications, K. aerogenes - in case of cryptogenic etiology.

Anaerobic pathogens (Eikenella corrodens, Actinomyces odontolyticus and Veillonella parvula) were detected exclusively in odontogenic abscesses. In one case, postoperative abscess had fungal etiology (Aspergillus fumigatus).

Rare pathogens included Nocardia abscessus and Listeria monocytogenes. Nocardia species are a group of gram-positive bacteria widely distributed in environment (soil, salt and fresh water) [10]. The leading risk factors are immunodeficiency states (HIV, corticosteroid therapy, organ transplantation, chronic pulmonary diseases) [11, 12]. Disseminated nocardiosis with CNS involvement is characterized by high mortality rate (up to 85%), predominantly in immunocompromised patients. However, brain abscesses also occur in immunocompetent individuals with mortality rate up to 20% [10]. Diagnosis of brain abscesses caused by Nocardia may be difficult due to slow growth of pathogen on nutrient media. Nocardia growth becomes noticeable only after 2—7 days [12, 13].

Listeria monocytogenes is a widespread gram-positive bacterium. The primary route of transmission is foodborne through contaminated food products. Listeriosis is often asymptomatic or presents as a mild febrile illness with gastrointestinal disturbances. Central nervous system involvement most often manifests as meningitis, but can also manifest as brain abscesses (approximately 10% of all CNS infections). Individuals with immunodeficiency are at high risk of invasive forms of infection. As an intracellular pathogen, L. monocytogenes is able to directly spread linearly through the white matter tracts [14].

Despite identification of such rare and clinically significant pathogens, the underlying trend in our cohort remains

unchanged. Our data indicate a shift in etiologic and microbiological structure of brain abscesses towards predominant postoperative cases and appropriate staphylococcal flora. This differs from historical data. This likely reflects the overall trend of increasing number of neurosurgical interventions.

Conclusion

Thus, these data highlight the need for regular updating of local epidemiological data on brain abscesses. A thorough history collection in these patients can enable reasonable and timely prescription of adequate baseline empirical antimicrobial therapy. Its choice is fundamentally dependent on knowledge of spectrum of probable pathogens, especially without microbiological verification.

This study was supported by the grant No. 23-75-30012 from the Russian Science Foundation, https://rscf.ru/project/23-75-30012/

Author contribution:
Concept and design of the study — Baranich A.I., Sychev A.A.
Collection and analysis of data — Baranich A.I., Kurdyumova N.V., Sukhorukova M.V., Veliev Z.Sh., Korotkov D.S., Kakurin K.O.
Statistical analysis — Baranich A.I.
Writing the text — Baranich A.I.
Editing — Sychev A.A., Savin I.A., Kurdyumova N.V., Sukhorukova M.V., Kudrina V.G.

The authors declare no conflicts of interest.

REFERENCES

1. Bodilsen J, D'Alessandris QG, Humphreys H, Iro MA, Klein M, Last K, Montesinos IL, Pagliano P, Sipahi OR, San-Juan R, Tattevin P, Thurnher M, de J Treviño-Rangel R, Brouwer MC; ESCMID Study Group for Infections of the Brain (ESGIB). European society of Clinical Microbiology and Infectious Diseases guidelines on diagnosis and treatment of brain abscess in children and adults. *Clinical Microbiology and Infection.* 2024;30(1):66-89. https://doi.org/10.1016/j.cmi.2023.08.016
2. Bodilsen J, Eriksen EM, Nielsen MD, Duerlund LS, Mariager T, Nielsen H, Brouwer MC. Clinical features and outcome of brain abscess after introduction of CT and MRI: A meta-analysis. *Journal of Infection.* 2025;90(2):106394. https://doi.org/10.1016/j.jinf.2024.106394
3. Bilgin E, Arslan Gulen T, Kızılpınar G, Işıkber GG, Sezer C, Tas ZA, Oruc E. The characteristics of the cases with brain abscess and the analysis of the predictive factors for poor outcome. *The Journal of Infection in Developing Countries.* 2025;19(8):1182-1188. https://doi.org/10.3855/jidc.20676
4. Baranich AI, Sychev AA, Savin IA, Kudrina VG. Drug interactions in neurosurgical patients. *Burdenko's Journal of Neurosurgery.* 2023;87(6):100-105. (In Russ.). https://doi.org/10.17116/neiro202387061100
5. Dzhindzhikhadze RS, Dreval ON, Lazarev VA, Polyakov AV, Kambiev RL, Fedorov DN, Banina VB, Barbashova AS. Successful microsurgical resection of a large brainstem abscess: case report and literature review. *Burdenko's Journal of Neurosurgery.* 2022;86(3):56-62. (In Russ.). https://doi.org/10.17116/neiro20228603156
6. Ortenberg EA, Veshkurtzeva IM. Intracranial abscesses: some clinical pharmacology issues of a multidisciplinary approach. *Clinical Microbiology and Antimicrobial Chemotherapy.* 2025;27(1):27-32. (In Russ.). https://doi.org/10.36488/cmac.2025.1.27-32
7. Brouwer MC, Coutinho JM, van de Beek D. Clinical characteristics and outcome of brain abscess: systematic review and meta-analysis. *Neurology.* 2014;82(9):806-813. https://doi.org/10.1212/WNL.0000000000000172
8. Cai Y, Liu J, Jia G, Hou Y, Wang Y. Clinical characteristics, complications, and outcome of brain abscess treated by stereotactic aspiration: a retrospective analysis. *BMC Infectious Diseases.* 2025;25(1):373. https://doi.org/10.1186/s12879-025-10770-4
9. Lange N, Berndt M, Jörger AK, Wagner A, Lummel N, Ryang YM, Wantia N, Meyer B, Gempt J. Clinical Characteristics and Course of Postoperative Brain Abscess. *World Neurosurgery.* 2018;120:e675-e683. https://doi.org/10.1016/j.wneu.2018.08.143
10. Anwar S, Acharya S, Thapa K, Adhikari N, Mobarakai N. Brain Abscesses by Nocardia: An Interesting Case. *Cureus.* 2023;15(5):e38911. https://doi.org/10.7759/cureus.38911
11. Vega Brizneda M, Miranda C, Cober E, Misra A, Harrington S, Yetmar ZA. Risk Factors and Outcomes of Disseminated Nocardiosis Across Host Risk Groups. *Open Forum Infectious Diseases.* 2026;13(1):ofag008. https://10.1093/ofid/ofag008
12. Qin L, Wang S, Zheng Z, Zhang W, Qu Q, Li J, Tan Y, Cao L. A complicated infection by cutaneous *Nocardia wallacei* and pulmonary *Mycobacterium abscessus* in a Chinese immunocompetent patient: a case report. *Frontiers in Cellular and Infection Microbiology.* 2023;13:1229298. https://doi.org/10.3389/fcimb.2023.1229298
13. Ziogou A, Giannakodimos A, Giannakodimos I, Baliou S, Tsantes AG, Ioannou P. *Nocardia* Osteomyelitis in Humans-A Narrative Review of Reported Cases, Microbiology, and Management. *Pathogens.* 2025;14(10):1032. https://doi.org/10.3390/pathogens14101032
14. Bristowe H, Dissanayake K, Chandra J, Arias M. Listeria brain abscess: a therapeutically challenging rare presentation of listeriosis. *BMC Infectious Diseases.* 2024;24(1):477. https://doi.org/10.1186/s12879-024-09295-z

Received 04.02.2025
Accepted 12.03.2026

COMMENT

The authors present a relevant clinical and epidemiological study devoted to etiological structure and microbiological spectrum of brain abscesses in a large neurosurgical hospital.

The relevance of this issue is beyond doubt. Brain abscesses are life-threatening diseases, and effectiveness of empirical antimicrobial therapy depends on current local

data on causative agents. The authors rightly note the lack of modern national researches on this issue.

The main result of this study is identification of a shift in etiologic structure of brain abscesses compared to historical data (in particular, meta-analysis by M.C. Brouwer et al.). In study population, postoperative complications (39%) with predominance of Staphylococcus spp. (26.8%) prevail instead of otogenic/odontogenic abscesses. This is an important finding reflecting the realities of modern neurosurgery (increasing number of procedures and changing patient profiles). Data on rare but clinically significant pathogens (Aspergillus, Nocardia, Listeria) are also interesting for physicians.

This is a single-center retrospective study (2022–2025, *n*=41). Clear inclusion and exclusion criteria ensured homogeneous sample (primary brain abscesses only). A positive aspect is system for monitoring infectious complications based on antibiotic prescriptions that minimizes loss of cases.

The article is written in good scientific language. References include relevant international and national studies (including those dated 2024—2026).

This article provides valuable local epidemiological data important for optimizing baseline antimicrobial therapy in a neurosurgical hospital. The authors' conclusions regarding the need for regular updating local protocols and careful collecting anamnesis are justified. Despite certain limitations (retrospective design, small sample size, no PCR verification), the article deserves publication, as it draws attention to changing structure of this pathology (increased proportion of postoperative staphylococcal abscesses) and can underlie further multiple-center studies.

Dzhindzhikhadze R.S. (Moscow)