Burdenko's Journal of Neurosurgery
2026, No. 2, pp. 112–117
https://doi.org/10.17116/neiro202690021112

Surgical treatment of hemifacial spasm: a systematic review

© V.N. Shimansky[1], L.A. Sidneva[1], S.V. Tanyashin[1], A.A. Ogurtsova[1], V.K. Poshataev[1], M.V. Kolycheva[2], I.O. Kugushev[1], R.A. Sadykov[1], V.A. Gorbulev[1]

[1]Burdenko Neurosurgical Center, Moscow, Russia;
[2]Pirogov Russian National Research Medical University, Moscow, Russia

ABSTRACT
The annual incidence of hemifacial spasm is 8—15 cases per 100.000. This disease is not life-threatening, but it significantly impacts the quality of life. Primary treatment is vascular decompression of the facial nerve. Thus, improvement of appropriate technique is crucial for higher efficacy and safety.
Objective. To determine the optimal algorithm for vascular decompression according to available international experience in surgical treatment of hemifacial spasm.
Material and methods. A systematic review was conducted in accordance with the PRISMA guidelines. To identify relevant publications, we screened the PubMed, Google Scholar, and eLibrary databases through October 2024 using the keywords «microvascular decompression» and «hemifacial spasm». Only full-text articles in Russian, English, or French were included in the study.
Results. Among 364 manuscripts, 24 met the inclusion criteria. The majority of studies demonstrated available experience and effectiveness of vascular decompression without description of surgical approach.
Conclusion. Considering global experience, we proposed an optimal surgical algorithm, including initial dissection of bulbar nerves and facial nerve decompression, if possible, along its entire length.

Keywords: *hemifacial spasm, vascular decompression, neurovascular conflict, facial nerve.*

INFORMATION ABOUT THE AUTHORS:
Shimansky V.N. — https://orcid.org/0000-0002-3816-847X
Sidneva L.A. — https://orcid.org/0000-0002-9809-525X
Tanyashin S.V. — https://orcid.org/0000-0001-8351-5074
Ogurtsova A.A. — https://orcid.org/0000-0003-3595-2696
Poshataev V.K. — https://orcid.org/0000-0002-3279-3733
Kolycheva M.V. — https://orcid.org/0000-0002-7741-6616
Kugushev I.O. — https://orcid.org/0000-0001-8542-0060
Sadykov R.A. — https://orcid.org/0009-0006-0420-9399
Gorbulev V.A. — https://orcid.org/0009-0004-6928-8468
Corresponding author: Sidneva L.A. — e-mail: sidnevala@nsi.ru

TO CITE THIS ARTICLE:
Shimansky VN, Sidneva LA, Tanyashin SV, Ogurtsova AA, Poshataev VK, Kolycheva MV, Kugushev IO, Sadykov RA, Gorbulev VA. Surgical treatment of hemifacial spasm: a systematic review. *Burdenko's Journal of Neurosurgery*. 2026;90(2):112—117. https://doi.org/10.17116/neiro202690021112

Introduction

Hemifacial spasm (HFS) is characterized by periodic, painless, involuntary, tonic or clonic unilateral contractions of facial muscles [1]. Annual incidence is 8—15 cases per 100.000 with predominance in middle-aged and older women [2].

HFS is classified as primary or secondary depending on etiology. The main cause of primary HFS is vascular compression of the facial nerve at the root exit zone (REZ) by anterior inferior cerebellar artery, posterior inferior cerebellar artery, vertebral artery, their combinations, other arteries in posterior cranial fossa and veins [3—5]. Secondary HFS follows facial nerve damage by intracranial tumors, demyelinating diseases, trauma, infections, and vascular anomalies [3, 6—9].

HFS is a clinical diagnosis. To exclude secondary causes of disease and determine facial nerve topography, type and location of vessel, standard MRI of the head, FIESTA and 3D TOF MRA are performed [10].

Development of surgical treatment for HFS began in the mid-20th century with studies by E. Cambell and C. Keedy. In the 1960s and 1970s, P.J. Jannetta demonstrated the role of neurovascular conflict in pathogenesis of HFS and developed microvascular decompression. This procedure was first used on July 2, 1966 [11]. Since then, this technique has been continuously improved, including intraoperative neurophysiological monitoring (IONM) and endoscopic techniques [12—16].

Surgery is the only pathogenetic treatment for HFS, and effectiveness varies from 80% to 97% among different authors. Thus, analysis of vascular decompression stages is particularly important [17].

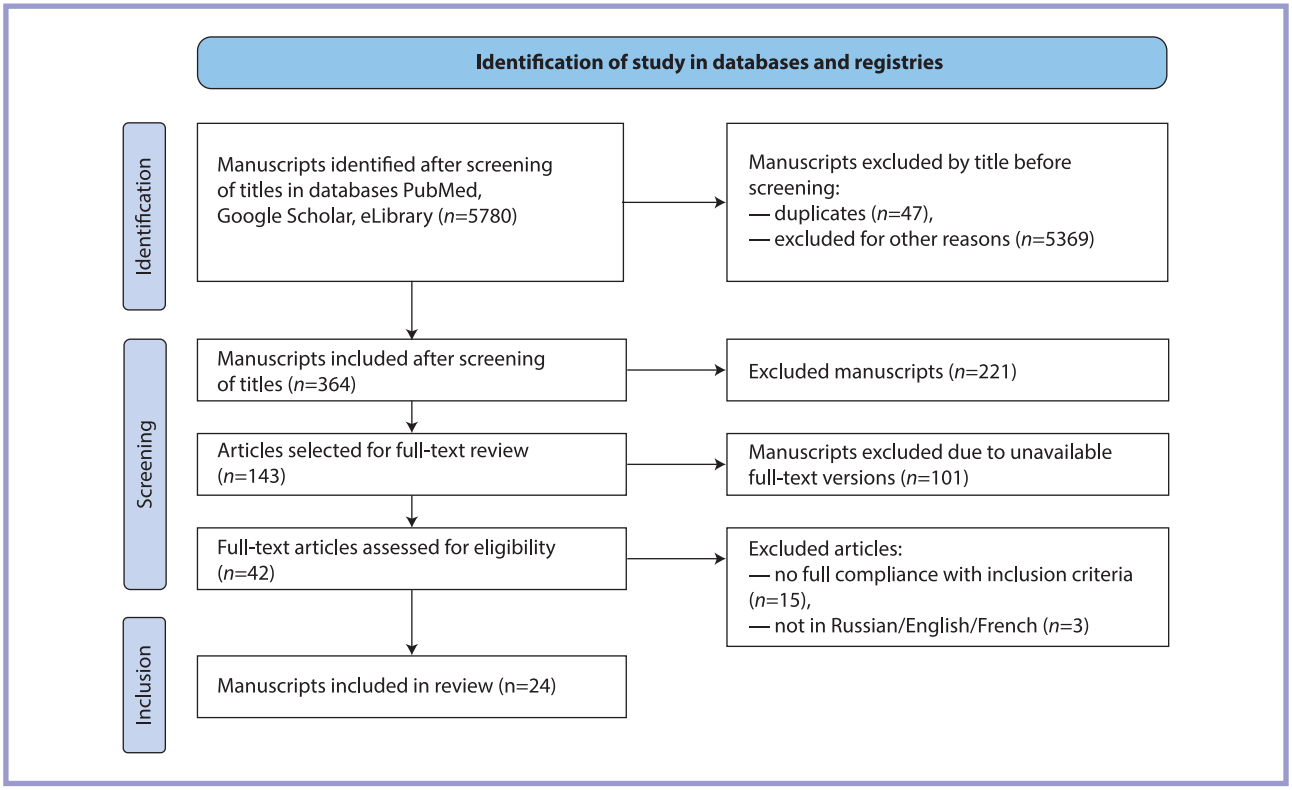

Fig. 1. **Study flowchart.**

Material and methods

Searching strategy

Searching was performed until October 2024 in PubMed, Google Scholar, and eLibrary databases in accordance with PRISMA guidelines. We used the keywords «microvascular decompression» and «hemifacial spasm». This resulted in 5.780 references. Of these, 411 ones were relevant. After excluding duplicates (*n*=47), 364 articles were included. All articles were individually reviewed, and 143 were selected for full-text analysis. We excluded 221 ineligible articles after analysis of abstracts (primary HFS, primary vascular decompression, not case report). Then, we excluded 101 articles with unavailable full text. Among residual 42 articles, 15 and 3 ones were excluded due to incomplete compliance with inclusion criteria and inappropriate language, respectively. Twenty-four studies were included in final analysis **(Fig. 1)**.

Results

Pathogenesis of disease and anatomical features of facial nerve

The two most common theories of HAS pathogenesis are peripheral and central ones [18]. Peripheral hypothesis postulates facial nerve compression at the REZ as the cause of disease [11, 19, 20]. According to central theory, HFS is associated with increased excitability of the motor nucleus of the facial nerve due to its deafferentation following facial nerve damage at the root entry zone. This leads to disinhibition and reorganization of the nucleus and increased impulse generation [21]. Both theories are not mutually exclusive. Perhaps, both mechanisms are links in a single pathogenetic chain (the «combined» hypothesis) [22].

Compression can occur at any site within REZ of the facial nerve (defined as the entire length of centrally myelinated fibers of facial nerve). Nerve fibers emerge from pontomedullary groove (root exit point) and remain attached to pontine surface for approximately 8 mm (attached segment) until they detach from the brainstem (root detachment point, RDP). Then, there is a transition zone 2 mm distally (TZ or Obersteiner-Redlich zone) followed by cisternal portion (CP) passing through subarachnoid space [20]. According to literature data, facial nerve compression within RDP/TZ occurs in 23% of cases, within attached segment - in 64%, within root exit point – in 10% of cases. However, there are cases without compression in REZ that necessitates distal revision of the root [23].

Surgical treatment

For vascular decompression, primary approach is retrosigmoid suboccipital one in semi-sitting, park bench or prone (preferably) position with head rotation. Crani-

Table. **Features and results of surgical treatment over the last 10 years.**

N	Author	Number of patients, *n*	Surgical approach (nuances)	Efficacy, %	Recurrence rate, %	Complication rate, %	Conclusion
1	J.Y. Kim et al., 2019 [35]	112 (16)	Lateral decubitus position, retrosigmoid approach, proximal Teflon transposition with interposition	93.5	—	25	Proximal Teflon transposition with interposition has advantages over traditional technique of vascular decompression for HFS caused by vertebral artery
2	K. Amagasaki et al., 2019 [27]	396 (22)	Retrosigmoid approach, vessel transposition by fixation to petrous part of temporal bone	90.9	4.5	27.2	Artery transposition using sling technique achieves effective detachment of the vessel from the facial nerve
3	S. Pusat et al., 2024 [29]	60	Lateral decubitus or supine position with head rotation, retrosigmoid approach, infrafloccular approach, dissection of bulbar nerves, examination of pontomedullary groove, placement of Teflon protector with fixation by fibrin glue	90	1.7	11.7	There is no need for retractor or IONM after sufficient arachnoid dissection of caudal nerves. Fibrin glue is used to ensure better fixation of protector. Decompression of facial nerve root is performed along its entire length with care for perforator vessels
4	Z. Li et al., 2018 [36]	320	Lateral decubitus position, retrosigmoid approach, nerve decompression within REZ	90.9	0	6.2	REZ decompression and IONM are necessary, since this area is less resistant to vascular pulsation
5	T. Inoue et al., 2021 [37]	60 (30)	Lateral decubitus position, retrosigmoid approach, bridge technique of protector placement between the lower part of the pons and nerve root to create free space above REZ in case of compression by vertebral artery	100	3.3	13.3	Bridge technique for facial nerve decompression in case of compression by vertebral artery requires less time, Teflon protectors and manipulations near bulbar nerves compared to sling technique
6	X. Jiang et al., 2018 [38]	117	Retrosigmoid approach, transposition with Teflon bandage and biomedical glue for compression by vertebral artery	95	0	7	Vessel transposition with Teflon bandage and biomedical glue was used depending on type of facial nerve compression by vertebral artery
7	F. Li et al., 2020 [39]	540	Lateral decubitus position, retrosigmoid approach, facial nerve decompression along its entire length, protector placement using interposition method	95	0	9	Decompression of the entire facial nerve root using interposition is a highly effective technique. No recurrence can be explained by short postoperative follow-up period
8	M.Y. Lv et al., 2017 [40]	189	Retrosigmoid approach, decompression of facial nerve root near the brainstem via protector placement	91	0	34.9	Facial nerve root exit zone is the main site of compression; therefore, targeted decompression of this area is the main stage of surgery.
9	K. Amagasaki et al., 2019 [41]	101	Retrosigmoid approach; the need for mobilization of PICA or AICA along the approach to REZ was studied	92	1	6	Mobilization of AICA and PICA following access to facial nerve root exit zone ensures optimal space and does not lead to hearing loss
10	Y. Nonaka et al., 2019 [30]	18	Retrosigmoid approach, transposition with wedge-shaped protector. Protector is covered with fibrin glue in case of hypertrophied vertebral artery	100	5.5	0	Wedge-shaped protector must be placed without contact with REZ to eliminate subsequent transmission of pulsation from displaced vessel to the root
11	J.S. Park et al., 2023 [31]	31	Retrosigmoid approach, thorough examination of REZ and prevention of iatrogenic compression of this area by large protector	93	3	6	When decompressing the facial nerve root, type of compression is taken into account to determine further strategy and prevent iatrogenic nerve compression
12	A. Alkhayri et al., 2023 [42]	200	Park bench position, retrosigmoid approach, REZ dissection followed by nerve revision and protector placement	92.5	7.5	26.5	Facial nerve compression by AICA is followed by worse results that may be due to difficult detachment of this artery from acoustic-facial group of nerves

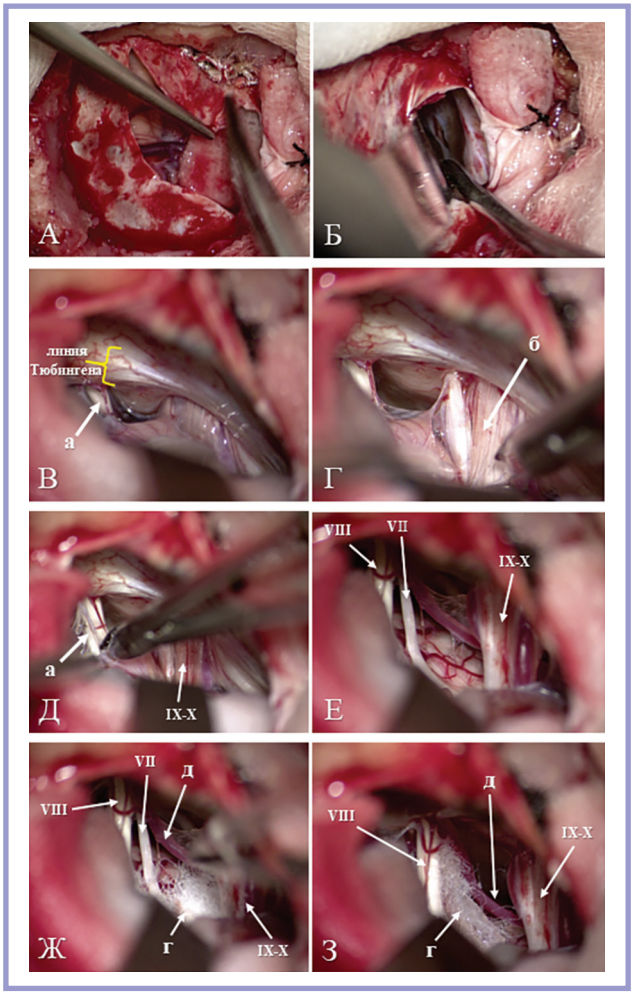

Fig. 2. **Stages of facial nerve decompression.**
A — dissection of dura mater; B — basal cistern drainage; C — visualization of the Tübingen line as a landmark for exit zone of acoustic-facial nerves (a); D — arachnoid dissection of bulbar nerves (b); E — arachnoid dissection of acoustic-facial nerves (a); F — visualization of cisternal and stem parts of the facial nerve root; G — placement of fluoroplastic felt protector (d) between stem part of the facial nerve root and anterior inferior cerebellar artery (e); H — placement of protector (d) between cisternal part of the facial nerve root (hidden by protector) and anterior inferior cerebellar artery (e).

otomy size is 2×2 cm. The main surgical stages include dissection of dura mater, drainage of posterior cranial fossa cisterns, arachnoid dissection of neurovascular structures, protector placement, suturing of dura mater and soft tissues [24].

Appropriate vessel is intraoperatively isolated from facial nerve by transposition or interposition with placement of artificial protectors or autologous tissue [25, 26].

There are various transposition methods including fixation to dura mater [27], fenestrated clips for aneurysm [28], surgical glue [29—32] and vessel suturing [27]. Protector from autologous or synthetic materials is the most common technique [33]. Hemostatic materials are used as an adhesive material for vessel fixation [34]. These techniques are not without drawbacks due to technical complexity and the risk of inflammatory reactions when adhesive compositions come into contact with nerves and brainstem. However, they are highly effective [29].

While indicating the effectiveness of vascular decompression in a large sample, most studies lack a full description of surgical technique. Detailed descriptions of techniques are often presented in a single variant of vascular compression, for example, regarding vertebral artery. The studies over the last 10 years included in the study are summarized in **Table.**

Discussion

Most authors note the need for facial nerve decompression along its entire length and importance of protector placement near the brainstem [29, 36, 39]. Lv M.Y. et al. emphasize that cisternal portion should not be neglected [40].

Facial root decompression near brainstem alone or complex transposition technique was characterized by high complication rate (over 20%) compared to other data [27, 40].

Complex anatomical arrangement of neurovascular structures relative to auditory nerve makes decompression of the entire length impossible without the risk of hearing loss or facial paresis. Amagasaki K. et al. [41] studied the effect of mobilization of anterior inferior cerebellar artery or posterior inferior cerebellar artery on hearing function in postoperative period. However, segment of vessels was localized near stem part of the nerve root rather cisternal one, where the main branches supplying VIII nerve were located. This explained low percentage of complications. Alkhayri A. et al. [42] attribute worse results of vascular decompression to the need to mobilize anterior inferior cerebellar artery during revision of facial nerve root along its entire length due to close relationship of arterial branches with VII and VIII nerves.

Many researchers draw attention to possible «iatrogenic» HFS due to placement of large amount of protector and prefer transposition techniques. This excludes contact of material with REZ [30, 31].

Our own experience has been accumulated since July 7, 1987, when facial nerve root decompression was first performed. We formulated an optimal algorithm for this procedure incorporating the results of IONM-guided surgeries (since 2017) [unpublished data] **(Fig. 2)**:

1) retrosigmoid approach no larger than 2×2 cm with lower border at the level of transition of vertical part of occipital bone to horizontal one and mandatory visualization of sigmoid sinus;
2) visualization of the Tübingen line (dura mater fold as a projection of lower border of internal auditory canal) to verify the exit site of acoustic-facial nerves;
3) baseline dissection of bulbar nerves to create a working space, free traction of cerebellar hemisphere and visualization of facial nerve exit zone;

4) facial nerve root decompression, if possible, along its entire length;
5) decompression of the stem part of the nerve root in case of anatomically complex interposition of neurovascular structures. With positive IONM values, decompression of only this zone may be sufficient in such a situation.

Conclusion

Vascular decompression is primary etiopathogenetic treatment. There are few publications fully describing surgical procedure in specific situations. Considering international and own experience, we presented an optimal surgical algorithm for hemifacial spasm.

Author contribution:
Concept and design of the study — Shimansky V.N., Tanyashin S.V., Poshataev V.K.
Collection and analysis of data — Sadykov R.A., Tanyashin S.V., Poshataev V.K.
Statistical analysis — Sadykov R.A., Gorbulev V.A.
Writing the text — Sidneva L.A., Kugushev I.O.
Editing — Shimansky V.N., Poshataev V.K., Kolycheva M.V., Ogurtsova A.A.

The authors declare no conflicts of interests.

REFERENCES

1. Kemp LW, Reich SG. Hemifacial spasm. *Current Treatment Options in Neurology.* 2024;6(3):175-179. https://doi.org/10.1007/s11940-004-0009-4
2. Shamalov NA, Zavaliy LB, Petrikov SS, Ramazanov GR, Tyrov IA, Koriagin AN, Fomkin AG, Kuular DV, Nikulina TA, Andriyanova EV. Epidemiologic characteristics of facial nerve diseases in a metropolis according to the unified medical city systems. *Medicine and Health Care Organization.* 2024;9(2):60-69. https://doi.org/10.56871/MHCO.2024.64.49.007
3. Salari M, Alikhani A, Vakoli K, Fathi M, Etemadifar M. Primary hemifacial spasm: anatomical insights. *Acta Neurologica Belgica.* 2025;125(1):35-41. https://doi.org/10.1007/s13760-024-02660-4
4. Ahmed A, Alsulaiman N, Diab MM, Alsuhaibani AH. Periocular clinical differences between primary and postparalytic hemifacial spasm: A retrospective comparative study. *Indian Journal of Ophthalmology.* 2025;73(10):1438-1442. https://doi.org/10.4103/IJO.IJO_806_25
5. Ghaffari-Rafi A, Choi SY, Leon-Rojas J, Shahlaie K. Predictors of Multi-Vessel Identification, Outcome, and Optimal Surgical Timing for Microvascular Decompression in Hemifacial Spasm. *Clinical Neurology and Neurosurgery.* 2023;233:107841. https://doi.org/10.1016/j.clineuro.2023.107841
6. Chen YY, Chuang MT, Tai SH, Lee EJ. Choroid plexus papilloma at the root entry zone causing hemifacial spasm. *The Kaohsiung Journal of Medical Sciences.* 2023;39(11):1157-1158. https://doi.org/10.1002/kjm2.12747
7. Ogul H, Unlu EN, Guclu D, Koksal A. Cerebellar Developmental Venous Anomaly Causing Tinnitus and Hemifacial Spasm: A Case Report. *Ear, Nose, & Throat Journal.* 2025;104(9):553-555. https://doi.org/10.1177/01455613221133226
8. Graboyes AZ, Quimby AE, Heman-Ackah S, Stone SL, Brant JA, Bigelow DC, Lee JYK. Radiation-induced cavernous malformation within a vestibular schwannoma: A case report. *SAGE Open Medical Case Report.* 2025;13: 2050313X251390626. https://doi.org/10.1177/2050313X251390626
9. Hashiguchi A, Takemoto Y, Ueda R, Moroki K, Tokuda H. Spontaneous Resolution of Hemifacial Spasm Following Falcotentorial Meningioma Resection: Impact of Posterior Cranial Fossa Volume Changes on Hemifacial Spasm. *Cureus.* 2025;17(6):e85450. https://doi.org/10.7759/cureus.85450
10. Bonomo R, Bonomo G, Iess G, Schiariti MP, Falco J, Stanziano M, Restelli F, Mazzapicchi, Broggi M, Labiad I, Acerbi F, Barbagallo GMV, Ferroli P. Evaluating the diagnostic role of magnetic resonance imaging in trigeminal neuralgia, hemifacial spasm, and glossopharyngeal neuralgia: A controlled blinded study. *Brain & Spine.* 2025;5:105607. https://doi.org/10.1016/j.bas.2025.105607
11. Jannetta PJ. Microsurgical exploration and decompression of the facial nerve in hemifacial spasm. *Current Topics in Surgical Research.* 1970;2:217-222.
12. Zachem TJ, Bello A, Lee B, Luo E, Woo J, Yoo S, Duerr E, Massat E, Hunter A, Yamamoto K, Adil SM, Kaplan S, Hachem RA, Husain AM, Codd PJ, Zomorodi A, Goodwin CR, Abdelgadir J. Current state of intraoperative neuromonitoring of the facial nerve during skull base surgery: A systematic review. *Journal of Clinical Neuroscience.* 2025;140:111525. https://doi.org/10.1016/j.jocn.2025.111525
13. Pan SY, Lai CM, Huang CW, Chen YC, Yang LY, Guo L. Is complete elimination of lateral spreading response essential in microvascular decompression for hemifacial spasm? *Neurosurgical Focus.* 2025;59(3):E5. https://doi.org/10.3171/2025.6.FOCUS25436
14. Yang J, Yang X, Liu H, Liu J, Li K, Shi J, Liang Y, Song Y, Fan X, Qiao H. The application value of intraoperative lateral spreading response monitoring during microvascular decompression in patients with primary hemifacial spasm. *European Journal of Medical Research.* 2025;30(1):1095. https://doi.org/10.1186/s40001-025-03293-w
15. Ansari A, Tavanaei R, Alikhani A, Hajikarimloo B, Zoghi S, Alnemari AM, Khorasanizadeh M, Zwagerman NT. Fully endoscopic microvascular decompression for hemifacial spasm: a systematic review. *Neurosurgical Review.* 2025;48(1):285. https://doi.org/10.1007/s10143-025-03181-1
16. Wang Q, Hao X, Liu Q, Chen J, Jiang R, Xu X, Shi W. Fully Endoscopic Microvascular Decompression for Hemifacial Spasm Using 2-Dimensional/3-Dimensional Endoscopy: Clinical Analysis of 204 Cases. *Operative Neurosurgery.* 2025. https://doi.org/10.1227/ons.0000000000001758
17. Ghaffari-Rafi A, Choi SY, Leon-Rojas J, Shahlaie K. Predictors of Multi-Vessel Identification, Outcome, and Optimal Surgical Timing for Microvascular Decompression in Hemifacial Spasm. *Clinical Neurology and Neurosurgery.* 2023;233:107841. https://doi.org/10.1016/j.clineuro.2023.107841
18. Jesuthasan A, Natalwala A, Davagnanam I, Saifee T, Zrinzo L. Hemifacial spasm: an update on pathophysiology, investigations and management. *Journal of Neurology.* 2025;272(8):502. https://doi.org/10.1007/s00415-025-13220-y
19. De Melo DLM, Bento Oliveira DRDCA, Pinheiro DS, Manzano GM. Ephatic transmission impairs trigemino-cervical reflex monitoring during microvascular decompression surgery for hemifacial spasm. *Clinical Neurophysiology.* 2025;174:59-60. https://doi.org/10.1016/j.clinph.2025.03.039
20. Nielsen VK. Electrophysiology of the facial nerve in hemifacial spasm: ectopic/ephaptic excitation. *Muscle Nerve.* 1985;8(7):545-555. https://doi.org/10.1002/mus.880080702
21. Duan Y, Lv K, Zhao C, Han L, Wang J, Zhang C, Zhang Z, Liu H, Yang K, Yuan Z, Zhu L, Wang Y, Luan J, Ma G, Liu J. Exploring Facial Nucleus-Centered Connectivity in Hemifacial Spasm: Novel Insights into Pathogenesis and Surgical Impact. *Brain Topography.* 2025;38(5):58. https://doi.org/10.1007/s10548-025-01133-y
22. Amano Y, Asayama B, Noro S, Abe T, Okuma M, Honjo K, Seo Y, Nakamura H. Correlation between Delayed Relief after Microvascular Decompression and Morphology of the Lateral Spread Response in Patients with Hemifacial Spasm-Temporal versus Mandibular Branch Stimulation. *Neurologia Medico-chirurgica.* 2024;65(2):45-51. https://doi.org/10.2176/jns-nmc.2024-0062
23. Campos-Benitez M, Kaufmann AM. Neurovascular compression findings in hemifacial spasm. *Journal of Neurosurgery.* 2008;109(3):416-420. https://doi.org/10.3171/JNS/2008/109/9/0416

24. Goto Y, Inoue T. A bony landmark in craniotomy for hemifacial spasm: The inferior retrosigmoid eminence. *Neurosurgical Review.* 2025;48(1):700. https://doi.org/10.1007/s10143-025-03865-8
25. Grigoryan GYu, Dzhindzhikhadze RS, Shumovsky VK, Grigoryan YuA. Interposition and transposition techniques of vascular decompression for hemifacial spasm. *Burdenko's Journal of Neurosurgery.* 2023;87(2):30-40. https://doi.org/10.17116/neiro20238702130
26. Draghi R, Tengattini F, Travaglini F, Salomi F, Sangiorgi D, Borghesi I, Calbucci F. Muscle pad interposition technique in microvascular decompression for primary hemifacial spasm: a single-center case series and systematic review. *Neurosurgical Focus.* 2025;59(3):E7. https://doi.org/10.3171/2025.6.FOCUS25432
27. Amagasaki K, Watanabe S, Naemura K, Shono N, Hosono A, Nakaguchi H. Transposition of the Culpit Artery Passing Between the Facial Nerve and Auditory Nerve in Microvascular Decompression Surgery for Hemifacial Spasm. *World Neurosurgery.* 2019;127:e996-e1002. https://doi.org/10.1016/j.wneu.2019.04.020
28. Corvino S, Seneca V, Iaconetta G, Catapano G. How I do it: sling transposition technique with biopatch and aneurysm clip for hemifacial spasm. *Acta Neurochirurgica.* 2025;167(1):260. https://doi.org/10.1007/s00701-025-06634-0
29. Pusat S, Erdogan E, Atar M, Erbas YC, Erdogan E. Microvascular Decompression for Hemifacial Spasm without the Use of Neuromonitoring and Fix Retraction: A Single-Center Experience. *Turkish Neurosurgery.* 2024;34(3):429-434. https://doi.org/10.5137/1019-5149.JTN.42249-22.3
30. Nonaka Y, Hayashi N, Matsumae M, Fukushima T. Wedge-technique for transposition of the vertebral artery in microvascular decompression for hemifacial spasm: technical nuances and surgical outcomes. *Acta Neurochirurgica.* 2019;161:1435-1442. https://doi.org/10.1007/s00701-018-03793-1
31. Park JS, Park K. Operative Findings of over 5000 Microvascular Decompression Surgeries for Hemifacial Spasm: Our Perspective and Current Updates. *Life.* 2023;13(9):1904. https://doi.org/10.3390/life13091904
32. Zheng WJ, He R, Zhang X, Chen F, Chen L, Liu Y, Yang J, Deng Z, Jiang T, Huang G. Glue-transposition technique for hemifacial spasm involving vertebrobasilar dolichoectasia: a comparative study and literature review. *Neurosurgical Review.* 2025;48(1):495. https://doi.org/10.1007/s10143-025-03612-z
33. Khan NR, Wu EM, Elarjani T, Morcos JJ. Macrovascular Decompression for Hemifacial Spasm Using Sling Technique. *World Neurosurgery.* 2023;170:67. https://doi.org/10.1016/j.wneu.2022.11.073
34. Mori K, Otani N, Toyooka T, Morita S, Numazawa S, Wada K, Watanabe S. Validation of Efficacy and Safety of TachoSil® Tissue Sealant for Vessel Transposition in Microvascular Decompression. *Operative Neurosurgery.* 2023;25(5):417-425. https://doi.org/10.1227/ons.0000000000000844
35. Kim JY, Jung S, Song TW, Kim IY, Moon KS, Jung TY, Jang WY. The Cornerstone Technique of Microvascular Decompression for Hemifacial Spasm with Vertebral Artery Offender. *World Neurosurgery.* 2019;126:e94-e100. https://doi.org/10.1016/j.wneu.2019.01.199
36. Li Z, Gao J, Wang T, Li Y. Retrospective clinical analysis of 320 cases of microvascular decompression for hemifacial spasm. *Medicine.* 2018;97(41):e11825. https://doi.org/10.1097/MD.0000000000011825
37. Inoue T, Shitara S, Goto Y, Arham A, Prasetya M, Radcliffe L, Fukushima T. Bridge technique for hemifacial spasm with vertebral artery involvement. *Acta Neurochirurgica.* 2021;163(12):3311-3320. https://doi.org/10.1007/s00701-021-05006-8
38. Jiang X, Wu M, Fu X, Niu C, He F, Sun K, Zhuang H. Microvascular Decompression for Hemifacial Spasm Associated with Vertebral Artery: Biomedical Glue-Coated Teflon Sling Transposition Technique. *World Neurosurgery.* 2018;120:e342-e348. https://doi.org/10.1016/j.wneu.2018.08.073
39. Li F, Liu R. Clinical analysis of microvascular decompression in patients with hemifacial spasm: a retrospective study. *Annals of Palliative Medicine.* 2020;9(2):318-323. https://doi.org/10.21037/apm.2020.01.11
40. Lv MY, Deng SL, Long XF, Liu ZL. Long-term outcome of microvascular decompression for hemifacial spasm. *British Journal of Neurosurgery.* 2017;31(3):322-326. https://doi.org/10.1080/02688697.2017.1297368
41. Amagasaki K, Watanabe S, Hosono A, Nakaguchi H. Mobilization of the Anterior/Posterior Inferior Cerebellar Artery on the Cerebellar Surface in Microvascular Decompression Surgery for Hemifacial Spasm: Potential Effect on Hearing Preservation. *Operative Neurosurgery.* 2019;16(2):179-185. https://doi.org/10.1093/ons/opy128
42. Alkhayri A, Bourdillon P, Chauvet D, Bugdadi A, Alyousef M, Alsalmi S, Apra C, Lefaucheur JP, Aldea S, Le Guérinel C. Surgical treatment of hemifacial spasms: how to predict failure and complications through a series of 200 patients. *Neurochirurgie.* 2023;69(6):101498. https://doi.org/10.1016/j.neuchi.2023.101498

Received 08.12.2025
Accepted 30.01.2026