Burdenko's Journal of Neurosurgery
2026, No. 2, pp. 103–109
https://doi.org/10.17116/neiro202690021103

Approaches in microsurgery for olfactory meningiomas: a systematic review and meta-analysis

© A.N. Abdullaev[1], R.S. Dzhindzhikhadze[1, 2], A.V. Polyakov[1], V.S. Gadzhiagaev[1], A.D. Zaitsev[1], E.I. Salyamova[1]

[1]Vladimirsky Moscow Regional Research Clinical Institute, Moscow, Russia;
[2]Russian Medical Academy of Continuous Professional Education, Moscow, Russia

ABSTRACT

Olfactory meningiomas are common neoplasms accounting for 4.5—18% of all intracranial meningiomas. Currently, transcranial (pterional, unilateral subfrontal, bilateral subfrontal, interhemispheric and through the frontal sinus) and endoscopic endonasal approaches are actively used.

Objective. To study the efficacy and safety of various surgical approaches to olfactory meningiomas.

Material and methods. The study included reports with data on clinical manifestations, surgical approach, extent of resection and postoperative complications in patients with olfactory meningiomas. Among 7.588 manuscripts, we enrolled 6.912 articles into screening after duplicate removal. There were 471 articles after title evaluation and 30 manuscripts after abstract review. After full-text review, 15 most relevant articles were selected for final analysis.

Results. Meta-analysis included 634 patients with olfactory meningiomas. The most common preoperative symptom was olfactory impairment (hyposmia/anosmia) (390 (62%) patients). The least common symptom was visual impairment (260 (41%) patients). Psychoemotional and/or cognitive impairment was observed in 270 (43%) patients. Bilateral subfrontal approach was the most common (226 (36%) cases), while interhemispheric access was the rarest (25 (4%) cases). Pterional approach was used in 100 (16%) cases, supraorbital approach in 95 (15%), endoscopic transnasal approach in 138 (22%) cases, and resection through the frontal sinus in 50 (8%) cases. Tumor resection Simpson I / II was achieved in 513 (81%) cases.

Conclusion. Surgery is the primary treatment for olfactory meningiomas. Optimal surgical approach should be determined after a comprehensive assessment of several factors, including tumor size and growth direction, clinical manifestations, severity of perifocal edema and individual anatomical features (particularly, dimensions of paranasal sinuses).

Keywords: *olfactory meningioma, approaches to anterior cranial fossa base, transnasal approaches to anterior cranial fossa.*

INFORMATION ABOUT THE AUTHORS:
Abdullaev A.N. — https://orcid.org/0000-0002-8297-9640
Dzhindzhikhadze R.S. — https://orcid.org/0000-0003-3283-9524
Polyakov A.V. — https://orcid.org/0000-0001-7413-1968
Gadzhiagaev V.S. — https://orcid.org/0000-0001-7661-4402
Zaitsev A.D. — https://orcid.org/0000-0002-0987-3436
Salyamova E.I. — https://orcid.org/0000-0001-6449-7114
Corresponding author: Abdullaev A.N. — e-mail: abdullaewns@gmail.com

TO CITE THIS ARTICLE:
Abdullaev AN, Dzhindzhikhadze RS, Polyakov AV, Gadzhiagaev VS, Zaitsev AD, Salyamova EI. Approaches in microsurgery for olfactory meningiomas: a systematic review and meta-analysis. *Burdenko's Journal of Neurosurgery.* 2026;90(2):103—109. (In Russ.).
https://doi.org/10.17116/neiro202690021103

Introduction

Olfactory meningiomas are among the most common and account for 4.5—18% of all intracranial meningiomas. These tumors arise from meninges near cribriform plate and often grow asymptomatically. This leads to delayed diagnosis when the tumor reaches a large size [1—5]. Olfactory meningiomas should be differentiated from other basal meningiomas of anterior cranial fossa, as there are differences in symptoms, neurological disorders, choice of approach, postoperative complications and mortality [6—8].

Clinical manifestations of olfactory meningiomas are different. The first symptom is often hyposmia with later progression to anosmia. Posterior tumor spread is fol lowed by unilateral or bilateral visual impairment. Severe perifocal cerebral edema is accompanied by cognitive and/or psychoemotional impairment. Foster-Kennedy syndrome can occur in some cases (unilateral optic disc atrophy and contralateral disc edema) [9—12].

Many approaches to olfactory meningiomas were described. Transcranial approaches have undergone evolution from extensive craniotomies to mini-approaches. With advances in microsurgical techniques and instru-

mentation, more and more studies devoted to minimally invasive craniotomies in surgery for basal tumors of anterior cranial fossa are being published [13—16]. Currently, both transcranial (pterional, unilateral subfrontal, bilateral subfrontal, interhemispheric, and through the frontal sinus) and endoscopic endonasal approaches are actively used. There is no an algorithm for selecting the optimal approach [17—19].

The purpose of this study was to evaluate efficacy and safety of various surgical approaches to olfactory meningiomas.

Material and methods

A systematic review was conducted according to the 2020 PRISMA (Preferred Reporting Items for Systematic Reviews and Meta-Analyses) guidelines. We reviewed The Cochrane Library, PubMed, and Google Scholar databases using the following keywords: meningioma, olfactory meningioma, approach to anterior cranial fossa. Inclusion criteria: English- or Russian-language articles, available full text, original study, sample >10 patients, surgical approach specified, histological diagnosis of meningioma, follow-up >3 months, preoperative and follow-up assessments of olfactory function, visual acuity, psychoemotional and/or cognitive functions, extent of resection and complications.

Primary screening of The Cochrane Library, PubMed, and Google Scholar databases revealed 7.588 manuscripts **(Figure)**. There were 6.912 articles after removing duplicates. We also excluded 6.441 and 30 articles after screening of titles and abstracts, respectively. After analysis of full-text articles, 15 manuscripts were enrolled in final analysis.

Results

This review included 15 most relevant studies devoted to microsurgical treatment of olfactory meningiomas over the past 25 years (2000—2025). The number of patients in samples ranged from 14 to 129 (mean 42.2 ones per a study). Patient data are presented in **Table 1**.

There were 634 patients with verified olfactory meningiomas. Olfactory impairment (hyposmia/anosmia) was the most common preoperative symptom (390 (62%) patients). Visual impairment was the least common symptom (260 (41%) patients). Psychoemotional and/or cognitive impairment was found in 270 (43%) patients. Subfrontal approach was the most frequent (226 cases), and interhemispheric approach was the rarest (25 cases). Pterional approach was used in 100 cases, supraorbital approach — in 95 cases, endoscopic transnasal approach — in 138 cases, access through frontal sinus — in 50 cases. Total resection (Simpson I, II) was achieved in 513 (81%) cases.

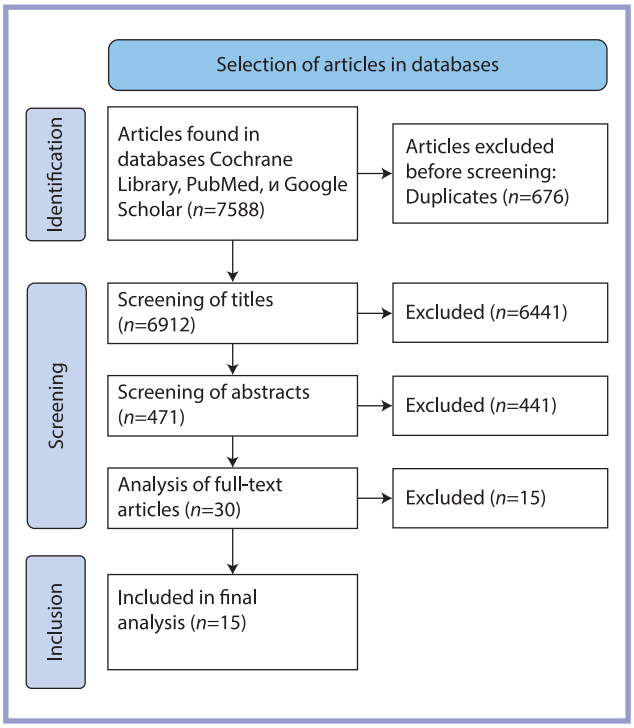

Figure. Study flowchart.

Interhemispheric approach

This access was performed in 25 cases. Preoperative visual impairment was detected in 13 (52%) patients. Of these, 6 (46%) experienced complete regression after surgery, while 7 (54%) ones had no changes. Olfactory impairment was recorded in 18 patients (72%) with persistent disorders in 7 (39%) patients. Preoperative psychoemotional and/or cognitive impairment was noted in 15 (60%) patients, with complete regression after surgery in 10 (67%) cases. Total resection was achieved in 20 (80%) cases. Complications occurred in 5 (25%) cases (cerebrospinal fluid leakage — 4 (16%), epileptic seizures — 1 (4%) case).

Pterional approach

Pterional approach was used in 100 (16%) patients with olfactory meningioma. Preoperative visual impairment was detected in 35 (35%) patients. Of these, 21 (60%) ones had complete regression, and 7 (20%) patients had no changes. Olfactory impairment occurred in 61 (61%) patients with persistent disorders in follow-up period among 72 (73%) patients. Preoperative psychoemotional and / or cognitive impairment was noted in 22 (22%) patients with complete regression after surgery in 19 (86%) cases. Total resection was achieved in 90 (90%) cases. Complications occurred in 23 (23%) cases (CSF leakage — 8 (8%), hemorrhage in surgical wound — 5 (5%), subcutaneous CSF accumulation — 3 (3%), hydrocephalus — 2 (2%), death — 2 (2%), hemiparesis, ventriculitis and pneumocephalus — 1 (1%) case).

Lateral supraorbital approach

Lateral supraorbital approach was used in 95 (15%) cases. Preoperative visual impairment was found in 37 (39%) patients. Of these, 28 (76%) ones had complete regression, and 9 (24%) patients had no changes. Olfactory impairment was diagnosed in 65 (68%) patients with persistent olfactory disorders in follow-up period among 77 (81%) patients. Preoperative psychoemotional and/or cognitive impairment was noted in 54 (57%) patients with complete regression in 50 (93%) cases. Total resection was achieved in 72 (76%) cases. Complications occurred in 16 (17%) patients (CSF leakage — 6 (6%), wound infection — 4 (4%), hydrocephalus — 3 (3%), hygroma — 2 (2%), hematoma — 1 (1%) case).

Bilateral subfrontal approach

Bilateral subfrontal approach was used in 226 cases (36%). Preoperative visual impairment was detected in 133 (59%) cases. Of these, 96 (72%) ones had complete regression, and 37 (28%) patients had no changes. Olfactory impairment was recorded in 161 (71%) patients with persistence of olfactory disorders in follow-up period among 174 (108%) patients. Preoperative psychoemotional and/or cognitive impairment was noted in 106 (47%) patients with complete regression in 89 (84%) cases. Total resection was achieved in 184 (81%) cases. Complications occurred in 36 (16%) patients (CSF leakage — 11 (5%), death — 9 (4%), hematoma — 3 (1%), cerebral edema — 3 (1%), tension pneumocephalus — 3 (1%), wound infection — 2 (1%), subdural hematoma — 2 (1%), hygroma — 1 (0.5%), meningitis — 1 (0.5%), ischemia — 1 (0.5%) case).

Resection through frontal sinus

This access was used in 50 (8%) cases. Preoperative visual impairment was detected in 3 (6%) patients. Of these, 2 ones had complete regression, and 1 patient demonstrated no changes. Olfactory impairment was recorded in 35 (70%) patients, in follow-up period — among 38 (76%) patients. Preoperative psychoemotional and/or cognitive impairment was noted in 17 (34%) patients, and complete regression occurred in 13 (76%) cases. Total resection was achieved in 50 (100%) cases. Complications arose in 11 (22%) cases (CSF leakage — 7 (14%), meningitis — 2 (4%), death — 2 (4%) cases).

Endoscopic transnasal approach

Endoscopic transnasal approach was used in 138 (22%) patients with olfactory meningioma. Preoperative visual impairment was detected in 39 (28%) patients. Of these, 19 (49%) ones had complete regression, while 20 (51%) patients had no changes. Olfactory impairment was recorded in 22 (16%) patients, and 138 (100%) patients experienced olfactory impairment in follow-up period. Preoperative psychoemotional and/or cognitive impairment was noted in 56 (41%) patients with complete regression in 53 (95%) cases. Total resection was achieved in 97 (70%) cases. Complications occurred in 48 (35%) cases (CSF leakage — 33 (24%), sinus infection — 6 (4%), meningitis — 4 (3%), abscess — 4 (3%), nosebleed — 1 (0.7%) case).

Discussion

Visual impairment regression was the rarest (46%) after interhemispheric interventions. This approach was followed by high rate of postoperative complications (25%), and CSF leakage was the most common. This suggests insufficient visual control of skull base defects and complexity of repair. These rates are likely due to small experience of authors (only 25 cases). The advantages of interhemispheric approach are technically straightforward craniotomy and short corridor towards the tumor. The disadvantages include the risk of damage to superior sagittal sinus and cortical veins with subsequent venous infarction, traumatic lateral traction of frontal lobes, narrow surgical corridor, small angle of attack in case of lateral tumor spread, difficult access to large cerebrospinal fluid cisterns and difficult brain relaxation, as well as no control of vessels and nerves in early stages of surgery [1, 20, 21].

Transcranial approaches, particularly pterional one, were followed by the highest rates of visual improvement (over 60%). The authors attribute this to visual control of optic nerves in early stages of surgery. Early drainage of prechiasmatic and carotid cisterns, as well as Sylvian fissure contributes to brain relaxation and less severe retraction-related frontal lobe trauma. The disadvantage of this approach is unavailable visual control of contralateral olfactory tract. Aggressive traction of ipsilateral frontal lobe is necessary for rostral tumor growth [22—24].

All patients developed postoperative hypo- or anosmia after transnasal endoscopic surgery, including those with normal olfaction before surgery. This is due to approach itself, as peripheral part of olfactory analyzer is damaged during this stage [25—28].

Endoscopic transnasal resection of olfactory meningioma was followed by the highest rates of regression of psychoemotional and cognitive impairment (95%). This is due to almost no frontal lobe traction. The lowest regression rates (67%) were observed after interhemispheric approach. Thus, frontal lobe traction is essential during tumor resection.

The highest postoperative complication rates (36%) were found after subfrontal and endoscopic transnasal surgeries. In case of subfrontal craniotomy, the most common complications were CSF leakage, hematoma in tu-

Table 1. **Summarized data.**

Authors, year	Number of patients, *n*	Access	Visual disorders, *n*		Olfactory impairment, *n*		Psychoemotional and/or cognitive disorders, *n*		Complications, *n*	Extent of resection (Simpson I, II), *n*
			Before	After	Before	After	Before	After		
H. Tuna et al., 2005 [1]	25	Interhemi-spheric	13	7	18	21	15	5	CSF leakage 5 Epilepsy 1	20
P.H. Aguiar et al., 2009 [2]	21	Pterional	8	2	21	21	4	0	Death 1 Hydrocephalus 2 Hemiparesis 1 Hematoma 1 Ventriculitis 1 Pneumocephalus 1 CSF leakage 4	21
R. Romani et al., 2009 [9]	66	Supraorbital	33	8	58	60	50	4	CSF leakage 6 Wound infection 4 Hydrocephalus 2 Hygroma 2 Hematoma 1	43
J.P. Pepper et al., 2011 [17]	19	Subfrontal	4	4	5	12	3	0	CSF leakage 3 Meningitis 1 Brain edema 3 Tension pneumocephalus 3 Hematoma 2 Ischemia 1	12
A.D. Bitter et al., 2013 [20]	61	Pterional	22	8	30	46	16	2	CSF accumulation 3 CSF leakage 2 Subdural hematoma 2 Death 1	55
M. Koutourousiou et al., 2014 [21]	50	Endoscopic transnasal	15	1	8	50	18	1	CSF leakage 15 Meningitis 1 Sinus infection 5 Abscess 3	45
G. Farooq et al., 2018 [22]	19	Subfrontal	15	1	11	2	13	7	Wound CSF leakage 1 Hematoma 2 Hygroma 1	19
A.V. Ciurea et al., 2017 [23]	59	Subfrontal	36	20	46	48	37	3	CSF leakage 7 Subdural hematoma 2 Wound infection 2 Death 2	52
A. Goel et al., 2018 [24]	129	Subfrontal	78	12	99	112	53	7	Death 7	101
B.E. Youngerman et al., 2020 [25]	15	Supraorbital	4	1	2	8	2	0	Hydrocephalus 1	15

Table 1. **Summarized data.** ***(End)***

Authors, year	Number of patients, *n*	Access	Visual disorders, *n*		Olfactory impairment, *n*		Psychoemotional and/or cognitive disorders, *n*		Complications, *n*	Extent of resection (Simpson I, II), *n*
			Before	After	Before	After	Before	After		
F. Zenga et al., 2020 [26]	50	Through frontal sinus	3	1	35	38	17	4	CSF leakage 7 Meningitis 2 Death 2	50
H. Emmez et al., 2022 [27]	18	Pterional	5	4	10	5	2	1	CSF leakage 2 Hematoma 2	14
P.O. Champagne et al., 2023 [28]	75	Endoscopic transnasal	24	20	38	75	37	1	Nosebleed 1 Sinusitis 1 CSF leakage 17 Meningitis 3	45
L. Marenco-Hillembrand et al., 2023 [29]	14	Supraorbital	0	0	5	9	2	0	–	14
A.J. Wang et al., 2024 [30]	13	Endoscopic transnasal	0	0	4	13	1	1	CSF leakage 1 Abscess 1 Death 1	7

mor bed, progression of cerebral edema in postoperative period and tension pneumocephalus. This group also has one of the highest mortality rates (4%). The advantages of subfrontal craniotomy include technical simplicity, comfortable access to sinuses and early tumor devascularization, including extradural one. Some authors emphasize frontal lobe traction, craniotomy limited by frontal sinus dimensions, delayed visualization of vessels and nerves, as well as unsatisfactory cosmetic result as disadvantages [29, 30].

In case of endoscopic transnasal surgery, CSF leakage was the most common complication (24% of cases). The advantages of endoscopic transnasal approach include extensive visualization of anterior skull base and possible total resection of hyperostosis and tumor matrix. However, this approach results in extensive skull base defect requiring complex multilayer reconstruction using autologous tissue and fibrin-thrombin composites [31, 32].

The lowest complication rates were observed after lateral supraorbital (16%) and subfrontal (17%) approaches.

Transfrontal sinus approach resulted in total tumor resection in 100% of patients. The advantages of this approach are wide surgical corridor with large angles of attack, visualization of anterior and lateral tumor borders, the most basal approach among all transcranial ones, possible resection of tumor remnants inside the sinus, basal hyperostosis and tumor matrix. The disadvantages include major surgical trauma, cranialization of frontal sinus with high risk of cerebrospinal fluid leakage and infection, complex multilayer repair requiring adequate equipment and unsatisfactory cosmetic result [33].

Total resection was rare (76%) after lateral supraorbital approach. Lateral supraorbital approach offers the same advantages as conventional pterional approach, but it is less traumatic and faster. CSF drainage after opening the basal cisterns provides visualization of necessary neurovascular structures. This approach also allows for preservation of contralateral olfactory tract. The disadvantage of this approach is small angles of attack, especially in patients with tumor components inside the sinus and/or significant rostral spread. Craniotomy with this approach is also highly variable and depends on frontal sinus size [34—42].

Data on complications, advantages and disadvantages of each approach are presented in **Table 2**.

Conclusion

Despite rapid advancement of radiotherapy, surgery is still primary treatment for olfactory meningiomas. Modern traditional transcranial, minimally invasive and endoscopic transnasal approaches have some advantages and disadvantages. Therefore, the choice of approach should be based on location and spread of tumor, involvement of vessels and nerves, severity of perifocal edema and involvement of paranasal sinuses. To achieve satisfactory results, one should also consider the risk of postoperative complications.

Author contribution:
Concept and design of the study — Dzhindzhikhadze R.S.
Collection and analysis of data — Abdullaev A.N.
Writing the text — Dzhindzhikhadze R.S., Abdullaev A.N.
Editing — Dzhindzhikhadze R.S., Abdullaev A.N., Polyakov A.V., Gadzhiagaev V.S., Zaitsev A.D., Salyamova E.I.

The authors declare no conflicts of interests.

REFERENCES

1. Tuna H, Bozkurt M, Ayten M, Erdogan A, Deda H. Olfactory groove meningiomas. *Journal of Clinical Neuroscience*. 2005;12(6):664-668. https://doi.org/10.1016/j.jocn.2005.05.002
2. Aguiar PH, Tahara A, Almeida AN, Simm R, Silva AN, Maldaun MV, Panagopoulos AT, Zicarelli CA, Silva PG. Olfactory groove meningiomas: approaches and complications. *Journal of Clinical Neuroscience*. 2009;16(9):1168-1173. https://doi.org/10.1016/j.jocn.2008.12.013
3. Barić H, Komljenović S, Garcia SG, Niemelä M. Skull base meningiomas: A bibliometric analysis and comprehensive overview of clinical reports. *Neurochirurgie*. 2025;71(2):101632. https://doi.org/10.1016/j.neuchi.2025.101632
4. Sasaki H. [Meningioma]. *No Shinkei Geka*. 2023;51(5):829-836. (Japanese). https://doi.org/10.11477/mf.1436204824
5. Boetto J, Birzu C, Kalamarides M, Peyre M, Sanson M. Les méningiomes: mise au point sur les connaissances actuelles [Meningiomas: A review of current knowledge]. *Revue de Médecine Interne*. 2022;43(2):98-105. (French). https://doi.org/10.1016/j.revmed.2021.06.011
6. Näslund O, Strand PS, Solheim O, Al Masri M, Rapi O, Thurin E, Jakola AS. Incidence, management, and outcome of incidental meningioma: what has happened in 10 years? *Journal of Neuro-Oncology*. 2023;165(2):291-299. https://doi.org/10.1007/s11060-023-04482-5
7. Ho VKY, Anten MM, Garst A, Bos EM, Snijders TJ, Eekers DBP, Seute T; Dutch Brain Tumour Registry (DBTR) and the Dutch Society for Neuro-Oncology (LWNO). Epidemiology of adult meningioma: Report from the Dutch Brain Tumour Registry (2000-2019). *European Journal of Neurology*. 2023;30(10):3244-3255. https://doi.org/10.1111/ene.15979
8. Oya S. [Latest Findings on Meningioma:WHO grades 1/2/3]. *No Shinkei Geka*. 2022;50(3):564-571. (Japanese). https://doi.org/10.11477/mf.1436204588
9. Romani R, Lehecka M, Gaal E, Toninelli S, Celik O, Niemelä M, Porras M, Jääskeläinen J, Hernesniemi J. Lateral supraorbital approach applied to olfactory groove meningiomas: experience with 66 consecutive patients. *Neurosurgery*. 2009;65(1):39-52; discussion 52-53. https://doi.org/10.1227/01.NEU.0000346266.69493.88
10. Demura M, Nakajima R, Tanaka S, Kinoshita M, Nakada M. Mentalizing can be Impaired in Patients with Meningiomas Originating in the Anterior Skull Base. *World Neurosurgery*. 2024;182:e872-e881. https://doi.org/10.1016/j.wneu.2023.12.067
11. Pashkov A, Filimonova E, Poptsova A, Martirosyan A, Prozorova P, Moysak G, Rzaev J. Cognitive, affective and behavioral functioning in patients with olfactory groove meningiomas: a systematic review. *Neurosurgical Review*. 2025;48(1):457. https://doi.org/10.1007/s10143-025-03626-7
12. Barne I, Wells CE, Wheeler M, Bairstow H, Brechin D, Evans S, Lever C. Cognition in Meningioma: Effects of Tumor Location and Tumor Removal. *World Neurosurgery*. 2025;194:123519. https://doi.org/10.1016/j.wneu.2024.11.102
13. Dzhindzhikhadze RS, Dreval' ON, Lazarev VA, Bogdanovich IO. Evolution of surgical approaches to the anterior and middle cranial fossa: from extended craniotomy to the supraorbital keyhole approach. *Burdenko's Journal of Neurosurgery*. 2016;80(3):99-105. (In Russ., In Engl.). https://doi.org/10.17116/neiro201680399-105
14. Westphal M, Saladino A, Tatagiba M. Skull Base Meningiomas. *Advances in Experimental Medicine and Biology*. 2023;1416:47-68. https://doi.org/10.1007/978-3-031-29750-2_5
15. Ganz JC. Meningiomas. *Progress in Brain Research*. 2022;268(1):163-190. https://doi.org/10.1016/bs.pbr.2021.10.031
16. Ungureanu G, Florian A, Florian SI. The impact of arachnoid structures on skull-base meningioma surgical management: a radiological analysis and narrative review. *Journal of Medicine and Life*. 2024;17(7):682-689. https://doi.org/10.25122/jml-2024-0349
17. Pepper JP, Hecht SL, Gebarski SS, Lin EM, Sullivan SE, Marentette LJ. Olfactory groove meningioma: discussion of clinical presentation and surgical outcomes following excision via the subcranial approach. *Laryngoscope*. 2011;121(11):2282-2289. https://doi.org/10.1002/lary.22174
18. Bailo M, Gagliardi F, Boari N, Spina A, Piloni M, Castellano A, Mortini P. Meningioma and Other Meningeal Tumors. *Advances in Experimental Medicine and Biology*. 2023;1405:73-97. https://doi.org/10.1007/978-3-031-23705-8_3
19. Kawabata S, Kashiwagi H, Nonoguchi N, Furuse M, Takami T, Miyatake SI, Wanibuchi M. [Defining the Role of Radiotherapy in Meningioma Treatment]. *No Shinkei Geka*. 2024;52(4):782-793. (Japanese). https://doi.org/10.11477/mf.1436204977
20. Bitter AD, Stavrinou LC, Ntoulias G, Petridis AK, Dukagjin M, Scholz M, Hassler W. The Role of the Pterional Approach in the Surgical Treatment of Olfactory Groove Meningiomas: A 20-year Experience. *Journal of Neurological Surgery Part B: Skull Base*. 2013;74(2):97-102. https://doi.org/10.1055/s-0033-1333618
21. Koutourousiou M, Fernandez-Miranda JC, Wang EW, Snyderman CH, Gardner PA. Endoscopic endonasal surgery for olfactory groove meningiomas: outcomes and limitations in 50 patients. *Neurosurgical Focus*. 2014;37(4):E8. https://doi.org/10.3171/2014.7.focus14330
22. Farooq G, Rehman L, Bokhari I, Rizvi SRH. Modern Microsurgical Resection of Olfactory Groove Meningiomas by Classical Bicoronal Subfrontal Approach without Orbital Osteotomies. *Asian Journal of Neurosurgery*. 2018;13(2):258-263. https://doi.org/10.4103/ajns.AJNS_66_16
23. Ciurea AV, Iencean SM, Rizea RE, Brehar FM. Olfactory groove meningiomas: a retrospective study on 59 surgical cases. *Neurosurgical Review*. 2012;35(2):195-202; discussion 202. https://doi.org/10.1007/s10143-011-0353-2
24. Goel A, Bhaganagare A, Shah A, Kaswa A, Rai S, Dharurkar P, Gore S. Olfactory groove meningiomas: An analysis based on surgical experience with 129 cases. *Neurology India*. 2018;66(4):1081-1086. https://doi.org/10.4103/0028-3886.236989
25. Youngerman BE, Shtayer L, Gerges MM, Larsen AG, Tomasiewicz HC, Schwartz TH. Eyebrow supraorbital keyhole craniotomy for olfactory groove meningiomas with endoscope assistance: case series and systematic review of extent of resection, quantification of postoperative frontal lobe injury, anosmia, and recurrence. *Acta Neurochirurgica*. 2021;163(1):101-112. https://doi.org/10.1007/s00701-020-04552-x
26. Zenga F, Penner F, Cofano F, Lavorato A, Tardivo V, Fontanella MM, Garbossa D, Stefini R. Trans-frontal sinus approach for olfactory groove meningiomas: a 19 year experience. *Clinical Neurology and Neurosurgery*. 2020;196:106041. https://doi.org/10.1016/j.clineuro.2020.106041
27. Emmez H, Aslan A, Demirci H, Çeltikçi E, Kaymaz AM, Börcek AÖ. The unilateral frontotemporal approach for large and giant olfactory groove meningioma: Experience with 18 consecutive patients. *Neurochirurgie*. 2022;68(1):36-43. https://doi.org/10.1016/j.neuchi.2021.04.023
28. Champagne PO, Zenonos GA, Wang EW, Snyderman CH, Gardner PA. The Evolution of Endoscopic Endonasal Approach for Olfactory Groove Meningiomas. *Operative Neurosurgery*. 2023;24(2):121-130. https://doi.org/10.1227/ons.0000000000000464
29. Marenco-Hillembrand L, Bamimore MA, Webb R, Chaichana KL. Unilateral Supraorbital Keyhole Craniotomy Avoiding the Frontal Sinus for Large

and Giant Olfactory-Groove Meningiomas: A Case Series. *World Neurosurgery.* 2023;170:e324-e330.
https://doi.org/10.1016/j.wneu.2022.11.015

30. Wang AJ, Lee CK, Blanch M, Talati PA, Gray ST, Bleier BS, Scangas GA, Holbrook EH, Curry WT. Endoscopic endonasal approach for olfactory groove meningioma resection: Strategies and outcomes in a retrospective case series. *Journal of Clinical Neuroscience.* 2024;122:93-102.
https://doi.org/10.1016/j.jocn.2024.03.001

31. Aguiar PH, Tahara A, Almeida AN, Simm R, Silva AN, Maldaun MV, Panagopoulos AT, Zicarelli CA, Silva PG. Olfactory groove meningiomas: approaches and complications. *Journal of Clinical Neuroscience.* 2009;16(9):1168-1173.
https://doi.org/10.1016/j.jocn.2008.12.013

32. Qasem LE, Al-Hilou A, Oros J, Weber KJ, Keil F, Jussen D, Prinz V, Seifert V, Baumgarten P, Marquardt G, Czabanka M. Single-stage versus two-stage resection for large anterior midline skull base meningiomas with bihemispheric peritumoral edema. *Scientific Reports.* 2025;15(1):7926.
https://doi.org/10.1038/s41598-025-92516-5

33. Yilmaz H, Akcay E, Tabanli A, Bologur O, Ak C, Benek HB, Yurt A. Is Unilateral Extended Pterional Craniotomy Adequate Instead of Bicoronal (Bifrontal) Craniotomy in Large or Giant Olfactory Groove Meningiomas? *Turkish Neurosurgery.* 2025;35(1):56-61.
https://doi.org/10.5137/1019-5149.JTN.46246-24.3

34. Alrasheed AS, Alqurashi A, Ajlan A. The Endoscopic L-Shape Approach for Anterior Skull Base Meningiomas with Olfactory Preservation: A Technical Note. *World Neurosurgery.* 2025;193:1059-1064.
https://doi.org/10.1016/j.wneu.2024.12.006

35. Champagne PO, Zenonos GA, Wang EW, Snyderman CH, Gardner PA. The Evolution of Endoscopic Endonasal Approach for Olfactory Groove Meningiomas. *Operative Neurosurgery.* 2023;24(2):121-130.
https://doi.org/10.1227/ons.0000000000000464

36. Caklili M, Emengen A, Yilmaz E, Genc H, Cabuk B, Anik I, Ceylan S. Endoscopic Endonasal Approach Limitations and Evolutions for Tuberculum Sellae Meningiomas: Data from Single-Center Experience of Sixty Patients. *Turkish Neurosurgery.* 2023;33(2):272-282.
https://doi.org/10.5137/1019-5149.JTN.38489-22.2

37. Ciurea AV, Iencean SM, Rizea RE, Brehar FM. Olfactory groove meningiomas: a retrospective study on 59 surgical cases. *Neurosurgical Review.* 2012;35(2):195-202; discussion 202.
https://doi.org/10.1007/s10143-011-0353-2

38. Cutler CB, Henson JC, Alt J, Karsy M. How I Do It: Endonasal transethmoidal, transcribriform approach for resection of giant olfactory groove meningioma. *Acta Neurochirurgica.* 2022;164(11):2981-2985.
https://doi.org/10.1007/s00701-022-05308-5

39. Xie T, Wang Y, Zhang X, Shao N, Lu W, Yang Q, Qu C, Li C, Liu T, Liu S, Zhu W. Endoscopic Far-Lateral Supracerebellar Infratentorial Approach for Petroclival Region Meningioma: Surgical Technique and Clinical Experience. *Operative Neurosurgery.* 2022;22(5):290-297.
https://doi.org/10.1227/ons.0000000000000126

40. Bander ED, Pandey A, Yan J, Giantini-Larsen AM, Schwartz A, Estin J, Stieg PE, Ramakrishna R, Tsiouris AJ, Schwartz TH. Olfactory groove meningiomas: supraorbital keyhole versus orbitofrontal, frontotemporal, or bifrontal approaches. *Journal of Neurosurgery.* 2023;140(6):1568-1575.
https://doi.org/10.3171/2023.10.JNS231432
https://doi.org/10.1016/j.wneu.2022.11.015

41. Abou-Al-Shaar H, Patel KP, Mallela AN, Sekula RF Jr. Lateral supraorbital approach for resection of large and giant olfactory groove meningiomas: a single center experience. *British Journal of Neurosurgery.* 2023;37(1):90-96.
https://doi.org/10.1080/02688697.2022.2117273

42. de Andrade EJ, Recinos PF. Exoscopic supraorbital approach for a tuberculum sellae meningioma. *Clinical Neurology and Neurosurgery.* 2023;231:107830.
https://doi.org/10.1016/j.clineuro.2023.107830

Received 14.08.2025
Reviced 07.10.2025
Accepted 26.11.2025

COMMENT

This review addresses an issue that has long been undiscussed in the Russian literature, i.e. optimal approach in surgery for basal meningiomas of anterior cranial fossa. The authors analyzed literature data and presented very interesting findings.

The most traumatic bilateral subfrontal approach was found to be the most common (36% of cases) despite associated 4% mortality rate. Moreover, less invasive pterional and lateral supraorbital approaches were less frequent. In my opinion, anterior interhemispheric approach without opening the frontal sinus is optimal for large anterior cranial fossa meningiomas, but it was used in only 4% of cases.

The shortcomings of interhemispheric approach described in the literature are primarily due to shortcomings in anesthetic management, associated with the lack of neuro-anesthesiologists in Western countries and predominant use of inhalational anesthetics (as they are cheaper). Anesthesia administered by universal anesthesiologist who usually works in several operating theater simultaneously often does not provide adequate brain relaxation. Consequently, neurosurgeons are forced to drain basal cisterns and work in a narrow corridor limited by edematous easily traumatized brain. At the Burdenko Neurosurgery Center, surgeries are performed under total brain relaxation and characterized by significantly better results.

Endoscopic transnasal approach was also one of the most common. It was used in 22% of cases despite serious complications in 35% of patients and 100% olfactory loss in follow-up period.

Thus, analysis of modern literature paints a rather grim picture. Despite much talk about minimally invasive surgery, neurosurgeons worldwide (there is only one Russian study in references) predominantly use traumatic and ineffective approaches developed in the last century.

Scientific substantiation of minimally invasive approaches to skull base meningiomas and unbiased determination of optimal ones are undoubtedly relevant.

Kozlov A.V. (Moscow)