Burdenko's Journal of Neurosurgery
2026, No. 2, pp. 92–95
https://doi.org/10.17116/neiro20269002192

Gunshot craniocerebral wound complicated by anaerobic brain abscess

© N.R. Saburov[1], I.N. Isengaliev[2], D.E. Alekseev[1], D.V. Svistov[1], Sh.Kh. Gizatullin[2], I.I. Ivanov[3], I.N. Chirko[4], E.A. Kim[2]

[1]Kirov Military Medical Academy, St. Petersburg, Russia;
[2]Burdenko Main Military Clinical Hospital, Moscow, Russia;
[3]National Medical Research Center for High Technologies — Vishnevsky Central Military Clinical Hospital, Krasnogorsk, Russia;
[4]Soloviev 442nd District Military Clinical Hospital, St. Petersburg, Russia

ABSTRACT
Brain abscess is a focal infectious inflammatory lesion characterized by collection of pus in brain tissue surrounded by a vascularized capsule. The most common cause is spread of microorganisms from distant foci of infection (e.g., odontogenic infection or sinusitis). The risk of intracranial infectious complications and mortality increases significantly in penetrating gunshot wounds to the skull and brain.
Material and methods. Available literature contains a few studies on infectious complications following combat traumatic brain injury. This article presents treatment of anaerobic brain abscess in a patient with previous penetrating gunshot skull wound.
Results. A 24-year-old patient admitted for specialized medical care with penetrating blind radial shrapnel skull and brain wound in the left occipital region complicated by intracerebral anaerobic abscess. The patient underwent secondary surgical debridement of craniocerebral wound, removal of abscess, and drainage system placement. On the fourth postoperative day, sedation was discontinued. There was moderate impairment of consciousness. By the ninth day, consciousness became normal. After primary treatment, the patient was transferred for rehabilitation.
Conclusion. This case highlights the role of strict adherence to the principles of emergency neurosurgical care when treating wounds complicated by intracranial infection.

Keywords: *anaerobic brain abscess, anaerobic infection, brain abscess, traumatic brain injury, complications of traumatic brain injury, gunshot wounds.*

INFORMATION ABOUT THE AUTHORS:
Saburov N.R. — https://orcid.org/0000-0001-9550-2430
Isengaliev I.N. — https://orcid.org/0000-0002-6444-4757
Alekseev D.E. — https://orcid.org/0000-0002-8685-3965
Svistov D.V. — https://orcid.org/0000-0002-3922-9887
Gizatullin Sh.Kh. — https://orcid.org/0000-0002-2953-9902
Ivanov I.I. — https://orcid.org/0009-0008-8436-0105
Chirko I.N. — e-mail: Chirko_ilya87@mail.ru
Kim E.A. — https://orcid.org/0009-0008-6442-2241
Corresponding author: Saburov N.R. — e-mail: nazar3031998@mail.ru

TO CITE THIS ARTICLE:
Saburov NR, Isengaliev IN, Alekseev DE, Svistov DV, Gizatullin ShKh, Ivanov II, Chirko IN, Kim EA. Gunshot craniocerebral wound complicated by anaerobic brain abscess. Case report and literature review. *Burdenko's Journal of Neurosurgery*. 2026;90(2):92–95. (In Russ.). https://doi.org/10.17116/neiro20269002192

Introduction

According to data from Uppsala University dated 2023, the world had a record number of ongoing armed conflicts at that time (59 wars and military clashes). An integral part of any armed conflict is sanitary and irreparable losses resulting from the impact on humans of wounding projectiles from various military small arms, fragmentation and high-explosive munitions, close-combat anti-personnel weapons, explosive munitions, etc. [1]. Traumatic brain injuries account for 15—20% of sanitary losses in modern armed conflicts. Of these, 50% are due to blast injuries, 40% — gunshot wounds (25% — shrapnel wounds, 15% — bullet wounds), 10% — non-gunshot injuries. A trend in modern armed conflicts is predominant blast injuries and shrapnel wounds with severe brain damage [1].

Current realities of combat operations compel medical services to bring qualified and specialized medical care closer to the front lines to reduce mortality and prevent infectious complications. Nevertheless, difficult tactical environment, wide geography of combat operations, high intensity of clashes and logistical difficulties complicate timely evacuation that leads to complications, including infectious ones such as meningitis, encephalitis, ventriculitis, and their progression to empyema and abscesses. The incidence of brain abscesses among all intracranial le-

sions in developing countries is approximately 8%, in developed countries — 1—2%. In the United States, approximately 2.500 patients with brain abscesses are diagnosed annually [2]. However, these data are valid for peacetime. Combat-related skull and brain trauma is characterized by higher incidence of infectious complications: meningitis — 15%, meningoencephalitis — 10—15%, anaerobic empyema — 5%, epi- and subdural empyema — 5—25%, skull bone osteomyelitis — up to 3% [1]. There are no available descriptions of anaerobic brain abscesses following combat-related traumatic brain injury. Therefore, we present successful treatment of such a complication after penetrating gunshot skull wound.

A 24-year-old patient was transported by the ambulance for qualified care. Time and circumstances of injury were unclear.

Hemodynamic data were stable upon admission. Consciousness was suppressed by drug-induced sedation at the previous stage. Body temperature was normal. Pupils were medium-sized (D=S), and light reaction was slow on both sides. Protective motor response with limb withdrawal was noted in response to painful stimuli. After removing the head bandage, we visualized a lacerated contused occipital wound with foul-smelling, foamy, creamy discharge.

CT of the head **(Fig. 1)** revealed brain tissue abnormalities in occipital region with gas inclusions in parenchyma of the left occipital and temporal lobes and in lateral ventricles. Laboratory tests revealed leukocytosis (up to 12×10^9/L), moderate anemia and thrombocytosis. Considering clinical, laboratory and neuroimaging data, we diagnosed shrapnel penetrating blind radial wound of the skull and brain in the left occipital region with intracerebral anaerobic abscess, gunshot perforated fracture of the left occipital bone.

Following preliminary preparation in intensive care unit, the patient was delivered to the operating theater. After wound debridement and excision of nonviable tissue, we visualized irregularly elongated entry wound with crushed, jagged edges, coated with debris and traces of soil, hair, and blood. Wound floor was covered with foul-smelling foaming detritus **(Fig. 2a)**.

After head fixation in the Mayfield-Kees clamp, we performed craniotomy in the left occipital zone. Examination of epidural space revealed dura mater defect with discharge of infected brain debris. A sample of fluid was harvested using an applicator, placed in Kitt-Tarozzi medium and sent to the laboratory for bacterial analysis **(Fig. 2b)**. Dura mater incision in horseshoe-shaped fashion was followed by total removal of necrotic brain tissue (left occipital and partially left temporal lobe). To prevent recurrent abscess, we repeatedly irrigated surgical field with 1% hydroxymethylquinoxaline dioxide. Surgery was finished after dura mater closure with periosteal flap and placement of subdural drainage tubes **(Fig. 2c)**.

Postoperative CT the next day confirmed total debridement of abscess, no signs of gas and normal position of drainage tubes **(Fig. 3)**. The same day, the patient was transferred to the Burdenko Main Military Clinical Hospital for further intensive care. Bacteriological analysis revealed growth of Proteus mirabilis, Escherichia coli and Enterococcus faecalis. Furthermore, laboratory testing revealed the human immunodeficiency virus. HIV infection was probably one of the factors contributing to anaerobic abscess and latent clinical data due to immunosuppression in this patient.

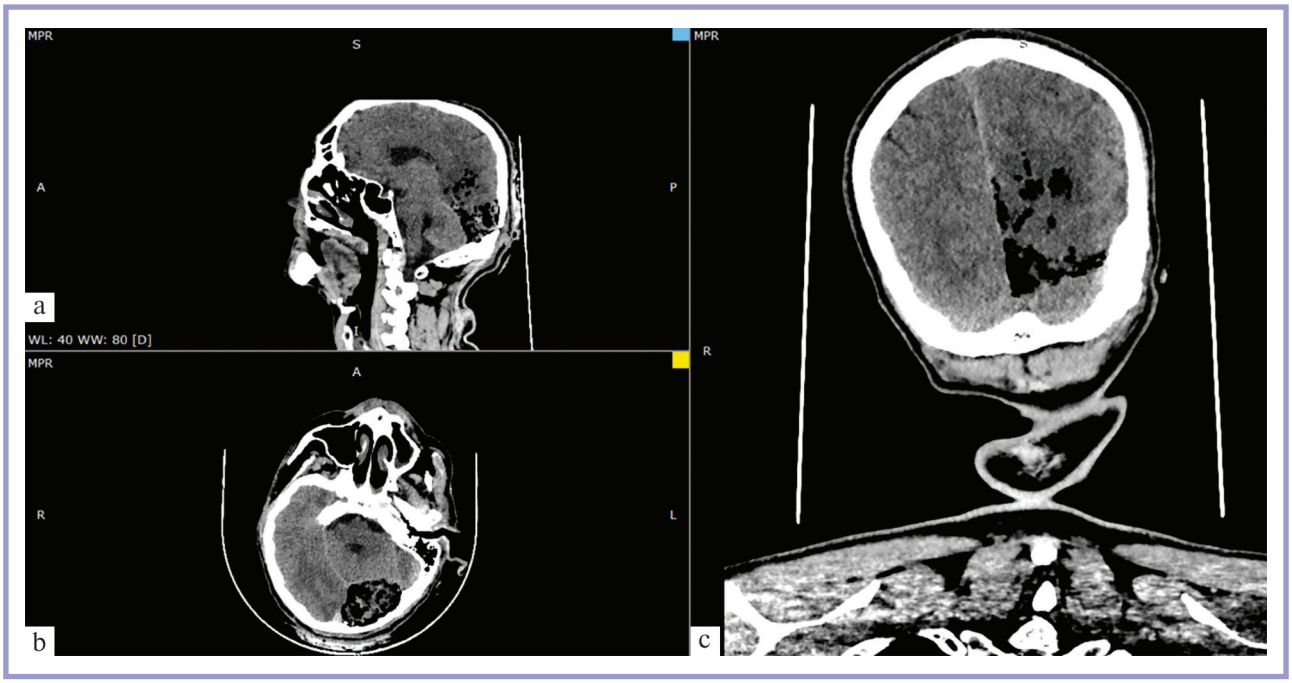

Fig. 1. **CT upon admission.**
a — sagittal images (gas spreading along the tentorium cerebelli across the occipital lobe to the parietal lobe; b — total lesion of the left occipital lobe; c — lesion extending throughout the entire thickness of the occipital lobe.

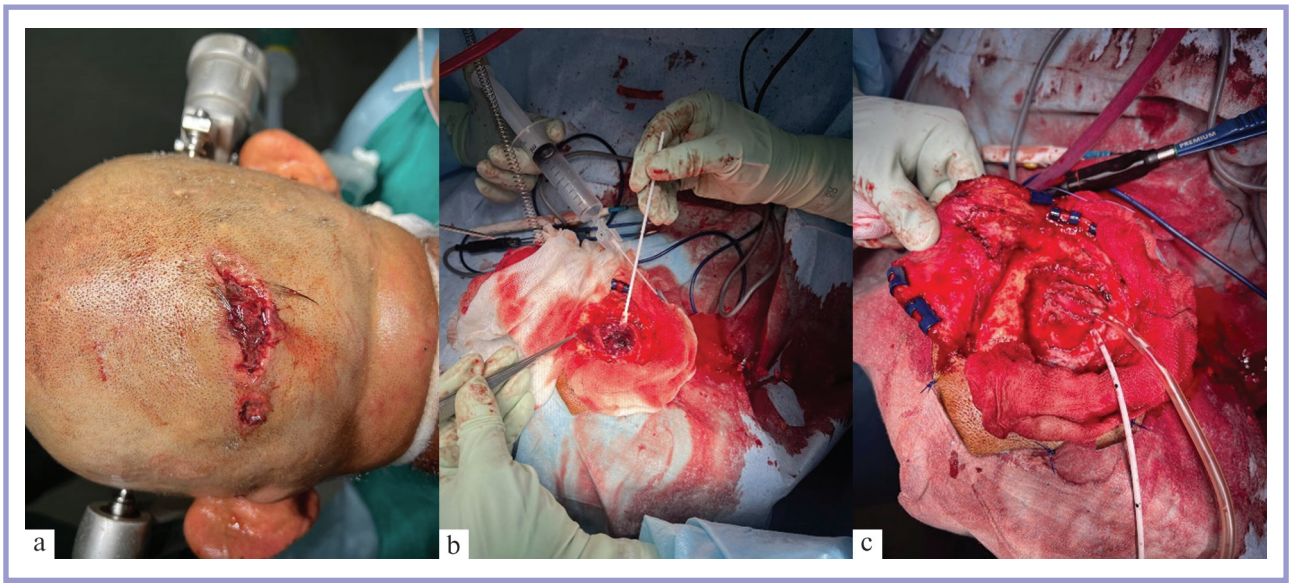

Fig. 2. **Intraoperative images.**
a — head wound; b — wound after dura mater dissection (applicator with content of brain abscess); c — postoperative view of the wound; dura mater repair, closure of muscular-aponeurotic defect, subdural drainage tubes are placed.

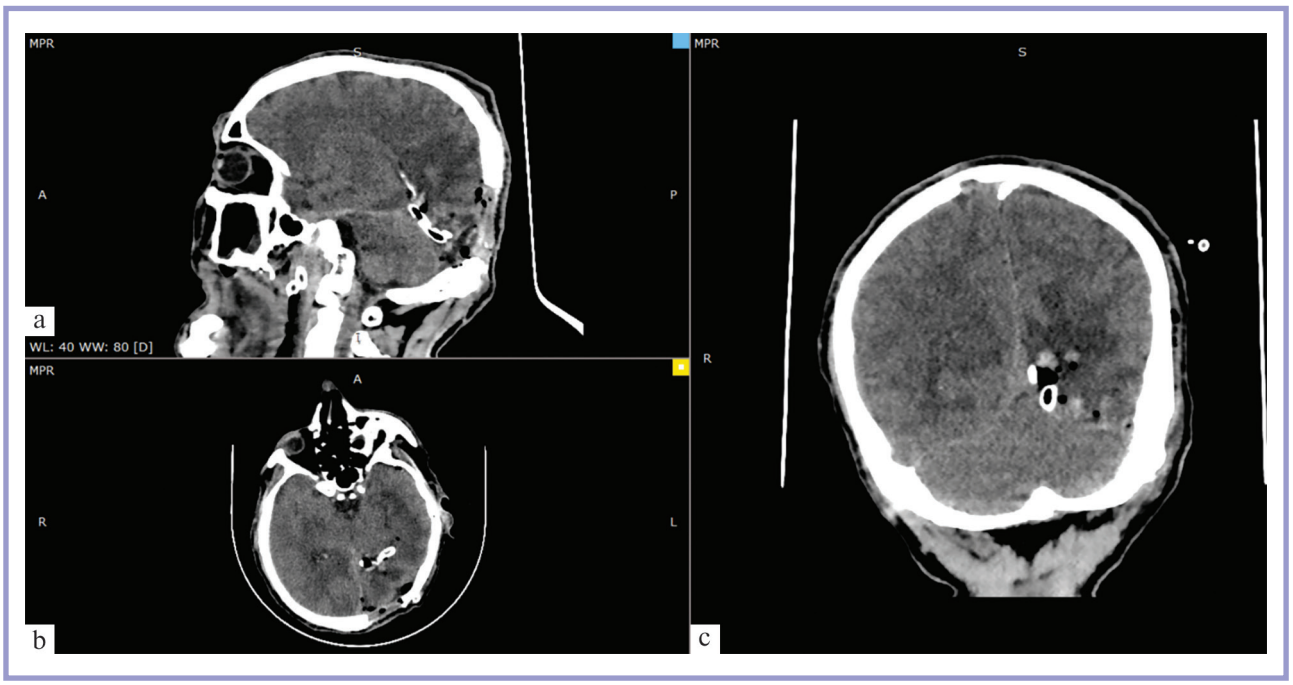

Fig. 3. **CT the next day after surgery.**
a — air inclusions, postoperative brain tissue changes and drainage tube along the tentorium to the posterior horns of the lateral ventricle; b — no altered tissue at the site of occipital lobe abscess, postoperative changes, drainage tube; c — hemorrhagic zones without pathological foci at the surgical site.

Intensive care was accompanied by control of various diagnostic data **(Fig. 4)**. Symptomatic and etiotropic therapy implied systemic administration of meropenem (2.0 g 3 times a day intravenously) and vancomycin (1.0 g 2 times a day intravenously) for 14 days, intrathecal hydroxymethylquinoxaline dioxide (dioxidine) (1.0 ml into drainage tube 2 times a day) and vancomycin (5 mg 2 times a day into drainage tube). Repeated bacteriological analysis of cerebrospinal fluid and drainage output revealed no regrowth of pathogenic microorganisms. Drainage tubes were removed on the 5th day after surgery. Sedation was discontinued in 4 days after surgery. There was moderate impairment of consciousness at that point. By the 9th day, consciousness became normal. Neurological examination revealed right-sided homonymous hemianopsia. After treatment, the patient was transferred for subsequent rehabilitation.

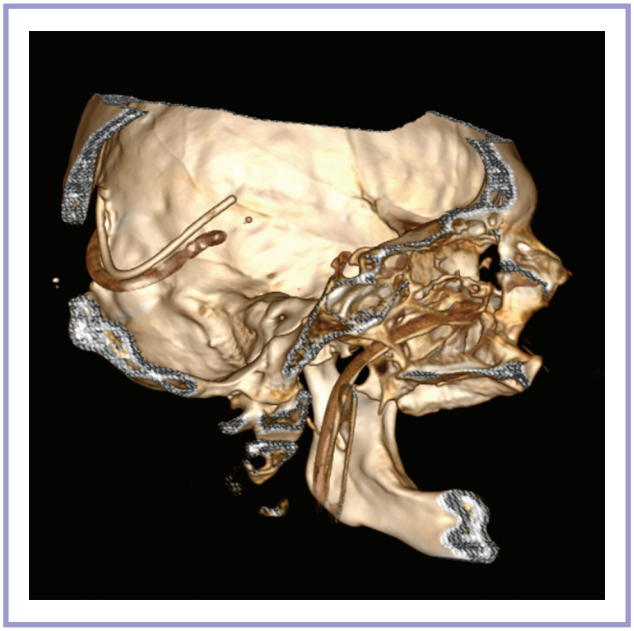

Fig. 4. **Postoperative 3D CT with drainage system.**

Discussion

According to foreign data, management of brain abscesses posed a complex challenge for surgeons in the 20th century. Mortality rates reached 30—50%. This was primarily due to narrow range of available antibiotics at the time, as well as inadequate diagnostic methods. However, this value decreased to 4—20% by the first decade of the 21st century [3]. In elective surgery, primary etiologic factor of brain abscess is focal infection in the body (inflammation of mastoid cells, sinusitis, odontogenic infection or hematogenous dissemination from other sites) [4–6]. A distinctive challenge of infectious complications after penetrating craniocerebral wounds is no timely and comprehensive diagnosis, as well as periodic difficulties with evacuation of wounded due to active combat operations. As a result, specialized care is often available only at the stage of severe neurological disorders and impaired consciousness following extensive brain damage by unidentified infectious agent. According to foreign studies, the most common pathogens in local dissemination are Staphylococcus aureus, Streptococci, Enterobacteriaceae, and Pseudomonas aeruginosa. Bacteroides fragilis predominate among anaerobic pathogens. Mycobacterium tuberculosis was the causative agent in one case [7]. These pathogens do not match those extracted from wound discharge in our case.

In this case, penetrating craniocerebral wound apparently was not perceived by the wounded person as a serious injury. Perhaps, combat situation at that moment prevented him from being evacuated in a timely manner. Impaired immune status together with these factors led to extensive purulent brain lesion with persistent visual impairment.

Conclusion

This case demonstrates that delayed specialized care for penetrating gunshot skull wounds, especially in patients with immunosuppression (HIV), lead to severe polymicrobial anaerobic brain abscesses. Aggressive wound debridement with drainage and subsequent antibiotic therapy were essential for favorable outcome. This case confirms the need for early diagnosis, active surgical management and analysis of immune status to prevent life-threatening complications and minimize neurological disorders.

Author contribution:
Concept and design of the study, editing — Gizatullin Sh.Kh., Svistov D.V., Ivanov I.I., Chirko I.N., Kim E.A.
Collection and analysis of data — Saburov N.R., Isengaliev I.N., Alekseev D.E.
Writing the text and data analysis — Saburov N.R., Isengaliev I.N.

The authors declare no conflicts of interests.

REFERENCES

1. Samokhvalov IM ed. *Military field surgery. National guidelines.* M.: GEOTAR-Media; 2024. (In Russ.).
2. McClelland S 3rd, Hall WA. Postoperative central nervous system infection: incidence and associated factors in 2111 neurosurgical procedures. *Clinical Infectious Diseases.* 2007;45(1):55-59. https://doi.org/10.1086/518580
3. Bodilsen J, D'Alessandris QG, Humphreys H, Iro MA, Klein M, Last K, Montesinos IL, Pagliano P, Sipahi OR, San-Juan R, Tattevin P, Thurnher M, de J Treviño-Rangel R, Brouwer MC; ESCMID Study Group for Infections of the Brain (ESGIB). European society of Clinical Microbiology and Infectious Diseases guidelines on diagnosis and treatment of brain abscess in children and adults. *Clinical Microbiology and Infection.* 2024;30(1):66-89. https://doi.org/10.1016/j.cmi.2023.08.016
4. Cantiera M, Tattevin P, Sonneville R. Brain abscess in immunocompetent adult patients. *Revue Neurologique.* 2019;175(7-8):469-474. https://doi.org/10.1016/j.neurol.2019.07.002
5. Cobo F. Brain abscesses caused by anaerobic microorganisms: a systematic review. *Revista Española de Quimioterapia.* 2023;36(2):152-159. https://doi.org/10.37201/req/114.2022
6. Cobo F, Martin-Hita L, Navarro-Marí JM. Brain abscesses caused by anaerobic bacteria. *Anaerobe.* 2022;76:102614. https://doi.org/10.1016/j.anaerobe.2022.102614
7. Chetty M, Rakhi B, Rachana K, Sujatha S, Srinivasan GM. An Eight Year Clinico-Microbiological Retrospective Study on Brain Abscesses in India. *Microbiology Insights.* 2022;15:11786361221106111. https://doi.org/10.1177/11786361221106111

Received 09.05.2025
Reviced 12.01.2026
Accepted 30.01.2026