Burdenko's Journal of Neurosurgery
2026, No. 2, pp. 85–89
https://doi.org/10.17116/neiro20269002185

Effect of cabergoline on fibrosis in prolactinoma

© I.A. Matsueva, A.A. Paltsev, K.A. Guseva, U.A. Tsoy, E.N. Grineva

Almazov National Medical Research Center, St. Petersburg, Russia

ABSTRACT

Dopamine agonists are an effective and safe treatment for prolactinomas. However, analysis of recent data has shown that dopamine agonists, including cabergoline, can cause tumor fibrosis and complicate subsequent surgery.

Objective. To determine the presence or absence of prolactinoma fibrosis in patients receiving cabergoline before surgery and to evaluate its impact on postoperative outcomes.

Material and methods. The study included 58 patients with prolactinoma and preoperative cabergoline therapy who underwent transsphenoidal adenomectomy between January 2018 and March 2025. To identify fibrosis, we analyzed prolactinoma tissue samples regarding connective tissue using Masson's trichrome staining.

Results. Fibrosis in prolactinoma was detected in 18 (31%) patients who received cabergoline. Comparison of patients with prolactinoma fibrosis (group 1, 18 patients) with patients whose prolactinomas did not show fibrosis (group 2, 40 patients) revealed significant differences regarding treatment duration and cabergoline dose (76 vs. 17 months, $p<0.001$; 3.25 mg/week vs. 2 mg/week, respectively, $p=0.049$). Resection of fibrous prolactinoma required more time (median 30 min) than non-fibrous prolactinoma (20 min) ($p=0.04$). The total number of complications was higher in patients with prolactinoma fibrosis ($p=0.041$).

Conclusion. Treatment of prolactinoma with cabergoline can lead to fibrosis, and appropriate probability is associated with duration of preoperative therapy. Cabergoline-induced fibrosis increased duration of resection and number of complications.

Keywords: *neuroendocrine tumor, prolactinoma, transsphenoidal adenomectomy, prolactinoma fibrosis, dopamine agonists.*

INFORMATION ABOUT THE AUTHORS:
Matsueva I.A. — https://orcid.org/0000-0003-2996-0067
Paltsev A.A. — https://orcid.org/0000-0002-9966-2965
Guseva K.A. — https://orcid.org/0009-0009-4477-9128
Tsoy U.A. — https://orcid.org/0000-0003-4013-4831
Grineva E.N. — https://orcid.org/0000-0003-0042-7680
Corresponding author: Matsueva I.A. — e-mail: irina.macueva.98@mail.ru

TO CITE THIS ARTICLE:
Matsueva IA, Paltsev AA, Guseva KA, Tsoy UA, Grineva EN. Impact of cabergoline on fibrosis in prolactinoma. *Burdenko's Journal of Neurosurgery*. 2026;90(2):85–89. (In Russ.). https://doi.org/10.17116/neiro20269002185

Introduction

Prolactin-secreting pituitary tumor or prolactinoma is one of the most common pituitary neuroendocrine tumors. Prevalence of prolactinomas ranges from 444 to 540 cases per million people, and annual incidence varies from 16 to 26 cases per million [1–3].

Despite active debate about whether transsphenoidal adenomectomy can replace dopamine agonists in first-line treatment for prolactinomas [4, 5], traditional approach prevails in clinical practice. In most cases, first-line treatment with dopamine agonists is followed by transsphenoidal adenomectomy in case of ineffectiveness, intolerance or side effects [2, 3]. Treatment of prolactinomas with cabergoline is an example of one of the most successful drug interventions with normalization of serum prolactin in 73—96% of cases and more than 50% shrinkage of tumor in 47—97% of patients [5]. Side effects and drug intolerance are rare [6]. However, very low (34%) rates of long-term remission after discontinuation of DAs necessitate long-term and even lifelong therapy [6]. An important circumstance preventing long-term drug treatment for prolactinoma is associated with available data on DA-induced tumor fibrosis complicating subsequent surgery [7—9]. Most available studies are devoted to the relationship between prolactinoma fibrosis and bromocriptine therapy. There are few data on cabergoline [7—9], although this drug is currently the main one in the treatment of prolactinomas.

The purpose of the study was to analyze fibrosis in prolactinomas after preoperative cabergoline therapy and its effect on postoperative outcomes.

Material and methods

An observational single-center retrospective study was approved by local ethics committee.

Table 1. **Characteristics of patients in both groups.**

Variable	Group 1 (*n*=18)	Group 2 (*n*=40)	*p*
Women, *n* (%)	6 (33.3)	17 (41)	0.485
Men, *n* (%)	12 (66.7)	23 (59)	
Age, years (Me, Q_1—Q_3)	43 (35—61)	49 (33—60)	0.806
Serum prolactin before surgery, ng/ml (Me, Q_1—Q_3)	455 (67—896)	153 (60—710)	0.35
Volume of prolactinoma before surgery, cm3 (Me, Q_1—Q_3)	10.46 (5.24—19.18)	11.21 (3.85—17.66)	0.13
Patients with macroadenoma, *n* (%)	18 (100)	38 (95)	0.46
Patients with invasion Knosp grade 3–4, *n* (%)	8 (44)	13 (32.5)	0.56
Ki-67, Me, Q_1—Q_3	1.1—1.5	1.1—1.4	0.9

Table 2. **Perioperative data in both groups.**

Variable	Group 1 (*n*=18)	Group 2 (*n*=40)	*p*
Tactile sensations of neurosurgeon, *n* (%):			
mellow	12 (66.7)	36 (90)	0.06
dense	6 (33.3)	4 (10)	
Resection time, min (Me, Q1—Q3)	30 (20—50)	20 (15—30)	0.04*
Blood loss, *n* (%):			
<100 ml	15 (83.3)	36 (90)	0.297
101–500 ml	3(16.7)	4 (10)	
Complications after surgery, *n* (%):			
no	13 (72)	38 (96)	0.041*
CSF leakage	3 (16)	1 (2)	
other ones (hemorrhage into the tumor, meningitis, inflammation of paranasal sinuses)	2 (12)	1 (2)	

There were 58 patients with prolactinoma who underwent transsphenoidal adenomectomy between 2018 and 2025. All patients received cabergoline before surgery. There were 37 (63%) men (median age 41 (34—61) years) and 21 (37%) women (median age 51 (34—61) years). In 24 (41%) patients, surgery was needed due to resistance to dopamine agonists. Six (10%) patients had pituitary apoplexy. In 28 (49%) cases, transsphenoidal adenomectomy was a joint decision between the patient and the physician.

Prolactinoma was verified after immunohistochemical analysis of tumor tissue in all patients. In addition to staining for prolactin, we analyzed Ki-67 proliferative index in all prolactinomas. To identify fibrosis, we examined prolactinoma tissue samples for connective tissue using Masson's trichrome staining. If connective tissue (fibrosis) was detected, we calculated its area using the ImageScope program (Leica Biosystems, Germany) as a percentage (0—100%) **(Fig. 1—3)**.

In all patients, we assessed duration of therapy and doses of cabergoline before transsphenoidal adenomectomy, serum prolactin before surgery, on the 1st day after surgery and 3 months later. Prolactin was measured in ng/mL (normal range 4.04—15.2 ng/mL for men and 4.79—23.3 ng/mL for women). If serum prolactin was measured in other units, we converted them to ng/ml using SlimHauz calculator (SlimHauz, Russia). We assessed MR data on sellar area including size of adenoma and cavernous sinus invasion. To assess dimensions of prolactinoma, we calculated its volume in cm^3 using the formula:

$$V=(\pi/6)\cdot h\cdot l\cdot w,$$

where h — height of adenoma, l — length of adenoma, w — width of adenoma.

Prolactinoma invasion was determined according to the Knosp classification [10]. Data on duration of resection and neurosurgeon's tactile sensations (soft-elastic, dense adenoma) were obtained from reports of surgeries. Serum prolactin after 3 months was provided by patients via email or telephone.

We compared the above-mentioned parameters, as well as duration and total dose of cabergoline in patients with and without fibrosis of prolactinoma tissue. Intraoperative tumor characteristics, results of transsphenoidal adenomectomy, intraoperative and postoperative complications were also assessed.

Statistical analysis was performed using IBM SPSS Statistics version 28 for Windows (IBM Corp., USA). Distribution normality was analyzed using the Shapiro—Wilk test (number of subjects <50) in each group. Distribution was non-parametric, and we presented results as median (Me) and interquartile range (Q_1—Q_3). Between-group comparisons were made using nonparametric methods (Mann-Whitney test, Fisher's exact test,

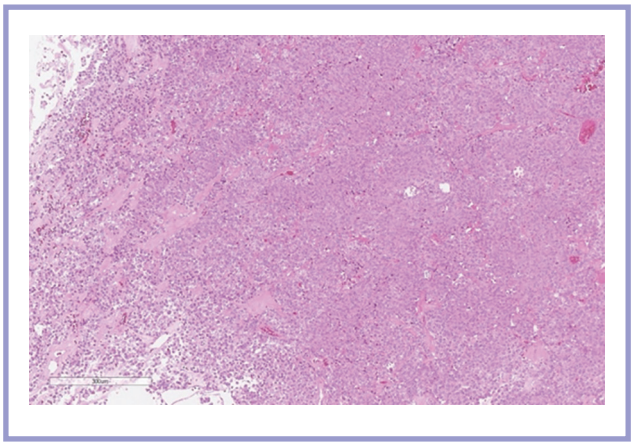

Fig. 1. **Prolactinoma without fibrosis (Masson's trichrome staining, x 200).**

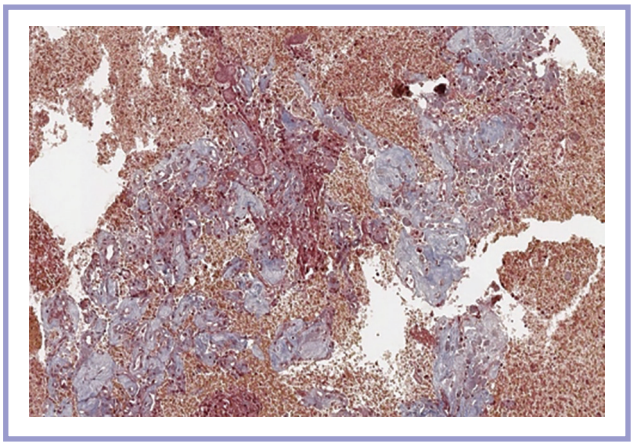

Fig. 2. **Prolactinoma tissue with 22% fibrosis area (Masson's trichrome staining, x200).**

relative risk and odds ratios, contingency tables). When comparing dependent sample, we used the Friedman test considering non- parametric distribution of variables. Differences were significant at $p<0.05$. Multivariate binary logistic regression was used for prognostic model of fibrosis. We also performed ROC analysis to determine significant duration of preoperative cabergoline therapy. Spearman's rank correlation coefficient was used to assess the relationship between prolactinoma fibrosis area (%) and duration of preoperative cabergoline therapy.

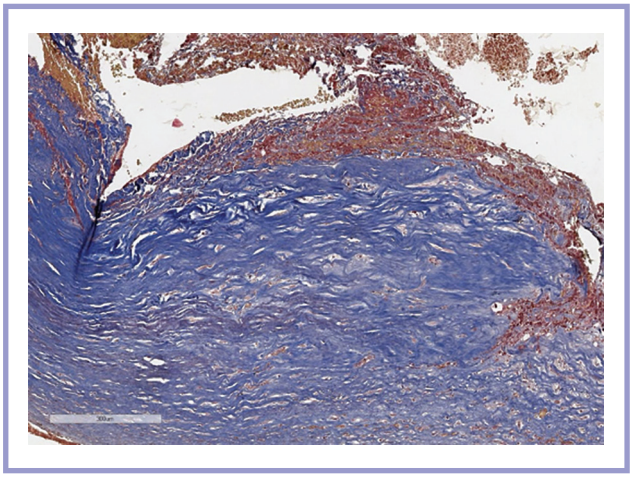

Fig. 3. **Prolactinoma tissue with 99% fibrosis area (Masson's trichrome staining, x200).**

Results

We found fibrosis (5.2—99%) in 18 (31%) patients.

Patients were divided into 2 groups depending on fibrosis: group 1 (18 people) with prolactinomas fibrosis and group 2 (40 people) without tumor tissue fibrosis. There were no between-group differences in several parameters **(Table 1)**.

There were significant differences in duration of preoperative cabergoline therapy (76 (53—94) vs. 17 (13—24) months, $p<0.001$), as well as cabergoline dose (3.25 (2—4) vs. 2 (2—4) mg/week, $p=0.049$).

Cabergoline therapy did not lead to normalization of serum prolactin in any group. Serum prolactin before therapy was 2219 (909—3503) and 1615 (200—3000) ng/ml, respectively ($p=0.047$). Prior to surgery, this value decreased to 455 (67—896) and 153 (60—710) ng/ml, respectively (insignificant differences). There were also no significant changes in dimensions of prolactinomas. In group 1, median volume of prolactinoma before therapy was 10.4 (5.6—28.4) cm^3, before surgery — 10.46 (5.24—19.18) cm^3 ($p=0.41$). In group 2, these values were 8.97 (3.43—15.75) and 11.21 (3.85—17.66) cm^3, respectively ($p=0.19$).

We analyzed ROC curve to establish the relationship between the risk of prolactinoma fibrosis and duration of cabergoline therapy **(Fig. 4)**. The area under the curve was 0.895, 95% confidence interval — 0.795—0.996. Sensitivity and specificity of the method for cabergoline therapy duration ⩾37 months were 94% and 90%, respectively. Final model was significant ($p<0.001$).

Total resection of prolactinoma was performed in 25 (43%) patients (7 (39%) and 18 (45%) patients, respectively, $p=0.45$). Serum prolactin did not differ between groups in early postoperative period (days 1—3) (86.5 (32—1695) and 120 (43—1416) ng/ml, respectively, $p=0.606$). After 3 postoperative months, we had available data on prolactin in 13 patients from group 1 and 30 ones from group 2 (222 (22—846) and 67.5 (21—279) ng/ml, respectively, $p=0.03$).

According to neurosurgeon's sensations, 33.3% of prolactinomas in group 1 were dense and only 10% in group 2, but these differences were not significant ($p=0.06$). Duration of prolactinoma resection was 30 (20—50) and 20 (15—30) min, respectively ($p=0.04$). Blood loss was similar and minor in both groups. Postoperative complications were rare, but they were more common in group 1 ($p=0.041$) **(Table 2)**.

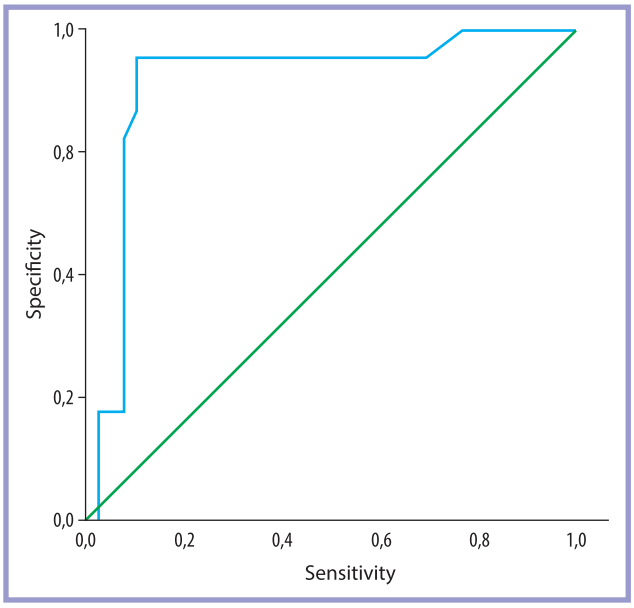

Fig. 4. **ROC curve characterizing the probability of fibrosis depending on duration of cabergoline intake.**

Discussion

Landolt A.M. was one of the first researchers to report the relationship between prolactinoma fibrosis and bromocriptine therapy. He used electron microscopy to quantify fibrous tissue around vessels in prolactinomas of patients who received (21 people) and did not receive (21 people) bromocriptine before surgery. The author convincingly demonstrated ($p<0.002$) higher perivascular fibrosis in patients who received bromocriptine before surgery [11]. These results were confirmed by other researchers [9, 12, 13]. Data on prolactinoma fibrosis following cabergoline therapy are presented mainly by case reports [14, 15] or analysis of patients treated with both bromocriptine and cabergoline [7]. Menucci M. et al. [7] analyzed treatment outcomes in 24 patients and found fibrous tumor consistency in 77% of patients after preoperative bromocriptine therapy and 22% of patients after preoperative cabergoline therapy. Among previously untreated patients, prolactinoma turned out to be fibrous in 33% of cases. In 2024, Chen Z. et al. [9] published one of the largest studies (290 patients with prolactinomas scheduled for transsphenoidal adenomectomy). Dense tumors were significantly more common in patients treated with dopamine agonists ($p<0.001$). When assessing collagen content in excised tumors, its proportion in «dense» prolactinomas was significantly higher ($p=0.002$). The majority (88.6%) of patients received only bromocriptine before surgery, and the authors were able to obtain association of collagen content only for this drug.

We included patients who received only cabergoline. Fibrous prolactinomas contained more than 5% collagen [16]. We identified such tumors in 31% of patients. Unlike Landolt A.M. [11], we did not find a relationship between fibrosis and age/gender of patients. This may be due to age differences. In the study by Landolt A.M., mean age was 27.7±6.1 years, in our study — 41 years in men and 51 years in women. Duration of preoperative cabergoline therapy was significantly longer in patients with fibrosis ($p<0.001$). Takahashi T. et al. [17] obtained similar results for bromocriptine therapy. Chen Z. et al. [9] found positive correlation between amount of collagen in patients with macroadenomas and cumulative dose of bromocriptine ($r=0.438$; $p<0.001$). According to ROC analysis, threshold total dose of bromocriptine significantly increasing the risk of fibrosis was 206 mg, duration of bromocriptine therapy — 2.5 months. For both indicators, sensitivity and specificity were 64.3% and 74.3%, respectively. In our model, duration of drug treatment ⩾37 months predicted fibrosis with sensitivity 94% and specificity 90%.

According to some researchers, prolactinoma fibrosis associated with dopamine agonists worsens the results of transsphenoidal adenomectomy. Thus, Menucci M. et al. [7] demonstrated less successful results of adenomectomy and higher risk of intraoperative complications in patients who received both bromocriptine and cabergoline. However, other studies revealed that preoperative dopamine agonists both improved results of transsphenoidal adenomectomy [18] and did not affect these outcomes [19]. Baussart B. et al. [20] stated fibrosis as a property of tumor rather consequence of treatment. Wright K. et al. [21] analyzed 35 studies and found that no preoperative dopamine agonists was one of the factors associated with higher rates of postoperative remission.

Unlike previous studies [11, 12, 14, 15], prolactinoma fibrosis did not affect resection of adenoma in our study. We also found no differences between normalization of serum prolactin immediately after transsphenoidal adenomectomy in patients with and without fibrosis. However, serum prolactin after 3 months was significantly higher in patients with fibrosis ($p=0.03$). Menucci M. et al. [7] presented similar data and established complete biochemical remission in 37% of patients without signs of fibrosis and in none with «fibrotic» prolactinoma. The authors emphasized that 2 out of 3 patients with signs of biochemical remission received cabergoline before surgery.

According to our data, resection was significantly longer in patients with fibrosis of prolactinoma ($p=0.04$). Fibrous prolactinomas are denser than prolactinomas without fibrosis ($p=0.06$). Ryba A. et al. [8] retrospectively analyzed surgical treatment of 159 patients. Surgery time was significantly longer in patients who received dopamine agonists (mainly cabergoline). The authors associated these differences with tumor changes caused by dopamine agonists. Postoperative complications (cerebrospinal fluid leakage, hemorrhage into the tumor, meningitis, inflammation of paranasal sinuses) were rare in our group, but more common in patients with fibrous adenomas ($p=0.041$). Menucci M. et al. [7] also found more common complications in patients with fibrous prolactinomas, but differences were not significant. Chen Z. et al. [9] reported significantly higher complication rate in patients with macroprolactinomas and dopamine agonist therapy prior to transsphenoidal adenomectomy compared to surgery as first line treatment.

Conclusion

The risk of prolactinoma tissue fibrosis when taking cabergoline reaches 31%. Severity of fibrosis depends on duration of preoperative cabergoline therapy. Patients with fibrous prolactinoma are characterized by higher complication rate after transsphenoidal adenomectomy and longer surgery time.

Study limitations

Our single-center retrospective study included a small cohort of patients. In addition, we excluded patients who did not receive cabergoline before transsphenoidal adenomectomy and patients with microprolactinoma.

Author contribution:
Concept and design of the study — Matsueva I.A. Grineva E.N
Collection and analysis of data — Matsueva I.A., Paltsev A.A., Guseva K.A.
Statistical analysis — Matsueva I.A.
Writing the text — Matsueva I.A., Grineva E.N, Paltsev A.A.
Editing — Grineva E.N. Tsoy U.A.
The authors declare no conflicts of interests.

REFERENCES

1. Melmed S, Kaiser UB, Lopes MB, Bertherat J, Syro LV, Raverot G, Reincke M, Johannsson G, Beckers A, Fleseriu M, Giustina A, Wass JAH, Ho KKY. Clinical Biology of the Pituitary Adenoma. *Endocrine Review.* 2022;43(6):1003-1037. https://doi.org/10.1210/endrev/bnac010
2. Petersenn S, Fleseriu M, Casanueva FF, Giustina A, Biermasz N, Biller BMK, Bronstein M, Chanson P, Fukuoka H, Gadelha M, Greenman Y, Gurnell M, Ho KKY, Honegger J, Ioachimescu AG, Kaiser UB, Karavitaki N, Katznelson L, Lodish M, Maiter D, Marcus HJ, McCormack A, Molitch M, Muir CA, Neggers S, Pereira AM, Pivonello R, Post K, Raverot G, Salvatori R, Samson SL, Shimon I, Spencer-Segal J, Vila G, Wass J, Melmed S. Author Correction: Diagnosis and management of prolactin-secreting pituitary adenomas: a Pituitary Society international Consensus Statement. *Nature Reviews Endocrinology.* 2024;20(1):62. https://doi.org/10.1038/s41574-023-00886-5
3. Dedov II, Melnichenko GA, Dzeranova LK, Andreeva EN, Grineva EN, Marova EI, Mokrysheva NG, Pigarova EA, Vorotnikova SY, Fedorova NS, Shutova AS, Przhiyalkovskaya EG, Ilovayskaya IA, Romantsova TI, Dogadin SA, Suplotova LA. Clinical guidelines 'Hyperprolactinemia' (draft). *Obesity and metabolism.* 2023;20(2):170-188. (In Russ.). https://doi.org/10.14341/omet13002
4. Ottenhausen M, Conrad J, Wolters LM, Ringel F. Surgery as first-line treatment for prolactinoma? Discussion of the literature and results of a consecutive series of surgically treated patients. *Neurosurgical Review.* 2023;46(1):128. https://doi.org/10.1007/s10143-023-02033-0
5. Mamelak A. Surgery as a first-line option for prolactinomas. *Expert Review of Endocrinology & Metabolism.* 2022;17(6):485-498. https://doi.org/10.1080/17446651.2022 .2131531
6. Zamanipoor Najafabadi AH, Zandbergen IM, de Vries F, Broersen LHA, van den Akker-van Marle ME, Pereira AM, Peul WC, Dekkers OM, van Furth WR, Biermasz NR. Surgery as a Viable Alternative First-Line Treatment for Prolactinoma Patients. A Systematic Review and Meta-Analysis. *The Journal of Clinical Endocrinology & Metabolism.* 2020;105(3):e32-e41. https://doi.org/10.1210/clinem/dgz144
7. Menucci M, Quiñones-Hinojosa A, Burger P, Salvatori R. Effect of dopaminergic drug treatment on surgical findings in prolactinomas. *Pituitary.* 2011;14(1):68-74. https://doi.org/10.1007/s11102-010-0261-4
8. Ryba A, Gonzalez Lopez D, Rotermund R, Flitsch J. Preoperative treatment with dopamine agonist therapy influences surgical outcome in prolactinoma: a retrospective single-center on 159 patients. *Acta Neurochirurgica.* 2024;166(1):316. https://doi.org/10.1007/s00701-024-06198-5
9. Chen Z, Shou X, Ji L, Cheng H, Shen M, Ma Z, He W, Ye Z, Zhang Y, Qiao N, Zhang Q, Wang Y. Presurgical Medical Treatment in Prolactinomas: Surgical Implications and Pathological Characteristics From 290 Cases. *The Journal of Clinical Endocrinology & Metabolism.* 2024;109(6):1433-1442. https://doi.org/10.1210/clinem/dgad758
10. Knosp E, Steiner E, Kitz K, Matula C. Pituitary adenomas with invasion of the cavernous sinus space: a magnetic resonance imaging classification compared with surgical findings. *Neurosurgery.* 1993;33(4):610-617; discussion 617-618. https://doi.org/10.1227/00006123-199310000-00008
11. Landolt AM, Osterwalder V. Perivascular fibrosis in prolactinomas: is it increased by bromocriptine? *The Journal of Clinical Endocrinology & Metabolism.* 1984;58(6):1179-1183. https://doi.org/10.1210/jcem-58-6-1179
12. Esiri MM, Bevan JS, Burke CW, Adams CB. Effect of bromocriptine treatment on the fibrous tissue content of prolactin-secreting and nonfunctioning macroadenomas of the pituitary gland. *The Journal of Clinical Endocrinology & Metabolism.* 1986;63(2):383-388. https://doi.org/10.1210/jcem-63-2-383
13. Tamasauskas A, Sinkunas K, Bunevicius A, Radziunas A, Skiriute D, Deltuva VP. Transsphenoidal surgery for microprolactinomas in women: results and prognosis. *Acta Neurochirurgica.* 2012;154(10):1889-1893. https://doi.org/10.1007/s00701-012-1450-x
14. Mohan N, Chia YY, Goh GH, Ting E, Teo K, Yeo TT. Cabergoline-induced fibrosis of prolactinomas: a neurosurgical perspective. *BMJ Case Reports.* 2017;2017:bcr2017220971. https://doi.org/10.1136/bcr-2017-220971
15. Pecorari IL, Qama E, Akbar N, Colley P, Fang CH, Agarwal V. The Effect of Preoperative Cabergoline on Prolactinoma Fibrosis: A Case Series. *Journal of Neurological Surgery Reports.* 2024;85(2):e66-e73. https://doi.org/10.1055/s-0044-1786740
16. Wei L, Lin SA, Fan K, Xiao D, Hong J, Wang S. Relationship between pituitary adenoma texture and collagen content revealed by comparative study of MRI and pathology analysis. *International Journal of Clinical and Experimental Medicine.* 2015;8(8):12898-12905.
17. Takahashi T, Kuwayama A, Katoh T, Kageyama N. [Histological changes and operative findings of pituitary adenomas after bromocriptine treatment]. *Nihon Naibunpi Gakkai Zasshi.* 1986;62(12):1336-1351. (Japanese). https://doi.org/10.1507/endocrine1927.62.12_1336
18. Sughrue ME, Chang EF, Tyrell JB, Kunwar S, Wilson CB, Blevins LS Jr. Pre-operative dopamine agonist therapy improves post-operative tumor control following prolactinoma resection. *Pituitary.* 2009;12(3):158-164. https://doi.org/10.1007/s11102-008-0135-1
19. Acitores Cancela A, Rodríguez Berrocal V, Pian-Arias H, Díez JJ, Iglesias P. Letter to the Editor Regarding «The Effect of Preoperative Cabergoline on Prolactinoma Fibrosis: A Case Series». *Journal of Neurological Surgery Reports.* 2024;85(4):e161-e162. https://doi.org/10.1055/s-0044-1791504
20. Baussart B, Villa C, Jouinot A, Raffin-Sanson ML, Foubert L, Cazabat L, Bernier M, Bonnet F, Dohan A, Bertherat J, Assié G, Gaillard S. Pituitary surgery as alternative to dopamine agonists treatment for microprolactinomas: a cohort study. *European Journal of Endocrinology.* 2021;185(6):783-791. https://doi.org/10.1530/EJE-21-0293
21. Wright K, Chaker L, Pacione D, Sam K, Feelders R, Xia Y, Agrawal N. Determinants of Surgical Remission in Prolactinomas: A Systematic Review and Meta-Analysis. *World Neurosurgery.* 2021;154:e349-e369. https://doi.org/10.1016/j.wneu.2021.07.035

Received 28.02.2025
Accepted 30.01.2026