Burdenko's Journal of Neurosurgery
2026, No. 2, pp. 37–42
https://doi.org/10.17116/neiro20269002137

Anatomical basis for a new method of atlas osteosynthesis in unstable C1 vertebral fractures

© V.N. Rashidov[1], I.Yu. Lisitskii[2], A.V. Lychagin[2], R.L. Kambiev[1], K.M. Kulakov[3], A.Yu. Zarov[2], A.L. Korkunov[2], V.G. Cherepanov[2], I.A. Vyazankin[2], E.Yu. Tselischeva[2]

[1]Clinical Hospital Lapino, Odintsovo, Russia;
[2]Sechenov First Moscow State Medical University (Sechenov University), Moscow, Russia;
[3]Mytishchi Regional Clinical Hospital, Mytishchi, Russia

ABSTRACT

Background. Surgical treatment for unstable atlas fractures is still controversial. Harm's atlantoaxial fusion or more extensive occipitospondylodesis reduces quality of life and functional status. Biomechanical rationales for anterior and posterior C1 osteosynthesis are based on small sample, and the role of ligamentous complex in C1-C2 segment remains understudied.

Objective. To evaluate the effectiveness of a new method of surgical treatment for unstable fractures of the first cervical vertebra.

Material and methods. Biomechanical analysis enrolled 10 anatomical specimens. Various injuries of the atlas ring and ligament complex were simulated. The role of apical and cruciate ligaments as additional stabilizers of craniovertebral junction was assessed. Morphometric parameters and anatomical relationships were presented using new surgical method for unstable C1 vertebral fractures and Harm's atlantoaxial fusion as a comparative treatment model.

Results. Instability was observed in all cases of ligamentous complex injury. Rotation angle in atlantoaxial segment remained stable. New surgical method for C1 vertebral injury reduces anterior atlantodental interval to 2.37±0.27 mm, distance between articular surfaces of C1-C2 vertebrae to 3.51±0.46 mm and Redlund-Johnell index to 36.61±1.22 mm without block rotation in atlantoaxial joint.

Conclusion. Original surgical method for unstable C1 fractures is effective when patient selection principles are followed. Preoperative planning and assessment of integrity of craniovertebral ligaments are essential to avoid tactical errors when choosing surgical intervention.

Keywords: *unstable Jefferson fracture, atlas osteosynthesis, atlantoaxial instability, transverse ligament of the atlas.*

INFORMATION ABOUT THE AUTHORS:
Rashidov V.N. – https://orcid.org/0009-0008-7692-2091
Lisitskii I.Yu. – https://orcid.org/0000-0003-2475-6278
Lychagin A.V. – https://orcid.org/0000-0002-2202-8149
Kambiev R.L. – https://orcid.org/0000-0003-3694-4698
Kulakov K.M. – https://orcid.org/0009-0007-5831-7288
Zarov A.Yu. – https://orcid.org/0000-0001-6381-5651
Korkunov A.L. – https://orcid.org/0000-0001-6331-0290
Cherepanov V.G. – https://orcid.org/0000-0003-0797-6383
Vyazankin I.A. – https://orcid.org/0000-0002-8020-2950
Tselischeva E.Yu. – https://orcid.org/0000-0002-1669-3935
Corresponding author: Rashidov V.N. – e-mail: dmrashidov@mail.ru

TO CITE THIS ARTICLE:
Rashidov VN, Lisitskii IYu, Lychagin AV, Kambiev RL, Kulakov KM, Zarov AYu, Korkunov AL, Cherepanov VG, Vyazankin IA, Tselischeva EYu. Anatomical basis for a new method of atlas osteosynthesis in unstable CI vertebra fractures. *Burdenko's Journal of Neurosergery.* 2026; 90(2):37–42. https://doi.org/10.17116/neiro20269002137

Abbreviations

PADI — posterior atlantodental interval
AADI — anterior atlantodental interval
TLA — transverse ligament of the atlas

Introduction

According to data over the last 20 years, the incidence of traumatic injuries of the upper cervical spine is 17 cases per 1 million people [1]. The mechanism of damage to CI vertebra was described in 1919 by G. Jefferson in 4 cases of atlas fracture resulting from axial load passing through occipital condyles and transmitted to CI-CII segments. Without horizontal head tilt, damage to only lateral masses of the atlas

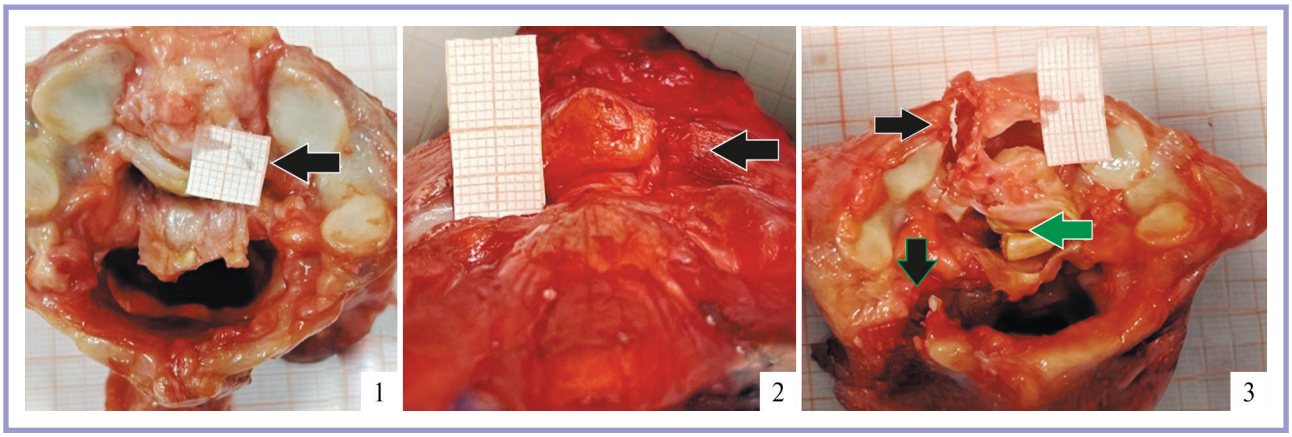

Fig. 1. **Model of unstable two-fragment fracture (Gehweiler classification - IIIb [8], Dickman classification - I [9]).**
1 — specimen demonstrating normal anatomy of transverse ligament of the atlas and C1 bone ring. The arrow indicates the graph paper for assessing anatomical relationships of transverse ligament of the atlas and odontoid process of C2 vertebra; 2 — model of atlas bone ring fracture without damage to ligaments of craniovertebral joint; the arrow indicates fracture line of anterior arch of C1 vertebra; 3 — black arrows — osteotomy zone, green — damage to transverse ligament of the atlas.

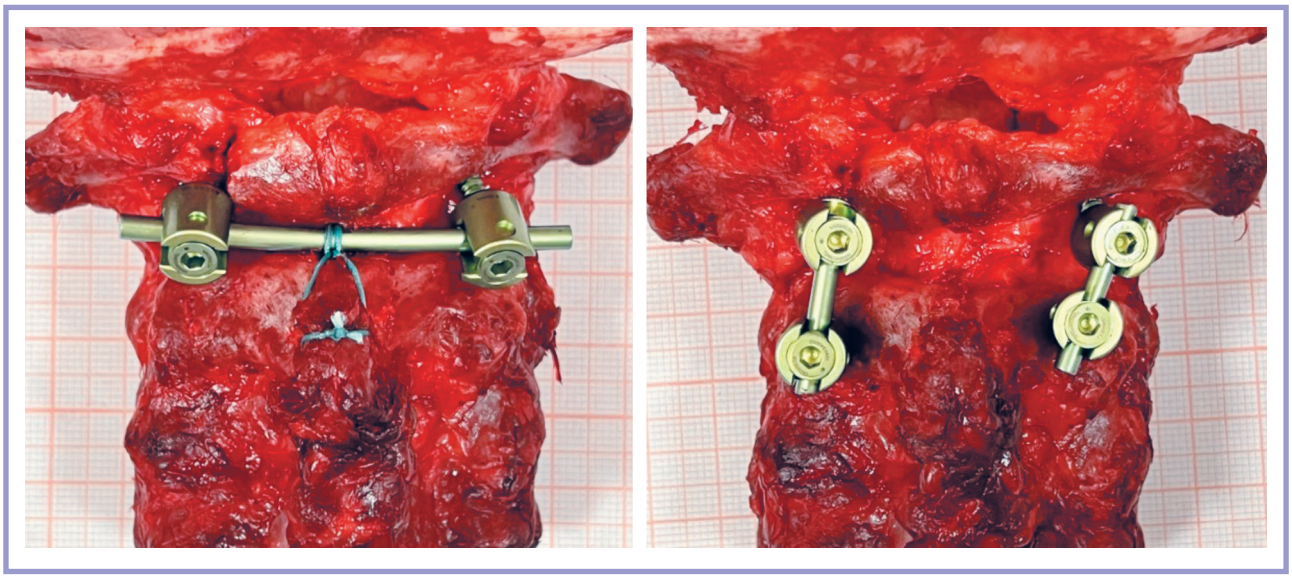

Fig. 2. **Surgical options for C1 unstable fractures.**
On the left — original technique of atlas osteosynthesis with titanium screws (described in the text); on the right — Harms atlantoaxial fusion [10].

occurs, while integrity of atlantooccipital joints is not compromised. Rotation in frontal plane is followed by fracture of anterior or posterior arch [2]. Subsequent studies confirmed the mechanism of injury and provided biomechanical rationale for bone ring damage. Panjabi M.M. used 8 anatomical specimens and determined that 3050 N axial load causes divergence of lateral masses and fracture line on medial surface of the joint [3]. Other studies found that lower force and head tilt were followed by damage to anterior or posterior arch of the atlas [4]. Damage to ligaments of craniovertebral junction is the main factor in verifying pathological mobility. As early as 1908, V. Quercioli emphasized the role of TLA for atlantoaxial instability [5].

The purpose of the study was to evaluate the effectiveness of a new surgical method for unstable fractures of the first cervical vertebra.

Material and methods

Ten specimens were obtained after autopsy of patients who died due to acute cerebrovascular accident or myocardial infarction. There was no previous craniovertebral trauma.

Osteotomy of cranial vault and skull base was performed in medial part of occipital bone. While maintaining vessels, nerves and ligaments, we skeletonized craniovertebral segment between occipital bone and C3 vertebra. Morphometric analysis of anatomical relationships of C0-C2 segment was performed before modeling of traumatic injury of the atlas.

At the first stage, we performed paramedian osteotomy of anterior and posterior arches of the atlas using power equipment. Thus, we created fracture of bone

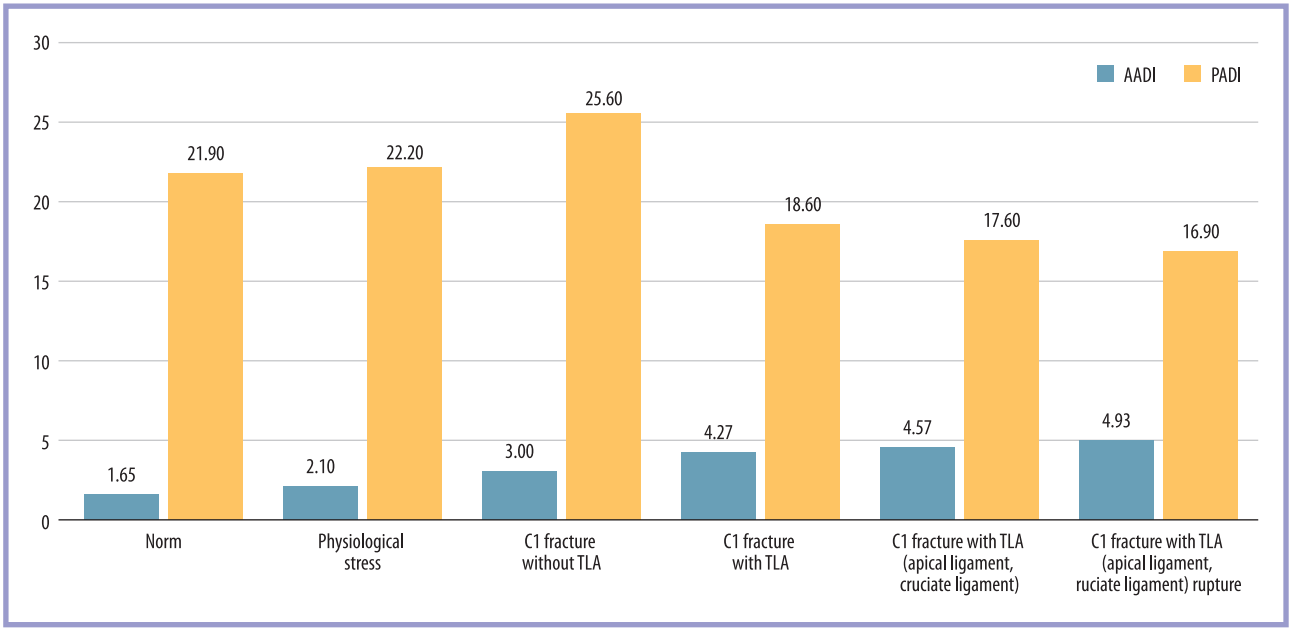

Fig. 3. **Relationship of PADI and AADI changes (mm) with damage to craniovertebral bones and ligaments.**

ring while preserving lateral masses. At the second stage, TLA was dissected. At this stage, atlantoaxial instability was recorded in all specimens. In addition to TLA dissection, apical ligament was damaged, and cruciate ligament was transected after morphometric measurements **(Fig. 1)**. All specimens were exposed to physiological loads. Similar studies on force and cyclic loads on C0-CII segment using cadaveric specimens are presented in the world literature [3, 6—7]. The third stage was original osteosynthesis **(Fig. 2)**. Polyaxial titanium screws 3.5×32 mm were inserted bicortically through lateral masses of C1 vertebra and connected to each other with a rod. We repositioned bone ring fragments through contraction. We performed decortication and formed a canal in medial part of spinous process of C2 vertebra using a high-speed bur. Fixation of rod with arch and spinous process of C2 vertebra was performed using polyethylene terephthalate suture loop.

For comparison with new technique, Harms atlantoaxial fusion [10] was performed at the final stage. Titanium transpedicular screws 3.5×30 mm were inserted through C2 pedicles and lateral masses of the atlas using original technique **(Fig. 2)**.

The relationship between shorter PADI and damage to apical and cruciate ligaments demonstrates additional role of ligaments in CI-CII segment stabilization (PADI=16.94±1.65 mm). AADI increased by 1.35±0.01 mm after fracture. Damage to C0-CII segment ligaments demonstrates greater translation of odontoid process relative to anterior arch of the atlas (up to 4.93±0.69 mm) **(Fig. 3)**.

After modeling of traumatic injury of the atlas, maximum distance between lateral surfaces of atlantoaxial joints (Spence's rule [10]) was 7.64±0.69 mm. No significant difference in lateral mass divergence was observed after additional dissection of apical and cruciate ligaments **(Fig. 4)**.

Analysis of rotational function in CI-CII instability revealed atlas rotation angle increase up to 65.28±0.69°. TLA damage was followed by higher rotation angle in atlantoaxial joints. Under physiological loading, this indicator did not change depending on damage to apical and cruciate ligaments **(Fig. 5)**.

Basilar impression was assessed depending on type of injury. There was no significant difference after osteotomy. TLA damage is essential for compression following odontoid process invagination into foramen magnum and severe neurological deficit. Intersection of apical and cruciate ligaments reflects additional role for odontoid process stabilization in atlas fracture reducing the Redlund-Johnell index to 31.54±0.96 mm **(Fig. 6)**.

Appropriate data demonstrate recovery of morphometric parameters to physiological values after original methods **(Table)**.

Functional outcome of atlantoaxial fusion in comparative model is inferior to less invasive technique reducing rotation angle in this segment to 17.7±1.41°. Divergence of articular surfaces of CI-CII vertebrae, according to Spence's rule, demonstrates impossible aligning bone fragments and formation of bone block after Harms fusion **(Table)**.

Discussion

Treatment of atlas fractures began with immobilization with Halo device followed by introduction of stabilizing systems [12]. External immobilization

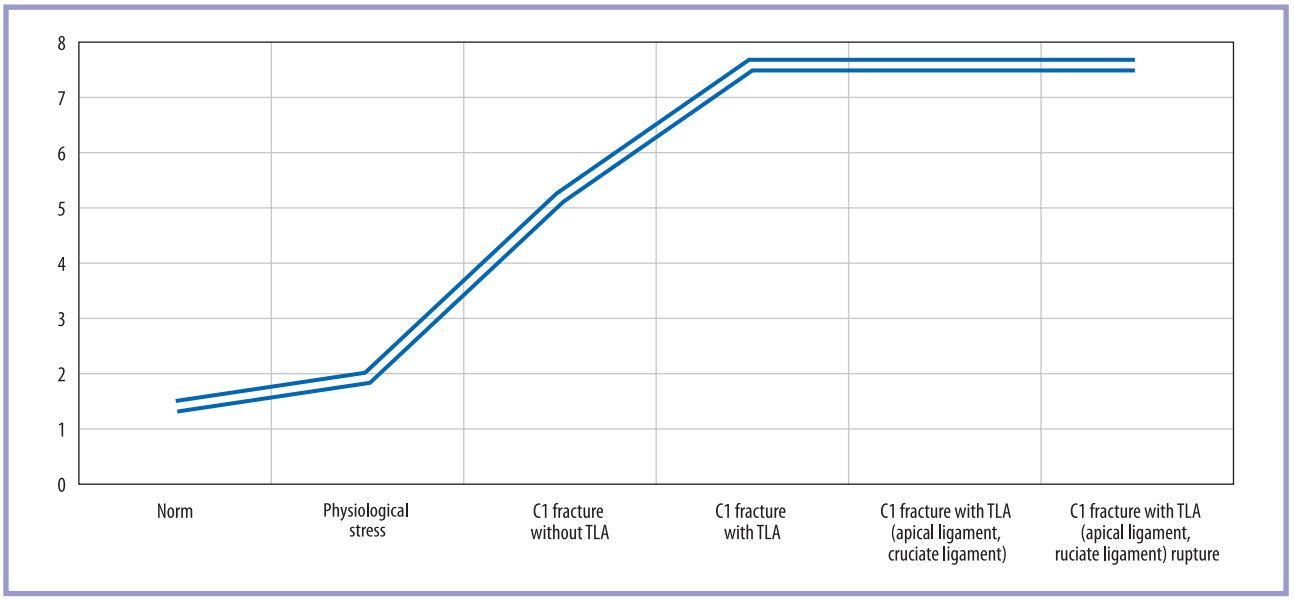

Fig. 4. **Distance between articular surfaces of CI-CII segments (mm) for various injuries.**

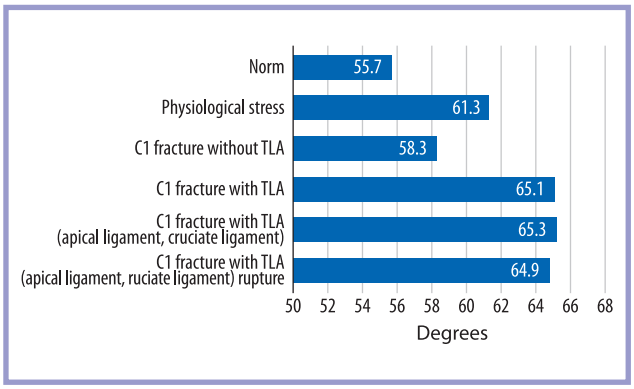

Fig. 5. **Morphometric changes of functional mobility in atlantoaxial joints following unstable CI fracture: C1 rotation angle for different injuries.**

was ineffective and reduced the quality of life in case of pathological mobility [13—14]. Occipitospondylodesis and its variations were the main surgical treatment until the end of the 20th century [15—18]. This approach prevented basilar impression and atlantoaxial joint instability with neurological deficit, but impaired functional outcomes. Reduced cervical spine rotation and high risk of purulent-inflammatory complications due to long surgical wound led to minimization of approaches to the upper cervical segment. Harms J. [10] presented technique with less surgical trauma. However, rotation angle significantly reduced in case of atlantoaxial fusion and impaired the quality of life. Posterior and anterior osteosynthesis of the atlas were developed to preserve rotational function of C0-CII segment [19—25]. Transoral osteosynthesis and repositioning of atlas ring fragments, introduced by M. Ruf [20], ensured physiological mobility. However, metal components can cause damage to posterior pharyngeal wall in follow-up. Posterior C1 osteosynthesis allows for less invasive repositioning while maintaining functional status. Certain authors described pathological mobility and chronic pain syndrome in some patients that necessitated atlantoaxial fusion [26—29].

In our study, we found the relationship between damage to TLA and migration of C1-C2 articular surfaces. This validates previous studies. In addition to TLA, apical and cruciate ligaments are also important for maintaining odontoid process. They create the so-called «buoy effect» [6]. We hypothesize that instability in these cases is caused by damage to additional stabilizers, and atlas osteosynthesis will be insufficient.

Original surgical method for unstable C1 fractures allows for repositioning of bone fragments and C1-C2 segment stability. In comparative model, rotation was 54.29±1.3° for new technique and 17.7±1.41° for atlantoaxial fusion. This highlights the advantages of our technique [30].

Study limitations are small number of specimens and no research of additional stabilizers and surrounding tissues.

Conclusion

This study highlights the role of apical and cruciate ligaments in maintaining atlantoaxial stability. Our experiment demonstrated effectiveness of original technique for correction of atlantoaxial instability. Comparison of surgical methods for Jefferson fractures demonstrates the advantage of new technique in preserving C1-C2 mobility. Original technique may be implemented for unstable C1 fractures.

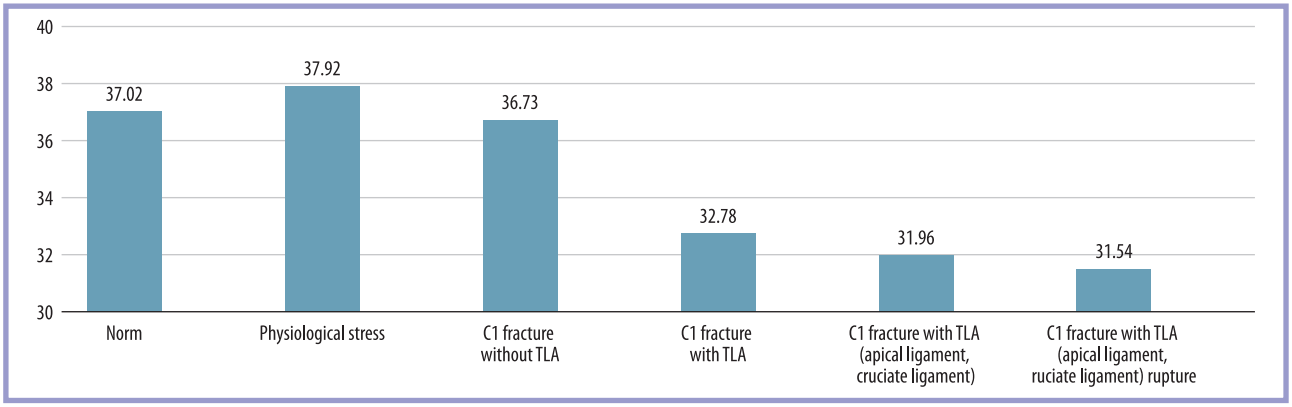

Fig. 6. **The Redlund—Johnell index (distance between the MacGregor line and midpoint of lower edge of CII vertebra) for different injuries.**

Table. **Evaluation of original atlas osteosynthesis and Harms fusion**

Surgical method	Variables				
	PADI, mm	AADI, mm	Distance between articular surfaces of C1-C2 vertebrae, mm	Rotation angle in CI-CII segment, °	Redlund-Johnell index, mm
Norm	1.65±0.25	21.99±1.57	1.4±0.48	55.69±1.98	37.02±1
Original atlas osteosynthesis	2.37±0.27	22.06±1.2	3.51±0.46	54.29±1.3	36.61±1.22
Harms fusion	5.01±0.5	19.56±2.02	7.24±0.31	17.7±1.41	36.93±0.74

Author contribution:
Concept and design of the study — Rashidov V.N., Lisitskiy I.Yu.
Collection and analysis of data — Kulakov K.M., Zarov A.Yu., Korkunov A.L., Cherepanov V.G., Vyazankin I.A., Tselishcheva E.Yu.
Statistical analysis — Rashidov V.N., Kulakov K.M.
Writing — Rashidov V.N.
Editing — Lisitskiy I.Yu., Lychagin A.V., Kambiev R.L.

The authors declare no conflicts of interests.

REFERENCES

1. Kim D, Viswanathan VK, Munakomi S, Menger RP. C1 Fractures. 2024. In: StatPearls [Internet]. Treasure Island (FL): StatPearls Publishing; 2025.
2. Jefferson G. Fracture of the atlas vertebra. Report of four cases, and a review of those previously recorded. *British Journal of Surgery*. 1919;7(27):407-422. https://doi.org/10.1002/bjs.1800072713
3. Oda T, Panjabi MM, Crisco JJ 3rd, Oxland TR, Katz L, Nolte LP. Experimental study of atlas injuries. II. Relevance to clinical diagnosis and treatment. *Spine*. 1991;16(10):S466-473. https://doi.org/10.1097/00007632-199110001-00002
4. Shin JJ, Kim KR, Shin J, Kang J, Lee HJ, Kim TW, Hong JT, Kim SW, Ha Y. Surgical Versus Conservative Management for Treating Unstable Atlas Fractures: A Multicenter Study. *Neurospine*. 2022;19(4):1013-1025. https://doi.org/10.14245/ns.2244352.176
5. Domenicucci M, Dugoni DE, Mancarella C, D'Elia A, Missori P. Vincenzo Quercioli (1876—1939), researcher and pioneer of the atlas fracture. *Journal of Neurosurgery: Spine*. 2015;22(3):253-258. https://doi.org/10.3171/2014.11.SPINE14483
6. Koller H, Resch H, Tauber M, Zenner J, Augat P, Penzkofer R, Acosta F, Kolb K, Kathrein A, Hitzl W. A biomechanical rationale for C1-ring osteosynthesis as treatment for displaced Jefferson burst fractures with incompetency of the transverse atlantal ligament. *European Spine Journal*. 2010;19(8):1288-1298. https://doi.org/10.1007/s00586-010-1380-3
7. Arena JD, Ghenbot Y, Tomlinson SB, Wathen CA, Schneider ALC, Chen HI, Ali ZS, Schuster JM, Petrov D. Navigated Osteosynthesis for Unstable Atlas Fractures: Technical Note and Case Series. *World Neurosurgery*. 2025;194:123524. https://doi.org/10.1016/j.wneu.2024.11.107
8. Gehweiler JA, Duff DE, Martinez S, Miller MD, Clark WM. Fractures of the atlas vertebra. *Skeletal Radiology*. 1976;1:97-102. https://doi.org/10.1007/BF00347414
9. Dickman CA, Greene KA, Sonntag VK. Injuries involving the transverse atlantal ligament: classification and treatment guidelines based upon experience with 39 injuries. *Neurosurgery*. 1996;38(1):44-50. https://doi.org/10.1097/00006123-199601000-00012
10. Harms J, Melcher RP. Posterior C1—C2 fusion with polyaxial screw and rod fixation. *Spine*. 2001;26(22):2467-2471. https://doi.org/10.1097/00007632-200111150-00014
11. Spence KF Jr, Decker S, Sell KW. Bursting atlantal fracture associated with rupture of the transverse ligament. *The Journal of Bone & Joint Surgery*. 1970;52(3):543-549.
12. Mohile NV, Kuczmarski AS, Minaie A, Syros A, Geller JS, Maaieh MA. Management of combined atlas and axis fractures: a systematic review. *North American Spine Society Journal*. 2023;14:100224. https://doi.org/10.1016/j.xnsj.2023.100224
13. Denton H, McDonnell JM, Curran J, Wilson K, Temperley H, Cunniffe G, Morris S, Darwish S, Butler JS. Isolated C1 arch fractures: C1-2 fusion vs. C1 osteosynthesis — surgical strategies for potentially unstable injuries. *European Spine Journal*. 2024;33(10):3904-3914. https://doi.org/10.1007/s00586-024-08460-x
14. Dong WX, Chu ZT, Hu Y. Treatment of unstable C1 semi-ring fractures with direct C1 pedicle screw fixation using a navigational template: A case report and literature review. *Medicine*. 2023;102(20):e33800. https://doi.org/10.1097/MD.0000000000033800

15. Yan L, Du J, Yang J, He B, Hao D, Zheng B, Yang X, Hui H, Liu T, Wang X, Guo H, Chen J, Wang S, Ma S, Dong S. C1-ring osteosynthesis versus C1-2 fixation fusion in the treatment of unstable atlas fractures: a multicenter, prospective, randomized controlled study with 5-year follow-up. *Journal of Neurosurgery: Spine*. 2022;37(2):157-165. https://doi.org/10.3171/2021.12.SPINE211063

16. Zou X, Yang H, Deng C, Chen J, Ma R, Ma X, Xia H. Management of Unstable C1 Fractures Involving the Lateral Mass: Posterior C1—C2 Screw-Rod Fixation and Fusion. *Medical Science Monitor*. 2023;29:e938600. https://doi.org/10.12659/MSM.938600

17. Eun J, Oh Y. Traumatic lateral atlantoaxial dislocation combined with a type II odontoid fracture in a patient with ankylosing spondylitis: A case report. *Medicine*. 2022;101(40):e30912. https://doi.org/10.1097/MD.0000000000030912

18. Yang K, Niu HG, Tao H, Liu C, Cao Y, Li W, Zhang JJ, Shen CL, Zhang YS. Posterior osteosynthesis with a new self-designed lateral mass screw-plate system for unstable atlas burst fractures. *BMC Musculoskeletal Disorders*. 2023;24(1):108. https://doi.org/10.1186/s12891-023-06209-z

19. Lisitsky IYu, Rashidov VN, Lychagin AV, Zarov AYu, Korkunov AL, Cherepanov VG, Vyazankin IA, Tselishcheva EYu. Original surgical technique of unstable atlas fracture osteosynthesis: case series analysis. *Russian Journal of Spine Surgery (Khirurgiya Pozvonochnika)*. 2025;22(1):53-61. (In Russ.). https://doi.org/10.14531/ss2025.1.53-61

20. Ruf M, Melcher R, Harms J. Transoral reduction and osteosynthesis C1 as a function-preserving option in the treatment of unstable Jefferson fractures. *Spine*. 2004;29(7):823-827. https://doi.org/10.1097/01.brs.0000116984.42466.7e

21. Niu HG, Zhao CK, Yang K, Tao H, Liu C, Zhang JJ, Shen CL, Zhang YS. Monoaxial Screws Versus Polyaxial Screws Osteosynthesis for Unstable Atlas Fractures: A Retrospective, Comparative Study With a Minimum Follow-Up of 3 years. *Global Spine Journal*. 2025;15(1):31-40. https://doi.org/10.1177/21925682241247489

22. Montemurro N, Carnesecchi S, Morganti R, De Carlo A, Cocciaro A. Surgical Outcomes of Craniocervical Junction Fractures in Elderly Patients: A Retrospective Single-Center Series. *Journal of Personalized Medicine*. 2025;15(10):485. https://doi.org/10.3390/jpm15100485

23. Ishihama Y, Ikeda T, Iemura S, Toriumi K, Goto K. Spontaneous Anterior Arch Fracture of the Atlas Following C1 Laminectomy in a Patient With Osteopetrosis: A Case With Five Years of Follow-Up. *Cureus*. 2025;17(2):e79471. https://doi.org/10.7759/cureus.79471

24. Kawasaki T, Takayama M, Maki Y, Nakajima K, Kobayashi T, Saiki M, Ioroi Y. A case of anterior arch fracture of the atlas associated with C1 laminectomy. *Surgical Neurology International*. 2023;14:136. https://doi.org/10.25259/SNI_254_2023

25. Palmieri G, Cofano F, Marengo N, Ajello M, Zenga F, Garbossa D. Posterior arch reconstruction in cervical surgery to restore the global biomechanics of the Atlas: a technical note. *British Journal of Neurosurgery*. 2023;37(5):1402-1405. https://doi.org/10.1080/02688697.2021.1881042

26. Liawrungrueang W, Laohapoonrungsee A, Bunmaprasert T. Acute traumatic lateral atlantoaxial dislocation associated with locked atlas lateral mass and odontoid process fracture: A clinical case study and literature review. *North American Spine Society Journal*. 2022;12:100169. https://doi.org/10.1016/j.xnsj.2022.100169

27. Shin JJ, Kim KR, Shin J, Kang J, Lee HJ, Kim TW, Hong JT, Kim SW, Ha Y. Surgical Versus Conservative Management for Treating Unstable Atlas Fractures: A Multicenter Study. *Neurospine*. 2022;19(4):1013-1025. https://doi.org/10.14245/ns.2244352.176

28. Shin JW, Suk KS, Kim HS, Yang JH, Kwon JW, Lee HM, Moon SH, Lee BH, Park SJ, Park SR, Kim SK. Direct Internal Fixation for Unstable Atlas Fractures. *Yonsei Medical Journal*. 2022;63(3):265-271. https://doi.org/10.3349/ymj.2022.63.3.265

29. Cai M, Wu Y, Ma R, Chen J, Chen Z, Deng C, Huang X, Ma X, Zou X. Comparison of Transoral Anterior Jefferson-Fracture Reduction Plate and Posterior Screw-Rod Fixation in C1-Ring Osteosynthesis for Unstable Atlas Fractures. *Neurospine*. 2024;21(2):544-554. https://doi.org/10.14245/ns.2347230.615

30. Lisitskiy IYu, Rashidov VN, Lychagin AV. *Method for surgical treatment of isolated unstable fractures of the first cervical vertebra*. Russian Federation Patent No. 2835893, Mar 5, 2025. Bulletin No. 7. (In Russ.).

Received 26.10.2025
Accepted 26.11.2025