Burdenko's Journal of Neurosurgery
2026, No. 2, pp. 29–34
https://doi.org/10.17116/neiro20269002129

Biopsy in the treatment of children with diffuse brainstem tumors

© S.S. Ozerov[1], A.L. Levov[1], A.N. Kislyakov[1], D.A. Skobeev[1], M.A. Kolcheva[1], V.N. Umerenkov[1], M.I. Livshits[1], G.E. Chmutin[2], E.V. Kumirova[3], V.V. Gorev[1]

[1]Morozovskaya Children's Clinical Hospital, Moscow, Russia;
[2]Peoples' Friendship University of Russia, Moscow, Russia;
[3]Pirogov Russian National Research Medical University, Moscow, Russia.

ABSTRACT

Background. Diffuse brainstem tumors account for 10—20% of all brain tumors in children. These neoplasms are the leading cause of death in pediatric neuro-oncology. There are no effective treatments for this disease. Overall survival rarely exceeds 1.5—2 years.

Objective. Biopsy of diffuse brainstem tumors to determine their histological type and molecular genetic markers; to identify potential targets for targeted therapy.

Material and methods. In 2021—2025, 26 patients with diffuse brainstem tumors underwent surgery at the Morozovskaya Children's Clinical Hospital. Age of patients was 1.5—17 years, duration of disease — from 1 week to 13 months. There was primary tumor in 96% of cases. Preliminary diagnosis was based on clinical presentation and MRI. Stereotactic biopsy using BrainLab neuronavigator via transcerebellar approach was performed in 24 patients, open biopsy — in 2 cases.

Results. The tumor was verified in 24 (92%) patients. Brain tissue was obtained from two patients. According to morphological data, 80% of patients had diffuse midline glioma. Ganglioglioma was detected in one case, high–grade glioma in one case, and low-grade glioma in one case. All patients underwent immunohistochemical examination of specimen, and 58% were examined using the NGS program. The *H3K27M* mutation was detected in 71% of cases, *BRAF-V600E* mutations in 2 patients, and *FGFR2* gene mutation in 1 patient. Targeted therapy was based on information about mutations. The overall 2-year survival rate was 20%, event-free 2-year survival — 0%. Event–free survival of a patient with the *BRAF-V600E* mutation who received targeted therapy was 21 months.

Conclusion. Stereotactic biopsy of diffuse brainstem tumors can be performed safely. Identification of targets for personalized therapy may be essential for management of these patients.

Keywords: *pediatric brain tumors, brainstem tumor, DIPG, STB, targeted therapy.*

INFORMATION ABOUT THE AUTHORS:
Ozerov S.S. — https://orcid.org/0000-0001-7891-402X
Levov A.L. — https://orcid.org/0000-0003-3035-9375
Kislyakov A.N. — https://orcid.org/0000-0001-8735-4909
Skobeev D.A. — https://orcid.org/0000-0001-6446-9201
Kolcheva M.A. — https://orcid.org/0000-0001-6460-5234
Umerenkov V.N. – https://orcid.org/0000-0001-7821-0997
Livshits M.I. — https://orcid.org/0000-0001-7010-0101
Chmutin G.E. — https://orcid.org/0000-0002-3323-508X
Kumirova E.V. — https://orcid.org/0000-0001-6125-2410
Gorev V.V. — https://orcid.org/0000-0001-8272-3648
Corresponding author: Ozerov S.S. — e-mail: gagara3@yandex.ru

TO CITE THIS ARTICLE:
Ozerov SS, Levov AL, Kislyakov AN, Skobeev DA, Kolcheva MA, Umerenkov VN, Livshits MI, Chmutin GE, Kumirova EV, Gorev VV. Biopsy in the treatment of children with diffuse brainstem tumors. *Burdenko's Journal of Neurosurgery*. 2026;90(2):29–34. (In Russ.).
https://doi.org/10.17116/neiro20269002129

Introduction

Diffuse intrinsic pontine gliomas (DIPGs) account for 10—20% of all brain tumors in children. These are ones of the most common causes of death in pediatric neuro-oncology [1]. In 1910, Harvey Cushing first mentioned these tumors. He described a 15-year-old girl with nausea and vomiting, convergent strabismus, peripheral facial nerve palsy and pyramidal symptoms. Surgeon suspected cerebellar tumor and performed exploration of posterior cranial fossa. Despite wide occipital craniotomy and several attempts of encephalotomy of cerebellar hemispheres, the tumor could not be found. A suspected location in pons was suggested, and surgery was completed. Comatose status of the patient was followed by death several days later. Autopsy confirmed pontine tumor. This ended «major surgery» for patients with diffuse intrinsic pontine gliomas [2, 3].

Currently, diagnosis of DIPG is based on MRI data. Local radiotherapy somewhat slows progression of disease. If hydrocephalus develops, bypass surgery is performed. Chemotherapy is not followed by better outcomes. However, temozolomide monotherapy is still prescribed in some cases. Two-year overall survival does not exceed 10—20% [1, 3, 4].

The role of biopsy in the treatment of patients with DIPG has remained controversial for the past thirty years. In the 1970s and 1980s, this procedure was widely used in children and adults [5]. However, histological type of tumor did not affect prognosis. In 1993, Albright A.L. et al. published a Children's Cancer Group study. The main conclusion was thesis that «magnetic resonance imaging provides images completely diagnosing pontine gliomas and providing prognostic information equivalent to biopsy» [6]. Biopsy was indicated only for atypical and unclear cases. It was also proposed to return to biopsy if its results would somehow allow for modification of therapy and influence prognosis of disease [3, 7, 8].

Understanding the biology of DIPG has advanced significantly in recent years. It has become clear that in most cases they are classified as diffuse midline gliomas (DMG). About 80% of these tumors carry a mutation in histone 3 (substitution of lysine 27 to methionine). In the 2016 and 2021 WHO classification of CNS tumors, DMGs are classified into a special class (midline diffuse H3 K27M-mutant gliomas) [1, 9, 10].

In large-scale hospitals, biopsies of these tumors are usually performed to enroll patients in clinical trials, as numerous new targeted drugs have emerged in recent years with perspective results in blood cancers and solid tumors. Thus, researches of DIPG biology are largely focused on feasibility of targeted therapy [7, 11, 12].

Currently, the study devoted to selection of DIPG patients for targeted therapy is being conducted at the Morozov Children's Clinical Hospital.

The purpose of the study was DIPG biopsy to determine its histological variant and molecular genetic markers, as well as identification of potential targets for therapy.

Material and methods

Between October 2021 and March 2025, all patients with DIPG confirmed by contrast-enhanced MRI underwent stereotactic or open biopsy of tumor. Biopsy was performed regardless of whether the tumor appeared typical DIPG or not. We examined tissue samples using conventional histological and immunohistochemical methods, as well as comprehensive genomic profiling (Next Generation Sequencing (NGS) panel, Roche Diagnostics, Switzerland) to identify molecular alterations and indications for targeted therapy. All patients underwent standard radiotherapy (local or craniospinal depending on tumor extent). Candidates for targeted therapy were selected considering NGS data.

Biopsy technique

Open biopsy was performed for lateral tumor spread into cerebellar hemisphere for tissue sampling at the maximum distance from the brainstem, as well as at the patient's relatives' request. Stereotactic biopsy was performed using a Brainlab neuronavigator (Germany). In navigation system, we planned suboccipital lateral approach to the pons through the middle cerebellar peduncle on the side of the largest lesion **(Fig. 1)**. Surgery was carried out in patient prone position with head fixed in Mayfield clamp. Frameless stereotactic biopsy was performed using VarioGuide system (Brainlab AG, Munich, Germany).

Results

Twenty-six patients (12 boys, 14 girls) aged 1.5—17 years (median 8 years) underwent surgery. Anamnesis of disease ranged from 1 week to 13 months (median 1 month). Brainstem tumor was primary in 96% of cases (25 patients). In one patient (4%), the neoplasm developed 3 years after therapy for acute lymphoblastic leukemia.

Stereotactic and open biopsy was performed in 24 and 2 patients, respectively. In two patients, stereotactic biopsy was performed twice because the first biopsy was inconclusive.

Ventriculoperitoneostomy was performed in 6 cases.

All patients underwent CT within 24 hours to detect postoperative complications and control biopsy trajectory. There were no postoperative complications.

Biopsy was informative in 92% of cases. Brain tissue was harvested in 2 (8%) cases. Spinal cord MRI was performed in 73% of patients. Metastases were detected in 3 (16%) patients.

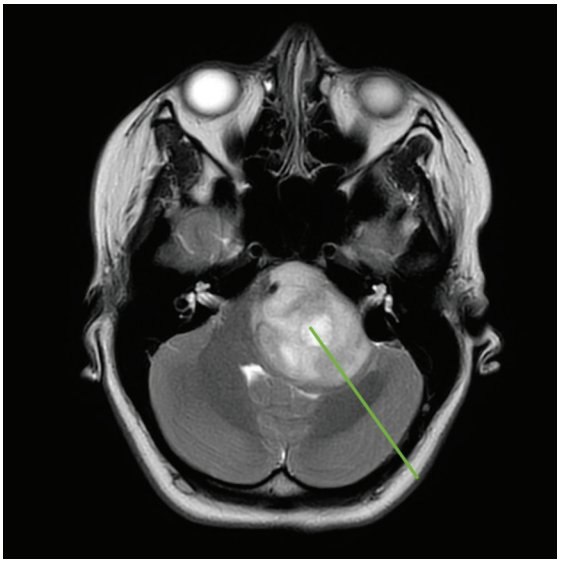

Fig. 1. **Scheme of transcerebellar biopsy trajectory (green) through the middle cerebellar peduncle.**

Table 1. **Mutations in tumors.**

Mutation	Number, *n*
H3K27M	17
BRAF-V600E	2
FGFR2	1
TP53	6
PIC3CA	3
PTEN	2
PDGFRA	2
RICTOR	1
MYCN amplification	1
BCL2L2 amplification	1
CDK4 amplification	1
CDKN2C	1
KIT	1
MUTYH R231H	1
PALB2	1
ASXL1	1
ROS1	1
TERT	1
PIC3R1	1

Histological and molecular genetic data

Morphological analysis revealed DMG in 21 (80%) patients. One case was diagnosed with ganglioglioma, one — igh-grade glioma, one — low-grade glioma.

All patients underwent immunohistochemistry of specimens.

Fourteen (58%) tumor tissue samples were scheduled for NGS analysis. DNA methylation was performed in one case at the Burdenko Neurosurgery Center.

The H3K27M mutation was detected in 17 (71%) patients, BRAF-V600E mutations — in 2 patients (1 with DMG, 1 with ganglioglioma). The FGFR2 gene mutation was detected in 1 patient. All mutations are presented in **Table 1**.

Thus, 3 patients had therapeutically significant mutations (two BRAF-600E mutations and one FGFR2 mutation) scheduled for targeted therapy.

Postoperative therapy

Data on radiotherapy are available for 23 (88%) patients. Of these, local irradiation was administered in 19 (90%) patients, craniospinal irradiation — 1 (5%), craniospinal irradiation with boost to the site of thoracic spine metastasis — 1 (5%). Radiotherapy was not administered in two patients (brain tissue after biopsy in 1 patient and ganglioglioma without indications for radiotherapy in another case).

Chemotherapy concurrently with radiotherapy was administered in 8 (35%) patients (temozolomide in 7 cases and valproic acid in 1 case). Postoperative chemotherapy was prescribed to 7 patients **(Table 2)**.

Table 2. **Patient and therapy characteristics.**

Variable	Number of patients, *n* (%)
Boys	12 (46)
Girls	14 (54)
Primary tumor	25 (96)
Secondary tumor (after acute lymphoblastic leukemia)	1 (4)
Stereotactic biopsy	24 (92)
Open biopsy	2 (8)
Ventriculoperitoneal shunting	6 (23)
Mortality	0 (0)
Complications	0 (0)
Spinal cord lesion	3 (16) (from all examined patients)
Radiotherapy	23 (88)
Local	19 (90) (from all irradiated patients)
Craniospinal irradiation	1 (5)
Craniospinal irradiation + boost	1 (5)
Chemotherapy in parallel with radiotherapy	8 (35) (from all irradiated patients)
Temozolomide	7 (30.5)
Valproic acid	1 (4.5)
Chemotherapy after radiotherapy	7 (30) (from all patients)
Temozolomide	3 (12)
Temozolomide, then bevacizumab + irinotecan	1 (4.5)
Temozolomide + bevacizumab	1 (4.5)
Vinblastine	1 (4.5)
Vinblastine + bevacizumab	1 (4.5)
Targeted therapy	3 (11.5)

Three patients underwent target therapy after tumor biopsy (2 patients — dabrafenib and trametinib, one patient – erdafitinib) **(Table 2)**.

Survival

Overall 2-year survival rate in the entire group was 20% **(Fig. 2)**.

Disease-free 2-year survival rate was 0% **(Fig. 3)**.

The median of disease-free survival was 7 months. Disease-free survival of a patient with DMG and BRAF-V600E mutation who received targeted therapy (dabrafenib, trametinib) was 21 months, and tumor progression occurred after this period. Patients with ganglioglioma and BRAF-V600E mutation, as well as DMG and FGFR2 mutation are also receiving targeted therapy. However, treatment has been recently initiated, and it is too early to assess the results.

Discussion

The role of biopsy in diagnosis and treatment of children with DIPG is actively debated. Most of these

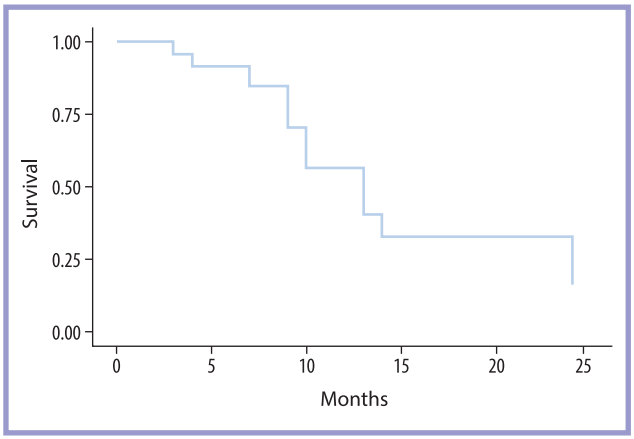

Fig. 2. **Overall survival.**

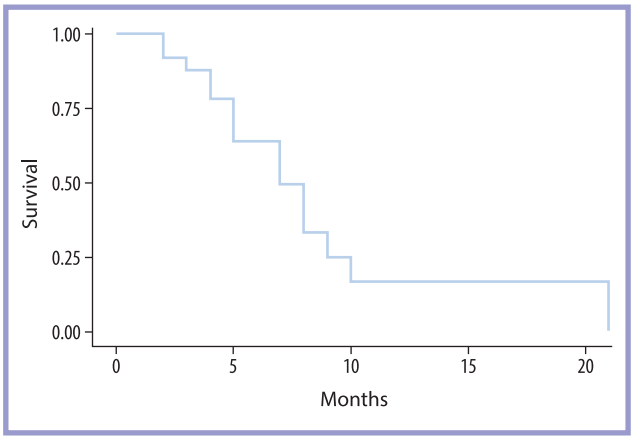

Fig. 3. **Disease-free survival.**

tumors are H3K27M-mutated DMG, and prognosis is inevitably poor for all patients. Median survival hovers around 12 months and has not improved in recent decades. A new class of targeted drugs offers hope for changes in the treatment of these patients. Therefore, there has been a renaissance of interest in DIPG biopsies in recent years to identify patients who may benefit from new drugs. This raises several questions:

— How safe are brainstem tumor biopsies?
— What information can we obtain after biopsy?
— How can biopsy results be used?

Safety of biopsy

One of the largest meta-analyses on DIPG biopsy in children reviews 29 samples of patients (1.002 patients) over 20 years (2003—2023) [8]. Of these, 87% ones underwent stereotactic biopsy, 12.7% — open biopsy, 0.3% — endoscopic biopsy. Efficacy of biopsy was 96.8%. Transient complications occurred in 6% of patients, irreversible complications (cranial nerve damage, hemiparesis) — in 1% of patients. The mortality rate was 0.5%.

Thus, biopsy of diffuse pontine tumors is a relatively safe and effective procedure in specialized centers as evidenced by our data.

Results of biopsy

Comparison of biopsy results is significantly more difficult. Indeed, specimens were analyzed using different protocols at different clinics. Tumor classification has changed over a long period. Thus, morphological findings from different years and different laboratories are not fully comparable. Different approaches to selecting surgical candidates are also significant. In some clinics, all DIPG patients were candidates for biopsy, while in others surgery was primarily performed in complex and atypical cases. Results of several recent series of DIPG biopsies in children are presented in **Table 3**.

The majority of tumors are DMG (often H3K27M-mutant). In some cases, identification of molecular mutations allowed target therapy.

Targeted and personalized therapy

Although clinical trials on targeted therapy in the treatment of patients with DIPG have been ongoing for over 15 years, there are no results of large-scale studies devoted to pontine tumor biopsy data to prescribe personalized treatment. There are only several samples with different numbers of patients. For example, Pfaff E. et al. [14] (INFORM Study) described selection and administration of targeted therapy, but did not provide treatment outcomes. Del Baldo G. et al. [12] reported 19.8% two-year overall survival among 25 patients including 9 ones who received target therapy. Median survival in the group of personalized treatment was 20.26 months, without targeted therapy — 14.18 months. Differences are significant, although they do not exceed average statistical values. Gojo J. et al. [17] reported 7 patients with verified DIPG who received different targeted therapy regimens according to molecular genetic markers. Median overall survival in the personalized treatment cohort was 16.5 months, in the control group — 17.5 months. No significant differences were found between cohorts, but long-lived patients (>2 years) were present only in the personalized treatment cohort.

Between 2014 and 2019, Grill J. et al. [18] included 233 patients with verified DIPG (BIOMEDE trial) to compare three targeted agents (erlotinib, everolimus, and dasatinib) in combination with radiotherapy (54 Gy). The median follow-up was 5.3 years. Overall survival after randomization was 9.0, 11.3 and 9.4 months for erlotinib, everolimus and dasatinib, respectively (p=0.45). Overall survival rates did not differ from those in historical biopsy-confirmed cohort.

Thus, efficacy of targeted therapy for DIPG has not yet been proven. This situation is not unique

Table 3. **Histological and molecular features of DIPG specimens.**

Authors, year (study period)	Number of patients	Histological data, %	Mutations for targeted therapy
S. Puget et al., 2015 (2002—2015) [13]	130	Glioma: WHO grade II — 30.5 WHO grade III — 39 WHO grade IV — 30.5	Targeted mutations were not studied; tumor malignancy grade did not affect patient survival
E. Pfaff et al. (INFORM study), 2019 (2015—2018) [14]	21	DMG — 90	5 mutations suitable for targeted therapy: 2 patients with PDGFRA mutation (dasatinib, sorafenib); 1 patient with PIC3CA mutation (everolimus); 1 patient with KRAS amplification (trametinib, cetuximab); 1 patient with PDGFRA+MET fusion mutation (crizotinib, dasatinib)
M. Wang et al., 2022 (2016—2021) [15]	71	DMG — 100 *H3K27M*-mutant — 84 wild-type — 16	No data on target mutations were presented
G. Del Baldo et al., 2022 (2014—2019) [12]	25	DMG — 100	5 patients — mTOR/p-mTOR (everolimus); 2 patients — ACVR1 (palovarotene); 1 patient — BRAF V600E+mTOR/p-mTOR (everolimus, vemurafenib); 1 patient — PDGFRA (pazopanib)
A. Früh et al., 2023 (2009—2022) (biopsy was preferred for patients with atypical tumors) [16]	27	DMG — 65 Pilocytic astrocytoma WHO grade I — 15 Diffuse astrocytoma WHO grade II — 7 Anaplastic astrocytoma WHO grade IV — 7 Glioblastoma WHO grade IV — 3 Atypical teratoid rhabdoid tumor — 3	No data on target mutations were presented
J. Gojo et al., 2020 (2015—2018) [17]	7 (DIPG)	DMG — 100	3 patients — PIC3CA (miltefosine or everolimus); 1 patient — ACVR1 (palovarotene); 1 patient — TMB (nivolumab); 1 patient — FGFR3 (pazopanib); 1 patient — PDGFRA (pazopanib)

to DIPG but applies to neurooncology at al. To date, targeted therapy has demonstrated therapeutic value only in a certain segment of benign gliomas [19—22]. It is not yet widely used in other major groups of CNS tumors (glioblastomas, medulloblastomas, ependymomas, meningiomas, etc.).

Nevertheless, traditional treatments for brain and spinal cord malignancies, such as surgery, radio- and chemotherapy, have virtually exhausted their potential. Personalized therapy is a rapidly developing area of oncology, and dozens of studies on targeted and immune therapy are being currently performed [7, 10, 12, 23, 24].

Conclusion

Modern data confirm that brainstem biopsy is relatively safe. Diffuse pontine tumors are molecularly heterogeneous diseases, and a shift to molecularly targeted trials is necessary to improve treatment outcomes. Further research will be aimed at improving survival rates when treating specific molecular targets and developing less invasive methods for obtaining molecular profiles that could eliminate the need for tissue sampling.

Author contribution:
Concept and design of the study — Ozerov S.S., Kumirova E.V., Gorev V.V.
Collection and analysis of data — Ozerov S.S., Levov A.V., Umerenkov V.N., Kislyakov A.N., Skobeev D.A.
Statistical analysis — Ozerov S.S., Kolcheva M.A.
Writing the text — Ozerov S.S., Kumirova E.V.
Editing — Kumirova E.V., Chmutin G.E., Livshits M.I.

The authors declare no conflicts of interests.

REFERENCES

1. Ozerov SS, Ryzhova MV, Kumirova EV. Diffuse brainstem tumors in children. Tumor biology and hope for a better outcome. Current state of the problem. *Burdenko's Journal of Neurosurgery.* 2021;85(4):77-86. (In Russ.). https://doi.org/10.17116/neiro20218504177
2. Dmetrichuk JM, Pendleton C, Jallo GI, Quiñones-Hinojosa A. Father of neurosurgery: Harvey Cushing's early experience with a pediatric brainstem glioma at the Johns Hopkins Hospital. *Journal of Neurosurgery: Pediatrics.* 2011;8(4):337-341. https://doi.org/10.3171/2011.7.PEDS11101

3. Tosi U, Souweidane M. Fifty years of DIPG: looking at the future with hope. *Child's Nervous System*. 2023;39(10):2675-2686. https://doi.org/10.1007/s00381-023-06037-5
4. Vanan MI, Eisenstat DD. DIPG in Children — What Can We Learn from the Past? *Frontiers in Oncology*. 2015;5:237. https://doi.org/10.3389/fonc.2015.00237
5. Hersh DS, Kumar R, Moore KA, Smith LGF, Tinkle CL, Chiang J, Patay Z, Gajjar A, Choudhri AF, Lee-Diaz JA, Vaughn B, Klimo P. Safety and efficacy of brainstem biopsy in children and young adults. *Journal of Neurosurgery: Pediatrics*. 2020;26(5):552-562. https://doi.org/10.3171/2020.4.PEDS2092
6. Albright AL, Packer RJ, Zimmerman R, Rorke LB, Boyett J, Hammond GD. Magnetic resonance scans should replace biopsies for the diagnosis of diffuse brain stem gliomas: a report from the Children's Cancer Group. *Neurosurgery*. 1993;33(6):1026-1029; discussion 1029-1030. https://doi.org/10.1227/00006123-199312000-00010
7. Di Ruscio V, Del Baldo G, Fabozzi F, Vinci M, Cacchione A, de Billy E, Megaro G, Carai A, Mastronuzzi A. Pediatric Diffuse Midline Gliomas: An Unfinished Puzzle. *Diagnostics*. 2022;12(9):2064. https://doi.org/10.3390/diagnostics12092064
8. Sheikh SR, Patel NJ, Recinos VMR. Safety and Technical Efficacy of Pediatric Brainstem Biopsies: An Updated Meta-Analysis of 1000+ Children. *World Neurosurgery*. 2024;189:428-438.e2. https://doi.org/10.1016/j.wneu.2024.06.163
9. Tosi U, Souweidane M. Diffuse Midline Gliomas: Challenges and New Strategies in a Changing Clinical Landscape. *Cancers*. 2024;16(1):219. https://doi.org/10.3390/cancers16010219
10. Sheikh SR, Recinos VMR, Thompson EM, Mangum R, Wright-Nadkarni M, Gampel B, Patel NJ. The role of brainstem biopsy and targeted therapies in pediatric diffuse midline glioma/diffuse intrinsic pontine glioma. *Frontiers in Oncology*. 2024;14:1504440. https://doi.org/10.3389/fonc.2024.1504440
11. Lo Greco MC, Marano G, La Rocca M, Acquaviva G, Milazzotto R, Liardo RLE, Basile A, Foti PV, Palmucci S, David E, Parisi S, Pontoriero A, Pergolizzi S, Spatola C. Latest Advancements in the Management of H3K27M-Mutant Diffuse Intrinsic Pontine Glioma: A Narrative Review. *Cancers*. 2025;17(3):420. https://doi.org/10.3390/cancers17030420
12. Del Baldo G, Carai A, Abbas R, Cacchione A, Vinci M, Di Ruscio V, Colafati GS, Rossi S, Diomedi Camassei F, Maestro N, Temelso S, Pericoli G, De Billy E, Giovannoni I, Carboni A, Rinelli M, Agolini E, Mackay A, Jones C, Chiesa S, Balducci M, Locatelli F, Mastronuzzi A. Targeted therapy for pediatric diffuse intrinsic pontine glioma: a single-center experience. *Therapeutic Advances in Medical Oncology*. 2022;14:17588359221113693. https://doi.org/10.1177/17588359221113693
13. Puget S, Beccaria K, Blauwblomme T, Roujeau T, James S, Grill J, Zerah M, Varlet P, Sainte-Rose C. Biopsy in a series of 130 pediatric diffuse intrinsic Pontine gliomas. *Child's Nervous System*. 2015;31(10):1773-1780. https://doi.org/10.1007/s00381-015-2832-1
14. Pfaff E, El Damaty A, Balasubramanian GP, Blattner-Johnson M, Worst BC, Stark S, Witt H, Pajtler KW, van Tilburg CM, Witt R, Milde T, Jakobs M, Fiesel P, Frühwald MC, Hernáiz Driever P, Thomale UW, Schuhmann MU, Metzler M, Bochennek K, Simon T, Dürken M, Karremann M, Knirsch S, Ebinger M, von Bueren AO, Pietsch T, Herold-Mende C, Reuss DE, Kiening K, Lichter P, Eggert A, Kramm CM, Pfister SM, Jones DTW, Bächli H, Witt O. Brainstem biopsy in pediatric diffuse intrinsic pontine glioma in the era of precision medicine: the INFORM study experience. *The European Journal of Cancer*. 2019;114:27-35. https://doi.org/10.1016/j.ejca.2019.03.019
15. Wang M, Zhang Y, Shi W, Zhu R, Li H, Zhao R. Frameless robot-assisted stereotactic biopsy: an effective and minimally invasive technique for pediatric diffuse intrinsic pontine gliomas. *Journal of Neuro-Oncology*. 2022;160(1):107-114. https://doi.org/10.1007/s11060-022-04122-4
16. Früh A, Schaumann A, Cohrs G, Pennacchietti V, Schulz M, Hernáiz Driever P, Koch A, Thomale UW. Biopsies of Caudal Brainstem Tumors in Pediatric Patients-A Single-Center Retrospective Case Series. *World Neurosurgery*. 2023;177: e84-e93. https://doi.org/10.1016/j.wneu.2023.05.108
17. Gojo J, Pavelka Z, Zapletalova D, Schmook MT, Mayr L, Madlener S, Kyr M, Vejmelkova K, Smrcka M, Czech T, Dorfer C, Skotakova J, Azizi вAA, Chocholous M, Reisinger D, Lastovicka D, Valik D, Haberler C, Peyrl A, Noskova H, Pál K, Jezova M, Veselska R, Kozakova S, Slaby O, Slavc I, Sterba J. Personalized Treatment of H3K27M-Mutant Pediatric Diffuse Gliomas Provides Improved Therapeutic Opportunities. *Frontiers in Oncology*. 2020;9:1436. https://doi.org/10.3389/fonc.2019.01436
18. Grill J, Le Teuff G, Varlet P, Hargrave DR, Nysom K, Blomgrenn K, McCowage GB, Bautista F, Van Vuurden D, Debily MA, Kergrohen T, Puget S, Bolle S, Abbou S, Leblond P, Boddaert N, Vassal G, Le Deley MC. Biological medicines for diffuse intrinsic pontine glioma (DIPG) eradication (BIOMEDE): Final results of an international randomized phase II platform trial comparing 3 targeted therapies in combination with radiotherapy from ITCC, SIOPE-Brain and ANZCHOG. *Journal of Clinical Oncology*. 2023;41(16_suppl):10003-10003. https://doi.org/10.1200/JCO.2023.41.16_suppl.10003
19. Hajikarimloo B, Tos SM, Alvani MS, Kooshki A, Hasanzade A, Zare AH, Zare AH, Najari D, Habibi MA. Efficacy and safety of dabrafenib plus trametinib in pediatric versus adult gliomas: a systematic review and meta-analysis. *Child's Nervous System*. 2025;41(1):104. https://doi.org/10.1007/s00381-025-06760-1
20. Cacciotti C, Tabori U, Hawkins C, Bennett J. Targeting the RAS/MAPK pathway in children with glioma. *Journal of Neuro-Oncology*. 2025;171(2):265-277. https://doi.org/10.1007/s11060-024-04857-2
21. Abu Laban D, Alsharif A, Al-Hussaini M, Obeidat M, Maraqa B, Alzoubi Q, Musharbash A, Jaddoua S, Ramlawi R, Khaleifeh K, Ibrahimi AK, Sarhan N, Bouffet E, Amayiri N. BRAF/MEK inhibitors use for pediatric gliomas; real world experience from a resource-limited country. *Frontiers in Oncology*. 2024;14:1417484. https://doi.org/10.3389/fonc.2024.1417484
22. Deland L, Keane S, Olsson Bontell T, Sjöberg Bexelius T, Gudinaviciene I, De La Cuesta E, De Luca F, Nilsson JA, Carén H, Mörse H, Abel F. A pilocytic astrocytoma with novel ATG16L1:: NTRK2 fusion responsive to larotrectinib: a case report with genomic and functional analysis. *Oncologist*. 2025;30(3): oyae254. https://doi.org/10.1093/oncolo/oyae254
23. Christian EA, Rutka JT. Emerging frontiers in diffuse intrinsic pontine glioma treatment: A new hope. *Neuro-Oncology*. 2025:27(8):2127-2128. https://doi.org/10.1093/neuonc/noaf117
24. Cacciotti C, Wright KD. Advances in Treatment of Diffuse Midline Gliomas. *Current Neurology and Neuroscience Reports*. 2023;23(12):849-856. https://doi.org/10.1007/s11910-023-01317-8

Received 01.07.2025
Reviced 09.10.2025
Accepted 30.01.2026