Burdenko's Journal of Neurosurgery
2026, No. 2, pp. 6–12
https://doi.org/10.17116/neiro2026900216

Microsurgical treatment of cerebral arteriovenous malformations: a 20-year experience of the Burdenko Neurosurgery Center

© Sh.Sh. Eliava[1], An.N. Konovalov[1, 2], Yu.V. Pilipenko[1], D.N. Okishev[1], F.V. Grebenev[1, 2], A.S. Kheyreddin[1], O.B. Belousova[1], A.A. Artemyev[1], T.Yu. Abzalov[2], I.A. Erokhin[2], S.S. Sergeeva[2], D.A. Starostenko[3]

[1]Burdenko Neurosurgery Center, Moscow, Russia;
[2]Sechenov First Moscow State Medical University, Moscow, Russia;
[3]Pirogov Russian National Research Medical University, Moscow, Russia.

ABSTRACT

Objective. To evaluate the results of microsurgical treatment of cerebral arteriovenous malformations (AVMs) over a 20-year period and their dynamics taking into account clinical and morphological characteristics of malformations, baseline functional status of patients and clinically relevant outcome measures.

Material and methods. A single-center retrospective cohort study included 1.273 cases of microsurgical treatment of cerebral AVMs between 2006 and 2025. Demographic data, AVM morphology, Spetzler-Martin grading, hemorrhage and seizures before surgery, preoperative embolization, early postoperative complications, and mRS scores before surgery and at discharge were assessed. A favorable outcome implied improvement or no deterioration compared to preoperative status. Clinically significant deterioration («new disability») was defined as deterioration compared to baseline status with mRS ≥3. Visual field defects were analyzed separately and not included in morbidity.

Results. In-hospital mortality was 0.6%. Favorable outcomes were observed in 1.165 out of 1.271 patients (91.7%). Clinically significant deterioration («new disability») was observed in 8.3% of patients. The incidence of complications and adverse outcomes increased along with higher Spetzler-Martin grades. Patients with previous hemorrhage were more likely to have baseline neurological deficit, but the incidence of «new disability» in this group was no different from that in patients without hemorrhage. Preoperative embolization was more common in patients with more difficult AVMs.

Conclusion. Microsurgical treatment of cerebral AVMs at a specialized center is characterized by low in-hospital mortality and high proportion of favorable functional outcomes.

Keywords: *arteriovenous malformation, microsurgery, Spetzler– Martin, functional outcome, new disability, preoperative embolization.*

INFORMATION ABOUT THE AUTHORS:
Eliava Sh.Sh. — https://orcid.org/0000-0001-6103-9329
Konovalov An.N. — https://orcid.org/0000-0002-0932-4752
Pilipenko Yu.V. — https://orcid.org/0000-0003-4001-3212
Okishev D.N. — https://orcid.org/0000-0003-0815-5624
Grebenev F.V. — https://orcid.org/0000-0003-2622-7804
Kheyreddin A.S. — https://orcid.org/0000-0002-6395-2055
Belousova O.B. — https://orcid.org/0000-0003-4908-8923
Alieva Isazade E.Ch. — https://orcid.org/0009-0004-2581-5078
Artemyev A.A. — https://orcid.org/0000-0002-3537-7997
Abzalov T.Y. — https://orcid.org/0009-0008-1321-563X
Erokhin I.A. — https://orcid.org/0009-0003-9584-5865
Sergeeva S.S. — https://orcid.org/0009-0007-4784-5640
Starostenko D.A. — https://orcid.org/0009-0005-3436-4579
Corresponding author: Konovalov An.N. — e-mail: ANKonovalov@nsi.ru

TO CITE THIS ARTICLE:
Eliava ShSh, Konovalov AnN, Pilipenko YuV, Okishev DN, Grebenev FV, Kheyreddin AS, Belousova OB, Alieva Isazade ECh, Artemyev AA, Abzalov TYu, Erokhin IA, Sergeeva SS, Starostenko DA. Microsurgical treatment of cerebral arteriovenous malformations: a 20-year experience of the Burdenko Neurosurgical Center. *Burdenko's Journal of Neurosurgery.* 2026;90(2):6–12. (In Russ.).
https://doi.org/10.17116/neiro2026900216

Introduction

Cerebral arteriovenous malformations (AVMs) are complex congenital vascular abnormalities. The most typical clinical manifestations are epileptic seizures and intracerebral hemorrhages. Hemorrhages are the most severe and prognostically unfavorable complication potentially resulting in persistent neurological impairment

and death [1—3]. The risk of hemorrhage persists throughout the patient's life and largely determines the indications for treatment with AVM exclusion [2].

Microsurgical treatment is one of the key methods for total exclusion of AVMs and ensures immediate elimination of the risk of recurrent hemorrhage [4—7]. However, surgical intervention is associated with potential neurological complications. This requires careful assessment of risk-benefit ratio of treatment and appropriate patient selection [4, 8].

The Spetzler-Martin scale, based on assessment of vascular tangle size, venous drainage and AVM localization relative to functionally significant brain areas, is widely used to stratify surgical risk and predict outcomes [9].

When assessing functional outcomes of treatment, it is necessary to take into account baseline neurological status. Without taking this factor into account, the number of patients with unfavorable functional outcome may be higher than actual level of unfavorable outcomes caused by surgical intervention [8].

The role of preoperative embolization deserves a special attention. On the one hand, embolization can reduce intraoperative blood loss and simplify resection of malformation. On the other hand, embolization is more often used in patients with more complex AVM angioarchitecture and high technical complexity of intervention. This should be taken into account when analyzing treatment outcomes [4, 7].

The purpose of the study was to evaluate the results of microsurgical treatment of cerebral AVMs at the Burdenko Neurosurgery Center over a 20-year period and their dynamics taking into account clinical and morphological characteristics of malformations, baseline functional status of patients and clinically relevant outcome measures.

Material and methods

A single-center retrospective cohort study enrolled patients with AVMs who underwent microsurgical treatment between 2006 and 2025. The study is based on analysis of medical records in electronic registry. There were 1.273 patients **(Table 1**, **Fig. 1**, **2).**

The unit of analysis was a record in database containing information from the patient's medical history and surgical protocol. In case of duplicate identifiers reflecting multiple procedures on the same patient, the records were not aggregated.

Analysis included the following variables (if available): gender, age, previous hemorrhage, AVM location and size, relationship to functionally significant areas, venous drainage pattern, SM grade, information about preoperative endovascular intervention, mRS score before surgery and at discharge, early postoperative complications and extent of resection according to follow-up angiography data. Categorical variables were standardized (including binary «yes/no» answers). Validity checks were performed for obviously impossible values and logical inconsistencies.

Table 1. **Patient characteristics.**

Variable	Value
Number of patients, *n*	1273
Mean age, years	32.4±14.2
Men, *n* (%)	752 (59.1)
Women, *n* (%)	521 (40.9)
Previous hemorrhage, *n* (%)	758 (59.5)
Mean preoperative mRS score	1±1.21
Spetzler–Martin grades, *n* (%)	
I	131 (10.3)
II	477 (37.5)
III	442 (34.7)
IV	121 (9.5)
V	2 (0.2)
No data	100 (7.9)
AVM size, *n* (%)	
Mean dimension, mm	35.5±13.4
<30 mm	271 (21.3)
30—60 mm	715 (56.2)
>60 mm	27 (2.1)
No data	260 (20.4)
Functionally significant zone, *n* (%)	585 (46.0)
Deep venous drainage, *n* (%)	166/1207 (13.8)
Hemorrhage, *n* (%)	758/1273 (59.5).
Epileptic syndrome, *n* (%)	410/1273 (32.2)
Preoperative embolization, *n* (%)	174/1273 (13.7)

Note: mRS — modified Rankin scale.

Completeness of recording of certain parameters was limited due to retrospective nature of our study. In particular, data on perioperative blood loss, wound cerebrospinal fluid leakage, transient neurological disorders, and other minor complications were not always reported. This characterizes specifics of medical records at different periods. At the same time, hospital-stay, functional outcome at discharge, mortality and major complications were recorded in almost all cases. Thus, these data were significant for assessing early outcomes of microsurgical treatment. We did not analyze structure of epileptic syndrome (nature, frequency and duration of seizures) in this study. Only the presence of epileptic seizures was recorded as a binary indicator.

AVM size was measured in millimeters. When recording size as multiple dimensions (e.g., «a·b·c»), we used maximum indicator. A categorical size variable was additionally created: <30, 30—60, >60 mm.

A functionally significant area was defined as a brain region whose damage is associated with major neurological deficit. These areas included primary motor and sensory cortex, speech areas in dominant hemisphere (Broca's and Wernicke's areas), visual cortex, loop of Meynert, subcortical structures, cerebellar nuclei, and cerebellar peduncles.

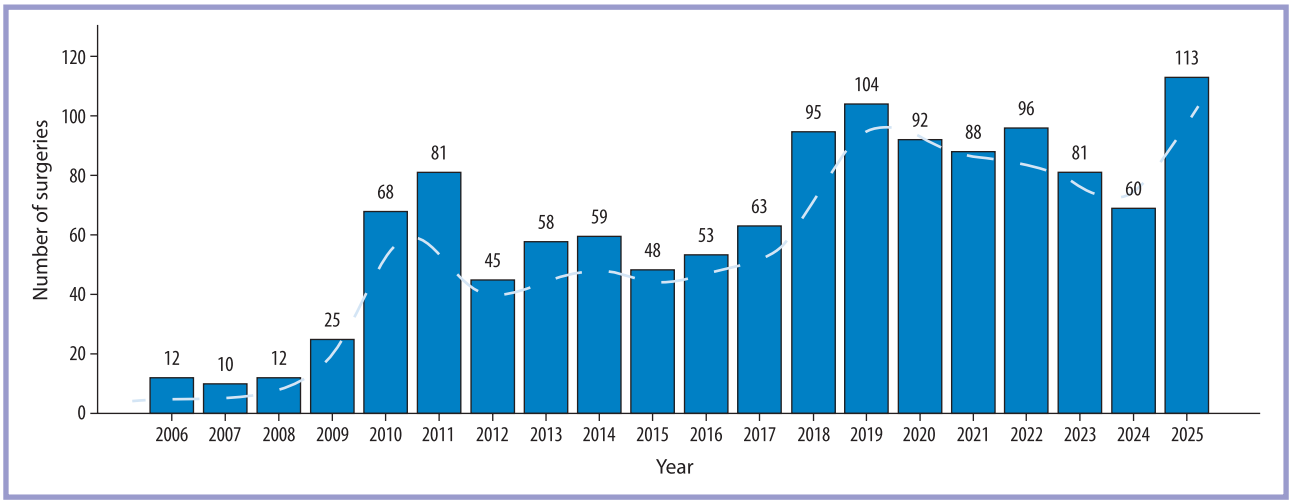

Fig. 1. **Annual numbers of microsurgical procedures.**

Deep venous drainage was defined as blood outflow from AVM primarily or partially through deep cerebral venous system. Deep venous drainage included drainage into internal cerebral veins, vein of Galen, straight sinus and other deep venous collectors, including basal veins and deep cerebellar veins.

We used Spetzler-Martin grade specified in database. Results were analyzed and presented separately for Spetzler-Martin grades I, II, III, IV and V. In case of extremely small number of cases with Spetzler-Martin grade V, we presented only descriptive conclusions for this group.

Functional outcome was assessed as mRS score at discharge. The primary endpoint was unfavorable functional outcome.

Unfavorable outcome was defined as a combination of two conditions:

1. mRS at discharge $\geqslant 3$;
2. Deterioration compared to preoperative status, i.e. ΔmRS=mRS (discharge) — mRS (preoperative) >0.

For example, no deterioration (ΔmRS=0) was interpreted as a favorable outcome for primary endpoint in a patient with baseline impairment (mRS $\geqslant 3$). We did not include visual impairments (visual field defects) in complications and analyzed them separately. Visual impairment was defined as visual disorders after surgery without similar abnormalities before surgery (if appropriate data were available in a case record: ophthalmologist examination, neurological examination, discharge summary).

Severe complication implied complication together with functional deterioration (ΔmRS>0) or mRS score 4—6 at discharge.

Extent of AVM resection was assessed using angiography data or surgical protocol if neuroimaging data were unavailable. Residual malformation was recorded for any indication of subtotal resection, residual fragments or partial resection.

Statistical analysis

Continuous variables are presented as mean ± SD for parametric distributions and median [Q_1; Q_3] for non-parametric distributions. Categorical variables are presented as absolute and relative frequencies (*n*, %). Between-group comparisons of categorical variables implied the Pearson χ^2 test or Fisher's exact test for low expected frequencies. For continuous variables, we assessed distribution normality (Shapiro-Wilk test) and, if necessary, equality of variances. Finally, we used the t-test (including Welch's method) or Mann-Whitney test depending on results. Differences were significant at $p<0.05$ (two-tailed test). To assess the risk factors of adverse outcomes, we used multivariate logistic regression with odds ratios, 95% confidence intervals (CI) and p-values. The relationship between independent variables was assessed using the variance inflation factor. Model robustness was assessed by the number of events per a variable with limitations of interpretation for small event numbers.

Results

Annual numbers of surgeries demonstrate ascending trend despite significant variability **(Fig. 1)**. Treatment outcomes are presented in **Table 2** and **Fig. 3**. The median of mRS score at discharge was 2 [0; 2] (mean 1.5±1.3). There were 984 (77.3%) out of 1.273 patients with good outcomes (mRS score 0—2). Among 1.273 ones, 211 (16.6%) patients had preoperative mRS score $\geqslant 3$. Of these, 204 (96.7%) ones were discharged with improvement or without deterioration (ΔmRS $\leqslant 0$). Thus, favorable outcomes (no significant functional deterioration (including improvement, no change or deterioration with mRS score 0—2)) were observed in 1.165 (91.7%) out of 1.273 patients.

In-hospital mortality was 0.6% (8 out of 1.273 patients). Unfavorable outcomes were observed in 106 (8.3%)

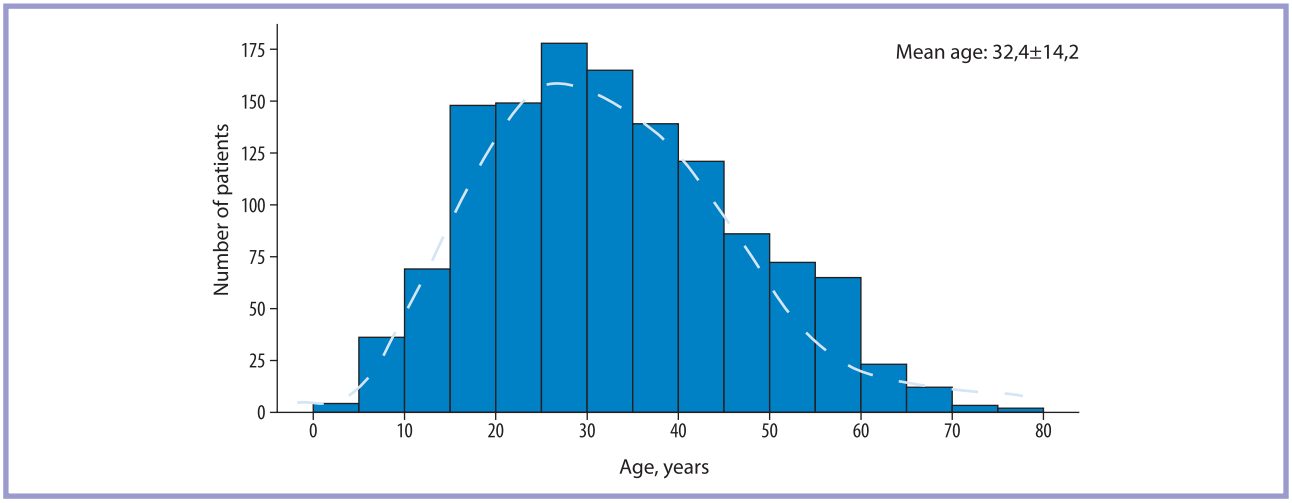

Fig. 2. **Age-adjusted patient distribution.**

Table 2. **Early outcomes after microsurgical treat ment of arteriovenous malformations.**

Variable	Value, *n* (%)
Death (mRS=6)	8 (0.6)
«New disability»: mRS ⩾3 + ΔmRS >0	106 (8.3)
Severe complications	19 (1.5)
All complications *	303 (23.8)
New visual disturbances after surgery	162 (12.7)
Total resection	618/663 (93.2)

Note: * — excluding visual field impairment.

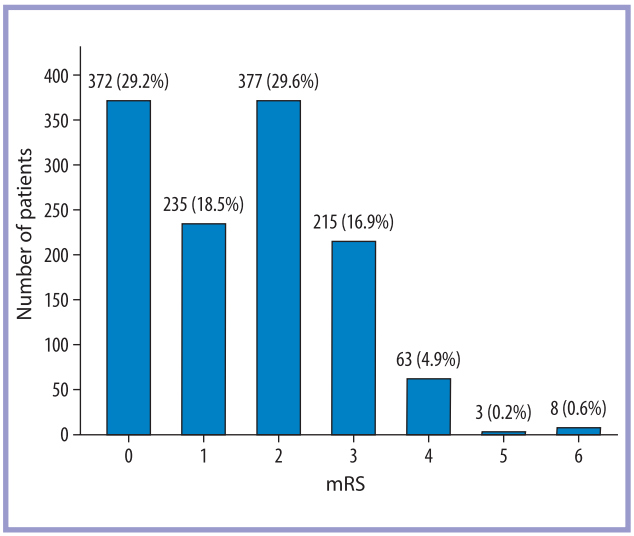

Fig. 3. **Distribution of mRS scores at discharge.**

out of 1.273 patients taking into account new neurological impairment (mRS score ⩾3 combined with ΔmRS >0) **(Table 2)**.

Any early complications (cerebral and extracerebral), recorded in appropriate database field, were observed in 303 (23.8%) out of 1.273 patients. Severe complications with mRS score 4—6 were found in 25 (2.0%) out of 1.273 patients, severe non-fatal complications – in 19 (1.5%) out of 1.273 patients.

If there was a high risk of new or aggravation of baseline visual field impairments after surgery for AVMs near visual cortex or optic pathway, patients were warned of this complication. Surgery was performed only with their consent. Preoperative visual field impairments were present in 244 (19.3%) out of 1.267 patients, at discharge – in 415 (33.2%) out of 1.251 patients. Thus, new/worsened visual impairments accounted for 199 (15.9%) out of 1.248 patients.

Evaluation of AVM excision quality was available for 670 (56.2%) patients. Residual malformation was observed in 6.8% of cases. When stratified by diagnostic method, total resection was confirmed by CTA in 365 (94.3%) out of 387 patients, by digital subtraction angiography – in 233 (91.0%) out of 256 patients.

Year-adjusted analysis of outcomes demonstrated a downward trend in mortality and stable low complication rate. Proportion of patients with mandatory postoperative angiography to assess AVM resection quality increased. Despite the increasing number of interventions following expansion of capabilities, the incidence of adverse outcomes did not change significantly and remained low **(Fig. 4)**.

Stratification by Spetzler-Martin grades is presented in **Table 3**. The incidence of adverse outcomes («new disability») increased with higher Spetzler-Martin grades. The Spetzler-Martin grade V group was extremely small, so results were descriptive in nature. The incidence of any complications also increased with higher Spetzler-Martin grades.

Patients with previous hemorrhage were characterized by smaller AVM compared to patients without hemorrhage (30 [25; 40] mm, mean 33.9±13.3 mm, *n*=561 vs.

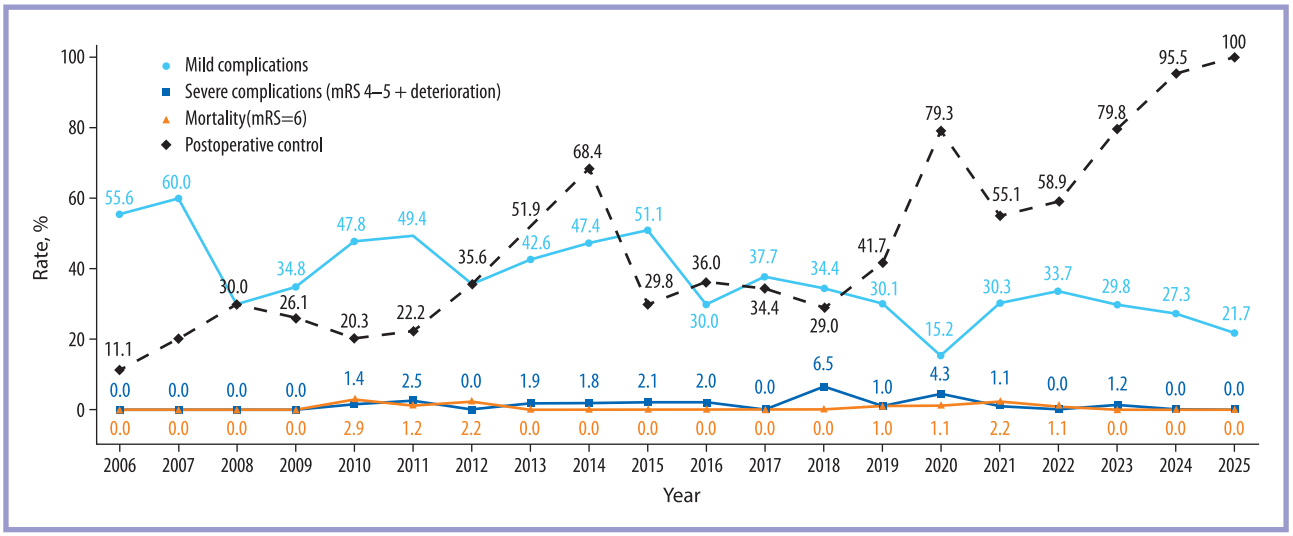

Fig. 4. **Year-adjusted trends in complication rates, in-hospital mortality and follow-up angiography.**

median 40 [30; 45] mm, mean 37.6±13.2 mm, n=452; p<0.001) and more severe neurological impairment before surgery (mRS score 1 [0; 3], mean 1.5±1.3 vs. 1 [0; 1], mean 0.7±0.8; p<0.001). Moreover, the incidence of clinically significant deterioration taking into account baseline functional status («new disability») did not differ significantly between groups (7.8% and 9.1%, respectively, p=0.410).

Localization in functionally significant zone was associated with higher incidence of unfavorable outcomes according to «new disability» criterion (69 (11.8%) out of 584 versus 37 (5.4%) out of 682, p<0.001), as well as higher incidence of complications (184 (31.5%) out of 585 versus 119 (17.4%) out of 683, p<0.001).

Preoperative embolization was associated with larger AVM (40 [35; 50] mm (44.1±14.5), n=142 vs. 30 [25; 40] mm (34.2±12.6), n=870; p<0.001) and higher incidence of «new disability» (23 (13.2%) out of 174 vs. 83 (7.6%) out of 1096, p=0.018), as well as higher incidence of complications (56 (32.2%) out of 174 vs. 247 (22.5%) out of 1098, p=0.007).

In multivariate logistic regression including Spetzler-Martin grading (n=1170; 101 adverse events), higher grade was an independent predictor of «new disability» (OR 1.71 per one grade change, 95% CI 1.32–2.22; p<0.001). Age, previous hemorrhage and preoperative embolization were not significant predictors in this model. Functional significance of zone was an independent predictor of «new disability» (OR 2.71, 95% CI 1.68—4.38; p<0.001). AVM enlargement (10 mm increment) did not significantly impact adverse outcomes (OR 1.16; 95% CI 0.99—1.36; p=0.074).

Discussion

This study presents a 20-year experience in microsurgical treatment of cerebral AVMs at a single neurosurgical center. The key findings were low (0.6%) in-hospital mortality, acceptable rate of early complications and clinically significant deterioration when compared to baseline functional status. Visual field impairment in AVMs located in occipital lobes or near visual pathways is predictable justifying their separate consideration and exclusion from unexpected complications. Considering predictable nature of these disorders, it is essential to discuss this risk with the patient and include it in informed consent form

Thus, microsurgical treatment is still an effective and predictable method in carefully selected patients with appropriate surgical experience [4—7].

Our results are comparable with data from large modern microsurgical series. Schramm J. et al. [6] demonstrated very high total resection rate (99%; 98.7% for small AVMs) and mortality rate (1.7%, n=5) among 288 patients. Early neurological deterioration was observed in 39.2% of cases, persistent deficit — in 12.2%, persistent significant deficit — in 5.6% of cases. Ren Q. et al. [7] presented similar patterns in a large series, where favorable outcomes (mRS score 0—2) exceeded 75%. Complication rate and mortality increased with higher SM grades. Thus, our data are consistent with the best indicators reported in the literature [11—15].

Higher SM grades were independent predictor of adverse outcome in multivariate logistic regression. Functional significance of the area was the most sensitive factor in surgical risk. Lawton M.T. et al. [16] developed additional prognostic scale where age over 40 years and hemorrhagic manifestation worsened surgical prognosis. These factors were included in the model as independent risk factors along with morphological characteristics of AVM. However, we did not confirm significant influence of age and hemorrhage. This may be due to differences in outcome assessment and requires further analysis.

Interpretation of results in context of post-ARUBA era deserves separate discussion. The ARUBA study demonstrated the advantage of conservative management

Table 3. **Complication and mortality rates depending on Spetzler-Martin grades.**

SM	N	Any complications, *n* (%)	Severe complications, *n* (%)	Unfavorable outcome, *n*/N (%)	Mortality, *n* (%)	Non-total resection, *n*, (%)
I	131	14 (10.7)	0	4/130 (3.1)	0	1 (0.9)
II	477	94 (19.7)	4 (0.8)	31/477 (6.5)	1 (0.2)	14 (3.2)
III	442	130 (29.4)	11 (2.5)	44/442 (10)	5 (1.1)	15 (3.6)
IV	121	46 (38.0)	8 (6.6)	22/121 (18.2)	2 (1.7)	7 (6.4)
V	2	1 (50.0)	0	0/2 (0)	0	1 (50)
Total	1173	285 (24.3)	23 (2.0)	101 (8.6)	8 (0.7)	38 (3.2)

for unruptured AVMs regarding the combined endpoint «stroke or death» [17]. Nevertheless, numerous subsequent studies indicated the limitations of these conclusions. Modern observational samples of patients comparable in criteria to ARUBA population demonstrate low risk of persistent disabling neurological impairment and mortality in case of strict patient selection and microsurgical treatment in specialized centers [5, 6]. According to large national study in the USA, incidence of admissions for ruptured AVMs and in-hospital mortality significantly increased in post-ARUBA period [1, 2].

In our sample, patients with previous hemorrhage had expectedly higher preoperative mRS scores and lower functional status at discharge. However, the rate of clinically significant deterioration in this group was not different from that in patients without hemorrhage. This highlights the need to distinguish baseline neurological deficit and new surgery-induced impairment when assessing treatment outcomes in patients with ruptured AVMs. This is consistent with current concepts of clinical interpretation of functional outcomes [8].

In our cohort, the incidence of complications, adverse outcomes and residual shunting increased with higher SM grades. Microsurgical treatment demonstrated the most favorable results for AVM grade I—III as confirmed by recent series [5—7]. There were significantly more frequent complications and adverse outcomes among patients with AVM grade IV—V. This emphasizes the need for careful patient selection, multidisciplinary discussion and consideration of alternative or combined treatment strategies [6, 11]. Small size of the SM grade V group in this study limits conclusions for this category and reflects general approach to conservative treatment of such AVMs.

In our study, preoperative embolization was more common in patients with larger AVMs characterized by more difficult structure and localization. This subgroup is technically more challenging for microsurgical resection. Modern systematic reviews and meta-analyses do not confirm adverse effect of preoperative embolization as an independent factor on functional outcomes. They consider embolization as an auxiliary step in individual treatment strategy for complex AVMs [4, 12, 13].

Conclusion

Microsurgical treatment of cerebral arteriovenous malformations in a specialized center ensures low postoperative mortality and acceptable early clinical outcomes. Visual field defects are usually expectable consequence of surgery for certain arteriovenous malformations. This fact justifies their separate consideration and exclusion from unexpected complications.

Prospective follow-up studies with standardized endpoints are needed to clarify the role of microsurgery in seizure control and resection quality.

Author contribution:
Concept and design of the study — Eliava Sh.Sh., Konovalov An.N., Pilipenko Yu.V.
Collection and analysis of data — Okishev D.N., Kheyreddin A.S., Belousova O.B., Alieva Isazade E.Ch., Artemyev A.A., Abzalov T.Yu., Erokhin I.A., Sergeeva S.S., Starostenko D.A.
Statistical analysis — Konovalov An.N., Grebenev F.V., Abzalov T.Yu., Erokhin I.A.
Writing the text — Konovalov An.N., Belousova O.B.
Editing — Eliava Sh.Sh., Belousova O.B., Pilipenko Yu.V.

The authors declare no conflicts of interests.

REFERENCES

1. Dicpinigaitis A.J., Ogulnick J.V., Mayer S.A., Gandhi C.D., Al-Mufti F. Increase in ruptured cerebral arteriovenous malformations and mortality in the United States: unintended consequences of the ARUBA trial? *Stroke: Vascular and Interventional Neurology.* 2023;3:e000442. https://doi.org/10.1161/SVIN.122.000442
2. Luther E., Chen S.H., McCarthy D.J., Sur S., Ding D., Starke R.M., Crowley R.W., Liu K.C., Chalouhi N., Jabbour P.M. National reduction in cerebral arteriovenous malformation treatment correlated with increased rupture incidence. *Journal of NeuroInterventional Surgery.* 2023;15(8):735-740. https://doi.org/10.1136/jnis-2022-019110
3. Derdeyn C.P., Zipfel G.J., Albuquerque F.C., Cooke D.L., Feldmann E., Sheehan J.P., Torner J.C. Management of brain arteriovenous malformations: a scientific statement from the American Heart Association/American Stroke Association. *Stroke.* 2017;48(8):e200-e224. https://doi.org/10.1161/STR.0000000000000134
4. Sattari S.A., Shahbandi A., Yang W., Xu R., Yu J., Starke R.M., Jabbour P.M., Ding D. Microsurgery versus microsurgery with preoperative embolization for brain AVM treatment: a systematic review and meta-analysis. *Neurosurgery.* 2023;92(1):27-41. https://doi.org/10.1227/neu.0000000000002171
5. Potts M.B., Lau D., Abla A.A., Kim H., Young W.L., Lawton M.T. Current surgical results with low-grade brain AVMs. *Journal of Neurosurgery.* 2015;122(4):912-920. https://doi.org/10.3171/2014.12.JNS14938
6. Schramm J., Schaller K., Esche J., Boström A. Microsurgery for cerebral AVMs: subgroup outcomes in a consecutive series of 288 cases. *Journal of Neurosurgery*. 2017;126(4):1056-1063. https://doi.org/10.3171/2016.4.JNS153017
7. Ren Q., He M., Zeng Y., Zhao Y., Chen J., Li Y., Liu A. Microsurgery for intracranial AVM: long-term outcomes in 445 patients. *PLoS One*. 2017;12(3):e0174325. https://doi.org/10.1371/journal.pone.0174325
8. Inoa V., Goyal N., Arthur A.S., Rai A.T., Elijovich L., Hoit D.A., Spiotta A.M., Turk A.S., Frei D., Mocco J., Jadhav A.P. Is the modified Rankin Scale still the right endpoint for neurointerventional trials? *Journal of NeuroInterventional Surgery.* 2025;17(12):1267-1269. https://doi.org/10.1136/jnis-2025-024605
9. Spetzler R.F., Martin N.A. A proposed grading system for arteriovenous malformations. *Journal of Neurosurgery.* 1986;65(4):476-483. https://doi.org/10.3171/jns.1986.65.4.0476
10. Éliava ShSh, Filatov IuM, Pilipenko IuV, et al. Microsurgical treatment of cerebral arteriovenous malformations in Burdenko Neurosurgical Institute (recent experience). *Burdenko's Journal of Neurosurgery.* 2012;76(3):34-44. (In Russ.)
11. Park M.T., Essibayi M.A., Srinivasan V.M., Daniels D.J., Lanzino G., Brinjikji W. Surgical management outcomes after preoperative embolization: a systematic review and meta-analysis. *Neurosurgical Review.* 2022;45(6):3499-3510. https://doi.org/10.1007/s10143-022-01860-x
12. Dmitriev A.V., Eliava Sh.Sh., Yakovlev S.B., Pilipenko Yu.V., Gorozhanin V.A., Belousova O.B. Complications and functional outcomes of microsurgical resection of arteriovenous malformations following preoperative endovascular embolization. *Bulletin of Neurology, Psychiatry and Neurosurgery.* 2023;(6). https://doi.org/10.33920/med-01-2306-03
13. Gorozhanin VA, Pilipenko IuV, Belousova OB, Éliava ShSh. Microsurgical treatment of non-bleeding cerebral arteriovenous malformations. *Burdenko's Journal of Neurosurgery*. 2018;82(5):119-124. (In Russ., In Engl.) https://doi.org/10.17116/neiro201882051119
14. Gorozhanin VA, Éliava ShSh, Pilipenko IuV, Shekhtman OD, Sazonova OB. Immediate outcomes of microsurgical treatment of cerebral arteriovenous malformations in non-hemorrhagic patients. *Burdenko's Journal of Neurosurgery.* 2018;82(6):30-37. (In Russ., In Engl.) https://doi.org/10.17116/neiro20188206130
15. Éliava ShSh, Pilipenko IuV, Yakovlev SB, Golanov AV, Mariashev SA, Grebenev FV. Arteriovenous malformations of the brain in children: treatment results for 376 patients. *Burdenko's Journal of Neurosurgery.* 2020;84(2):22-34. (In Russ., In Engl.) https://doi.org/10.17116/neiro20208402122
16. Lawton M.T., Kim H., McCulloch C.E., Mikhak B., Young W.L. A supplementary grading scale for selecting patients with brain arteriovenous malformations for surgery. *Neurosurgery*. 2010;66(4):702-713. https://doi.org/10.1227/01.NEU.0000367555.16733.E1
17. Mohr J.P., Parides M.K., Stapf C., Moquete E., Moy C.S., Overbey J.R., Al-Shahi Salman R., Vicaut E., Young W.L., Houdart E., Cordonnier C., Stefani M.A., Hartmann A., von Kummer R., Mast H., Stapf C. Medical management with or without interventional therapy for unruptured AVMs (ARUBA). *Lancet*. 2014;383(9917):614-621. https://doi.org/10.1016/S0140-6736(13)62302-8

Received 15.01.2026
Accepted 30.01.2026