Burdenko's Journal of Neurosurgery
2026, No. 1, pp. 100–107
https://doi.org/10.17116/neiro202690011100

Facial neuropathy in early postoperative period after resection of cerebellopontine angle tumor using various modalities of intraoperative neurophysiological monitoring: a systematic review and meta-analysis

© E.G. SELIVERSTOVA[1], M.V. SINKIN[1, 2], A.A. GRIN[1, 2]

[1]Sklifosovsky Research Institute for Emergency Care, Moscow, Russia;
[2]Pirogov Russian National Research Medical University, Moscow, Russia

ABSTRACT

Objective. To analyze the incidence of facial neuropathy after microsurgical resection of cerebellopontine angle (CPA) tumors using various intraoperative neurophysiological monitoring (IONM) scenarios.

Material and methods. We analyzed 792 articles from PubMed, Google Scholar, Web of Science, and e-library databases and selected 35 eligible studies. There were 4,657 patients including 1,173 ones with facial neuropathy after CPA tumor resection. Statistical analysis was performed using OpenMeta Analyst software. Differences were significant at $p< 0.05$.

Results. The pooled incidence of postoperative facial neuropathy after CPA tumor resection was 28.9% (95% CI: 23.3% — 34.6%). In case of multimodal IONM, this value decreased to 23.5% (95% CI: 17.9% — 29.2%). This demonstrates significant effectiveness of this approach compared to direct facial nerve stimulation and resting EMG monitoring.

Keywords: *facial neuropathy, intraoperative neurophysiological monitoring, cerebellopontine angle tumor.*

INFORMATION ABOUT THE AUTHORS:
Seliverstova E.G. — https://orcid.org/0000-0001-9652-1457
Sinkin M.V. — https://orcid.org/0000-0001-5026-0060
Grin A.A. — https://orcid.org/0000-0003-3515-8329
Corresponding author: Seliverstova E.G. — e-mail: e.seliverstova.md@gmail.com

TO CITE THIS ARTICLE:
Seliverstova EG, Sinkin MV, Grin AA. Facial neuropathy in early postoperative period after resection of cerebellopontine angle tumor using various modalities of intraoperative neurophysiological monitoring: a systematic review and meta-analysis. *Burdenko's Journal of Neurosurgery*. 2026;90(1):100–107. (In Russ.). https://doi.org/10.17116/neiro202690011100

Abbreviations

IONM — intraoperative neurophysiological monitoring
FEMP — facial evoked motor potentials
CPA — cerebellopontine angle
TES — transcranial electrical stimulation
EMG — electromyography
H-B — House-Brackmann scale

Introduction

CPA tumors are neoplasms within depression between the pons, medulla oblongata and cerebellum. They account for 5—10% of all intracranial tumors. Vestibulocochlear neuroma is the most common and accounts for up to 85—95% of tumors in this area [1]. Meningiomas, epidermoid cysts and cholesteatomas are less common [2]. Rare CPA tumors include arachnoid cysts, cavernous malformations, fourth ventricle tumors, craniopharyngiomas, hemangioblastomas, medulloblastomas, and other cerebellar neoplasms, lipomas, lymphomas, and paragangliomas [3]. Malignant tumors of this region are most often represented by metastatic lesions, and melanoma metastases prevail [4]. This disease can debut at the age of 40—70 years and occurs with equal frequency in men and women. Symptoms depend on location of CPA tumor, its size and nerve compression (primarily V and VII cranial nerves). Microsurgical techniques and IONM for resection of CPA tumors preserve not only anatomical integrity of facial nerve, but also its function in most patients. There are several IONM modalities that are informative for predicting facial neuropathy.

The purpose of this study was to analyze available literature data on the incidence of facial neuropathy after microsurgical resection of CPA tumors using various IONM scenarios.

Material and methods

Searching and selection of studies. Searching algorithm was developed in accordance with PRISMA guidelines [5]. We reviewed the PubMed, Google Scholar, Web of Science, and eLIBRARY databases using search queries, keywords and Boolean operators. Abstracts, meeting minutes, books, case reports and case series were excluded. The following queries were used to screen foreign databases: "facial nerve palsy", "cerebellar pontine angle tumors" and "intraoperative neurophysiological monitoring"; for Russian-language database — "опухоль мостомозжечкового угла", "нейропатия лицевого нерва", "интраоперационный нейрофизиологический мониторинг". Searching was conducted without publication date restrictions and finished on November 12, 2024.

Inclusion/exclusion criteria. A systematic review included case-control studies with total or near-total tumor resection and assessed facial nerve function (H-B grade at discharge). Facial neuropathy was defined as a de novo deterioration of facial nerve function by >1 point (H-B scale) or deterioration of facial nerve function by ⩾1 points (H-B scale).

Microsurgical tumor resection was performed using IONM whose protocol included direct nerve stimulation, combination of direct stimulation and resting EMG monitoring or combination of three modalities (nerve stimulation, resting EMG monitoring and FMEP).

Meta-analysis excluded patients with neurofibromatosis type 2 and continued tumor growth (recurrence).

Data extraction and synthesis. After primary screening, we found 775 English-language articles and 89 Russian-language articles. Study flowchart is presented in **Fig. 1**.

Risk of bias. We assessed validity and methodological quality of studies using the adapted Newcastle-Ottawa Scale (NOS). This system took into account the risk of bias across 8 domains (D1—D8) divided into 3 categories: patient selection, group comparability and exposure analysis [6]. The risk of bias was classified as low (8—9 points), moderate (6—7 points) and high (⩽5 points) **(Table)**.

Statistical analysis. Statistical analysis was performed using OpenMeta[Analyst]. Results were presented in forest plots. When summarizing data of different studies, we used random-effect model due to significant statistical heterogeneity across most parameters (I^2>40%). Heterogeneity of studies was assessed using the Q-test, magnitude of heterogeneity — using the I^2 coefficient. Significant heterogeneity was established at p<0.1. Publication bias was assessed using funnel plots and Egger's test; bias was significant at p<0.05 and insignificant at p⩾0.05.

Results

There were 4,657 patients, and 1,173 ones developed facial neuropathy after microsurgical resection of CPA tumor.

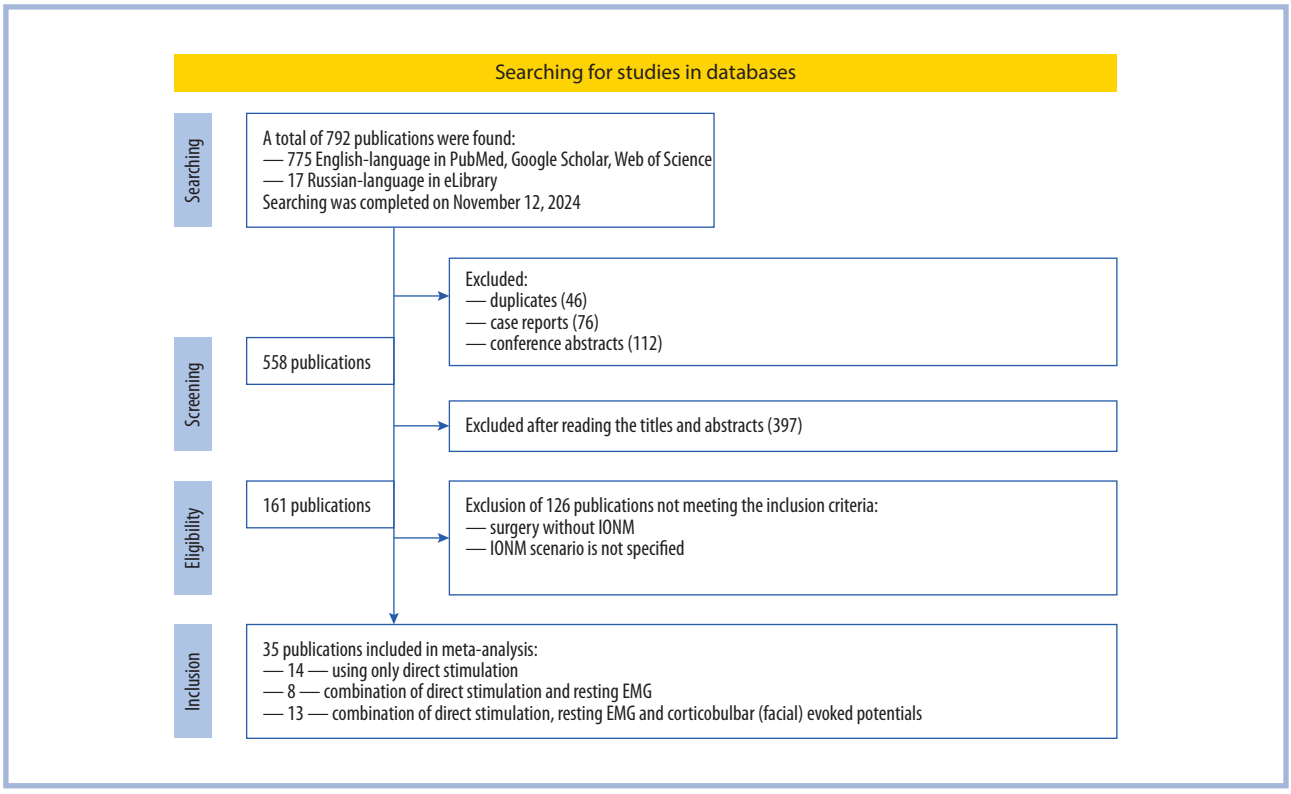

Fig. 1. **Study flowchart.**

Validity and methodological quality of studies

No.	Authors, year	D1	D2	D3	D4	D5	D6	D7	D8	Total score	Risk of bias
	DNS subgroup										
1	Y. Ren et al., 2020 [7]	☐	☐	☐	☐	☐	☐	☐	☐	7	Moderate
2	R.J. Yawn et al., 2018 [8]	☐	☐	☐	☐	☐	☐	☐	☐	7	Moderate
3	F. Arlt et al., 2022 [9]	☐	☐	☐	☐	☐☐	☐	☐	☐	7	Moderate
4	X.H. Jia et al., 2022 [10]	☐	☐	☐	☐	☐☐	☐	☐	☐	9	Low
5	F. Gazia et al., 2022 [11]	☐	☐	☐	☐	☐	☐	☐	☐	6	Moderate
6	A.K. Lalwani et al., 1994 [12]	☐	☐	☐	☐	☐☐	☐	☐	☐	8	Low
7	L.P. Carlstrom et al., 2015 [13]	☐	☐	☐	☐	☐☐	☐	☐	☐	8	Low
8	T.E. Delgado et al., 1979 [14]	☐	☐	☐	☐	☐	☐	☐	☐	5	High
9	G. Magliulo et al., 1998 [15]	☐	☐	☐	☐	☐	☐	☐	☐	6	Moderate
10	B. Isaacson et al., 2003 [16]	☐	☐	☐	☐	☐	☐	☐	☐	8	Low
11	X. Huang et al., 2018 [17]	☐	☐	☐	☐	☐	☐	☐	☐	7	Moderate
12	J.M. Taha et al., 1995 [18]	☐	☐	☐	☐	☐☐	☐	☐	☐	8	Low
13	R.H. Goldbrunner et al., 2000 [19]	☐	☐	☐	☐	☐☐	☐	☐	☐	9	Low
14	V.N. Shimansky et al., 2017 [20]	☐	☐	☐	☐	☐☐	☐	☐	☐	6	Moderate
	Fr subgroup										
15	M. Farid et al., 2019 [21]	☐	☐	☐	☐	☐	☐	☐	☐	7	Moderate
16	J.E. Benecke Jr et al., 1987 [22]	☐	☐	☐	☐	☐	☐	☐	☐	6	Moderate
17	G.A. Grant et al., 2002 [23]	☐	☐	☐	☐	☐	☐	☐	☐	6	Moderate
18	R.P. Morton et al., 2011 [24]	☐	☐	☐	☐	☐☐	☐	☐	☐	9	Low
19	J. Prell et al., 2007 [25]	☐	☐	☐	☐	☐☐	☐	☐	☐	9	Low
20	J. Romstöck et al., 2000 [26]	☐	☐	☐	☐	☐	☐	☐	☐	5	High
21	J. Prell et al., 2014 [27]	☐	☐	☐	☐	☐	☐	☐	☐	4	High
22	S.A. Utesova et al., 2015 [28]	☐	☐	☐	☐	☐	☐	☐	☐	5	High
	Fmep subgroup										
23	S. Chang et al., 2019 [29]	☐	☐	☐	☐	☐☐	☐	☐	☐	9	Low
24	C.C. Dong et al., 2005 [30]	☐	☐	☐	☐	☐☐	☐	☐	☐	9	Low
25	T. Goto et al., 2010 [31]	☐	☐	☐	☐	☐☐	☐	☐	☐	9	Low
26	I. Fernández-Conejero et al., 2022 [32]	☐	☐	☐	☐	☐☐	☐	☐	☐	9	Low
27	Baek J.S. et al., 2018 [33]	☐	☐	☐	☐	☐	☐	☐	☐	6	Moderate
28	J. Sarnthein et al., 2013 [34]	☐	☐	☐	☐	☐☐	☐	☐	☐	7	Low
29	V.K. Karanth et al., 2024 [35]	☐	☐	☐	☐	☐☐	☐	☐	☐	9	Low
30	K. Machetlanz et al., 2024 [36]	☐	☐	☐	☐	☐☐	☐	☐	☐	9	Low
31	M.A. Acioly et al., 2010 [37]	☐	☐	☐	☐	☐	☐	☐	☐	8	Low
32	M.A. Acioly et al., 2011 [38]	☐	☐	☐	☐	☐	☐	☐	☐	7	Moderate
33	S.K. Bhimrao et al., 2016 [39]	☐	☐	☐	☐	☐☐	☐	☐	☐	9	Low
34	S.W. Liu et al., 2015 [40]	☐	☐	☐	☐	☐☐	☐	☐	☐	9	Low
35	R. Hiruta et al., 2021 [41]	☐	☐	☐	☐	☐☐	☐	☐	☐	9	Low
	☐ — 1 score ☐☐ — 0 score										

Note. DNS — direct nerve stimulation; FR — free run; FEMP — facial evoked motor potentials.

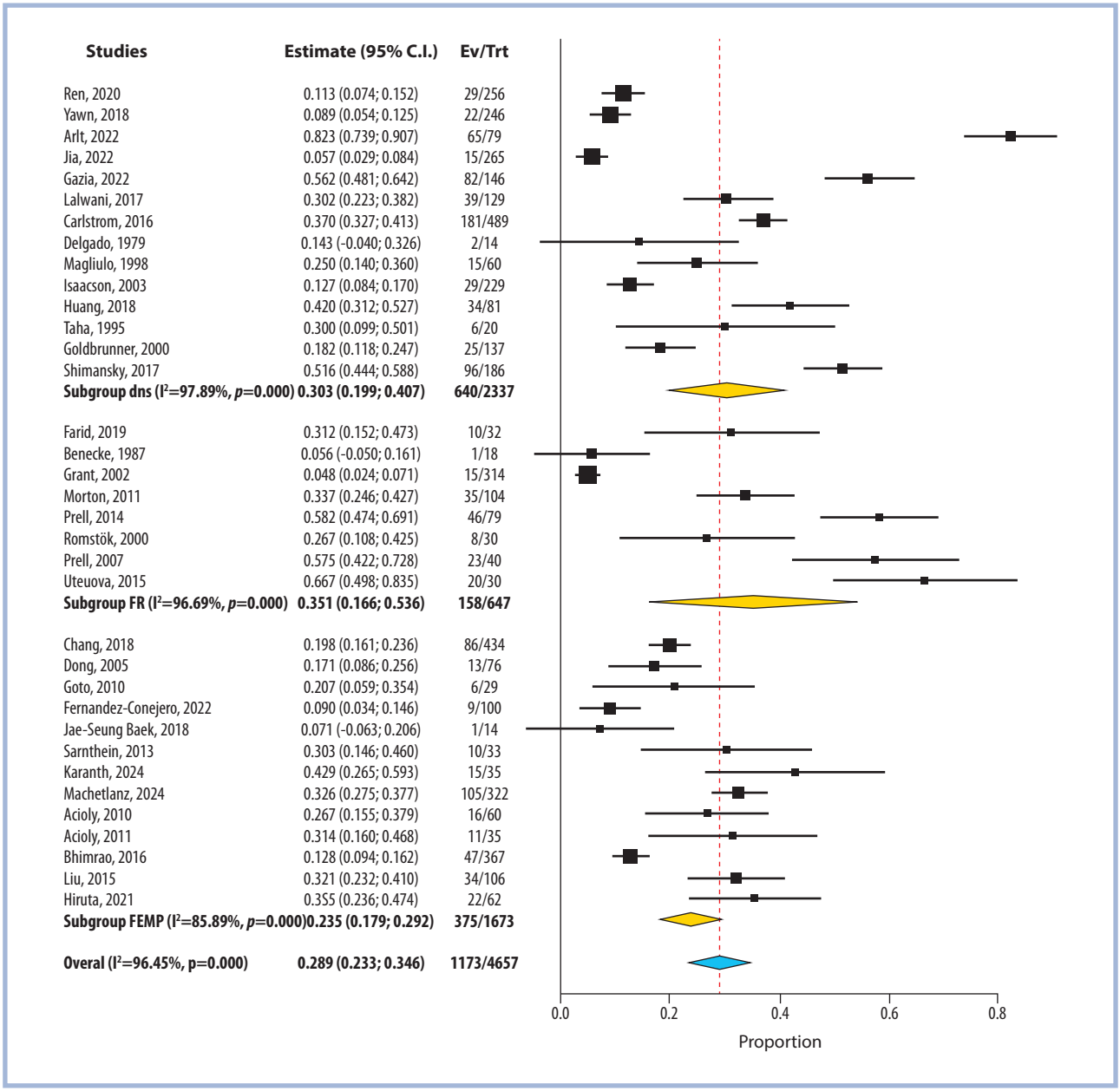

Fig. 2. **Incidence of postoperative facial neuropathy after microsurgical resection of CPA tumor.**
Black squares indicate the weighted effect size of each study (square size corresponds to study weights), black segments represent 95% confidence interval, yellow diamond represents the weighted mean for each subgroup, and blue diamond represents the pooled incidence of postoperative facial neuropathy.

We divided 35 articles into 3 subgroups:

1) DNS — CPA tumor resection under DNS;
2) FR — CPA tumor resection under DNS and continuous resting EMG monitoring;
3) FEMP — CPA tumor resection under multimodal IONM including DNS, continuous resting EMG monitoring and FEMP.

The pooled incidence of postoperative facial neuropathy after CPA tumor resection was 28.9% (95% CI 23.3—34.6) **(Fig. 2)**.

The incidence of early postoperative facial neuropathy in the DNS subgroup varied across studies from 5.7% (X.H. Jia et al., 2022) to 56.2% (F. Gazia et al., 2017) with significant heterogeneity (I^2=97.89%, p<0.001). The overall incidence rate was 30.3% (95% CI 19.9—40.7) **(Fig. 2)**.

The incidence of early postoperative facial neuropathy in the FR subgroup ranged from 4.8% (G.A. Grant et al., 2002) to 66.7% (S.A. Uteuova et al., 2015) with significant variability (I^2=96.69%, p<0.001). The overall incidence rate was 35.1% (95% CI: 16.6—53.6) **(Fig. 2)**.

The incidence of early postoperative facial nerve neuropathy in the FEMP subgroup ranged from 9% (I. Fernández-Conejero et al., 2022) to 42.9% (V.K. Karanth et al., 2024) with less variability (I^2=85.89%, p<0.001). The overall incidence was 23.5% (95% CI 17.9—29.2) **(Fig. 2)**.

Discussion

Since introduction of IONM in CPA tumor surgery, various neurophysiological techniques have been proposed to prevent intraoperative facial nerve damage.

Direct facial nerve stimulation is necessary for its identification during resection and assessment of its functional integrity at the end of surgery.

Resting EMG allows for control of continuous EMG activity recorded by needle electrodes in facial muscles to identify specific patterns called "A-trains". Increased number and duration of A-train recordings during tumor resection correlate with severity of postoperative facial neuropathy. However, false-positive A-train recordings were reported in patients with facial nerve splitting. In these cases, intermedius nerve innervating facial muscles passes separately from facial nerve within CPA, and facial nerve function remains intact despite large number of A-trains.

FEMP monitoring through TES was first proposed by C.C. Dong et al. in 2005. This procedure is valuable to assess integrity of the entire corticonuclear tract [30]. Importantly, FEMP monitoring may be performed throughout the entire resection in real time. This minimizes intraoperative damage to facial nerve and facilitates safe and maximal resection with predictable immediate postoperative results. Sensitivity of FEMP monitoring is 76%, specificity — 94% [32].

Thus, multimodal IONM allows for nerve identification, determination of direction and extent of resection, as we as continuous intraoperative monitoring of facial nerve function.

The overall incidence of postoperative facial neuropathy after CPA tumor resection was 28.9% (95% CI 23.3—34.6). It varied depending on IONM scenario. In case of multimodal IONM, the incidence decreased to 23.5% (95% CI 17.9—29.2) that indicated higher efficacy of this approach compared to DNS and/or resting EMG monitoring alone.

Significant heterogeneity between subgroups in the incidence of facial neuropathy (I^2=97.89% for DNS and 96.69% for FR) suggests that factors contributing to neuropathy can vary depending on techniques, qualifications of specialists and anatomical characteristics of patients. However, a more detailed analysis aimed at quantifying the contribution of each factor was not possible in this review.

Conclusion

Thus, multimodal intraoperative neurophysiological monitoring including direct nerve stimulation, monitoring of transcranial facial motor potentials and electromyography of facial muscles, allows for preservation of anatomical integrity and function of facial nerve. Results of meta-analysis highlight the need for further implementation and standardization of intraoperative neurophysiological monitoring scenarios to minimize postoperative complications.

Author contribution:
Concept and design of the study — Seliverstova E.G., Sinkin M.V., Grin A.A.
Collection and analysis of data — Seliverstova E.G.
Statistical analysis — Seliverstova E.G.
Writing — Seliverstova E.G.
Editing — Sinkin M.V., Grin A.A.

No conflict of interests to declare.

REFERENCES

1. Sarrazin J, Hélie O, Cordoliani Y. Tumeurs de l'angle ponto-cérébelleux chez l'adulte [Cerebellopontine angle tumors in adults]. *Journal de Radiologie.* 2000;81(6):675-690. (French).
2. Mehta NH, Patel RV, Gupta S, Arora H, Nawabi NL, Karanth R, Sadler S, Medeiros L, Jha R, Chavarro VS, Bernstock JD, Smith TR, Arnaout O. Cerebellopontine Angle Meningiomas: A Multi-Institutional Cohort Study. *Neurosurgery.* 2024;97(1):105-111. https://doi.org/10.1227/neu.0000000000003258
3. Mellouli M, Bahri I, Abid N, Boudawara A, Gouiaa N, Boudawara T. Une tumeur rare de l'angle pontocérébelleux [A rare tumor of the cerebellopontine angle]. *Annales de Pathologie.* 2014;34(6):482-484. (French). https://doi.org/10.1016/j.annpat.2014.09.006
4. Brackmann DE, Doherty JK. CPA melanoma: diagnosis and management. *Otology & Neurotology.* 2007;28(4):529-537. https://doi.org/10.1097/mao.0b013e3180383694
5. Moher D, Liberati A, Tetzlaff J, Altman DG; PRISMA Group. Preferred reporting items for systematic reviews and meta-analyses: the PRISMA statement. *PLoS Medicine.* 2009;6(7):e1000097. https://doi.org/10.1371/journal.pmed.1000097
6. Rebrova OYu, Fediaeva VK. The questionnaire to assess the risk of systematic bias in non-randomized comparative studies: the Russian-language version of the Newcastle-Ottawa scale. *Medical technologies. Assessment and choice.* 2016;3(25):14-19. (In Russ.).
7. Ren Y, MacDonald BV, Tawfik KO, Schwartz MS, Friedman RA. Clinical Predictors of Facial Nerve Outcomes After Surgical Resection of Vestibular Schwannoma. *Otolaryngology—Head and Neck Surgery.* 2021;164(5):1085-1093. https://doi.org/10.1177/0194599820961389
8. Yawn RJ, Dedmon MM, Xie D, Thompson RC, O'Malley MR, Bennett ML, Rivas A, Haynes DS. Delayed Facial Nerve Paralysis after Vestibular Schwannoma Resection. *Journal of Neurological Surgery Part B: Skull Base.* 2018;80(3):283-286. https://doi.org/10.1055/s-0038-1669941
9. Arlt F, Kasper J, Winkler D, Jähne K, Fehrenbach MK, Meixensberger J, Sander C. Facial Nerve Function After Microsurgical Resection in Vestibular Schwannoma Under Neurophysiological Monitoring. *Frontiers in Neurology.* 2022;13:850326. https://doi.org/10.3389/fneur.2022.850326
10. Jia XH, Gao Z, Lin NE, Yuan YS, Zhao WD. Delayed Facial Nerve Paralysis After Vestibular Schwannoma Resection. *World Neurosurgery.* 2023;170:e431-e435. https://doi.org/10.1016/j.wneu.2022.11.036
11. Gazia F, Callejo À, Pérez-Grau M, Lareo S, Prades J, Roca-Ribas F, Amilibia E. Pre- and intra-operative prognostic factors of facial nerve function in cerebellopontine angle surgery. *European Archives of Oto-Rhino-Laryngology.* 2023;280(3):1055-1062. https://doi.org/10.1007/s00405-022-07556-8

12. Lalwani AK, Butt FY, Jackler RK, Pitts LH, Yingling CD. Facial nerve outcome after acoustic neuroma surgery: a study from the era of cranial nerve monitoring. *Otolaryngology—Head and Neck Surgery.* 1994;111(5):561-570. https://doi.org/10.1177/019459989411100505
13. Carlstrom LP, Copeland WR 3rd, Neff BA, Castner ML, Driscoll CL, Link MJ. Incidence and Risk Factors of Delayed Facial Palsy After Vestibular Schwannoma Resection. *Neurosurgery.* 2016;78(2):251-525. https://doi.org/10.1227/NEU.0000000000001015
14. Delgado TE, Bucheit WA, Rosenholtz HR, Chrissian S. Intraoperative monitoring of facila muscle evoked responses obtained by intracranial stimulation of the facila nerve: a more accurate technique for facila nerve dissection. *Neurosurgery.* 1979;4(5):418-421. https://doi.org/10.1227/00006123-197905000-00007
15. Magliulo G, Sepe C, Varacalli S, Crupi J. Acoustic neuroma surgery and delayed facial palsy. *European Archives of Oto-Rhino-Laryngology.* 1998;255(3):124-126. https://doi.org/10.1007/s004050050026
16. Isaacson B, Kileny PR, El-Kashlan H, Gadre AK. Intraoperative monitoring and facial nerve outcomes after vestibular schwannoma resection. *Otology & Neurotology.* 2003;24(5):812-817. https://doi.org/10.1097/00129492-200309000-00020
17. Huang X, Ren J, Xu J, Xu M, Chen D, Chen M, Ji K, Wang H, Chen H, Cao L, Shao Y, Zhong P, Ballena R, Zhou L, Mao Y. The utility of «low current» stimulation threshold of intraoperative electromyography monitoring in predicting facial nerve function outcome after vestibular schwannoma surgery: a prospective cohort study of 103 large tumors. *Journal of Neuro-Oncology.* 2018;138(2):383-390. https://doi.org/10.1007/s11060-018-2806-8
18. Taha JM, Tew JM Jr, Keith RW. Proximal-to-distal facial amplitude ratios as predictors of facial nerve function after acoustic neuroma excision. *Journal of Neurosurgery.* 1995;83(6):994-998. https://doi.org/10.3171/jns.1995.83.6.0994
19. Goldbrunner RH, Schlake HP, Milewski C, Tonn JC, Helms J, Roosen K. Quantitative parameters of intraoperative electromyography predict facial nerve outcomes for vestibular schwannoma surgery. *Neurosurgery.* 2000;46(5):1140-1146; discussion 1146-1148. https://doi.org/10.1097/00006123-200005000-00023
20. Shimansky VN, Shevchenko KV, Tanyashin SV, Shulgina AA, Poshataev VK, Odamanov DA, Karnaukhov VV. Postoperative outputs in function of the facial nerve depending on topography of auditory nerve neurinoma. *Sibirskoe medicinskoe obozrenie.* 2017;6:104-109. (In Russ.). https://doi.org/10.20333/2500136-2017-6-104-109
21. Farid AM, Elkholy AR. Preservation of facial nerve functions during vestibular schwannoma surgery: outcome analysis. *Egyptian Journal of Neurosurgery.* 2019;34:25. https://doi.org/10.1186/s41984-019-0051-x
22. Benecke JE Jr, Calder HB, Chadwick G. Facial nerve monitoring during acoustic neuroma removal. *Laryngoscope.* 1987;97(6):697-700. https://doi.org/10.1288/00005537-198706000-00009
23. Grant GA, Rostomily RR, Kim DK, Mayberg MR, Farrell D, Avellino A, Duckert LG, Gates GA, Winn HR. Delayed facial palsy after resection of vestibular schwannoma. *Journal of Neurosurgery.* 2002;97(1):93-96. https://doi.org/10.3171/jns.2002.97.1.0093
24. Morton RP, Ackerman PD, Pisansky MT, Krezalek M, Leonetti JP, Raffin MJ, Anderson DE. Prognostic factors for the incidence and recovery of delayed facial nerve palsy after vestibular schwannoma resection. *Journal of Neurosurgery.* 2011;114(2):375-380. https://doi.org/10.3171/2010.5.JNS091854
25. Prell J, Rampp S, Romstöck J, Fahlbusch R, Strauss C. Train time as a quantitative electromyographic parameter for facial nerve function in patients undergoing surgery for vestibular schwannoma. *Journal of Neurosurgery.* 2007;106(5):826-832. https://doi.org/10.3171/jns.2007.106.5.826
26. Romstöck J, Strauss C, Fahlbusch R. Continuous electromyography monitoring of motor cranial nerves during cerebellopontine angle surgery. *Journal of Neurosurgery.* 2000;93(4):586-593. https://doi.org/10.3171/jns.2000.93.4.0586
27. Prell J, Strauss C, Rachinger J, Alfieri A, Scheller C, Herfurth K, Rampp S. Facial nerve palsy after vestibular schwannoma surgery: dynamic risk-stratification based on continuous EMG-monitoring. *Clinical Neurophysiology.* 2014;125(2):415-421. https://doi.org/10.1016/j.clinph.2013.07.015
28. Uteuova SA, Zhumadildina AZh, Maul YaYa. Experince of using intraoperation neuromonitoring in cerebellopontine angle tumor surgery. *Neurosurgery and Neurology of Kazakhstan.* 2015;1(38):29-33. (In Russ.).
29. Chang S, Makarenko S, Despot I, Dong C, Westerberg BD, Akagami R. Differential Recovery in Early- and Late-Onset Delayed Facial Palsy Following Vestibular Schwannoma Resection. *Operative Neurosurgery.* 2020;18(1):34-40. https://doi.org/10.1093/ons/opz083
30. Dong CC, Macdonald DB, Akagami R, Westerberg B, Alkhani A, Kanaan I, Hassounah M. Intraoperative facial motor evoked potential monitoring with transcranial electrical stimulation during skull base surgery. *Clinical Neurophysiology.* 2005;116(3):588-596. https://doi.org/10.1016/j.clinph.2004.09.013
31. Goto T, Muraoka H, Kodama K, Hara Y, Yako T, Hongo K. Intraoperative Monitoring of Motor Evoked Potential for the Facial Nerve Using a Cranial Peg-Screw Electrode and a «Threshold-level» Stimulation Method. *Skull Base.* 2010;20(6):429-434. https://doi.org/10.1055/s-0030-1261270
32. Fernández-Conejero I, Ulkatan S, Sen C, Miró Lladó J, Deletis V. Intraoperative monitoring of facial corticobulbar motor evoked potentials: Methodological improvement and analysis of 100 patients. *Clinical Neurophysiology.* 2022;142:228-235. https://doi.org/10.1016/j.clinph.2022.08.006
33. Baek JS, Park SK, Kim DJ, Park CW, Lim SH, Lee JH, Cho YK. Facial Motor Evoked Potential Techniques and Functional Prediction during Cerebello-pontine Angle Surgery. *The Korean Journal of Clinical Laboratory Science.* 2018;50:470-476. https://doi.org/10.15324/kjcls.2018.50.4.470
34. Sarnthein J, Hejrati N, Neidert MC, Huber AM, Krayenbühl N. Facial nerve motor evoked potentials during skull base surgery to monitor facial nerve function using the threshold-level method. *Neurosurgical Focus.* 2013;34(3):E7. https://doi.org/10.3171/2012.12.FOCUS12386
35. Karanth VK, Yerragunta T, Sampath N, Yerramneni V, Kanala R, Kumar EP, Govindaraj A. Multimodal intraoperative neurophysiological monitoring with special emphasis on facial MEPs for facial nerve preservation in vestibular schwannoma surgeries: Surgical nuances and outcome predictability. *Indian Journal of Physiology and Pharmacology.* 2024;68:118-125. https://doi.org/10.25259/IJPP_77_2024
36. Machetanz K, Roegele M, Liebsch M, Oberle L, Weinbrenner E, Gorbachuk M, Wang SS, Tatagiba M, Naros G. Predictive value of facial motor-evoked potential and electromyography for facial motor function in vestibular schwannoma surgery. *Acta Neurochirurgica.* 2024;166(1):23. https://doi.org/10.1007/s00701-024-05927-0
37. Acioly MA, Liebsch M, Carvalho CH, Gharabaghi A, Tatagiba M. Transcranial electrocortical stimulation to monitor the facial nerve motor function during cerebellopontine angle surgery. *Neurosurgery.* 2010;66(6):354-361; discussion 362. https://doi.org/10.1227/01.neu.0000369654.41677.b7
38. Acioly MA, Gharabaghi A, Liebsch M, Carvalho CH, Aguiar PH, Tatagiba M. Quantitative parameters of facial motor evoked potential during vestibular schwannoma surgery predict postoperative facial nerve function. *Acta Neurochirurgica.* 2011;153(6):1169-1179. https://doi.org/10.1007/s00701-011-0995-4
39. Bhimrao SK, Le TN, Dong CC, Makarenko S, Wongprasartsuk S, Westerberg BD, Akagami R. Role of Facial Nerve Motor-Evoked Potential Ratio in Predicting Facial Nerve Function in Vestibular Schwannoma Surgery Both Immediate and at 1 Year. *Otology & Neurotology.* 2016;37(8):1162-1167. https://doi.org/10.1097/MAO.0000000000001137
40. Liu SW, Jiang W, Zhang HQ, Li XP, Wan XY, Emmanuel B, Shu K, Chen JC, Chen J, Lei T. Intraoperative neuromonitoring for removal of large vestibular schwannoma: Facial nerve outcome and predictive factors. *Clinical Neurology and Neurosurgery.* 2015;133:83-89. https://doi.org/10.1016/j.clineuro.2015.03.016
41. Hiruta R, Sato T, Itakura T, Fujii M, Sakuma J, Bakhit M, Kojima T, Ichikawa M, Iwatate K, Saito K. Intraoperative transcranial facial motor evoked potential monitoring in surgery of cerebellopontine angle tumors predicts early and late postoperative facial nerve function. *Clinical Neurophysiology.* 2021;132(4):864-871. https://doi.org/10.1016/j.clinph.2020.12.025

Received 28.01.2025
Reviced 14.07.2025
Accepted 26.11.2025