Burdenko's Journal of Neurosurgery
2026, No. 1, pp. 92–99
https://doi.org/10.17116/neiro20269001192

Giant cavernous malformation of the genu of the corpus callosum

© K.A. CHIZHOVA[1], R.R. MAVLYUTOVA[1], V.M. VINNIKOV[1], I.YU. BELOV[1, 2], D.A. GULYAEV[1, 2]

[1]Almazov National Medical Research Centre, St. Petersburg, Russia;
[2]Petrov National Medical Research Centre of Oncology, St. Petersburg, Russia

ABSTRACT
Cavernous malformations of the corpus callosum are rare accounting for less than 1% of all subtentorial cavernous malformations. Clinical manifestations are usually caused by hemorrhage into adjacent parenchyma. Epileptic seizures are the most common. Multiple hemorrhages with progressive neurological impairment require surgical intervention.
Objective. To present giant cavernoma of the genu of the corpus callosum extending to the fornix, basal frontal lobes and bottom of the third ventricle, as well as review of available literature.
Results. A patient with giant cavernous malformation of the genu of the corpus callosum extending to the fornix, basal frontal lobes and bottom of the third ventricle underwent total resection of malformation. Symptoms included headaches, epileptic seizures, and hydrocephalus. Korsakoff syndrome developed after surgery and partially regressed at discharge. After 3 months, hydrocephalus completely regressed. Elements of Korsakoff syndrome persisted with improvements under rehabilitation sessions with neuropsychologist.
Conclusion. Despite difficult anatomical location and giant size, total resection of cavernous malformation provided satisfactory outcome with minimal neurological complications.

Keywords: *cavernous malformation, genu of the corpus callosum, epileptic seizures, biventricular hydrocephalus, Korsakoff syndrome.*

INFORMATION ABOUT THE AUTHORS:
Chizhova K.A. — https://orcid.org/0000-0002-7443-0500
Mavlyutova R.R. — https://orcid.org/0009-0001-6266-5898
Vinnikov V.M. — https://orcid.org/0009-0001-9214-6335
Belov I.Yu. — https://orcid.org/0000-0003-2473-2671
Gulyaev D.A. — https://orcid.org/0000-0002-5509-5612
Corresponding author: Chizhova K.A. — e-mail: k.a.chizhova98@gmail.com

TO CITE THIS ARTICLE:
Chizhova KA, Mavlyutova RR, Vinnikov VM, Belov IYu, Gulyaev DA. Giant cavernous malformation of the genu of the corpus callosum. *Burdenko's Journal of Neurosergery*. 2026;90(1):92–99. (In Russ.). https://doi.org/10.17116/neiro20269001192

Abbreviations

CM — cavernous malformation

Introduction

CMs are low-flow vascular malformations consisting of dilated cavities (caverns) with endothelial walls [1]. The prevalence of CMs is approximately 0.5% (0.2—0.9%), but most cases (up to 70%) are asymptomatic [2, 3]. Clinical manifestations are various and depend on location of malformation in the central nervous system. Symptoms are most often due to hemorrhage into adjacent parenchyma. According to the literature, the annual risk of bleeding from CMs reaches 3%, and the risk of recurrent bleeding is 4.5—23% per year [4]. Epileptic seizures are the most common manifestation [5]. CMs can be located in any part of the central nervous system. CMs of the corpus callosum are rare and account for <1% of all supratentorial CMs [6]. Resection of these CMs, like other deep-seated CMs, presents certain difficulties. However, surgery may be justified in patients with clinical and radiographic evidence of disease progression.

The purpose of this study was to demonstrate successful total resection of giant CM of the corpus callosum extending into the columns of the fornix, basal frontal lobes and bottom of the third ventricle. The patient had long history of progressive symptoms due to repeated hemorrhages with biventricular obstructive hydrocephalus.

A 41-year-old patient (foreign language teacher) noted daily intense bursting headaches in November 2011. Head MRI revealed tumor of the genu of the corpus callosum 35×27×29 mm with surrounding hemosiderin deposits and areas of hemorrhage. In February 2012, the patient admitted to the Burdenko Neurosurgery Center, where

stereotactic biopsy revealed CM with perifocal hemorrhage. After comprehensive analysis of diagnostic data, the team of specialists did not recommend surgical treatment due to high risk of complications.

There was subsequent remittent progression of disease. In 2018, headache attack was complicated by a generalized epileptic seizure lasting approximately 10 min. She was hospitalized in neurosurgical department. CT of the brain was performed upon admission, and follow-up with anticonvulsant therapy (valproic acid 600 mg daily) was recommended. The drug was discontinued after 6 months due to no epileptic seizures. In 2018, the patient was advised to continue follow-up due to high risk of perioperative complications. In October 2023, MRI revealed significant enlargement of malformation up to 48×34×33 mm with signs of multiple hemorrhages.

In January 2024, daily hypertensive headaches recurred. They were poorly controlled by nonsteroidal anti-inflammatory drugs and accompanied by nausea. MRI revealed signs of another subacute hemorrhage, as well as occlusive biventricular hydrocephalus. The patient admitted to municipal hospital, where ventriculoperitoneal shunting was performed at Dandy points on both sides (Medtronic medium-pressure system). Hypertension syndrome regressed after surgery. Postoperative CT revealed that the tip of the left ventricular catheter was located extraventricularly in basal ganglia. Therefore, reimplantation of the left ventricular catheter was carried out. A month later, CT showed shrinkage of lateral ventricles, but headaches persisted. Three months after surgery (April 2024), the patient developed fistula within the shunt valve pump in the right occipital region. Therefore, valve reimplantation in the left occipital region and excision of fistula in the right occipital region were performed in municipal hospital.

In June 2024, the patient presented to the Almazov National Medical Research Center. Considering progressive course of disease and multiple hemorrhages, surgical treatment was recommended. MRI upon admission **(Fig. 1)** revealed giant irregularly shaped CM extending to the genu of the corpus callosum, frontal lobes, septum pellucidum and bottom of the third ventricle.

CM measured 47×36×40 mm and compressed anterior parts of the third ventricle and anterior horns of lateral ventricles at the level of the foramina of Monro. There were asymmetrical lateral ventricles (D<S), enlarged left lateral ventricle and slit-like third ventricle displaced to the right. Upon admission, neurological status included emotional-affective disturbances (anxiety) and hypertensive headaches.

On June 13, 2024, microsurgical resection of CM was performed **(Fig. 2)**. After standard left-sided anterior interhemispheric approach, we visualized cavernous malformation consisted of pathological, thin-walled, deformed venous vessels and fragments of scarred tissue. CM was surrounded by yellowish-gray and brown brain tissue with signs of multiple hemorrhages. The malformation involved the genu and the rostrum of the corpus callosum, as well as columns of the fornix. CM extended into posterobasal parts of frontal lobes. Microsurgical resection of CM was performed along the border with visually intact brain matter. Content of CM vessels included venous blood, grayish-brown oily fluid and whitish-gray pasty masses. Many caverns were connected to anterior septal veins of both lateral ventricles. We intraoperatively visualized both foramina of Monro displaced posteriorly and compressed by malformation. Anterior communicating artery-anterior cerebral artery complex and left internal carotid artery were intact after resection of malformation.

Korsakoff syndrome occurred after surgery with the most severe symptoms in the first three days. Fixation amnesia prevailed. Amnesia partially regressed at discharge. We assessed preoperative and postoperative cognitive and emotional-affective impairments using the following scales: Montreal Cognitive Assessment (MoCA), Frontal Assessment Battery (FAB), Hospital Anxiety and Depression Scale (HADS), Number Connection Test A and B **(Table)**. There were preoperative mild cognitive impairment and severe anxiety. Postoperatively, deterioration of these parameters was most pronounced on the first postoperative day, but they almost returned to preoperative data by the third day with the exception of the HADS scores **(Fig. 3)**.

The patient was discharged on the 11th postoperative day. Follow-up examination 3 months after surgery revealed persistent elements of Korsakoff syndrome with improvements following rehabilitation sessions with a neuropsychologist.

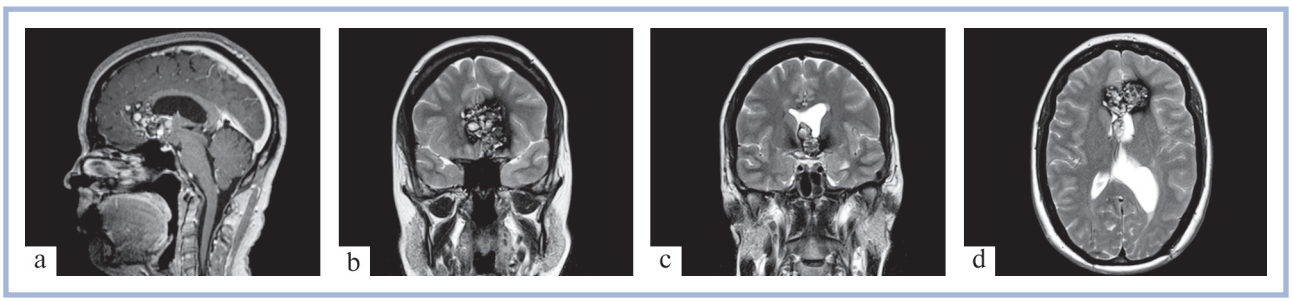

Fig. 1. **Contrast-enhanced MRI upon admission.**
a — sagittal contrast-enhanced T1WI, cavernous malformation of the corpus callosum extending to the columns of the fornix, basal frontal lobes and bottom of the third ventricle; b-d — T2WI, occlusion of anterior horns of lateral ventricles by cavernous malformation.

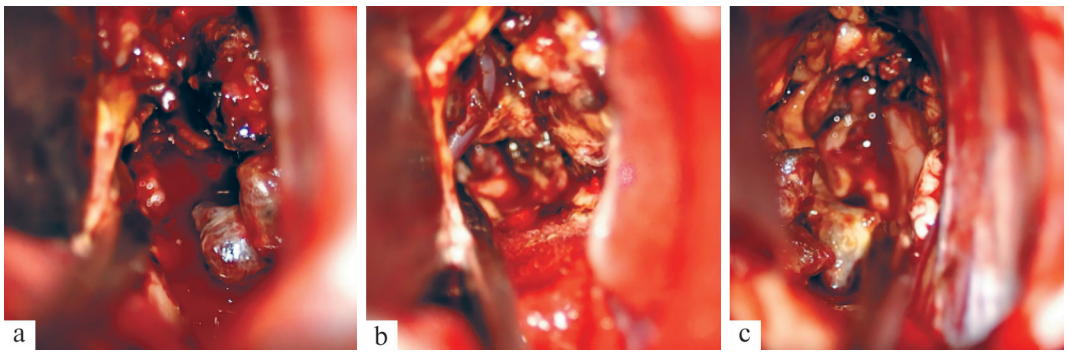

Fig. 2. **Resection of cavernous malformation of the genu of the corpus callosum. Intraoperative images.**
a — some caverns forming the genu of the corpus callosum are removed; the largest caverns are visible on the right side of the wound; b — left anterior septal vein is visualized during subsequent dissection, bottom of the third ventricle is visible deep in the wound; c — cavity represented by anterior horns of lateral ventricles and third ventricle after resection; some caverns located most laterally are visualized on the left.

Assessment criteria for the MoCa, HADS, FAB, TMAa and TMAb scales

MoCA	Norm	Mild cognitive impairment	Moderate cognitive impairment	Severe cognitive impairment
scores	26—30	18—25	10—17	<10
FAB	Norm	Moderate dysfunction	Signs of dementia	
scores	16—18	12—15	<11	
HADS	Norm	Subclinical anxiety or depression	Severe anxiety or depression	
scores	0—7	8—10	>11	
TMAa	Norm (average result)	Deficit		
seconds	29	>78		
TMAb	Norm (average result)	Deficit		
seconds	75	>273		

The patient did not return to work. However, we believe the prospects for full recovery are quite high considering high compliance and positive coping strategies (mRS score 2 in 3 months after surgery). Follow-up MRI revealed no residual CM, and hydrocephalus completely regressed **(Fig. 4)**.

Discussion

CMs of the corpus callosum are rare. In the literature, this disease is described in case reports or small case series. Reyns N. et al. [7] described the earliest case in 1999. In 2001, Harada S. et al. [8] reported CM of the genu of the corpus callosum with vertigo, and Zacharia T.T. et al. [9] presented combination of the same localization with CM of the spinal cord. Three more cases were published over the next 10 years [10—12]. In 2011, Chang E.F. et al. [13] presented a small series of 10 patients. In 2014, Pavesi G. et al. [14] described small CM of the middle third of corpus callosum manifested by acute delirium with fantastic content. One case report is devoted to CM of the middle third of the corpus callosum in a patient with Klippel-Trenaunay syndrome [15]. In Russian literature, Belousova O.B. et al. [16] described CM of the corpus callosum.

Despite high incidence of epileptic seizures in patients with CM, only three cases with this course were described among patients with CM of the corpus callosum [17—20]. Mechanisms of epilepsy in patients with lesions of the corpus callosum are not fully understood. Appropriate neoplasms can extend to cingulate gyrus, and epileptic discharge can reach temporal cortex from this region [17, 20]. Repeated hemorrhages and hemosiderin deposits in surrounding tissue are also important [6]. Interestingly, the genu of the corpus callosum is the main pathway for spread of secondarily generalized seizures. According to the literature, cortical lesions associated with the genu of the corpus callosum are significantly more likely to be associated with generalized epilepsy [20, 21].

In this case, further seizures were prevented by anticonvulsant therapy. However, this was not the main factor in clinical presentation. Repeated multiple hemorrhages led to progressive CM enlargement and biventricular hydrocephalus that required resection.

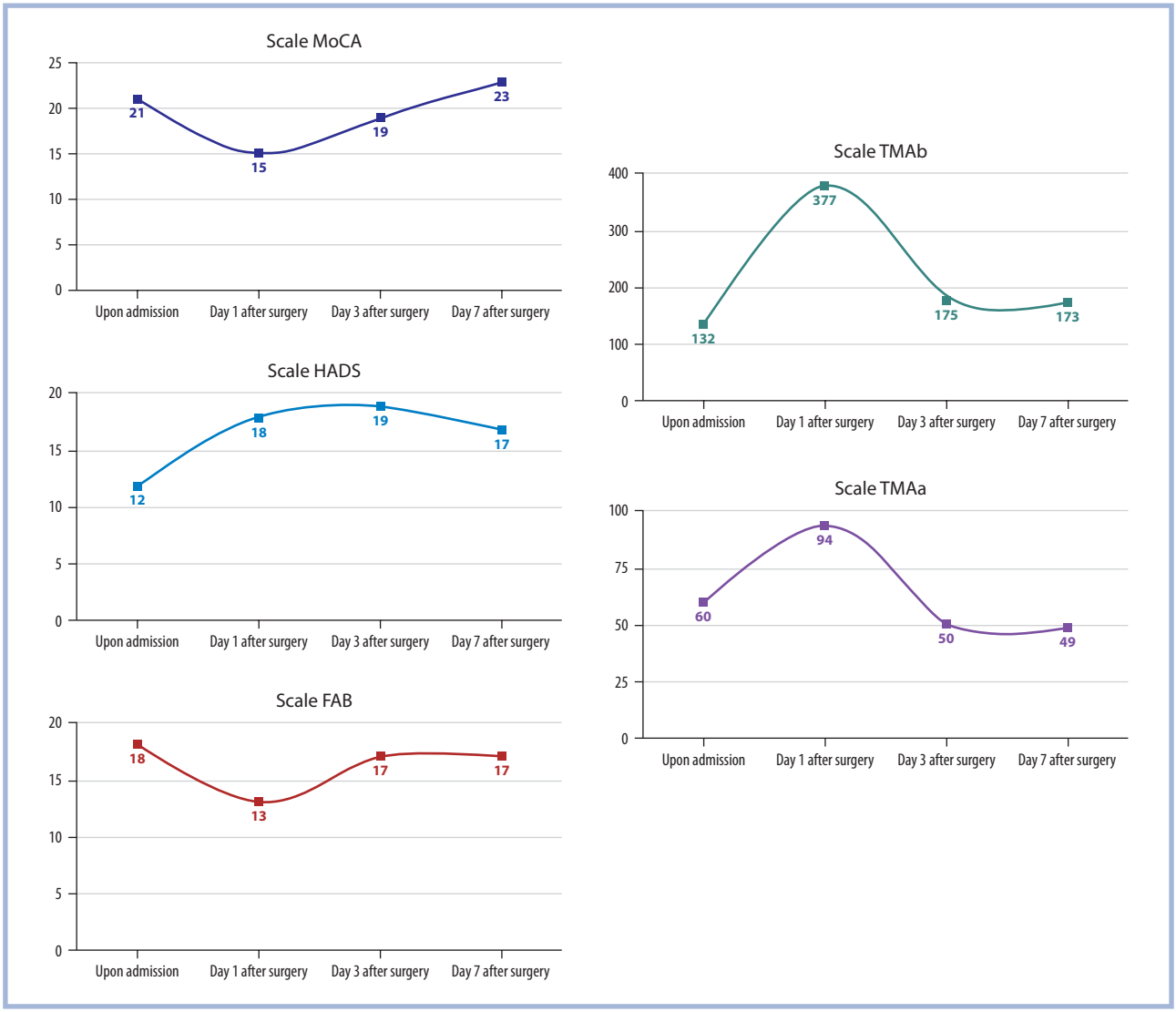

Fig. 3. **MoCA, HADS, FAB, TMAa, and TMAb scores preoperatively and in early postoperative period (days 1, 3, and 7 postoperatively).**

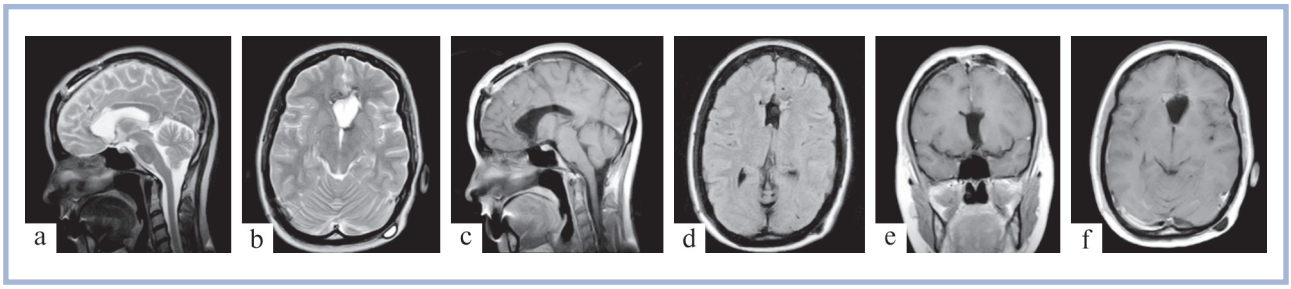

Fig. 4. **Contrast-enhanced MRI after 3 postoperative months.**
a, b — sagittal and axial T2WI; c—f — sagittal, coronal, axial contrast-enhanced T1WI. No remnants of cavernous malformation are detected.

Postoperative period was complicated by Korsakoff syndrome with fixation amnesia, impaired memory of sequence of events, confabulations and anamnestic disorientation. Retrograde and antegrade amnesia is also possible [22]. In neurosurgical practice, this syndrome was described in surgical interventions for neoplasms involving mammillary bodies, tumors with bilateral fornix involvement, and infarction of thalamus and mammillothalamic fasciculus [23—27]. In 2024, Mazzacane F. et al. [28] published the largest systematic review of amnestic syndrome following damage to fornix columns. Interestingly, bilateral damage was detected in majority of patients

(48/55, 87%), and almost half of the patients had involvement of the corpus callosum (23/55, 42%). Fornix columns are simultaneously commissural, association and projection tracts. They mainly consist of fibers coming from hippocampal region. This area is essential in the Papez circuit and central for organization of memory storage [29]. Fornix columns, as a part of this hippocampal-diencephalic system, contribute to efficient encoding and recall of new episodic information [30—31]. Thus, bilateral lesions of limbic system components can cause significant memory impairments, whose severity depends on extent of damage. In our opinion, surgical intervention in our patient could contribute to amnestic syndrome considering no clear MR and intraoperative visualization of fornix columns due to extensive spread of CM.

Conclusion

This case of giant cavernous malformation of the genu of the corpus callosum demonstrates difficult treatment of this rare disease. Multiple hemorrhages led to CM enlargement with biventricular hydrocephalus that required surgical intervention. Microsurgical resection of cavernous malformation, despite complex anatomical location, provided favorable outcome with minimal neurological complications. The main complication was Korsakoff syndrome. However, the patient demonstrated positive cognitive dynamics in follow-up. Total resection of malformation and regression of hydrocephalus confirm successful treatment, and surgical resection of cavernoma appears reasonable.

Author contribution:
Concept and design of the study — Chizhova K.A., Vinnikov V.M.
Data collection and analysis — Chizhova K.A., Mavlyutova R.R.
Writing — Chizhova K.A., Mavlyutova R.R.
Editing — Vinnikov V.M., Belov I.Yu., Gulyaev D.A.

No conflict of interests to declare.

COMMENT

The authors present resection of giant cavernous malformation of the corpus callosum and mediobasal frontal lobes extending into septum pellucidum and bottom of the third ventricle. CM was completely removed with minimal tissue defects as evidenced by MRI data 3 months after surgery. However, as expected with such a location, the patient developed severe psychopathological symptoms after surgery. Despite partial regression, appropriate symptoms persisted 3 months after the procedure. The risk of such symptoms inspired refusal of surgery at the Burdenko Neurosurgery Center in 2012 and 2018. However, progression of disease in a young woman with CM enlargement, recurrent hemorrhages and hydrocephalus undoubtedly required more aggressive treatment strategy. This case demonstrates difficult decision-making in treating patients with deep-seated CMs of functionally significant brain areas, as well as the need for follow-up of patients with this seemingly benign disease. Perhaps, earlier surgery would have had a more favorable outcome.

Belousova O.B. (Moscow)