Burdenko's Journal of Neurosurgery
2025, No. 5, pp. 5–15
https://doi.org/10.17116/neiro2025890515

The one-line principle in classification of cerebral aneurysm clipping

© YU.V. PILIPENKO[1], SH.SH. ELIAVA[1], D.N. OKISHEV[1], AN.N. KONOVALOV[1, 2], A.S. KHEYREDDIN[1], M.B. KHOLMATOV[1], F.V. GREBENEV[1, 2], A.A. ABRAMYAN[3]

[1]Burdenko Neurosurgical Center, Moscow, Russia;
[2]Sechenov First Moscow State Medical University, Moscow, Russia;
[3]Rutgers University, New Brunswick, NJ, USA

ABSTRACT

Despite numerous clipping techniques, a standardized classification based on a single unifying principle remains absent.

Objective. To develop a classification of clipping methods based on the one-line principle.

Material and Methods. The classification was developed based on studies by Ishikawa T. et al., who introduced the «ideal closure line» for aneurysm clipping. We analyzed 678 cases of reconstructive clipping of cerebral aneurysms performed at the 3rd Neurosurgical Department of the Burdenko Neurosurgical Center between September 1, 2024, and December 29, 2024.

Results. Reconstructive clipping methods for cerebral aneurysms, based on the one-line principle, were categorized into eight types. Clipping along a one line without segmenting the aneurysm neck, including simple single clipping, simple reinforced clipping, and clipping with tunneling of the efferent artery, was performed in the majority of cases (58.5%). Linear fragmented clipping of individual aneurysm neck segments, including tandem, counter, and cross techniques, tunneling of the parent artery, perpendicular clipping, and combined clipping, was performed in 39.8% of cases. Discrete fragmented clipping with multiple lines of aneurysm neck clamping was used in only 1.8% of cases.

Conclusion. We developed a novel classification of aneurysm clipping based on the one-line principle. This classification primarily serves scientific purposes, facilitating the evaluation of clinical and angiographic outcomes of various clipping methods across different topographic and morphological variants of cerebral aneurysms.

Keywords: *classification of clipping, cerebral aneurysms.*

INFORMATION ABOUT THE AUTHORS:
Pilipenko Yu.V. — https://orcid.org/0000-0003-4001-3212
Eliava Sh.Sh. — https://orcid.org/0000-0001-6103-9329
Okishev D.N. — https://orcid.org/0000-0003-0815-5624
Konovalov An.N. — https://orcid.org/0000-0002-0932-4752
Kheyreddin A.S. — https://orcid.org/0000-0002-6395-2055
Kholmatov M.B. — https://orcid.org/0000-0001-9916-722X
Grebenev F.V. — https://orcid.org/0000-0003-2622-7804
Abramyan A.A. — https://orcid.org/0000-0003-2642-7590
Corresponding author: Pilipenko Yu.V. — e-mail: 3664656@mail.ru

TO CITE THIS ARTICLE:
Pilipenko YuV, Eliava ShSh, Okishev DN, Konovalov AnN, Kheyreddin AS, Kholmatov MB, Grebenev FV, Abramyan AA. The one-line principle in classification of cerebral aneurysm clipping. *Burdenko's Journal of Neurosurgery*. 2025;89(5):5–15. (In Russ.). https://doi.org/10.17116/neiro2025890515

Introduction

Various clipping techniques and vascular clips have been developed since W.E. Dandy performed the first cerebral aneurysm clipping in 1937 [1].

Surgery for cerebral aneurysms is divided into two groups: deconstructive (with parent artery sacrifice) and reconstructive (with parent artery preservation) [2, 3].

Deconstructive procedures are classified into three types: trapping, proximal clipping, and distal clipping [4—6]. Artery sacrifice, with or without revascularization, is more commonly used for large partially thrombosed fusiform aneurysms, when the risk of clipping with parent artery preservation is high.

Reconstructive clipping is typically performed for saccular aneurysms. There are many different techniques. The following terms are part of the neurosurgical nomenclature. Aneurysm neck clipping with a single clip is termed “single” [7], “conventional” [8], “direct” [9], “standard” [10], or “simple” [11]. If procedure

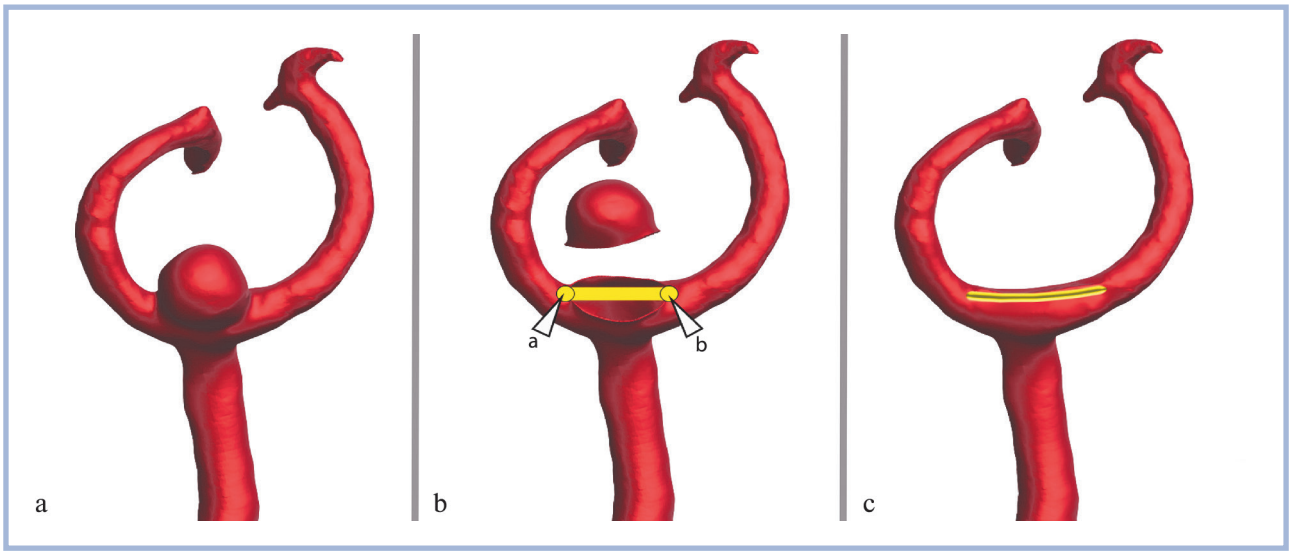

***Fig.* 1. Single clip application along the maximum length of the aneurysm neck.**
a — classic bifurcation aneurysm; b — virtual excision of aneurysm dome for visualization of arterial wall defect. Segment ab corresponds to maximum length of the aneurysm neck; c — defect closure line after applying one clip along the axis of the efferent arteries.

with a single clip is not feasible, the clipping is referred to as "multiple"[1], "complex" [12], "with lumen reconstruction" [13], or "with lumen remodeling" [14].

Ishikawa et al. [15] introduced the concept of the "ideal closure line" for clipping of middle cerebral artery bifurcation aneurysms. Adherence to the principle of clipping along the ideal line is intended to prevent residual aneurysms.

We identified no classification of reconstructive clipping techniques for all topographic aneurysm variants based on a unified principle.

The objective of this study was to develop a classification of aneurysm clipping based on one-line principle.

Material and methods

We analyzed 678 cases of reconstructive cerebral aneurysm clipping at the 3rd neurosurgical department (Burdenko Neurosurgery Center) between January 9, 2024 and December 29, 2024.

Rationale for the one-line principle

Blood fills the aneurysm cavity through arterial wall defect. The purpose of clipping is to repair the wall defect, thereby preventing blood flow into the aneurysm.

A clip applied to the aneurysm neck compresses it, forming a line at the point where its blades meet. The arterial walls at the aneurysm neck are aligned along the closure line. The curvature and length of the closure line depend on the size of the aneurysm neck and the number of arterial branches involved.

Arteries associated with the aneurysm are classified as afferent (parent) or efferent (outflow) vessels. In aneurysms away from the bifurcation, the configuration of the closure line follows the curvature of the parent artery. In bifurcation aneurysms, closure line curvature may be determined by curvature of the parent and efferent arteries.

Clipping the maximum length of the aneurysm neck is critical to eliminate residual filling **(Fig. 1)**.

In some cases, a single clip cannot fully close the wall defect across its entire length. Therefore, multiple clips placed on targeted segments of the aneurysm neck can be used to completely isolate the aneurysm. In such a situation, the fragmented clipping definition, as proposed by Sekhar et al. [16], is considered appropriate. Fragmented clipping is typically performed along a one-line, which may be straight, curved, or angulated. An angulated closure line requires the exclusion of the aneurysm using clips placed on different segments of the aneurysm neck **(Fig. 2)**.

Results

For the clipping of 678 cerebral aneurysms, 1193 clips were applied, resulting in a mean of 1.8±1.0 clips per aneurysm. Clipping methods and aneurysm localization are presented in the **Table**. We have previously described clinical outcomes in these patients [17].

One-line clipping without dividing the aneurysm neck into segments, including simple single clipping, simple reinforced clipping, and clipping with tunneling of the efferent artery, was performed in the majority of cases (58.5%). In 39.8% of cases, fragmented clipping was per-

[1] Lawton MT. *Seven Aneurysms: Tenets and Techniques for Clipping.* New York: Thieme; 2010.

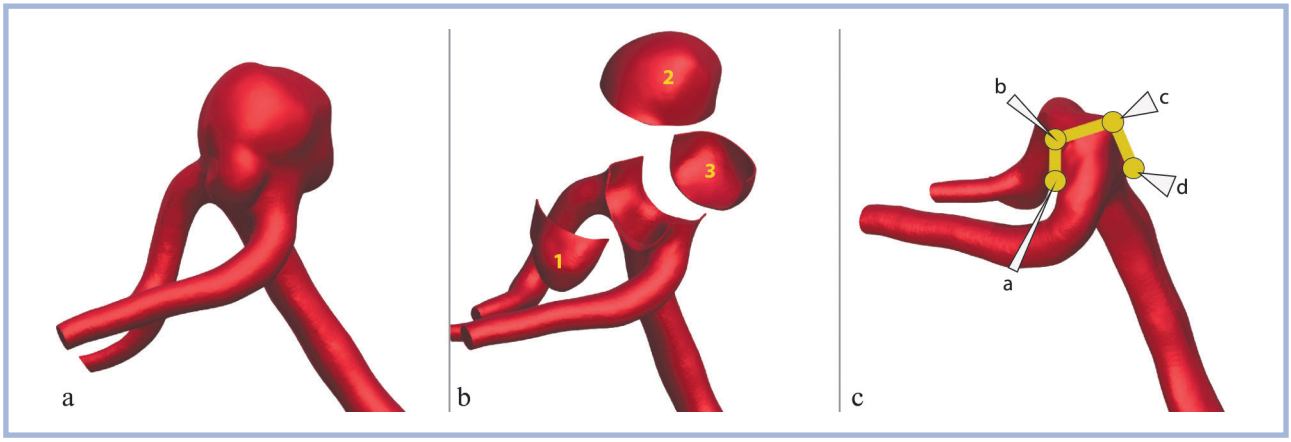

***Fig.* 2. Fragmented clipping along an angulated line, where each segment of the line involves closure of the aneurysm on different arterial surfaces.**
a — bifurcation aneurysm; b — virtual excision of aneurysm parts on three sides for visualization of arterial wall defect; c — angulated line following closure of arterial defect with different clips at three segments corresponding to different surfaces: ab — exclusion of aneurysm part #1, bc — exclusion of aneurysm part #2, cd — exclusion of aneurysm part #3.

Clipping methods and localization of cerebral aneurysms

Method	Localization of aneurysms				Total, *n* (%)
	ICA	MCA	ACA	VBS	
Simple single	98	90	116	7	311 (45.9)
Simple reinforced	18	26	26	3	73 (10.8)
Tandem	29	102	60	7	198 (29.2)
Counter	4	5	6	–	15 (2.2)
Cross	–	16	6	1	23 (3.4)
With tunneling of the efferent artery	–	2	9	1	12 (1.8)
With tunneling of the parent artery	2	1	3	1	7 (1.0)
Perpendicular	1	3	2	–	6 (0.9)
Combined	4	10	6	1	21 (3.1)
Discrete	1	6	5	–	12 (1.8)
Total, *n* (%)	157 (23.2)	261 (38.5)	239 (35.3)	21 (3.1)	678 (100)

Note. ICA — internal carotid artery; MCA — middle cerebral artery; ACA — anterior cerebral artery; VBS — vertebrobasilar system.

formed on separate segments of the aneurysm neck along a one line, including techniques such as tandem, counter, cross, with tunneling of the parent artery, perpendicular, and combined clipping. Discrete clipping with multiple lines of aneurysm neck closure was performed only in 1.8% of cases.

Total aneurysm exclusion was achieved in 91.6% of cases.

Names of various clipping techniques require discussion.

Discussion

When defining various clipping techniques, we combined our own terminology with the most commonly accepted terms found in the relevant literature.

Types of linear clipping depending on the application technique, number and type of clips.

If a single conventional clip, regardless of its configuration, completely closes the aneurysm neck, this technique is called simple single clipping **(Fig. 3 a)**. However, complete capture of the neck with a single clip may not ensure cessation of blood filling in the aneurysm dome due to insufficient compressive force. In such case, a single conventional clip may be reinforced with one or more clips. Tkachev V.V. et al.[2] termed this technique “simple reinforced clipping”. Additional clips are applied distally and parallel to the first clip **(Fig. 3 b)**. In prior classifications, this technique was termed «stacked clipping» [18].

[2]Tkachev VV, Muzlaev GG, Porkhanov VA. *Microsurgery of Cerebral Aneurysms: Experience of Regional Healthcare*. Saint Petersburg: Great Print; 2019. (In Russ.).

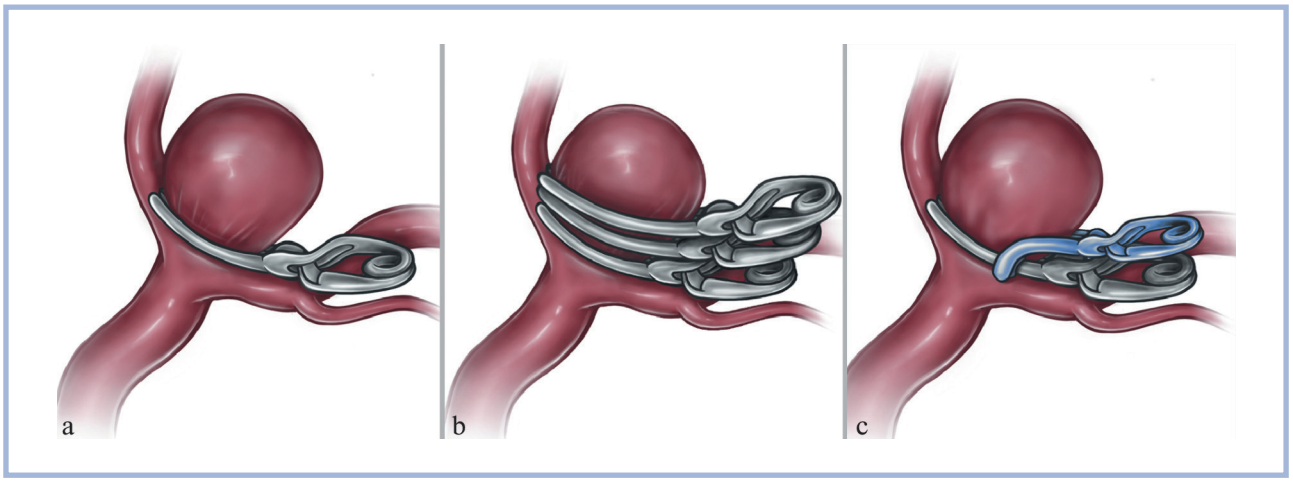

***Fig.* 3. Simple single and reinforced clipping.**
a — simple single clipping (O1); b — simple clipping with distal reinforcement (O1R); c — simple clipping with booster clips (O1B).

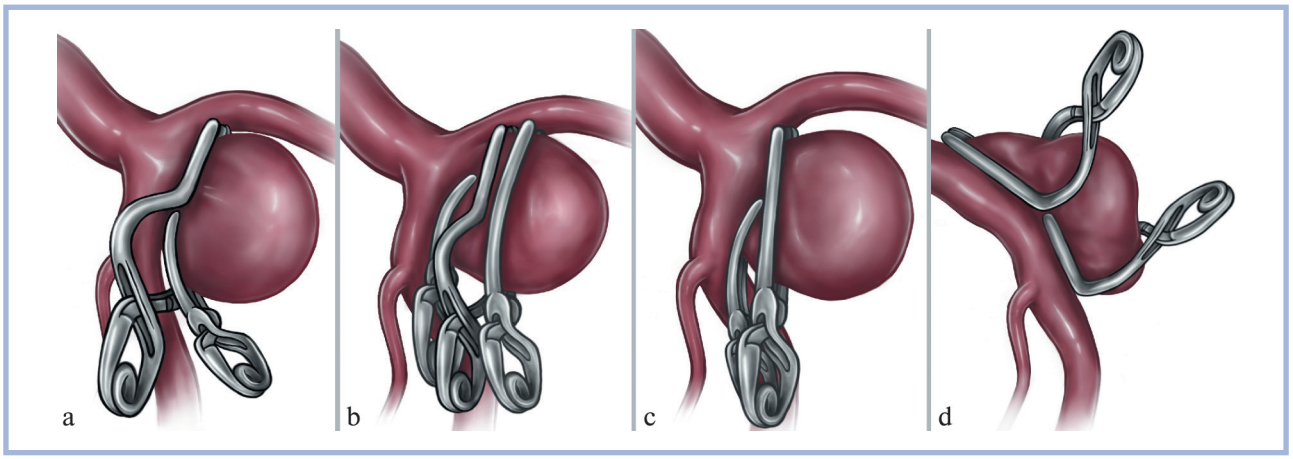

***Fig.* 4. Tandem clipping.**
a — Classic Drake tandem clipping (F1); b — with distal reinforcement (F1R); c — with conventional clips (F2); d — with angular fenestrated clips through aneurysm dome (F3).

Another variant of reinforcing clipping is application of a booster clip over the first clip **(Fig. 3 c)**. Drake C.G. [19] called this technique "piggyback stacking clipping". Booster clips have a reinforced spring compression mechanism and a groove on the inner surface of the blades.

Instead of booster clip, neurosurgeons sometimes apply the second conventional or fenestrated clip over the first clip for reinforcement. However, there are no special grooves on the inner surfaces of their blades. Thus, it is more difficult to use such clips for reinforcement due to potential slipping.

Eliava Sh.Sh. et al.[3] believe that any clipping method implies primary clip applied first and additional clips for enhancing compression of primary clip or exclusion of residual aneurysm parts.

Aneurysm neck fragmentation with multiple clips may be necessary if primary clip is insufficient in length or aneurysm neck extends over multiple arterial surfaces. Tandem clipping is advisable in such situations. One compression line is created by several clips placed in end-to-end fashion. Two or more clips can be used for this purpose. In this case, the spring mechanisms of all clips are positioned on the same side. In the original variant proposed by Drake C.G. [19], tandem clipping was achieved by applying a straight fenestrated clip, the blades of which occluded one part of the aneurysm neck, while the remaining part was left within the fenestration. This open part of the aneurysm neck was then covered with a second conventional clip applied adjacent to the fenestration **(Fig. 4 a)**. In some situations, this method can require distal reinforcement **(Fig. 4 b)**.

Tandem clipping may also be performed with conventional non-fenestrated clips **(Fig. 4 c)**.

Another variant of tandem clipping involves the use of several angulated fenestrated clips. The last ones

[3] *Preventive Surgical Treatment of Cerebral Aneurysms.* Eliava ShSh, ed. M.: Science; 2021. (In Russ.).

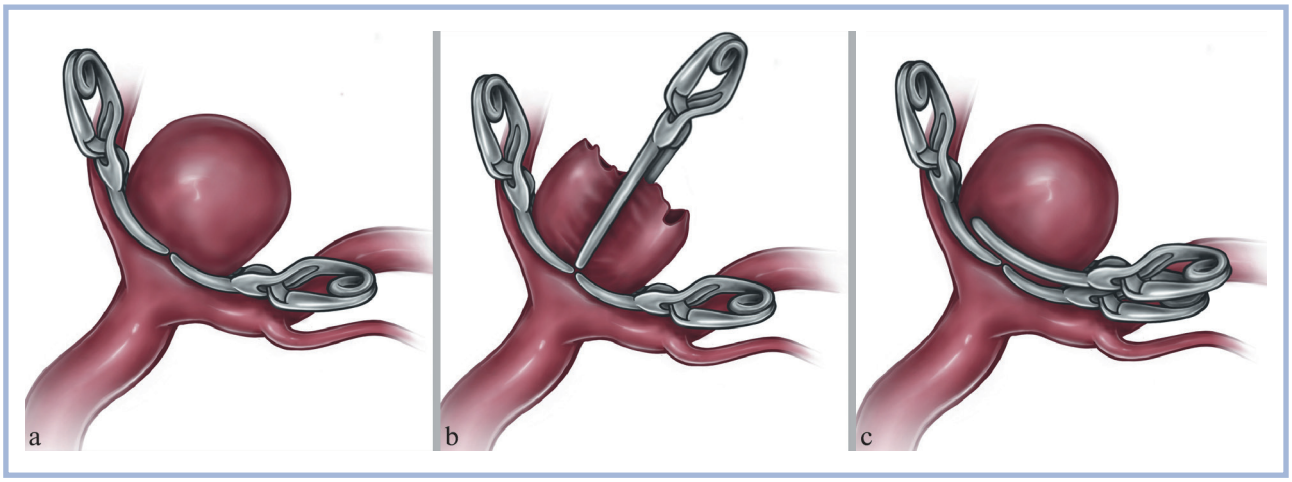

***Fig.* 5. Counter clipping.**
a — typical counter clipping (F4); b — with central reinforcement (F4R1); c — with parallel reinforcement (F4R2).

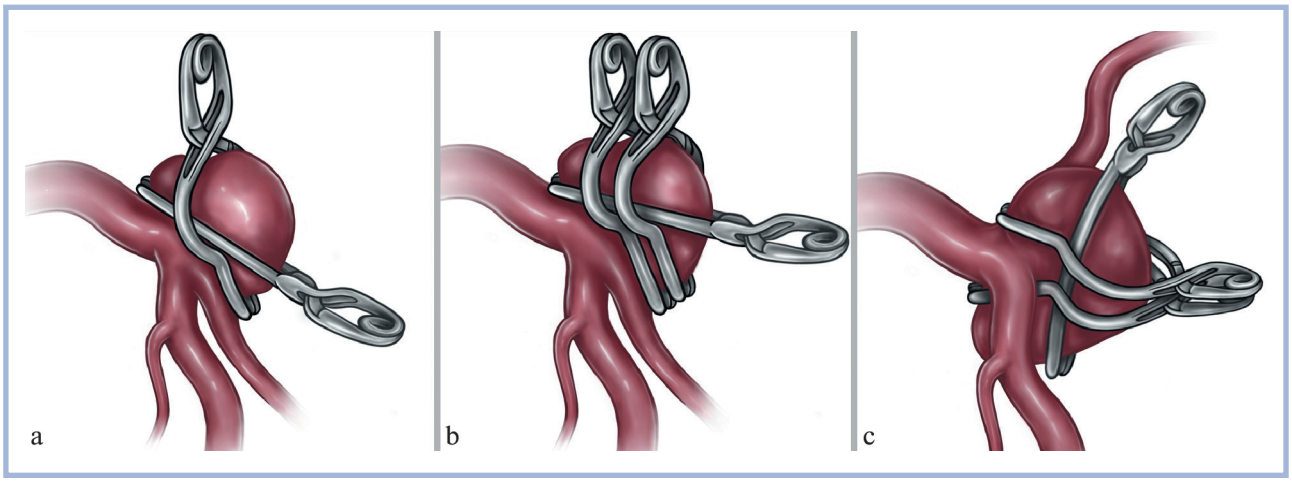

***Fig.* 6. Cross-clipping.**
a — typical cross-clipping (F5); b — with distal reinforcement (F5R); c — double cross-clipping (F6).

are applied in a row so that blades close aneurysm neck and fenestrated part encloses aneurysm dome **(Fig. 4 d)**. The idea behind this clipping is to create a clamping force at the neck and eliminate loss of compression force when portions of the clips closest to the spring mechanism touch the aneurysm dome.

In counter clipping, the tips of the clip blades face each other, and spring mechanisms are on opposite sides unlike tandem clipping. Typical counter clipping implies only two clips **(Fig. 5 a)**. To prevent persistent aneurysm filling after counter clipping, two reinforcement options may be employed: a straight clip applied at the junction of the clips across the aneurysm dome **(Fig. 5 b)** or reinforcing clips applied parallel to previous clips **(Fig. 5 c)**).

Cross-clipping is another option for fragmented clipping with fenestrated clips **(Fig. 6 a)**. Cross-clipping is more common for aneurysm neck extending onto opposite arterial surfaces [20]. First, a standard clip is applied to the part of the aneurysm neck along one arterial surface. Next, a fenestrated clip is placed, and its blades enclose residual part of the neck on the other arterial surface. Blades of the first clip are enclosed within the fenestration of the second clip. Cross-clipping can sometimes require distal reinforcement **(Fig. 6 b)**. Aneurysms extending onto three arterial surfaces can necessitate double cross-clipping **(Fig. 6 c)**.

The technique, in which fenestrated clips are used with the artery enclosed within their fenestration, we have termed “tunneling”.

The efferent artery is often closely adherent to the aneurysm dome. Safe dissection of adhesions is not always possible. In this case, a fenestrated clip is applied so that its fenestration encloses the efferent artery, and its blades occlude the aneurysm neck **(Fig. 7 a)**. If aneurysm dome continues to fill despite a fenestrated clip completely enclosing aneurysm neck, one or more fenestrated clips of similar configuration are applied distally and parallel to the first clip for reinforcement **(Fig. 7 b)**. Moreover, reinforcement can be provided by conventional clips **(Fig. 7 c)**.

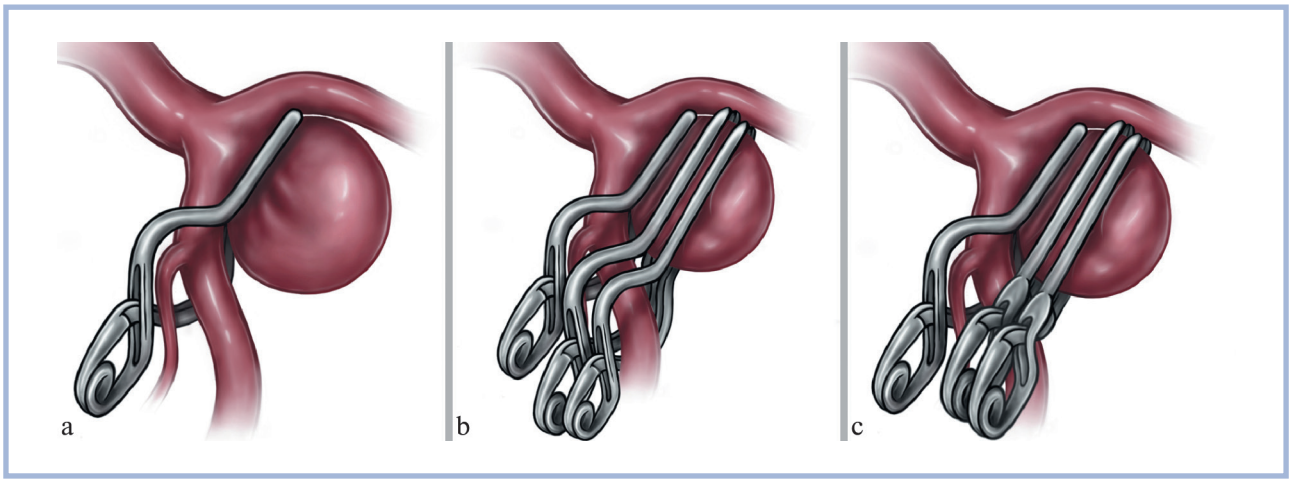

***Fig. 7*. Clipping with tunneling of the efferent artery.**
a — using a single clip (O2); b — reinforced with fenestrated clips (O2R1); c — reinforced with conventional clips (O2R2).

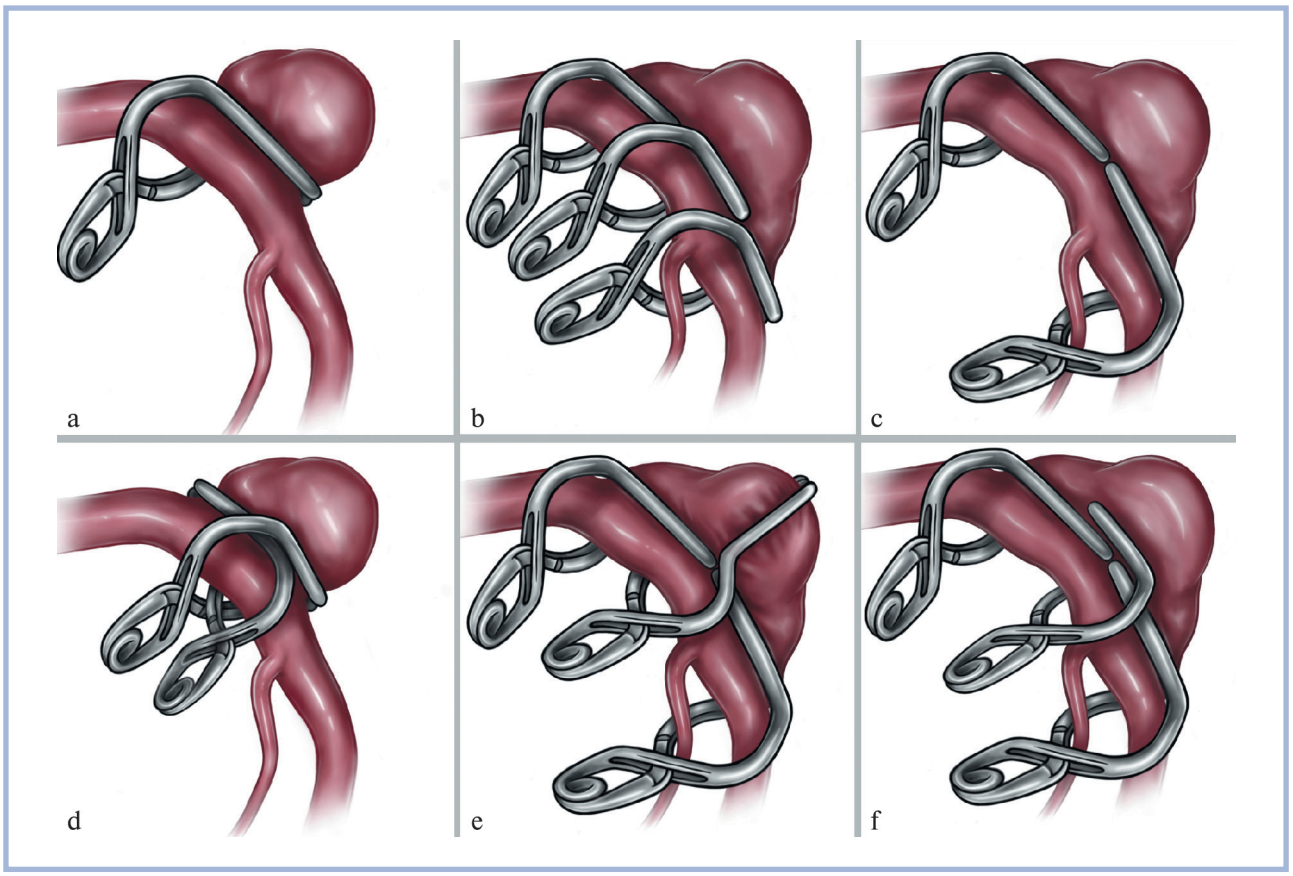

***Fig.* 8. Clipping with tunneling of the parent artery.**
a — using a single clip (O3); b — Sugita tandem clipping (F7); c — counter clipping (F8); d — cross-clipping (F9); e — counter clipping with central reinforcement (F8R1); f — counter clipping with parallel reinforcement (F8R2).

Parent artery tunneling is usually used for aneurysms where arterial part being formed faces the surgeon, and aneurysm part being excluded faces the opposite direction. a single angulated fenestrated clip may be effective for this purpose **(Fig. 8 a)**. In the original Sugita technique [21], parent artery tunneling is achieved using tandem clipping with multiple angulated fenestrated clips **(Fig. 8 b)**. Variations of this technique are counter **(Fig. 8 c)** and cross **(Fig. 8 d)** clipping. Counter clipping with parent artery tunneling may require distal reinforcement: central **(Fig. 8 e)** or parallel **(Fig. 8 f)**).

There is a fragmentation technique with clipping perpendicularly to arterial axis rather (not parallel as in most

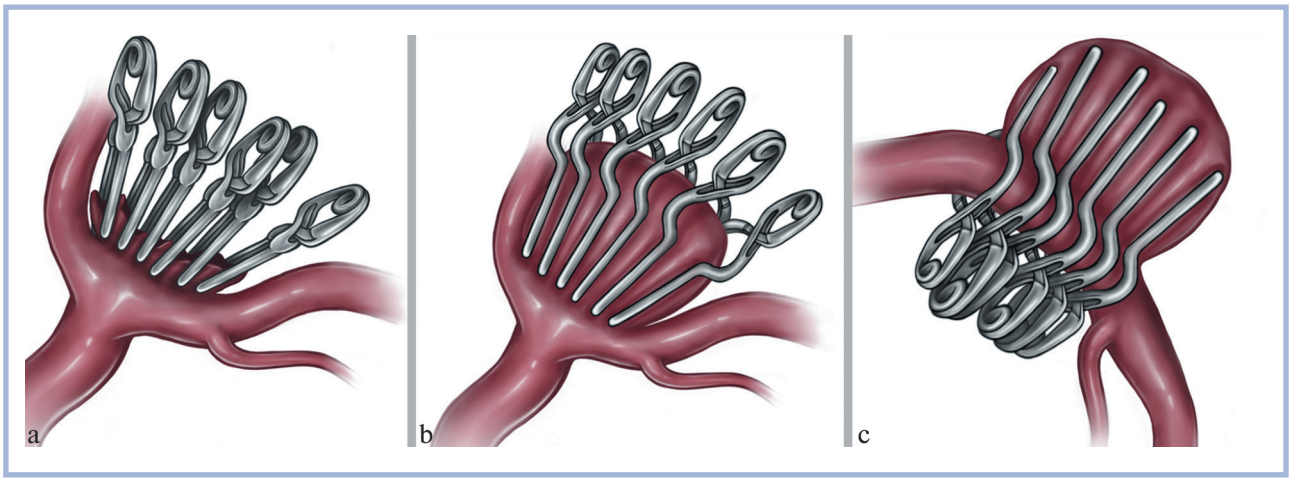

***Fig.* 9. Perpendicular clipping.**
a — typical perpendicular clipping (F10); b — with fenestrated clips through aneurysm dome (F11); c — with fenestrated clips and parent artery tunneling (F12).

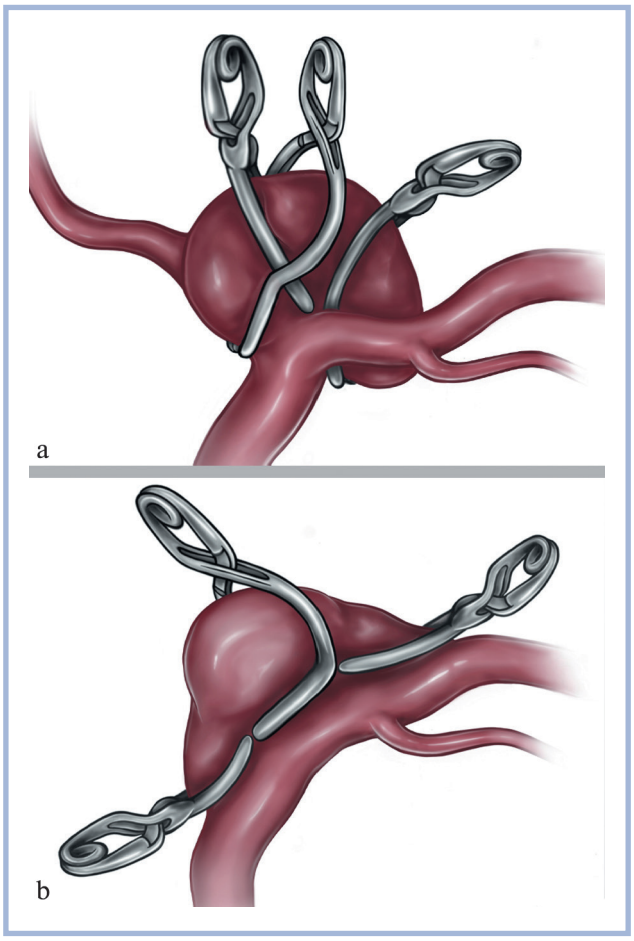

***Fig.* 10. Combined clipping.**
a — combination of tandem and cross-clipping (F13: F2+F6); b — combination of tandem and counter clipping (F13: F2+F4).

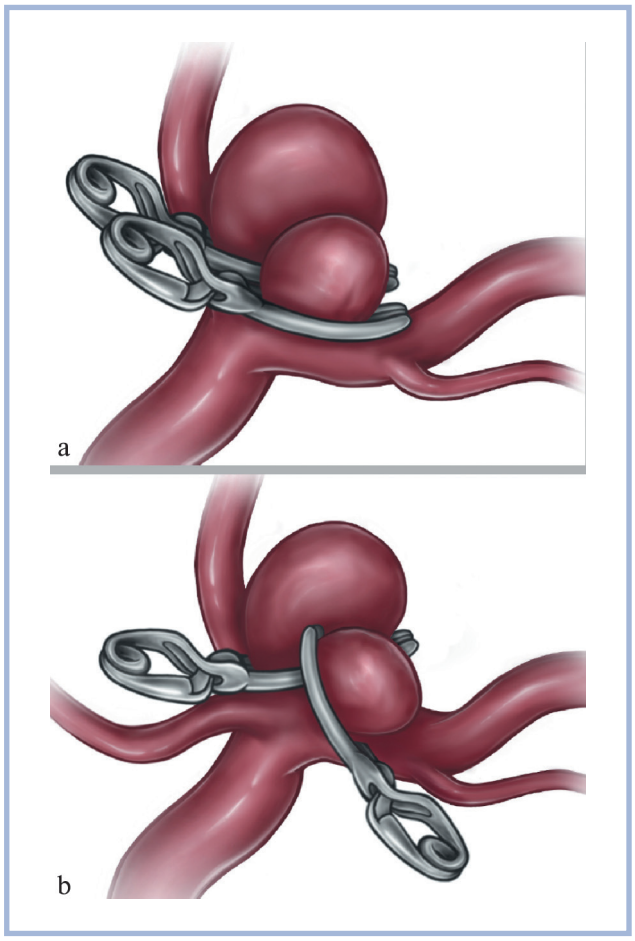

***Fig.* 11. Discrete clipping.**
a — with non-intersecting lines (D1: O1+O1); b — with intersecting lines (D2: O1+O1).

cases). In an earlier publication, this technique is referred to as a "picket fence" [22]. The arterial defect compression line is formed by the tips of the clips. The indication may be heterogeneous structure of aneurysm neck with atherosclerotic plaques or mural clots. Conventional straight or curved clips are used for perpendicular clipping. These clips are more convenient to apply to aneurysm stump **(Fig. 9 a)**. If aneurysm is not excised, fenestrated

clips are preferable **(Fig. 9 b)**. Yang I. et al. [23] called this option "dome tube". Parent artery tunneling with straight fenestrated clips **(Fig. 9 c)** or the so-called "reverse picket fence" [24] are also possible.

We termed the combination of different neck fragmentation methods with linear clip application as combined clipping. Several common options are presented in **Fig. 10**.

Discrete clipping

In rare cases, one-line clipping of the aneurysm neck is impossible, such as in multi-lobed, trifurcation, or other complex aneurysms. We have termed this clipping technique "discrete". This clipping technique is also a variant of fragmented clipping. Discrete clipping results in two or more closure lines on the aneurysm neck. Each of these lines can be formed by one of the above-described linear clipping methods (O1–O3 or F1–F13). The lines following discrete clipping may not intersect **(Fig. 11 a)** or may intersect **(Fig. 11 b)** within the aneurysm neck forming T-, Y-, X-shaped or other intersection configurations.

One-line principle-based classification of reconstructive clipping methods:

I. One-line clipping:
1. **Simple clipping:**
   O1 — Simple single clipping;
   O1R — with distal reinforcement;
   O1B — with booster clips.
2. **Tandem clipping:**
   F1 — Classic Drake tandem clipping;
   F1R — with distal reinforcement;
   F2 — with conventional clips;
   F3 — with angulated fenestrated clips through aneurysm dome.
3. **Counter clipping:**
   F4 — Typical counter clipping;
   F4R1 — with central reinforcement;
   F4R2 — with parallel reinforcement.
4. **Cross-clipping:**
   F5 — Typical cross-clipping;
   F5R — with distal reinforcement;
   F6 — Double cross-clipping.
5. **Clipping with tunneling of the efferent artery:**
   O2 — using a single clip;
   O2R1 — reinforced with fenestrated clips;
   O2R2 — reinforced with conventional clips.
6. **Clipping with tunneling of the parent artery:**
   O3 — using a single clip;
   F7 — Sugita tandem clipping with tunneling of the parent artery;
   F8 — Counter clipping with tunneling of the parent artery;
   F8R1 — Counter clipping with central reinforcement and tunneling of the parent artery;
   F8R2 — Counter clipping with parallel reinforcement and tunneling of the parent artery;
   F9 — Cross-clipping with tunneling of the parent artery.
7. **Perpendicular clipping:**
   F10 — Typical perpendicular clipping;
   F11 — with fenestrated clips through aneurysm dome;
   F12 — with fenestrated clips and parent artery tunneling.
8. **Combined clipping:**
   F13 — combinations of F1–F12.

II. Discrete clipping:
   D1 — with non-intersecting lines;
   D2 — with intersecting lines.

Note: O — one clip; R — reinforcement (reinforcement due to distal application of conventional or fenestrated clips); B — booster clip; F — fragmented clipping; D — discrete clipping.

Conclusion

We developed a novel unified classification of aneurysm clipping methods. Reconstructive aneurysm clipping methods based on one-line principle are divided into 8 types, and each type can include several subtypes.

Clipping along one line is possible in 98.3% of cases. In most (58.5%) cases, linear clipping is performed without dividing the neck into segments. One-line linear fragmented clipping is performed in 39.8% of cases, discrete fragmented clipping with multiple lines — only in 1.8% of cases.

This classification primarily serves scientific purposes, facilitating the evaluation of clinical and angiographic outcomes of various clipping methods across different topographic and morphological variants of cerebral aneurysms.

A comprehensive study of clipping methods will make them clearer for novice neurosurgeons and will be valuable in choosing the optimal surgical technique.

Author contribution:
Concept and design of the study — Pilipenko Yu.V., Okishev D.N., Abramyan A.A.
Collection and analysis of data — Pilipenko Yu.V., Kholmatov M.B., Konovalov An.N., Kheyreddin A.S.
Statistical analysis — Grebenev F.V.
Writing the text — Pilipenko Yu.V., Kholmatov M.B.
Editing — Eliava Sh.Sh.

The authors declare no conflicts of interest.

REFERENCES

1. Dandy WE. Intracranial aneurysm of the internal carotid artery: Cured by operation. *Annals of Surgery*. 1938;107(5):654-659. https://doi.org/10.1097/00000658-193805000-00003
2. Sturiale CL, Rapisarda A, Albanese A. Clipping of Anterior Circulation Aneurysms: Operative Instructions and Safety Rules for Young Cerebrovascular Surgeons. *Advances and Technical Standards in Neurosurgery*. 2024;50:201-229. https://doi.org/10.1007/978-3-031-53578-9_7
3. Silverstein JW, Doron O, Ellis JA. Deliberate Parent Artery Sacrifice Guided by Intraoperative Neurophysiological Monitoring During Complex Surgical Clipping of a Ruptured Anterior Communicating Artery Aneurysm. *Neurodiagnostic Journal*. 2022;62(2):108-119. https://doi.org/10.1080/21646821.2022.2072156
4. Shenoy VS, Miller C, Sen RD, McAvoy M, Montoure A, Kim LJ, Sekhar LN. High-Flow Bypass and Clip Trapping of a Giant Fusiform Middle Cerebral Artery (M1) Aneurysm: Technical Case Instruction. *Operative Neurosurgery*. 2023;25(3):e183-e187. https://doi.org/10.1227/ONS.0000000000000785
5. Liu P, Shi Y, An Q, Zhu W. How I do it: left posterior cerebral artery P1-2 segment dissecting aneurysm distal clipping via an A1-RAG-P2 bypass. *Acta Neurochirurgica*. 2022;164(9):2447-2451. https://doi.org/10.1007/S00701-022-05293-9
6. Li S, Huang Z, Chen H, Chen F. Proximal Clipping and Distal High-Flow Bypass in the Treatment of Giant/Complex Intracranial Aneurysm: An Opportunity or a Risk from a Fluid — Structural Interaction Analysis. *Cardiovascular Engineering and Technology*. 2024;15(2):159-170. https://doi.org/10.1007/s13239-023-00704-z
7. Schwandt E, Kockro R, Kramer A, Glaser M, Ringel F. Presurgical selection of the ideal aneurysm clip by the use of a three-dimensional planning system. *Neurosurgical Review*. 2022;45(4):2887-2894. https://doi.org/10.1007/S10143-022-01794-4
8. Nagaraj A, Raju B, Jumah F, Nanda A. Surgical Resection and Clipping of an Atherosclerotic Partially Calcified Middle Cerebral Artery Trifurcation Aneurysm with Clipping of an Anterior Communicating Artery Aneurysm: 2-Dimensional Operative Video. *World Neurosurgery*. 2022;166:28. https://doi.org/10.1016/J.WNEU.2022.05.077
9. Zhu W, Liu P, Tian Y, Gu Y, Xu B, Chen L, Zhou L, Mao Y. Complex middle cerebral artery aneurysms: a new classification based on the angioarchitecture and surgical strategies. *Acta Neurochirurgica*. 2013;155(8):1481-1491. https://doi.org/10.1007/S00701-013-1751-8
10. Scerrati A, Sabatino G, Della Pepa GM, Albanese A, Marchese E, Puca A, Olivi A, Sturiale CL. Treatment and outcome of thrombosed aneurysms of the middle cerebral artery: institutional experience and a systematic review. *Neurosurgical Review*. 2019;42(3):649-661. https://doi.org/10.1007/S10143-018-0984-7
11. Huang CQ, Kang DZ, Yu LH, Zheng SF, Yao PS, Lin YX, Lin ZY. The classification of intracranial aneurysm neck: A single center research experience. *Chinese Neurosurgical Journal*. 2018;4:39. https://doi.org/10.1186/s41016-018-0138-3
12. Auricchio AM, Di Bonaventura R, Marchese E, Della Pepa GM, Sturiale CL, Menna G, Skrap B, Olivi A, Albanese A. Navigating Complexity: A Comprehensive Approach to Middle Cerebral Artery Aneurysms. *Journal of Clinical Medicine*. 2024;13(5):1286. https://doi.org/10.3390/JCM13051286
13. Natarajan SK, Zeeshan Q, Ghodke BV, Sekhar LN. Brain Bypass Surgery for Complex Middle Cerebral Artery Aneurysms: Evolving Techniques, Results, and Lessons Learned. *World Neurosurgery*. 2019;130:e272-e293. https://doi.org/10.1016/J.WNEU.2019.06.059
14. Sangrador-Deitos MV, Rodríguez Hernández LA, Balcázar-Padrón JC, Ruiz-Treviño A, Nathal E. Giant Posterior Inferior Cerebellar Artery Aneurysm Mimicking a Brainstem Tumor. *Cureus*. 2022;14(2):e22706. https://doi.org/10.7759/CUREUS.22706
15. Ishikawa T, Nakayama N, Moroi J, Kobayashi N, Kawai H, Muto T, Yasui N. Concept of ideal closure line for clipping of middle cerebral artery aneurysms — technical note. *Neurologia Medico-Chirurgica*. 2009;49(6):273-277. https://doi.org/10.2176/nmc.49.273
16. Sekhar LN, Stimac D, Bakir A, Rak R. Reconstruction options for complex middle cerebral artery aneurysms. *Neurosurgery*. 2005;56(1):66-74. https://doi.org/10.1227/01.NEU.0000144210.44405.E0
17. Eliava ShSh, Pilipenko YuV, Kholmatov MB, Belousova OB, Kheireddin AS, Okishev DN, Konovalov AnN, Grebenev FV. Microsurgical treatment of 723 cerebral aneurysms: a single-center prospective study. *Burdenko's Journal of Neurosurgery*. 2025;89(3):60-67. (In Russ.). https://doi.org/10.17116/neiro20258903160
18. Pipolo DO, Demichelis ME, Purves C, Campero A, Villalonga JF, Luzzi S, Baldoncini M. Piggyback Stacking and Booster Clipping Technique: A Technical Note. *World Neurosurgery*. 2022;164:306-309. https://doi.org/10.1016/J.WNEU.2022.05.106
19. Drake CG. Giant intracranial aneurysms: experience with surgical treatment in 174 patients. *Clinical Neurosurgery*. 1979;26:12-95. https://doi.org/10.1093/neurosurgery/26.cn_suppl_1.12
20. Degollado-García J, Rodríguez-Rubio HA, Bonilla-Suastegui A, Serrano-Rubio A, Nicolas-Cruz CF, Nathal E. Limitation of fenestrated clips during clipping of middle cerebral artery aneurysm: Technical note. *Surgical Neurology International*. 2023;14:204. https://doi.org/10.25259/SNI_374_2023
21. Sugita K, Kobayashi S, Kyoshima K, Nakagawa F. Fenestrated clips for unusual aneurysms of the carotid artery. *Journal of Neurosurgery*. 1982;57(2):240-246. https://doi.org/10.3171/JNS.1982.57.2.0240
22. Davies JM, Lawton MT. "Picket Fence" clipping technique for large and complex aneurysms. *Neurosurgical Focus*. 2015;39(Video Suppl 1):V17. https://doi.org/10.3171/2015.7.FocusVid.14632
23. Yang I, Lawton MT. Clipping of complex aneurysms with fenestration tubes: application and assessment of three types of clip techniques. *Neurosurgery*. 2008;62(5 Suppl 2):ONS371-378; discussion 378-379. https://doi.org/10.1227/01.NEU.0000326021.14810.0C
24. Mascitelli J, Gandhi S, Cavallo C, Hardesty DA, Lawton MT. "Reverse Picket Fence" Technique for Clipping of a Large, Anterior Communicating Artery Aneurysm: 2-Dimensional Operative Video. *Operative Neurosurgery*. 2020;18(3):E86-E87. https://doi.org/10.1093/ONS/OPZ170

Received 19.05.2025
Accepted 18.07.2025

COMMENT

Pilipenko Yu.V. et al. discuss an important issue of one-line principle in microsurgical treatment of cerebral aneurysms. The authors thoroughly studied the problem of total aneurysm exclusion without remnants. It is no secret that shape of saccular aneurysms is often far from perfect and does not resemble a hemisphere. Some aneurysms are characterized by diverticula, calcification of dome and/or neck, extension of aneurysm neck into afferent and/or efferent arteries, fusion of dome with arterial branches. In such cases, clipping with a single clip is often impossible. a so-called clipping line is necessary to ensure total aneurysm exclusion. It is desirable that clipping planes not intersect, but form a broken line.

The authors describe the concept of clipping line within junction of clip blades. Stretched arterial walls are aligned along this line.

The authors analyzed clipping lines in 678 patients undergoing aneurysm repair. Thanks to understanding of one-line clipping concept, discrete fragmented clipping with multiple closure lines was performed in only 1.8% of cases. Total aneurysm exclusion was achieved in 91.6% of cases that is a very good result.

Professional illustrations present various clipping lines for the main techniques. a unique classification of reconstructive clipping options is particularly valuable. This classification is of great importance for retrospective research of quality and methods of cerebral aneurysm clipping. However, this system may be also valuable in clinical practice for preoperative planning of microsurgical treatment of aneurysms with 3D modeling. Indeed, one can preoperatively select clip shapes, types and numbers, as well as model aneurysm clipping line.

The manuscript is certainly important for neurosurgeons, especially young specialists. Indeed, this article is valuable to understand the differences in clipping methods and correctly select clips of various shapes and sizes for total aneurysm exclusion.

Dubovoy A.V. (Moscow)