Burdenko's Journal of Neurosurgery
2024, №5, pp. 60–68
https://doi.org/10.17116/neiro20248805160

Intrascopic predictors of favorable outcomes after ventriculoperitoneal shunting in Hakim—Adams syndrome: a single-center retrospective non-randomized study

© A.V. STANISHEVSKIY[1], G.V. GAVRILOV[1, 2], A.V. LEBEDENKO[1], B.G. ADLEYBA[1], M.N. RADKOV[1], D.V. SVISTOV[1], V.YU. CHEREBILLO[2]

[1]Kirov Military Medical Academy, St. Petersburg, Russia;
[2]Pavlov First St. Petersburg State Medical University, St. Petersburg, Russia

ABSTRACT

The main feature of idiopathic normal pressure hydrocephalus is reversible clinical manifestations after timely ventriculoperitoneal shunting. However, the effectiveness of such interventions does not exceed 85%. Invasive diagnostic methods are used to select candidates for surgery. At the same time, literature data indicate neuroimaging symptoms predicting postoperative outcomes without invasive examination.

Objective. To identify intrascopic predictors of favorable outcomes after ventriculoperitoneal shunting in Hakim—Adams syndrome; to present a model for evaluating MRI data and selecting candidates for surgery.

Material and methods. A single-center retrospective non-randomized study enrolled head MRI data in patients with idiopathic normal-pressure hydrocephalus who underwent ventriculoperitoneal shunting between September 2020 and March 2022. There were 34 patients including 15 ones in the main group (significant improvement after surgery) and 19 ones in the control group. We analyzed quantitative neuroimaging features: ventriculocranial indices, DESH syndrome (DESH score), angle of corpus callosum at the level of anterior and posterior commissures, dimensions of temporal horns of lateral ventricles, the number of lacunar infarcts in basal ganglia and white matter of hemispheres.

Results. We identified the most significant predictors of favorable outcomes after ventriculoperitoneal shunting: Evans index, indexed longitudinal size of lateral ventricles, angle of corpus callosum (at the level of anterior and posterior commissures) and DESH score. We created a classification model using discriminant analysis. This model allows us to predict the outcomes after ventriculoperitoneal shunting.

Conclusion. A comprehensive assessment of intrascopic symptoms allows us to predict the outcomes after ventriculoperitoneal shunting in patients with Hakim—Adams syndrome. In the future, we can avoid invasive diagnostic manipulations in some patients.

Keywords: *idiopathic normal pressure hydrocephalus, outcome prediction, callosal angle, DESH syndrome, ventriculoperitoneal shunting.*

INFORMATION ABOUT THE AUTHORS:
Stanishevskiy A.V. — https://orcid.org/0000-0002-2615-269X
Gavrilov G.V. — https://orcid.org/0000-0002-8594-1533
Lebedenko A.V. — https://orcid.org/0000-0002-2441-6436
Adleyba B.G. — https://orcid.org/0000-0002-9761-7095
Radkov M.N. — https://orcid.org/0000-0002-6626-7707
Svistov D.V. — https://orcid.org/0000-0002-3922-9887
Cherebillo V.Yu. — https://orcid.org/0000-0001-6803-9954
Corresponding author: Stanishevskiy A.V. — e-mail: a-stan@mail.ru

TO CITE THIS ARTICLE:
Stanisheskiy AV, Gavrilov GV, Lebedenko AV, Adleyba BG, Radkov MN, Svistov DV, Cherebillo VYu. Intrascopic predictors of favorable outcomes after ventriculoperitoneal shunting in Hakim—Adams syndrome: a single-center retrospective non-randomized study. *Burdenko's Journal of Neurosurgery* 2024;88(5):60–68. (In Russ.). https://doi.org/10.17116/neiro20248805160

Introduction

In the last 10 years, idiopathic normal pressure hydrocephalus (iNPH, Hakim-Adams syndrome) has increasingly been considered as a manifestation of general neurodegenerative process [1]. Such symptoms of iNPH as gait disturbance, short-term memory loss and urination disorders significantly reduce the quality of life and can lead to severe disability. The main feature of iNPH distinguishing this disease from other types of NPH is potential complete or partial regression of manifestations after ventriculoperitoneal shunting [2]. To date, the effectiveness of ventriculoperitoneal shunting does not exceed 85% in large series [3, 4]. At the same time, more than half

Table 1. **Literature data on MR predictors of positive outcomes after ventriculoperitoneal shunting**

MP-predictor of positive outcomes after ventriculoperitoneal shunting	Articles confirming the effectiveness of the predictor	Reference values*	
		ineffective VPS	effective VPS
Ventriculocranial indices:			
Evans index	H.E. Subramanian et al., 2021 [14]	36	41
index of longitudinal size of lateral ventricles	W. He et al., 2020 [15]	40	58
Angle of corpus callosum:			
standard variant	S.G. Thavarajasingam et al., 2023 [12]	$\geqslant 90^0$	$<90^0$
anterior modification	P. Mantovani et al., 2021 [16]	$\geqslant 112^0$	$<112^0$
DESH-score**	N. Shinoda et al., 2017 [17]	4.3	6.4
Transverse size of temporal horns of lateral ventricles, mm	K. Kockum et al., 2018 [18]	<4	>6
Number of lacunar infarction foci	Y.J. Hong et al., 2018 [10]	⩾1	0

Note. * — mean values calculated for samples in certain study or cut-of values; ** — reference values of DESH-score (Disproportionately Enlarged Subarachnoid Space Hedrocephalus, hydrocephalus syndrome with disproportionately enlarged subarachnoid spaces — a combination of enlarged lateral ventricles with expansion of Sylvian fissures and narrowing of convexital subarachnoid spaces) are predictors of improvement in assessment of postoperative iNPH GS scores (Idiopathic Normal Pressure Hydrocephalus Grading Scale [19]).

of patients note significant clinical improvement in case of high-quality selection, and 2/3 become independent from others [5, 6].

An urgent objective in research of iNPH is development of methods for predicting the outcomes of ventriculoperitoneal shunting [7]. According to modern guidelines [2, 8], invasive research methods such as tap test, external lumbar drainage of cerebrospinal fluid, infusion load test or nocturnal intracranial pressure monitoring with parenchymal sensor are currently used to select candidates for ventriculoperitoneal shunting. Importantly, tap test is the simplest and the least effective in predicting the outcomes of ventriculoperitoneal shunting [9]. Other methods require long-term hospital-stay, availability of specialized equipment and complex interpretation of results.

To date, some studies identified neuroimaging (MRI) predictors of positive postoperative outcomes [10—12], and the most significant ones were determined [13] **(Table 1)**.

The purpose of the study was to identify intrascopic predictors of favorable outcomes after ventriculoperitoneal shunting in Hakim-Adams syndrome and to present a model for evaluating MRI data and selecting candidates for surgery.

Material and methods

A single-center non-randomized retrospective study was performed. At the first stage, we collected medical records and MRI data on patients with iNPH who underwent ventriculoperitoneal shunting with constant mean (100 mm H_2O) pressure valve and anti-siphon system between September 2020 and March 2022. We assessed preoperative symptoms using the validated Barthel index [20]. The second stage included a telephone survey of patients and their relatives for analysis of clinical manifestations within the first year after surgery. We objectified these data considering Barthel index changes (%). Inclusion criteria: stereotypical ventriculoperitoneal shunting within the study period, available preoperative Barthel index of symptoms, preoperative MRI data (DICOM) allowing for multiplanar reconstruction of images, up-to-date contact information for communication with the patient and/or his representative, no fatal outcome, no complications of concomitant diseases, no postoperative complications and dysfunction of shunting system. All patients were divided into 2 groups: the main group included patients with positive dynamics of Barthel index > 20% (n=15), the control group — other patients (n=19).

We analyzed the following values considering MRI data: Evans index (EI), longitudinal size index (LSI) of lateral ventricles [15], angle of corpus callosum (at the level of posterior and anterior commissures), DESH-score [17], width of temporal horns of lateral ventricles and the number of lacunar infarcts in periventricular white matter and basal ganglia. RadiAnt DICOM Viewer (Medixant, Poland) was used to analyze MRI data **(Figure)**. When calculating the LSI of lateral ventricles and width of temporal horns, we used mean value between the right and left sides **(Figure a, b)**. The angle of corpus callosum was estimated at the level of anterior and posterior commissures in multiplanar reconstructions in accordance with the previously described technique **(Figure c—f)** [16, 21]. Lacunar infarcts were assessed using the technique presented by Hong Y.J. et al. **(Figure g, h)** [10].

We compared both groups using nonparametric statistical methods. Discriminant analysis was performed with assessment of coefficients of discriminant functions. Considering these data, we made a classification model to predict the outcomes after ventriculoperitoneal shunting.

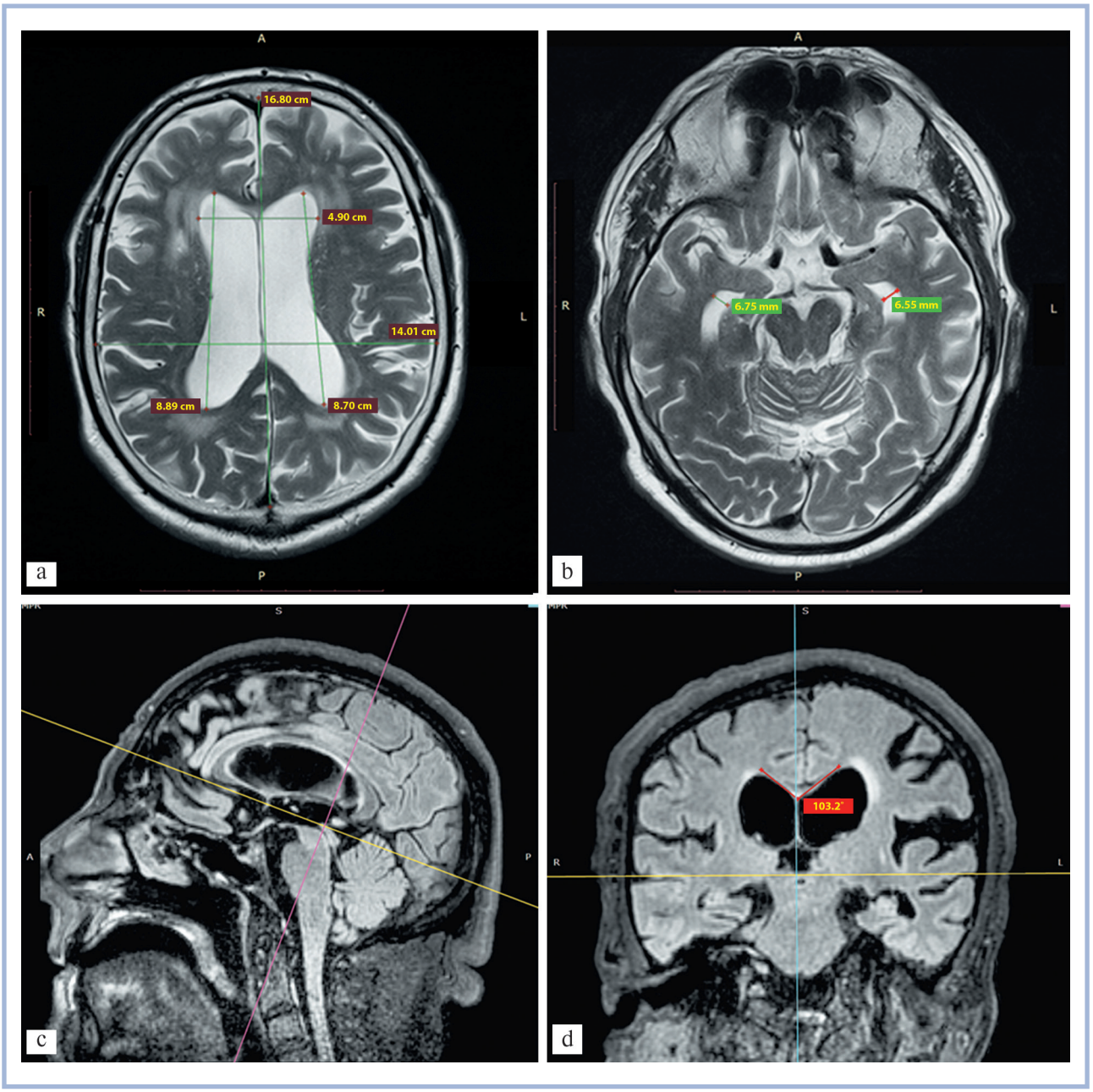

Analysis of MR predictors (a—d).
a — ventriculocranial indices (Evans index and longitudinal size index of lateral ventricles); b — width of temporal horns of lateral ventricles; c, d — angle of corpus callosum at the level of posterior commissure; e, f — angle of corpus callosum at the level of anterior commissure; g, h — foci of lacunar infarction.

Results

Thirty-four patients met the inclusion criteria (23 men and 11 women). There were no significant between-group differences in gender, age, duration of follow-up and preoperative Barthel index. The median follow-up was 2.5 years (Q25 — 22 months, Q75 — 35.3 months). The study group included 15 patients with 30.4% (95% CI 26.5—36) Barthel index change. In the control group, no postoperative changes was noted in 1 patient, minor positive dynamics (<10% of baseline Barthel index) — in 19 patients. Between-group comparison of MR signs revealed significant differences in EI, LSI of lateral ventricles, angle of corpus callosum (in both modifications) and DESH scores **(Table 2)**.

After discriminant analysis, we obtained the following classification model:

$$I_{VPS\ outcome} = 0.123 \cdot X_{EI} - 0.048 \cdot X_{LSI} + 0.159 \cdot X_{temp\ horn} + 0.044 \cdot X_{ACC(p)} + 0.053 \cdot X_{ACC(a)} + 0.55 \cdot X_{LI} - 0.51 \cdot X_{DESH\text{-}score} - 11.02,$$

where $I_{VPS\ outcome}$ — discriminant function characterizing the probability of significant improvement after VPS; X_{EI} — EI value; X_{LSI} — LSI of lateral ventricles; X_{temp}



Analysis of MR predictors (e—h).
a — ventriculocranial indices (Evans index and longitudinal size index of lateral ventricles); b — width of temporal horns of lateral ventricles; c, d — angle of corpus callosum at the level of posterior commissure; e, f — angle of corpus callosum at the level of anterior commissure; g, h — foci of lacunar infarction.

$_{horn}$ — width of temporal horns of lateral ventricles (mm); $X_{ACC(p)}$ — angle of corpus callosum at the level of posterior commissure (^{0}); $X_{ACC(a)}$ — angle of corpus callosum at the level of anterior commissure (^{0}); X_{LI} — number of lacunar infarctions; $X_{DESH\text{-}score}$ – DESH-score; Discrimination constant: –0.489.

$I_{VPS\ outcome}$ >–0.489 characterizes the group of positive prognosis after VPS.

Comparison of mean values of discriminant function in both groups using the Wilks λ coefficient revealed significant differences (p<0.001).

Sensitivity and specificity of the model was 93.3% and 100%, respectively. Thus, diagnostic characteristics of the model are not inferior to those calculated previously for invasive methods of diagnosing iNPH [22].

Discussion

Discovery of gliolymphatic brain system significantly changed the understanding of iNPH pathogenesis [23]. Indeed, patterns and mechanisms of neurological disorders

Table 2. **Magnetic resonance predictors in both groups**

MR-predictor		Study group (n=15)	Control group (n=19)	p-value
		Me (95% CI)	Me (95% CI)	
Ventriculocranial indices	EI	36 (34—39)	33 (32—34)	0.014
	LSI of lateral ventricles	57 (55—62)	51 (50—53)	<0.001
Width of temporal horns of lateral ventricles		4 (4—6)	6 (5—7)	0.215
Angle of corpus callosum	at the level of posterior commissure	79 (74—85)	104 (101—107)	<0.001
	at the level of anterior commissure	103 (98—107)	120 (117—124)	<0.001
Number of lacunar infarcts		0.3 (0.06—0.6)	0.8 (0.4—1.3)	0.120
DESH-score		5 (5—7)	2 (2—3)	<0.001

common to several neurodegenerative processes were revealed. Tseng P.H. et al. [24] supported the hypothesis about common causes and pathogenesis of iNPH and other neurodegenerative diseases. According to their data, VPS in patients with iNPH significantly reduces the risk of dementia and Alzheimer's disease in addition to effect on baseline clinical manifestations. These data can change the indications for surgical treatment of iNPH. Nevertheless, regression of baseline neurological symptoms is currently the main criterion of effective VPS, and the main objective for neurosurgeons is selection of patients only for potentially effective VPS.

iNPH was first described in 1965, and invasive methods were proposed to select candidates for VPS. The last ones have not lost their relevance to this day. However, effectiveness of these methods is not absolute due to certain factors such as the need for surgical procedure causing discomfort in patients. As a result, some ones refuse further cooperation with the doctor. This circumstance necessitated analysis of other potential predictors of effective surgical treatment (clinical, neuroimaging, CSF-related ones, etc.). Clinical picture of disease does not allow predicting the effectiveness of surgery [25]. Analysis of CSF protein composition in patients with iNPH is one of the promising areas in searching for predictors [26]. The main limitation for this diagnostics is complexity of procedures and the need for highly specialized analytical equipment.

The same factors complicate the widespread use of complex neuroimaging techniques in diagnosis and prognosis of iNPH, such as MR elastography of the brain, MR spectroscopy or diffusion tensor MRI with analysis of fractional anisotropy coefficient in periventricular white matter. Effectiveness of these approaches was demonstrated in several studies [27—29]. At the same time, there are MR data on specific configuration changes of subarachnoid spaces. Systematization of this information identified new neuroimaging symptoms, such as DESH syndrome, angle of corpus callosum, etc. Importantly, information on possible predicting the outcomes of treatment when identifying these symptoms is contradictory. Indeed, the same signs are recognized as predictors of outcomes after VPS in some studies, while other studies reject these predictors [10, 30]. After systematic literature review, we established the most promising neuroimaging signs regarding prediction of outcomes after VPS [13]. Signs that may be quantitatively assessed were selected for discriminant analysis and classification model. The difference between this study and analysis of neuroimaging symptoms described in the literature, for example, the iNPH Grading Scale [18], is that each symptom is empirically assigned certain points in this scale. The sum of these values determines prognosis of VPS. At the same time, contribution of each predictor in determining the outcome is not taken into account. In our model, the values of neuroimaging predictors are assessed in a complex. As a result, certain patient is discriminated into the group of positive or negative prognosis after VPS.

Considering diagnostic properties, this prognostic model may be valuable to avoid the need for invasive methods in predicting the outcomes after VPS.

Conclusion

Neuroimaging parameters (EI, LSI of lateral ventricles, angle of corpus callosum (in both modifications) and DESH-score) can be considered as predictors of the outcomes after VPS in patients with idiopathic normal-pressure hydrocephalus. A comprehensive analysis of these predictors using the described discriminant model can exclude the need for invasive diagnostic methods.

Study limitations

The main limitations of this study are related to insufficient sample power. In addition, telephone surveys are inferior to follow-up examination by a specialist.

Author contribution:
Concept and design of the study — Stanishevsky A.V., Gavrilov G.V., Svistov D.V., Cherebillo V.Yu.
Collection and analysis of data — Stanishevsky A.V., Lebedenko A.V., Adleyba B.G., Radkov M.N.
Writing — Stanishevsky A.V.
Editing — Gavrilov G.V., Svistov D.V., Cherebillo V.Yu.

No conflict of interests to declare.

REFERENCES

1. Kanno S, Suzuki K. [Preoperative Predictors of Outcomes of Cerebrospinal Fluid Shunt Surgery in Patients with Idiopathic Normal Pressure Hydrocephalus]. *Brain and Nerves*. 2024;76(2):167-173. (In Japanese). https://doi.org/10.11477/mf.1416202579
2. *Guidelines on treatment of normal pressure hydrocephalus of adults*. Legzdain MA, Gavrilov GV, Svistov DV, eds. SPb; 2015. (In Russ.).
3. Toma AK, Papadopoulos MC, Stapleton S, Kitchen ND, Watkins LD. Systematic review of the outcome of shunt surgery in idiopathic normal-pressure hydrocephalus. *Acta Neurochirurgica*. 2013;155(10):1977-1980. https://doi.org/10.1007/s00701-013-1835-5
4. Greuter L, Schenker T, Guzman R, Soleman J. Endoscopic third ventriculostomy compared to ventriculoperitoneal shunt as treatment for idiopathic normal pressure hydrocephalus: a systematic review and meta-analysis. *British Journal of Neurosurgery*. 2022:1-7. https://doi.org/10.1080/02688697.2022.2149697
5. Popal AM, Zhu Z, Guo X, Zheng Z, Cai C, Jiang H, Zhang J, Shao A, Zhu J. Outcomes of Ventriculoperitoneal Shunt in Patients With Idiopathic Normal-Pressure Hydrocephalus 2 Years After Surgery. *Frontiers in Surgery*. 2021;8:641561. https://doi.org/10.3389/fsurg.2021.641561
6. Torregrossa F, Buscemi F, Gulino V, Campisi BM, Teresi G, Grasso G. Health-Related Quality of Life and Role of Surgical Treatment in Idiopathic Normal Pressure Hydrocephalus: A Systematic Review. *World Neurosurgery*. 2023;179:197-203.e1. https://doi.org/10.1016/j.wneu.2023.08.105
7. Jakopin NE, Myong E, Bogucki T, Gray D, Gross P, McComb JG, Shannon CN, Tamber MS, Toyama M, van der Willigen T, Yazdani A, Hamilton MG, Koschnitzky JE. Establishing ranked priorities for future hydrocephalus research. *Journal of Neurosurgery*. 2023;139(2):492-501. https://doi.org/10.3171/2022.10.JNS22753
8. Nakajima M, Yamada S, Miyajima M, Ishii K, Kuriyama N, Kazui H, Kanemoto H, Suehiro T, Yoshiyama K, Kameda M, Kajimoto Y, Mase M, Murai H, Kita D, Kimura T, Samejima N, Tokuda T, Kaijima M, Akiba C, Kawamura K, Atsuchi M, Hirata Y, Matsumae M, Sasaki M, Yamashita F, Aoki S, Irie R, Miyake H, Kato T, Mori E, Ishikawa M, Date I, Arai H; research committee of idiopathic normal pressure hydrocephalus. Guidelines for Management of Idiopathic Normal Pressure Hydrocephalus (Third Edition): Endorsed by the Japanese Society of Normal Pressure Hydrocephalus. *Neurologia Medico-Chirurgica*. 2021;61(2):63-97. https://doi.org/10.2176/nmc.st.2020-0292
9. Thavarajasingam SG, El-Khatib M, Rea M, Russo S, Lemcke J, Al-Nusair L, Vajkoczy P. Clinical predictors of shunt response in the diagnosis and treatment of idiopathic normal pressure hydrocephalus: a systematic review and meta-analysis. *Acta Neurochirurgica*. 2021;163(10):2641-2672. https://doi.org/10.1007/s00701-021-04922-z
10. Hong YJ, Kim M-J, Jeong E, Kim J-E, Hwang J, Lee J-I, Lee J-H, Na DL. Preoperative biomarkers in patients with idiopathic normal pressure hydrocephalus showing a favorable shunt surgery outcome. *Journal of the Neurological Sciences*. 2018;387:21-26. https://doi.org/10.1016/j.jns.2018.01.017
11. Kimura T, Yamada S, Sugimura T, Seki T, Miyano M, Fukuda S, Takeuchi S, Miyata S, Tucker A, Fujita T, Hashizume A, Izumi N, Kawasaki K, Nakagaki A, Sako K. Preoperative Predictive Factors of Short-Term Outcome in Idiopathic Normal Pressure Hydrocephalus. *World Neurosurgery*. 2021;151:e399-e406. https://doi.org/10.1016/j.wneu.2021.04.055
12. Thavarajasingam SG, El-Khatib M, Vemulapalli K, Iradukunda HAS, K SV, Borchert R, Russo S, Eide PK. Radiological predictors of shunt response in the diagnosis and treatment of idiopathic normal pressure hydrocephalus: a systematic review and meta-analysis. *Acta Neurochirurgica*. 2023;165(2):369-419. https://doi.org/10.1007/s00701-022-05402-8
13. Stanishevskiy AV, Gavrilov GV, Radkov MN, Adleyba BG, Svistov DV. Predictors of Satisfactory Surgical Outcome in Idiopathic Normal Pressure Hydrocephalus (Review). *Sovremennye tekhnologii v meditsine*. 2024;16(2):68. https://doi.org/10.17691/stm2024.16.2.07
14. Subramanian HE, Fadel SA, Matouk CC, Zohrabian VM, Mahajan A. The Utility of Imaging Parameters in Predicting Long-Term Clinical Improvement After Shunt Surgery in Patients with Idiopathic Normal Pressure Hydrocephalus. *World Neurosurgery*. 2021;149:e1-e10. https://doi.org/10.1016/j.wneu.2021.02.108
15. He W, Fang X, Wang X, Gao P, Gao X, Zhou X, Mao R, Hu J, Hua Y, Xia J. A new index for assessing cerebral ventricular volume in idiopathic normal-pressure hydrocephalus: a comparison with Evans' index. *Neuroradiology*. 2020;62(6):661-667. https://doi.org/10.1007/s00234-020-02361-8
16. Mantovani P, Giannini G, Milletti D, Cevoli S, Valsecchi N, Gramegna LL, Albini-Riccioli L, Sturiale C, Cortelli P, Lanzino G, Elder BD, Palandri G; PRO-HYDRO Study Group. Anterior callosal angle correlates with gait impairment and fall risk in iNPH patients. *Acta Neurochirurgica*. 2021;163(3):759-766. https://doi.org/10.1007/s00701-020-04699-7
17. Shinoda N, Hirai O, Hori S, Mikami K, Bando T, Shimo D, Kuroyama T, Kuramoto Y, Matsumoto M, Ueno Y. Utility of MRI-based disproportionately enlarged subarachnoid space hydrocephalus scoring for predicting prognosis after surgery for idiopathic normal pressure hydrocephalus: clinical research. *Journal of Neurosurgery*. 2017;127(6):1436-1442. https://doi.org/10.3171/2016.9.JNS161080
18. Kockum K, Lilja-Lund O, Larsson EM, Rosell M, Söderström L, Virhammar J, Laurell K. The idiopathic normal-pressure hydrocephalus Radscale: a radiological scale for structured evaluation. *European Journal of Neurology*. 2018;25(3):569-576. https://doi.org/10.1111/ene.13555
19. Zemack G, Romner B. Adjustable valves in normal-pressure hydrocephalus: a retrospective study of 218 patients. *Neurosurgery*. 2002;51:1392-1402.
20. Bogolepova AN, Vasenina EE, Gomzyakova NA, Gusev EI, Dudchenko NG, Emelin AYu, Zalutskaya NM, Isaev RI, Kotovskaya YuV, Levin OS, Litvinenko IV, Lobzin VYu, Martynov MU, Mkhitaryan EA, Neznanov NG, Palchikova EI, Tkacheva ON, Cherdak MA, Chimagomedova ASh, Yakhno NN. Clinical Guidelines for Cognitive Disorders in Elderly and Older Patients. *S.S. Korsakov Journal of Neurology and Psychiatry*. 2021;121(10-3): 6-137. (In Russ.). https://doi.org/10.17116/jnevro2021121103
21. Virhammar J, Laurell K, Cesarini KG, Larsson EM. The callosal angle measured on MRI as a predictor of outcome in idiopathic normal-pressure hydrocephalus. *Journal of Neurosurgery*. 2014;120(1):178-184. https://doi.org/10.3171/2013.8.JNS13575
22. Gavrilov GV, Radkov MN, Gydar BV, Svistov DV, Stanishevskiy AV, Averyanov DA. Invasive preoperative diagnostic of idiopathic normal pressure hydrocephalus. *Russian Journal of Neurosurgery*. 2020;22(1):31-38. (In Russ.). https://doi.org/10.17650/1683-3295-2020-22-1-31-38
23. Gavrilov GV, Stanishevskiy AV, Gaydar BV, Svistov DV. Idiopathic normal pressure hydrocephalus. Retrospective review of pathogenesis and modern theories. *Pathological Physiology and Experimental Therapy, Russian Journal*. 2020;64(3):146-155. (In Russ.). https://doi.org/10.25557/0031-2991.2020.03.146-155
24. Tseng P-H, Huang W-T, Wang J-H, Huang B-R, Huang H-Y, Tsai S-T. Cerebrospinal fluid shunt surgery reduces the risk of developing dementia and Alzheimer's disease in patients with idiopathic normal pressure hydrocephalus: a nationwide population-based propensity-weighted cohort study. *Fluids Barriers CNS*. 2024;21(1):16. https://doi.org/10.1186/s12987-024-00517-9
25. Andrén K, Wikkelsø C, Laurell K, Kollén L, Hellström P, Tullberg M. Symptoms and signs did not predict outcome after surgery: a prospective study of 143 patients with idiopathic normal pressure hydrocephalus. *Journal of Neurology*. 2024;271(6):3215-3226. https://doi.org/10.1007/s00415-024-12248-w
26. Adleyba BG, Gavrilov GV, Stanishevskiy AV, Gaydar BV, Svistov DV, Lobzin VYu, Kolmakova KA. Biomarkers of idiopathic normal pressure hydrocephalus. *Nevrologiya, nejrokhirurgiya, psikhosomatika*. 2019;11(1):53-58. (In Russ.). https://doi.org/10.14412/2074-2711-2019-1-53-58
27. Koyama T, Marumoto K, Domen K, Ohmura T, Miyake H. Diffusion tensor imaging of idiopathic normal pressure hydrocephalus: a voxel-based fractional anisotropy study. *Neurologia Medico-Chirurgica*. 2012;52(2):68-74. https://doi.org/10.2176/nmc.52.68
28. Lundin F, Tisell A, Leijon G, Leinhard OD, Davidsson L, Grönqvist A, Wikkelsø C, Lundberg P. Preoperative and postoperative 1H-MR spectroscopy changes in frontal deep white matter and the thalamus in idiopathic normal pressure hydrocephalus. *Journal of Neurology, Neurosurgery and Psychiatry*. 2013;84(2):188-93. https://doi.org/10.1136/jnnp-2012-302190
29. Fattahi N, Arani A, Perry A, Meyer F, Manduca A, Glaser K, Senjem ML, Ehman RL, Huston J. MR Elastography Demonstrates Increased Brain Stiffness in Normal Pressure Hydrocephalus. *American Journal of Neuroradiology*. 2016;37(3):462-7. https://doi.org/10.3174/ajnr.A4560
30. Johannsson B, Munthe S, Poulsen FR, Pedersen CB. Idiopathic normal pressure hydrocephalus; treatment and outcome in the Region of Southern Denmark. *Clinical Neurology and Neurosurgery*. 2022;213:107107. https://doi.org/10.1016/j.clineuro.2021.107107

Received 13.03.2024
Accepted 21.06.2024

COMMENT

The manuscript is devoted to idiopathic normal pressure hydrocephalus and Hakim-Adams syndrome. On the one hand, this problem was studied in sufficient detail; on the other hand, it remains unsolved. Diagnostic algorithm for iNPH currently involves MRI of the head with analysis of signs of communicating hydrocephalus and, in particular, specific signs of iNPH. After that, tap-test is performed. VPS is based on positive tap-test. The authors tried to identify specific MR signs determining the indications for VPS without tap-test. They identified and statistically confirm MR signs necessitating VPS without tap-test in some patients. However, these data cannot be recommended in widespread neurosurgical practice to date, since the modern clinical guidelines for the treatment of iNPH establish the need for tap-test. These data can be used to select patients and make selection qualitative. The results of this study can undoubtedly underlie new clinical guidelines in the future.

Shevchenko K.V. (Moscow)