Burdenko's journal of neurosurgery
2020, №6, pp. 76-85
https://doi.org/10.17116/neiro20208406176

# Completeness of brain aneurysm exclusion according to CT angiography

© YU.V. PILIPENKO, SH.Sh. ELIAVA, I.N. PRONIN, D.N. OKISHEV, A.A. ABRAMYAN

Burdenko Center of Neurosurgery, Moscow, Russia

**ABSTRACT**

**Objective.** To develop a classification of the completeness of brain aneurysm exclusion according to CT angiography for determining further diagnostic and curative strategy.

**Material and methods.** The study included 138 patients who had 164 brain aneurysms. Clipping was carried out at the Burdenko Neurosurgery Center in 2013-2017. Titanium clips were used in 111 cases, cobalt clips — in 53 patients.

**Results.** Completeness of brain aneurysm exclusion was assessed in 149 cases using CT angiography. In 15 cases, artifacts from cobalt clips impaired assessment. Total exclusion was achieved in 136 (91.3%) cases, subtotal (a remainder of residual neck) — in 10 (6.7%) cases, complete exclusion of the body and bottom (patent neck) — 2 (1.3%) patients, partial exclusion (partially patent bottom) — 1 patient (0.7%). In this series, a clip prevented complete contrast enhancement of brain aneurysm bottom in all cases.

**Conclusion.** CTA is a reliable method for assessing the quality of exclusion of brain aneurysm in patients with implanted titanium clips. In case of cobalt clips, stratification depending on severity of CT artifacts should be performed for data interpretation. In some cases, artifacts impair visualization of the vessels adjacent to the clips. In these patients, direct cerebral angiography or dual-energy computed tomography scanners with metal artifact suppression programs should be recommended.

Follow-up is recommended for patients with remnants of residual cervix. Redo surgery is indicated for completely patent neck, as well as partial or complete contrast enhancement of aneurysm bottom.

***Keywords:*** *CT angiography, brain aneurysm, control angiography, completeness of aneurysm exclusion, clip artifacts.*

**INFORMATION ABOUT THE AUTHORS:**
Pilipenko Yu.V. — https://orcid.org/0000-0003-4001-3212; e-mail: 3664656@mail.ru
Eliava Sh.Sh. — https://orcid.org/0000-0001-6103-9329
Pronin I.N. — https://orcid.org/0000-0002-4480-0275
Okishev D.N. — https://orcid.org/0000-0003-0815-5624
Abramyan A.A. — https://orcid.org/0000-0003-2642-7590

**Corresponding author:** Pilipenko Yu.V. — e-mail: 3664656@mail.ru

**TO CITE THIS ARTICLE:**
Pilipenko YuV, Eliava ShSh, Pronin IN, Okishev DN, Abramyan AA. Completeness of brain aneurysm exclusion according to CT angiography. *Burdenko's Journal of Neurosurgery = Zhurnal voprosy neirokhirurgii imeni N.N. Burdenko*. 2020;84(6):76–85. (In Russ.).
https://doi.org/10.17116/neiro20208406176

**Abbreviations:**
BA — brain aneurysm
CT — computed tomography
CTA — computed tomography angiography
MCA — middle cerebral artery
CAG — cerebral angiography

In recent years, CT angiography (CTA) has been increasingly used to assess the completeness of BA exclusion. This method is distinguished by high speed and minimal invasiveness [1]. At the same time, artifacts from clips and other factors can influence estimation of BA exclusion quality [2, 3]. Modern classifications of BA exclusion quality do not ensure exhaustive answers about the sufficiency of control CTA and the need for additional subtraction cerebral angiography (CAG), as well as the strategy for incomplete BA exclusion.

The purpose of the study was to develop the CTA-based classification of completeness of BA exclusion quality for determining the further diagnostic and treatment strategy.

## Material and methods

BA exclusion quality was evaluated in 138 patients who underwent surgery at the Burdenko Neurosurgery Center in 2013—2017. Age of patients ranged from 20 to 78 years (mean 48 years). There were 90 females and 48 males.

There were 179 BAs in 138 patients. Multiple aneurysms were diagnosed in 42 (30.4%) patients. Hemorrhage occurred in 66 patients, and 18 of them were operated within 14 days after hemorrhage. There were 72 patients without hemorrhage. Aneurysm neck clipping was performed in 164 cases. In 15 patients with multiple BAs and small aneurysms (less than 2 mm), surgery was rejected. In most cases, clipped BAs were small (2—5 mm, $n = 70$) and medium (6—14 mm, $n = 79$). Large aneu-

***Table 1.*** **Artifacts and aneurysm exclusion quality in various types of clips.**

| Type of clips | Arterial brain aneurysm, *n* | Artifact grade | | | | Quality | | | | |
|---|---|---|---|---|---|---|---|---|---|---|
| | | A0 | A1 | A2 | A3 | R1 | R2 | R3 | R4 | R? * |
| Sugita II (titanium) | 81 | 81 | — | — | — | 73 | 6 | 1 | 1 | — |
| Neuron-N (cobalt) | 53 | 9 | 29 | 13 | 2 | 34 | 3 | 1 | — | 15 |
| Aesculap (titanium) | 23 | 23 | — | — | — | 22 | 1 | — | — | — |
| Neuron-N (titanium) | 7 | 7 | — | — | — | 7 | — | — | — | — |
| Total | 164 | 120 | 29 | 13 | 2 | 136 | 10 | 2 | 1 | 15 |

Note: * — R? — aneurysm exclusion quality could not be assessed due to clip-related artifacts.

rysms (15—24 mm) were clipped in 15 cases. All clipped aneurysms were saccular. Patients with fusiform and giant aneurysms were not analyzed in this manuscript, since more difficult procedures and direct CAG are usually required in these cases.

Titanium clips Sugita II (Mizuho Corporation, Japan, ISO 5832-3) were applied in 81 cases; cobalt clips (alloy 40KHNM-PN, GOST 14118-85, LLC "Neuron-N", Russia) — 53 cases; titanium clips Yasargil ("Aesculap", B. Braun company, Germany, ISO 5832-3) — in 23 cases, titanium clips Neuron-N ( Russia, alloy BT6, GOST 19807) — in 7 cases. In total, we deployed 244 clips to exclude 164 aneurysms (mean 1.5 clips per one aneurysm).

CTA in 3—7 days after surgery was performed in 52 patients with 62 BAs, after 1 year — in 86 patients with 102 aneurysms. Indications for control CTA in early postoperative period: 1) arterial aneurysms with complex anatomical characteristics (large dimension, wide neck, atherosclerotic walls, etc.); 2) surgeon's doubts regarding the completeness of BA exclusion.

CTA was performed using various CT scanners. Most of patients underwent control survey in diagnostic centers at their place of residence. Seventy-three patients underwent CTA at the Burdenko Neurosurgery Center (64-slice OPTIMA CT scanner, GE Healthcare, USA). Slice width was 0.625 mm. In this research, we were interested in interpretation of survey data and subsequent CTA-based clinical strategy rather examination protocols and correlation with various CT scanners. The images were visualized in a DICOM viewer (Inobitek LLC, Russia) with processing in Maximum Intensity projection (MIP) mode.

## Results

Artifacts from the clips were absent in all patients with titanium clips (regardless their number). At the same time, cobalt clips were followed by artifacts (interference) in the majority (83%) of patients. We have developed the following classification of clip-induced artifacts:

1) A0 — no artifacts **(Fig. 1);**

2) A1 — artifacts not impairing visualization of the vessels adjacent to the clips **(Fig. 2);**

3) A2 — artifacts impairing visualization of the vessels adjacent to the clips **(Fig. 3);**

4) A3 — artifacts impairing visualization of the vessels adjacent to the clips and distant vessels **(Fig. 4).**

In case of grades A0 and A1, imaging was satisfactory for assessing the BA exclusion quality. Grades A2 and A3 determined unsatisfactory imaging and CAG was advised.

Spearman's rank correlation revealed a direct relationship between the higher number of cobalt clips installed and severity of artifacts ($r = 0.5$, $p < 0.01$). Visualization was satisfactory in 84% of patients with one cobalt clip and 42% in several cobalt clips ($\chi^2$ test, $p < 0.01$).

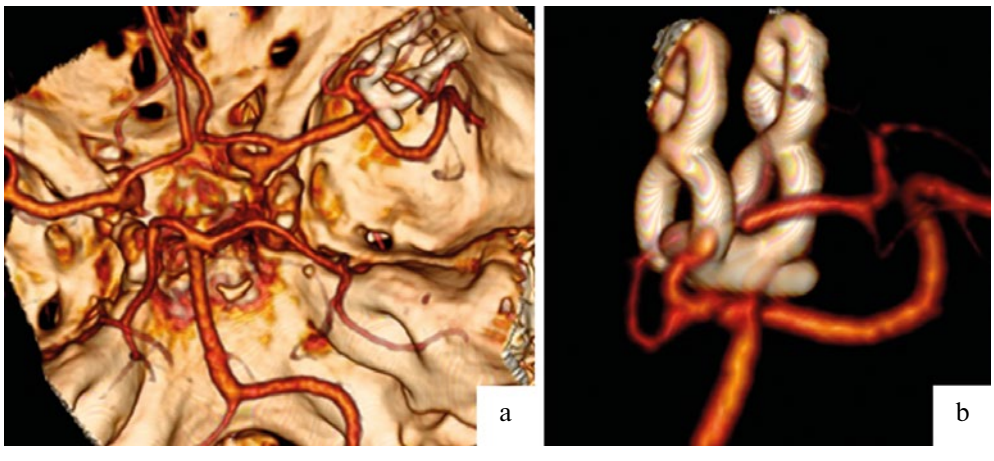


***Fig. 1.*** **3D CTA. No clip-related artifacts. a — circle of Willis; b — clips within the bifurcation of the right middle cerebral artery.**

For all types of clips (titanium and cobalt), BA exclusion quality was assessed in 149 cases with visualization grade A0 and A1 **(Table 1).**

We have used our own classification to estimate BA exclusion quality **(Fig. 5):**

R1 — total aneurysm exclusion;

R2 — subtotal aneurysm exclusion (partial contrast enhancement of the neck);

R3 — complete exclusion of aneurysm body and bottom (complete contrast enhancement of the neck within 1–3 mm without diverticula and additional chambers);

R4 — partial aneurysm exclusion (partial contrast enhancement of aneurysm bottom, another chamber of BA or diverticulum within the neck);

R5 — no aneurysm exclusion (complete contrast enhancement of aneurysm bottom or other area caused hemorrhage).

Total exclusion (R1) was achieved in 136 (91.3%) out of 149 cases with satisfactory CT visualization. Subtotal exclusion (R2) was found in 10 (6.7%) cases. An example is shown in **Fig. 6**. These patients were followed-up and repeated CT was recommended after a year.

Complete exclusion of aneurysm body and bottom with persistent contrast enhancement of the aneurysm neck (R3) was ensured in 2 (1.3%) cases. One of these cases is shown in **Fig. 7.** Elective redo surgery was recommended in both patients.

Partial exclusion (R4) was diagnosed only in 1 (0.7%) patient after unsuccessful contralateral clipping of middle

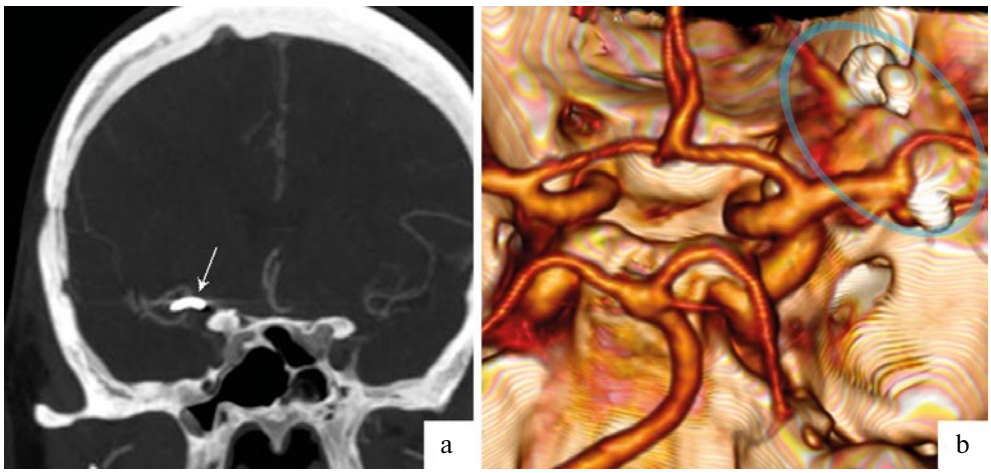


***Fig. 2.*** **CTA. Moderate number of clip-related artifacts.**

a — frontal MIP image. Bifurcation of the right middle cerebral artery is well-visible. The clip is indicated by an arrow; b — 3D reconstruction. Clip-related artifacts (blue line).

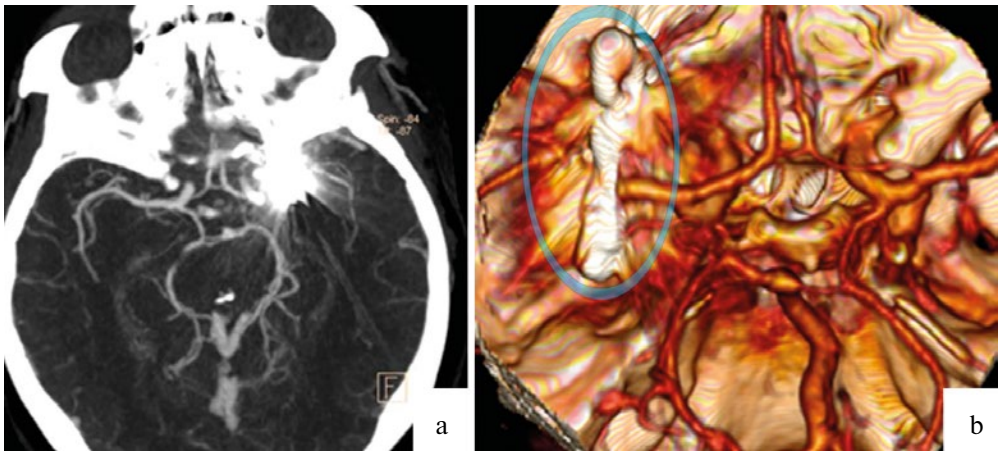


***Fig. 3.*** **CTA. Significant number of clip-related artifacts.**

a — axial MIP image. Bifurcation of the left middle cerebral artery is not visible due to artifacts, other arteries of circle of Willis are clearly visible; b — 3D reconstruction. Clip-related artifacts within the bifurcation of the middle cerebral artery on the left are circled with a blue line.

cerebral artery (MCA) aneurysm. Redo surgery with ipsilateral clipping of residual aneurysm was carried out 3 days later **(Fig. 8).**

R5 grade was absent in our sample (clip does not prevent complete contrast enhancement of the aneurysm bottom).

CTA-based assessment of BA exclusion quality was impossible in 12 patients with 15 aneurysms. Therefore, direct CAG was recommended.

## Discussion

An importance of postoperative control of BA exclusion quality is beyond doubt. According to large studies, incompletely clipped BAs are detected in 5.2–8.2% of patients [4–8], while intracranial hemorrhage after BA clipping occurs in 1–2% of cases [5, 7, 9].

In contrast to endovascular interventions with intraoperative control of BA exclusion quality, these methods are not exhaustive during microsurgical operations. For example, BA bottom dissection after clipping may not ensure information about filling the neck or other residual chamber. Intraoperative fluorescent angiography is also associated with common errors. Indeed, contrast agent in BA may be invisible through a thickened atherosclerotic wall of aneurysm. Moreover, patent segment may be hidden by adjacent vessel or even remain invisible due to insufficient surgical dissection of dense adhesions [10].

Direct CAG is a gold standard for assessing the BA exclusion quality [11-14]. However, this approach seems inappropriate in all patients at the present stage due to invasiveness and higher cost while CTA is often an adequate alternative to CAG. However, CTA sensitivity depends on the artifacts associated with metal clips. Some authors reported low informative value of CTA after aneurysm clipping in 28.6–34% of cases, especially in case of patent residual part < 2 mm [3, 15].

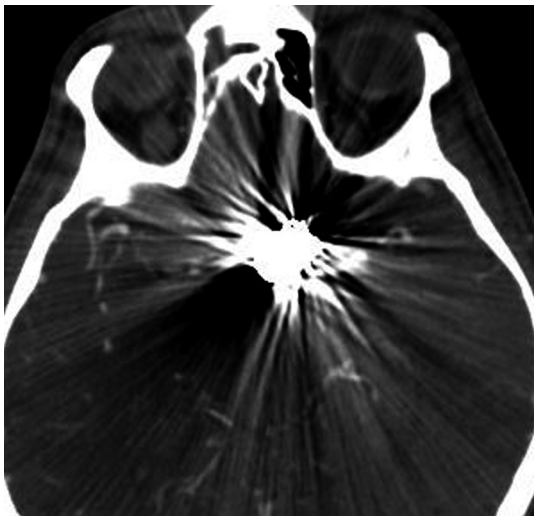

***Fig. 4.*** **CTA. Significant number of clip-related artifacts. Axial MIP image. Circle of Willis is not visible due to clip-related artifacts within the bifurcation of the left internal carotid artery.**

It is known that significant number of CT artifacts is associated with cobalt clips [16, 17]. Titanium clips usually result a small number of artifacts [14, 18, 19]. Some authors reported similar specificity and sensitivity of CTA and direct CAG for titanium clips [14, 20]. There is also a direct correlation between the number of clips and CT artifacts [3, 11, 14, 17, 21].

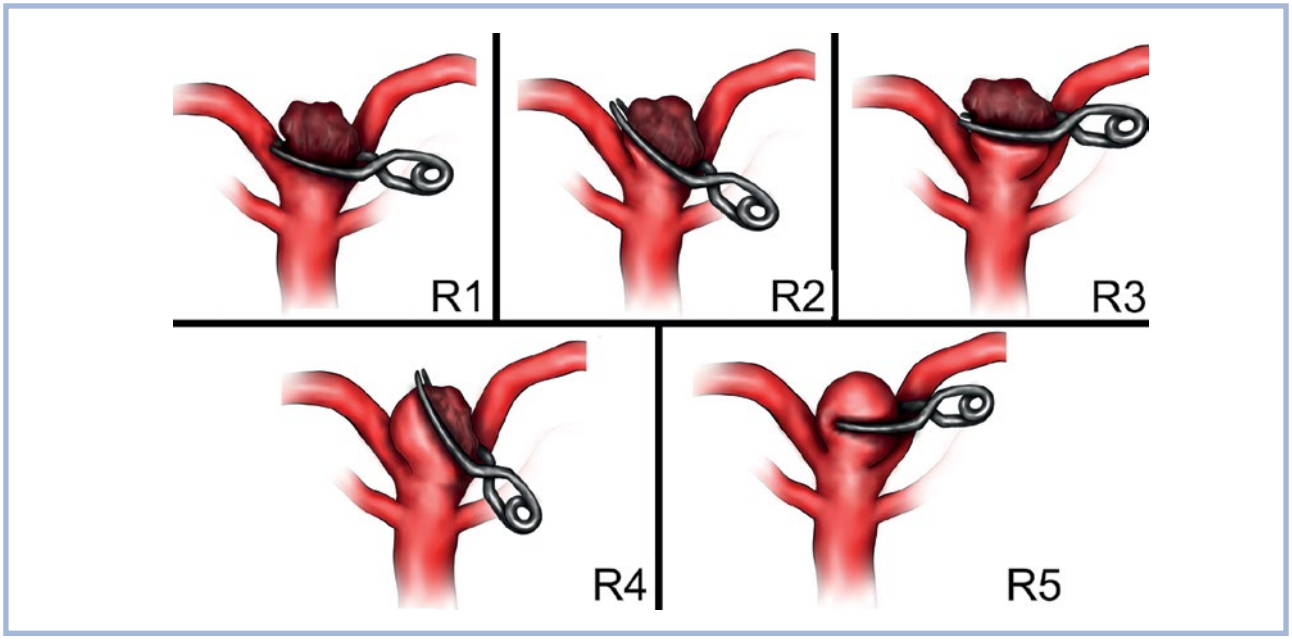


***Fig. 5.*** **BA exclusion quality. Explanations in the text.**

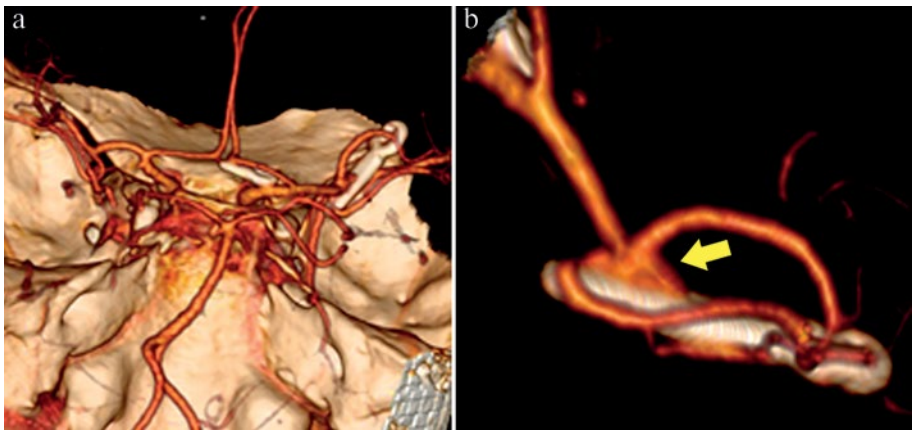


***Fig. 6.*** **Patient Sh., 50 years old. 3D CTA after clipping of aneurysms of anterior communicating artery and middle cerebral artery on the right. a — brain base vessels; b — region of a clipped aneurysm of the middle cerebral artery on the right. Small residual neck (arrow).**

It was noted that clips located perpendicular to scanning plane give less artifacts compared to clips oriented parallel to horizontal plane of CT scanner [3, 17, 22]. CTA data interpretation is more difficult in case of fenestrated clips [21].

Obviously, the latest technical innovations make it possible to improve CT imaging after clipping. In particular, modern protocols and scanning programs (metal artifact reduction software, MARs) [1, 2, 21, 23], dual-energy CT scanner [3, 23] and 4D CTA [21] are valuable for this purpose. MRI after clipping is inferior to CTA in diagnostic value since even titanium clips result artifacts in magnetic field [24, 25].

CTA classifications of clip-induced artifacts regardless vascular pools are more common in the literature [2, 17, 26].

In our study, we used 4 grades of clip-induced artifacts (A0, A1, A2, A3). We have divided the grades which were uninformative for BA exclusion assessment depending on the effect of artifacts on visualization of adjacent and distant arteries. Thus, the arteries of other pools may be analyzed in grade A2 that is important for multiple BA. At the same time, this possibility is absent for grade A3.

Some authors use the concept of "survey quality" in assessment of clipping outcomes [11, 14, 17, 27]. This approach is determined other factors rather clip-induced artifacts. For example, favorable imaging is achieved through scanning in arterial phase, no patient moving, etc. Undoubtedly, these aspects are essential for informative assessment of clipping quality and avoiding repeated examinations. In case of adequate quality of CTA, estimation of BA exclusion quality is the main question.

Some classifications divide BAs into totally clipped, partially clipped and patent (unclipped) [14, 28, 29]. The Raymond — Roy classification proposed for endovascular neurosurgery [30] also includes 3 classes. This grading system is often adapted for microsurgery **(Table 2).**

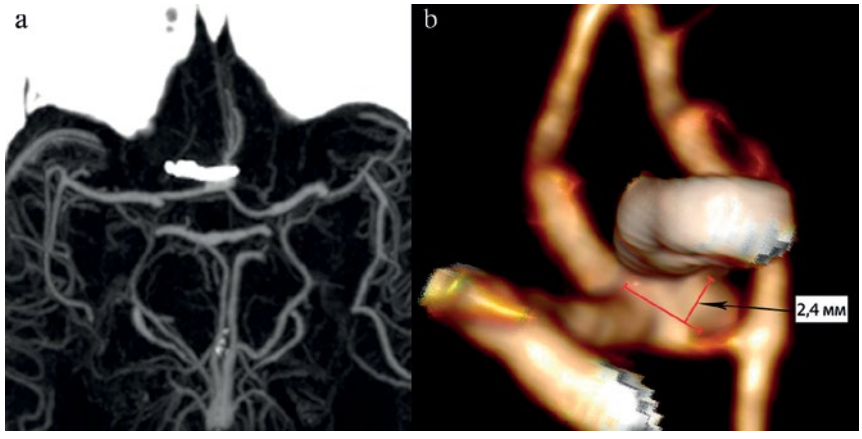


***Fig. 7.*** **Patient M., 41 years old. CTA after clipping of aneurysm of anterior communicating artery. a — brain base vessels; b — clipping area, 3D reconstruction. Residual neck with a height of 2.4 mm.**

A 5-point Sindou's classification is the most common for assessing the quality of microsurgical procedures [4, 11, 27, 31] **(Table 2).** In our opinion, the disadvantage of this classification is conventional definition of patent residues (as a percentage of baseline dimensions).

In our research, we used 5 degrees of BA exclusion **(Fig. 5).**

It would seem that total exclusion (R1 in our classification) should not cause controversy. However, the question of total exclusion and BA remnants on angiograms is discussed in the literature [6]. Some authors classify contrast-enhanced segment of BA over 1 mm as a minimal remnant [6, 32]. We agree with this criterion and consider any contrast-enhanced parts over 1 mm to be the remnant of arterial BA.

R2 exclusion in our research means residual part of the neck. C.A. David et al. [7] called such residual parts of the neck as "dog-ear". In most cases, these structures are stable in further long-term angiographic surveys and do not require redo surgery [7, 8, 33].

Patent neck of the aneurysm is designated as R3 in our classification. It is known that residual parts of this type are prone to enlargement and rupture in long-term postoperative period [5, 7]. Therefore, elective redo surgery is advisable in these patients if contraindications are absent. In this case, the main controversial point is a question about the neck on X-ray scans. What is a neck on these images? Where does the BA body begin? W.E. Stehbens performed histopathological studies using electron microscopy. They reported internal elastic membrane in the aneurysm neck in contrast to its body. This makes the neck more durable [34]. These differences are not visible during angiography, and researchers usually determine proximal part of the aneurysm as its neck [4, 7, 30]. Thus, in the CARAT study [5], residual neck was determined as a region making up 1–30% of baseline aneurysm dimension. In accordance with this rule, medium-sized arterial BA with a total height of 14 mm should have the neck height ⩽ 4.2 mm, large arterial BA with a total height of 24 mm — ⩽ 7.2 mm. Of course, this dimension is large enough to consider this part as a neck, especially since dimension of the neck with intact internal elastic membrane is proportional to BA size [34]. We understand the conventionality of all these measurements. Therefore, we consider a 3-mm part of the aneurysm proximal to the clip as residual neck.

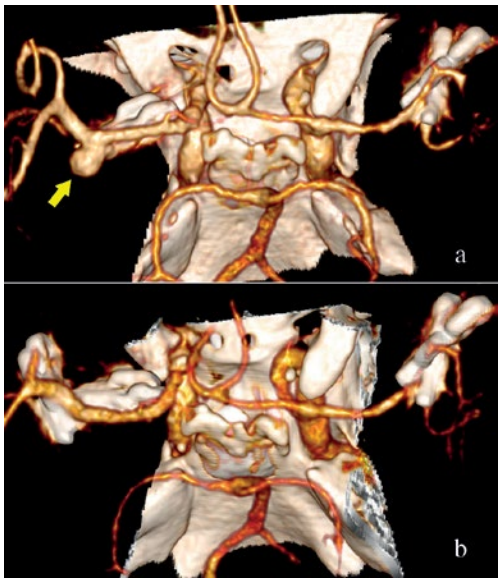


***Fig. 8.*** **Patient P., 62 years old. 3D CTA. a — examination after primary surgery, residual bottom of the left middle cerebral artery aneurysm (arrow); b — total aneurysm exclusion during redo surgery.**

R4 exclusion was determined as detection of any part of BA bottom or contrast enhancement of additional chambers. It is known that BA rupture usually occurs within the thinned wall (aneurysm bottom and, especially, diverticula) [34–36]. That is why early relapses of hemorrhages are typical of such remnants [5, 9].

In our opinion, the risk of postoperative hemorrhage may be less if the clip excludes the high-risk area or a thinned part of unruptured aneurysm (diverticulum). This is the main difference between R4 and R5 grades. In the last case, aneurysm bottom is completely contrasted.

We are sure that redo surgery is necessary for grades R4 and R5. Moreover, early procedure is advisable in the last case.

Thus, CTA-based assessment of BA exclusion quality should be carried out considering 2 criteria: severity of clip-induced artifacts and aneurysm exclusion quality.

## Conclusion

Computed tomography angiography is a reliable method for assessing the BA exclusion quality in patients

***Table 2.*** **Classification of brain aneurysm occlusion.**

| M. Sindou, 1997 [4] | Raymond-Roy, 2001 [30] | CARAT, 2008 [5] |
|---|---|---|
| 1) aneurysmal remnant less than 50% of neck size;<br>2) aneurysmal remnant over 50% of neck size;<br>3) residual sac of multilobulated BA;<br>4) residual sac less than 75% of aneurysmal size;<br>5) residual sac over 75% of aneurysmal size. | I. Total occlusion.<br>II. Residual neck.<br>III. Residual aneurysm. | 1. Complete obliteration (100%).<br>2. Small residual neck (91—99% of baseline aneurysm).<br>3. Residual neck (70—90% of baseline aneurysm).<br>4. Residual aneurysm (1—69% of baseline aneurysm).<br>5. No obliteration (0%). |

with titanium clips implanted. CT-based stratification depending on severity of clip-induced artifacts is required for data interpretation in patients with cobalt clips. In case of artifact-related impairment of visualization of adjacent vessels, direct cerebral angiography or dual-energy CT with metal artifact suppression programs should be recommended.

Follow-up is recommended in patients with residual neck of BA after clipping. Patent neck of aneurysm and partial or complete contrasting of aneurysm bottom require redo surgery.

**Authors' participation:**
Concept and design of the study — Pilipenko Yu.V.
Collection and analysis of data — Pilipenko Yu.V., Okishev D.N.
Statistical analysis — Pilipenko Yu.V.
Writing the text — Pilipenko Yu.V.
Artistic design — Abramyan A.A.
Editing — Eliava Sh.Sh., Pronin I.N.

**No conflict of interests to declare.**

## REFERENCES

1. Krylov VV, Grigorieva EV. *KT-angiografiya anevrizm golovnogo mozga.* M.: OOO Print-Studio, 2020. (In Russ.)
2. Bier G, Bongers MN, Hempel JM, Örgel A, Hauser TK, Ernemann U, Hennersdorf F. Follow-up CT and CT angiography after intracranial aneurysm clipping and coiling-improved image quality by iterative metal artifact reduction. *Neuroradiology*. 2017;59(7):649-654. https://doi.org/10.1007/s00234-017-1855-6
3. Dolati P, Eichberg D, Wong JH, Goyal M. The Utility of Dual-Energy Computed Tomographic Angiography for the Evaluation of Brain Aneurysms After Surgical Clipping: A Prospective Study. *World Neurosurgery*. 2015;84(5):1362-1371. https://doi.org/10.1016/j.wneu.2015.06.027
4. Acevedo JC, Turjman F, Sindou M. Postoperative arteriography in surgery for intracranial aneurysm. Prospective study in a consecutive series of 267 operated aneurysms. *Neurochirurgie*.1997;43(5):275-284.
5. Johnston SC, Dowd CF, Higashida RT, Lawton MT, Duckwiler GR, Gress DR; CARAT Investigators. Predictors of rehemorrhage after treatment of ruptured intracranial aneurysms: the Cerebral Aneurysm Rerupture after Treatment (CARAT) study. *Stroke*. 2008;39(1):120-125. https://doi.org/10.1161/STROKEAHA.107.495747
6. Thornton J, Bashir Q, Aletich VA, Debrun GM, Ausman JI, Charbel FT. What percentage of surgically clipped intracranial aneurysms have residual necks? *Neurosurgery*. 2000;46(6):1294-1298; discussion 1298-1300. https://doi.org/10.1097/00006123-200006000-00003
7. David CA, Vishteh AG, Spetzler RF, Lemole M, Lawton MT, Partovi S. Late angiographic follow-up review of surgically treated aneurysms. *Journal of Neurosurgery.* 1999;91(3):396-401. https://doi.org/10.3171/jns.1999.91.3.0396
8. Brown MA, Parish J, Guandique CF, Payner TD, Horner T, Leipzig T, Rupani KV, Kim R, Bohnstedt BN, Cohen-Gadol AA. A long-term study of durability and risk factors for aneurysm recurrence after microsurgical clip ligation. *Journal of Neurosurgery*. 2017;126(3):819-824. https://doi.org/10.3171/2016.2.JNS152059
9. Molyneux AJ, Kerr RS, Yu LM, Clarke M, Sneade M, Yarnold JA, Sandercock P. International subarachnoid aneurysm trial (ISAT) of neurosurgical clipping versus endovascular coiling in 2143 patients with ruptured intracranial aneurysms: a randomised comparison of effects on survival, dependency, seizures, rebleeding, subgroups, and aneurysm occlusion. *Lancet*. 2005;366(9488):809-817. https://doi.org/10.1016/S0140-6736(05)67214-5
10. Roessler K, Krawagna M, Dörfler A, Buchfelder M, Ganslandt O. Essentials in intraoperative indocyanine green videoangiography assessment for intracranial aneurysm surgery: conclusions from 295 consecutively clipped aneurysms and review of the literature. *Neurosurgical Focus*. 2014;36(2):E7. https://doi.org/10.3171/2013.11.FOCUS13475
11. Gerardin E, Tollard E, Derrey S, Langlois O, Dacher JN, Douvrin F, Freger P, Proust F. Usefulness of multislice computerized tomographic angiography in the postoperative evaluation of patients with clipped aneurysms. *Acta Neurochirurgica*. 2010;152(5):793-802. https://doi.org/10.1007/s00701-009-0465-4
12. Sagara Y, Kiyosue H, Hori Y, Sainoo M, Nagatomi H, Mori H. Limitations of three-dimensional reconstructed computerized tomography angiography after clip placement for intracranial aneurysms. *Journal of Neurosurgery.* 2005;103(4):656-661. https://doi.org/10.3171/jns.2005.103.4.0656
13. Uricchio M, Gupta S, Jakowenko N, Levito M, Vu N, Doucette J, Liew A, Papatheodorou S, Khawaja AM, Aglio LS, Aziz-Sultan MA, Zaidi H, Smith TR, Mekary RA. Computed Tomography Angiography Versus Digital Subtraction Angiography for Postclipping Aneurysm Obliteration Detection. *Stroke*. 2019;50(2):381-388. https://doi.org/10.1161/STROKEAHA.118.023614
14. Dehdashti AR, Binaghi S, Uske A, Regli L. Comparison of multislice computerized tomography angiography and digital subtraction angiography in the postoperative evaluation of patients with clipped aneurysms. *Journal of Neurosurgery.* 2006;104(3):395-403. https://doi.org/10.3171/jns.2006.104.3.395
15. Pechlivanis I, Koenen D, Engelhardt M, Scholz M, Koenig M, Heuser L, Harders A, Schmieder K. Computed tomographic angiography in the evaluation of clip placement for intracranial aneurysm. *Acta Neurochirurgica*. 2008;150(7):669-676. https://doi.org/10.1007/s00701-008-1515-z
16. van der Schaaf I, van Leeuwen M, Vlassenbroek A, Velthuis B. Minimizing clip artifacts in multi CTangiography of clipped patients. *AJNR American Journal of Neuroradiology*. 2006;27(1):60-66.
17. Zachenhofer I, Cejna M, Schuster A, Donat M, Roessler K. Image quality and artefact generation post-cerebral aneurysm clipping using a 64-row multislice computer tomography angiography (MSCTA) technology: a retrospective study and review of the literature. *Clinical Neurology and Neurosurgery.* 2010;112(5):386-391. https://doi.org/10.1016/j.clineuro.2010.02.001
18. Lee YH, Park KK, Song HT, Kim S, Suh JS. Metal artefact reduction in gemstone spectral imaging dual-energy CT with and without metal artefact reduction software. *European Radiology.* 2012;22(6):1331-1340. https://doi.org/10.1007/s00330-011-2370-5
19. Nagatani T, Shibuya M, Ooka K, Suzuki Y, Takayasu M, Yoshida J. Titanium aneurysm clips: mechanical characteristics and clinical trial. *Neurologia Medico-Chirurgica*. 1998;38(Suppl):39-44. https://doi.org/10.2176/nmc.38.suppl_39
20. Uysal E, Ozel A, Erturk SM, Kirdar O, Basak M. Comparison of multislice computed tomography angiography and digital subtraction angiography in the detection of residual or recurrent aneurysm after surgical clipping with titanium clips. *Acta Neurochirurgica*. 2009;151(2):131-135. https://doi.org/10.1007/s00701-009-0184-x
21. Kimura Y, Mikami T, Miyata K, Suzuki H, Hirano T, Komatsu K, Mikuni N. Vascular assessment after clipping surgery using four-dimensional CT angiography. *Neurosurgical Review*. 2019;42(1):107-114. https://doi.org/10.1007/s10143-018-0962-0
22. Brown JH, Lustrin ES, Lev MH, Ogilvy CS, Taveras JM. Reduction of aneurysm clip artifacts on CTangiograms: a technical note. *American Journal of Neuroradiology*. 1999;20(4):694-696.
23. Dunet V, Bernasconi M, Hajdu SD, Meuli RA, Daniel RT, Zerlauth JB. Impact of metal artifact reduction software on image quality of gemstone spectral imaging dual-energy cerebral CT angiography after intracranial aneurysm clipping. *Neuroradiology*. 2017;59(9):845-852. https://doi.org/10.1007/s00234-017-1871-6
24. Van Loon JJ, Yousry TA, Fink U, Seelos KC, Reulen HJ, Steiger HJ. Postoperative spiral computed tomography and magnetic resonance angiography after aneurysm clipping with titanium clips. *Neurosurgery*. 1997;41(4):851-856; discussion 856-857. https://doi.org/10.1097/00006123-199710000-00016
25. Friedrich B, Wostrack M, Ringel F, Ryang YM, Forschler A, Waldt S, Zimmer C, Nittka M, Preibisch C. Novel metal artifact reduction techniques with use of slice-encoding metal artifact correction and view-angle tilting

MR imaging for improved visualization of brain tissue near intracranial aneurysm clips. *Clinical Neuroradiology*. 2016;26(1):31-37. https://doi.org/10.1007/s00062-014-0324-4

26. Pan YN, Chen G, Li AJ, Chen ZQ, Gao X, Huang Y, Mattson B, Li S. Reduction of Metallic Artifacts of the Post-treatment Intracranial Aneurysms: Effects of Single Energy Metal Artifact Reduction Algorithm. *Clinical Neuroradiology*. 2019;29(2):277-284. https://doi.org/10.1007/s00062-017-0644-2
27. Golitz P, Struffert T, Ganslandt O, Lang S, Knossalla F, Doerfler A. Contrast-enhanced angiographic computed tomography for detection of aneurysm remnants after clipping: a comparison with digital subtraction angiography in 112 clipped aneurysms. *Neurosurgery*. 2014;74(6):606-614. https://doi.org/10.1227/neu.0000000000000326
28. Macdonald RL, Wallace MC, Kestle JR. Role of angiography following aneurysm surgery. *Journal of Neurosurgery.* 1993;79(6):826-832. https://doi.org/10.3171/jns.1993.79.6.0826
29. Le Roux PD, Elliott JP, Eskridge JM, Cohen W, Winn HR. Risks and benefits of diagnostic angiography after aneurysm surgery: a retrospective analysis of 597 studies. *Neurosurgery.* 1998;42(6):1248-1254. https://doi.org/10.1097/00006123-199806000-00026
30. Roy D, Milot G, Raymond J. Endovascular treatment of unruptured aneurysms. *Stroke.* 2001;32(9):1998-2004. https://doi.org/10.1161/hs0901.095600
31. Jabbarli R, Pierscianek D, Wrede K, Dammann P, Schlamann M, Fors-ting M, Muller O, Sure U. Aneurysm remnant after clipping: the risks and consequences. *Journal of Neurosurgery*. 2016;125(5):1249-1255. https://doi.org/10.3171/2015.10.JNS151536
32. Rauzzino MJ, Quinn CM, Fisher WS 3rd. Angiography after aneurysm surgery: Indications for «selective» angiography. *Surgical Neurology.* 1998;49(1):32-41. https://doi.org/10.1016/s0090-3019(97)00035-9
33. Feuerberg I, Lindquist C, Lindqvist M, Steiner L. Natural history of postoperative aneurysm rests. *Journal of Neurosurgery.* 1987;66(1):30-34. https://doi.org/10.3171/jns.1987.66.1.0030
34. Stehbens WE. Histopathology of cerebral aneurysms. *Archives of Neurology*. 1963;8:272-285. https://doi.org/10.1001/archneur.1963.00460030056005
35. Shah AD, Harris JL, Kyriacou SK, Humphrey JD. Further roles of geometry and properties in saccular aneurysm mechanics. *Computer Methods in Biomechanics and Biomedical Engineering*. 1997;1(2):109-121.
36. Steiger HJ, Aaslid R, Keller S, Reulen HJ. Strength, elasticity and viscoelastic properties of cerebral aneurysms. *Heart and Vessels*. 1986;5(1):41-46. https://doi.org/10.1007/bf02058357

Received 16.02.2020
Accepted 03.07.2020

## Commentary

The manuscript is devoted to an actual issue — long-term postoperative outcomes in patients with intracranial aneurysms and assessment of BA exclusion quality. The value of various diagnostic methods in initial assessment of unruptured aneurysms and non-traumatic subarachnoid hemorrhage is known. Modern protocols take into account the strengths and weaknesses of each method. At the same time, diagnostic algorithm after aneurysm exclusion is unclear in the modern literature. There is no consensus regarding timing of X-ray diagnosis, choice of technique and criteria for assessing the aneurysm exclusion quality. This is partly due to fast development of computed tomography (CT) and magnetic resonance imaging (MRI), programs for metal artifact signal suppression. Therefore, there is a possibility to replace invasive cerebral angiography (CAG).

The authors reported original classification of CT artifacts after aneurysm clipping. This classification will ensure a differentiated approach to postoperative X-ray survey. It would be advisable to analyze CT scans in patients with various clips and show the risk of significant artifacts (A4) depending on the number and material of clips (for example, odds ratio). This would make it possible to conclude advisability of CAG or 3T MRI for aneurysm exclusion quality assessment in patients with 3 or more cobalt clips. CT angiography is not informative and undesirable in these cases due to advanced irradiation.

Original classification of aneurysm exclusion quality seems to be useful. It is simpler than previous grading systems. Importantly, new classification can be used even in the absence of preoperative CT angiograms, although comparison with primary data is always desirable. However, I would like to see clearer exclusion criteria in material and methods heading that would clarify discussion. It should be noted that all previous classifications are not based on long-term follow-up. It is not understood exactly what the minimum size of residual aneurysm is associated with high risk of growth and subsequent rupture. Perhaps, new original classification will answer this question in a retrospective analysis of clipped aneurysms.

Thus, the manuscript is very useful for neurosurgeons and specialists for radiological diagnosis and justifies further research.

*E.V. Grigorieva (Moscow, Russia)*