Burdenko's journal of neurosurgery
2020, №6, pp. 67-75
https://doi.org/10.17116/neiro20208406167

# Skull defect repair in children using a 3D-printing technology

© K.A. SULIN, V.P. IVANOV, A.V. KIM, V.A. KHACHATRYAN

Almazov National Medical Research Center, Saint-Petersburg, Russia

**ABSTRACT**

Currently, 3D-printing technologies are increasingly used in neurosurgery. Active development of this approach is valuable to improve preoperative planning, intraoperative navigation, and manufacturing of realistic training models. In this manuscript, the authors report an experience of the pediatric neurosurgical department of the Almazov National Medical Research Center regarding 3D-printing technologies in manufacturing of individual implants for skull defect closure. The main aspects of this technology, advantages and disadvantages are considered. Moreover, the authors describe several cases of creating individual implants for children with skull defects of various origins, dimensions and complexity.

***Keywords:*** *3D printing, cranioplasty, preoperative planning, additive technologies, traumatic brain injury.*

**INFORMATION ABOUT THE AUTHORS:**
Sulin K.A. — https://orcid.org/0000-0001-6794-2420; e-mail: konstantinsulin92@gmail.com
Ivanov V.P. — https://orcid.org/0000-0002-1009-4077
Kim A.V. — https://orcid.org/0000-0002-6219-7270
Khachatryan V.A. — https://orcid.org/0000-0002-1635-6621

**Corresponding author:** Sulin K.A. — e-mail: konstantinsulin92@gmail.com

**TO CITE THIS ARTICLE:**
Sulin KA, Ivanov VP, Kim AV, Khachatryan VA. Skull defect repair in children using a 3D-printing technology. *Burdenko's Journal of Neurosurgery = Zhurnal voprosy neirokhirurgii imeni N.N. Burdenko*. 2020;84(6):67–75. (In Russ.). https://doi.org/10.17116/neiro20208406167

**Abbreviations**
CT — computed tomography
F — frontal region
FPT — fronto-parieto-temporal region
P — parietal region
PT — parieto-temporal region

Cranioplasty is one of the urgent problems of neurosurgery [1]. Skull defects are usually divided into congenital and acquired ones. These defects are associated with an increased risk of brain trauma and psychoemotional discomfort following cosmetic defect regardless the reasons of skull defects [2].

One of important problems in patients with skull defects is a syndrome of the trephined. The last one was described as early as 1939 by F.C. Grant and N.C. Norcross [3]. Another aspect is sinking skin flap syndrome described by A. Yamaura and N. Makino [4]. Both syndromes are characterized by similar symptoms. The main clinical manifestations of skull defect are headache, motor and cognitive deficit, speech disorders and local pain. Fear of possible damage to intracranial structures often results anxiety and depressive disorders in patients [5–7]. Thus, skull repair is a necessary component in rehabilitation of these patients.

3D printing has been widely applied in medicine [9–11] since the development of stereolithography by C. Hull [8]. Currently, 3D modeling and printing are used for training the young specialists [12, 13], preoperative planning and intraoperative navigation, selection of optimal approach and surgical procedure [14, 15], creation of individual instruments and devices for a particular patient [15, 16]. These methods are also used in cranioplasty.

There are several approaches to 3D printing of implants for skull repair. One of the methods is 3D modeling using various materials. Such implants are convenient, but they have certain limitations: high cost, need for special equipment, difficult modeling of some anatomical structures [17]. Another approach is manufacturing a model of skull with a defect for preoperative preparation of the implant considering individual characteristics of a patient.

The purpose of the study was to analyze the effectiveness of 3D modeling in skull repair for giant and complex defects in children.

## Material and methods

Skull repair was carried out in 10 patients aged 1.4 — 17 years with giant and complex skull defects for the period from May to November 2019. All procedures were performed at the Almazov Research Center (Department of Pediatric Neurosurgery). At the preoperative stage,

***Table*. Characteristics of patients with skull defects.**

| Patient | Sex | Age, years | Surgery time, min | Blood loss, ml | Location of defect |
|---|---|---|---|---|---|
| 1 | F | 6 | 225* | 50 | Right FPT area |
| 2 | M | 7 | 70 | 30 | Right PT area |
| 3 | F | 1 year 4 months | 70 | 30 | Right parietal area |
| 4 | M | 15 | 130 | 150 | Frontal area |
| 5 | M | 10 | 190** | 50 | Bilateral FPT area |
| 6 | M | 7 | 80 | 50 | Left PT area |
| 7 | F | 13 | 100 | 70 | Right FPT area |
| 8 | M | 8 | 70 | 30 | Right FPT area |
| 9 | F | 8 | 90 | 50 | Right FPT area |
| 10 | M | 11 | 80 | 50 | Right PT area |

*Note.* FPT — fronto-parieto-temporal area; PT — parieto-temporal area. * — cranioplasty with simultaneous removal of a foreign body; ** — bilateral cranioplasty.

skull models were created using CT-based (DICOM files) Fused deposition modeling (FDM) technology. Data post-processing was carried out using InVesallus, Slicer 3D, Poligon X software packages. We used dynamic titanium meshes 150 × 150 mm (DePuy Syntex MatrixNEURO, USA) and 100 × 100 mm (Codman & Shurtleff Inc., USA) to close skull defect. Implants were preoperatively formed considering the uniqueness of skull defect in each patient. Acute mesh corners were removed for adequate congruence with the bone surface. Thus, the implants were prepared before surgery. Then, these implants were sterilized.

We estimated the following parameters: implant deployment time, blood loss, patient's (parents') satisfaction with cosmetic outcome. The causes of skull defect and cranioplasty had some features. Therefore, we described them briefly.

## Results

There were 10 patients with various skull defects. In 7 out of 10 cases, the cause of skull defect was an injury. In 3 cases, defect occurred after decompressive cra-

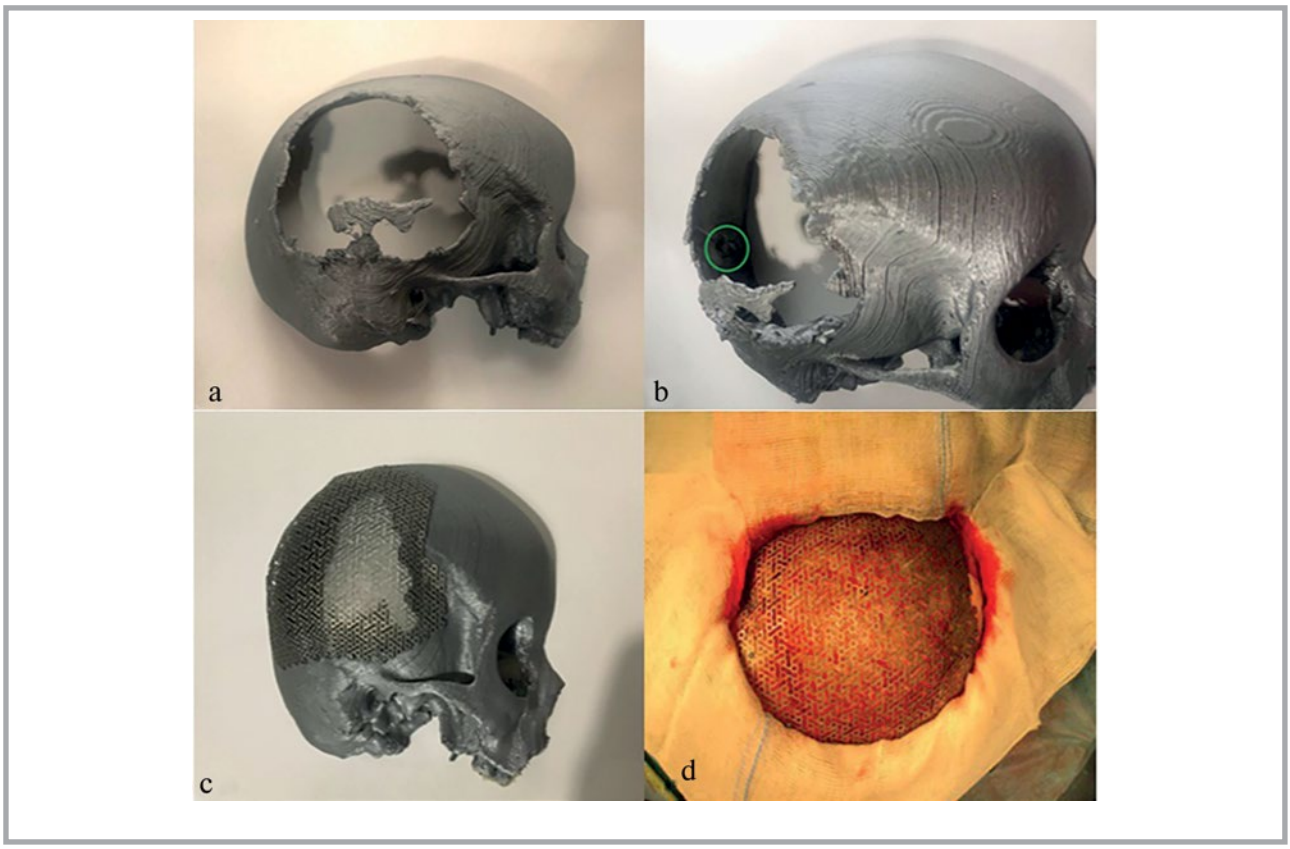


***Fig. 1.* Patient # 1.**

a — preoperative model of the patient's skull; b — foreign body (bullet) on the model of posterior surface of occipital bone; c — preoperative implant modeling; d — intraoperative position of implant.

niotomy for acute vascular disease. Characteristics of patient are shown in the **Table**.

In all cases, surgery time depended on the presence of additional surgical stage (removal of a bullet, patient #1) or several defects (patients # 3, 5). However, duration of intraoperative modeling and mesh installation was minimal and did not require additional procedures in all cases. Mean surgery time was 110.5 ± 52 min (min 70 min, max 225 min), mean blood loss — 56 ± 33.5 ml (min 30 ml, max 150 ml).

Skull modeling required 9 — 28 hours taking into account processing and direct printing of a model. Modeling of an individual implant took 45 min. Thus, model and implant have been prepared through no more than 2 days.

We will describe five the most typical cases to emphasize the features and advantages of this method.

**Patient # 1**

A 6-year-old girl T. was wounded by a lead bullet from an air gun. Emergency decompressive craniotomy in the right fronto-temporo-parietal region, debridement of subdural hematoma and cerebral detritus, dura mater repair with aponeurosis were performed. The patient was discharged in satisfactory condition for outpatient follow-up and subsequently appealed to the Almazov Research Center for further treatment. Bone defect 9 × 10 cm with soft tissue sinking and brain pulsation was observed in the fronto-temporo-parietal region **(Fig. 1, 2)**. The child had intermittent left-sided hemiparesis and behavioral disorders (attacks of aggression).

3D model of skull and dynamic titanium mesh were preoperatively created. The most optimal surgical approach was also planned for minimally traumatic extraction of a foreign body **(Fig. 1a—c).**

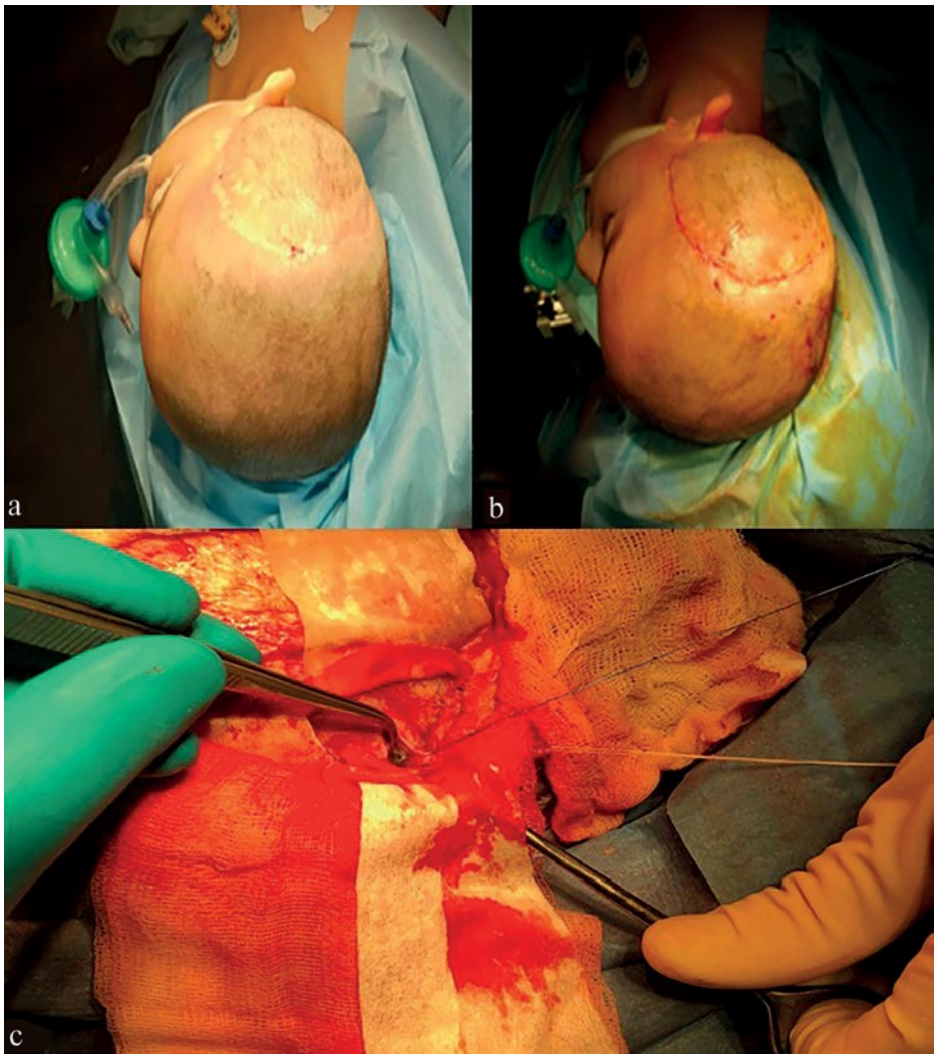


***Fig. 2.*** **Patient # 1.**
a — patient before surgery; b — patient after surgery; c — intraoperative image.

Removal of a foreign body with simultaneous skull repair was performed. Skull defect was enlarged towards occipital region using craniotome. Bullet position was identified using intraoperative ultrasound navigation. Localization of bullet was equal to its position on preoperative model **(Fig. 1b, 2c).** The bullet was mobilized and removed, dura mater was sutured tightly. The bone was fixed with a titanium plate. The defect was covered with a titanium mesh implant. Postoperative CT confirmed adequate position of the implant **(Fig. 1d, Fig. 2b).**

**Patient #2**

A 7-year-old boy R. received severe TBI after road traffic accident. CT revealed multiple hemorrhagic foci in the right hemisphere, subqdural hematoma in the left hemisphere, brain edema, multiple fractures of the cranial vault and skull base. Emergency debridement of a penetrating wound in the right parietal region, parietal bone resection, crush tissue debridement and dura mater repair were carried out. Clinical condition was stabilized. The child admitted to the Almazov Research Center. There was a skull defect 7 × 8 cm in the right parietal region with soft tissue sinking.

3D skull modeling and preoperative modeling of a dynamic titanium mesh preceded cranioplasty **(Fig. 3a, b).** Intraoperative correction of the implant was not required **(Fig. 3 c).**

**Patient # 3**

A girl M. aged 1 year and 4 months received TBI after traffic accident. She admitted in critical condition. CT revealed brain edema, contusion foci in the right temporal, parietal and occipital lobes, lateral brain dislocation, traumatic dehiscence of lambdoid suture on the left, left-sided occipital bone fracture, multiple comminuted fracture of the right parietal bone, fracture of petrous part of the temporal bone on the right. Right-sided decompressive craniotomy, debridement of brain detritus, bone fragments, revision of epi- and subdural space were performed. For the next stage of surgical treatment, the child admitted to the Almazov Research Center. There was a giant skull defect 9 × 8 cm with skin flap sinking. CT-based modeling of performed **(Fig. 4a, b).**

Cranioplasty of skull defect was performed. A premodeled titanium implant was installed. No additional mesh modeling was required. Titanium mesh was fixed with titanium screws. Dura mater was sutured in the central part of the mesh. Hemostasis and wound suturing in layer-by-layer fashion were performed **(Fig. 4c).**

**Patient # 4**

A 15-year-old boy Z. admitted with arteriovenous malformation of the right frontal lobe, subarachnoid hemorrhage, hematoma of the right frontal lobe. Emergency decompressive bilateral frontal craniectomy was performed at the place of residence. The patient was discharged in stable condition. Repeated hospitalization at the place of residence was required for cranioplasty with titanium mesh. However, suture failure and titanium implant infection occurred in postoperative period. Titanium plate was removed. Defect size was 12 × 12 cm. The patient admitted to the Almazov Research Center for cranioplasty **(Fig. 5a).**

Cranioplasty was carried out. Titanium plate was tightly deployed on the defect without additional correction **(Fig. 5b)** and fixed with screws **(Fig. 5c, d).**

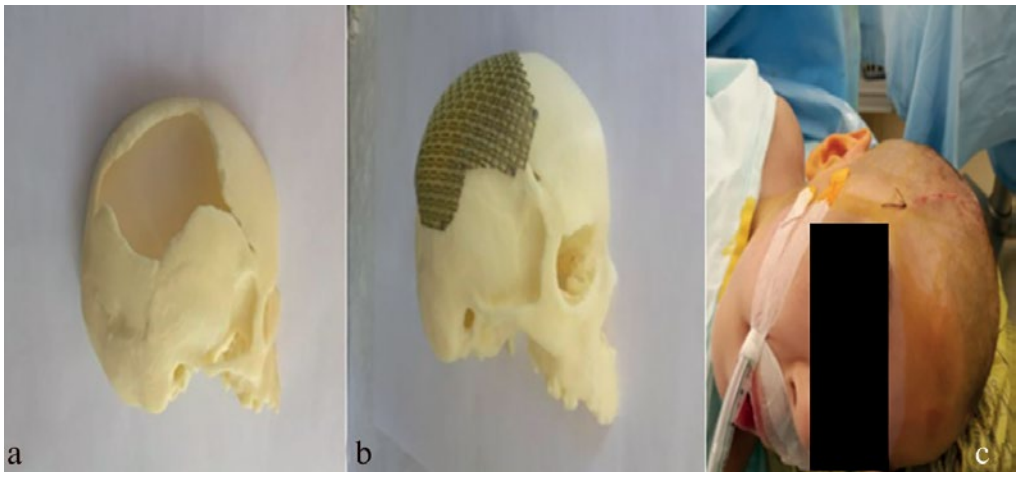


***Fig. 3.*** **Patient # 2.**
a — 3D model of the patient's skull; b — skull model with a titanium plate; c — postoperative result.

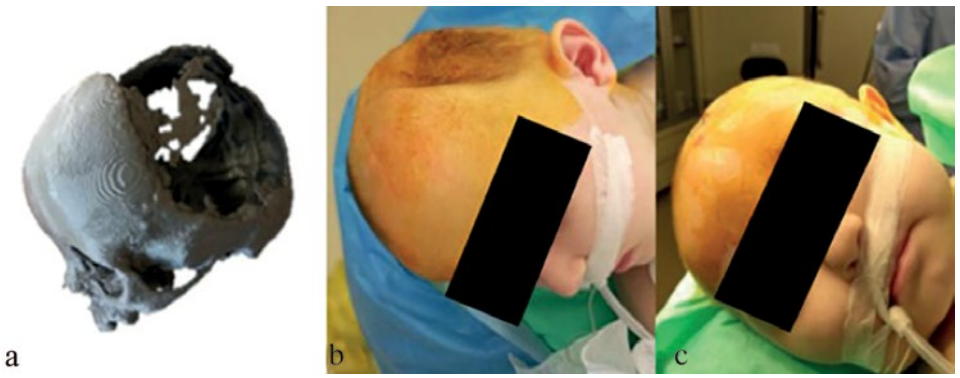


***Fig. 4.*** **Patient # 3.**
a — 3D model of the patient's skull; b — patient before surgery; c — postoperative result.

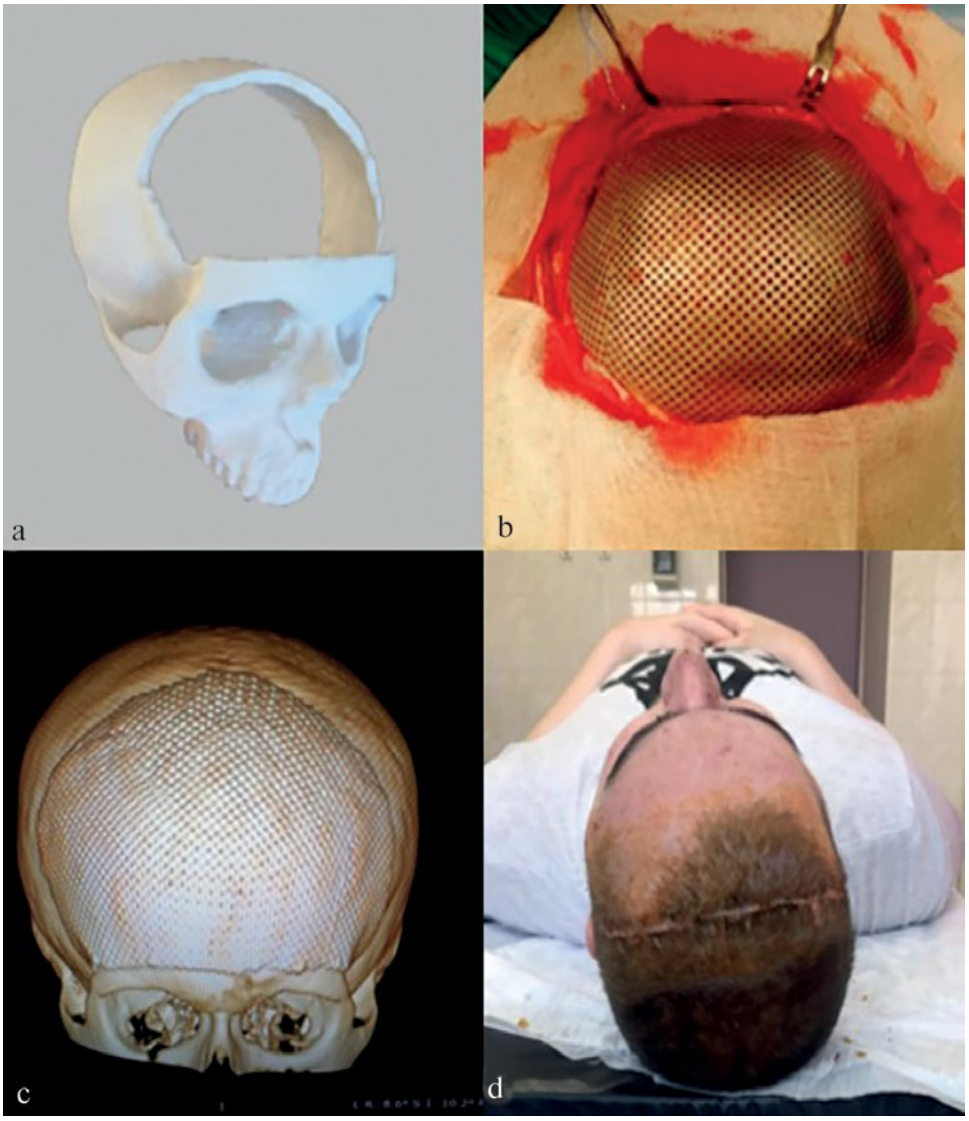


***Fig. 5.*** **Patient # 4.**
a — 3D model of the patient's skull; b — implant placement; c — control computed tomogram after surgery; d — patient after surgery.

**Patient # 5**

A 10-year-old boy A. was hospitalized to the children's hospital with parenchymal-ventricular hemorrhage followed by acute hematoma in the left frontal lobe. Emergency decompressive craniotomy with debridement of hematoma was performed. However, acute clinical deterioration required repeated debridement of hematoma in the left frontal lobe, craniotomy enlargement and clipping of left ICA aneurysm. External ventricular drainage and autologous cranioplasty were performed for persistent hypertensive-hydrocephalic syndrome. However, preoperative CT data of bone graft resorption were observed upon admission. The patient was hospitalized to the Almazov Research Center for cranioplasty.

There were 2 giant parietal bone defects (6 × 9 cm on the right and 8 × 9 on the left) **(Fig. 6a).** The patient underwent cranioplasty. Pre-modeled titanium implants were deployed into adequate position without additional correction **(Fig. 6b).** Frontal bone flaps were fixed to titanium mesh with bone sutures **(Fig. 6c).**

Thus, this approach ensured favorable postoperative outcome in 10 children with skull defects with reduced surgery time and blood loss. The patient's parents, staff and the patient himself assessed cosmetic result subjectively. In all cases, cosmetic result was satisfactory. None patient had postoperative infectious complications.

## Discussion

There is an opinion that 3D modeling in reconstructive neurosurgery ensures new possibilities for the treatment of patients with giant and complex skull defects. Preoperative manufacturing of implants is valuable to improve the congruence of defect and implant in the areas with complex anatomy that are difficult for intraoperative approach. The examples are defects extending to infratemporal fossa, orbit or zygomatic process of the temporal bone [18]. There are no time limitations during preoperative modeling of the graft, and surgeon can recreate the detailed anatomy of skull defect. At the same time, intraoperative modeling can significantly increase surgery time and blood loss, as well as the risk of postoperative complications [19]. In addition, surgeon can comprehensively study individual anatomy of the patient during preoperative modeling. This aspect also improves treatment quality.

Obviously, 3D modeling and preoperative preparation of titanium implants can shorten surgery time, reduce blood loss and risk of infectious complications. Cosmetic outcome is also improved since the surgeon is able to adapt the implant to individual characteristics of skull. Surgery time can vary significantly depending on the time after injury, need for additional surgical stages and characteristics of a particular hospital. In our study, mean surgery time was 110.5 ± 52 min (min 70 min, max 225 min). A retrospective study by Z.Y. Ng et al. [20] summarized 4-year experience of cranioplasty with titanium mesh in adults and showed that mean surgery time was 162 min.

According to some data, titanium mesh for cranioplasty is characterized by certain advantages including closure of large defects with various complex configurations, the lowest risk of infectious complications, high strength and plasticity, repair in any bone thickness. Moreover, I.T. Ma et al. [21] showed that titanium implants do not impair skull growth in children. Plastic properties of material made it possible to manufacture a prefabricated implant and re-sterilize it for surgery.

Thermoplastic properties of material are considered during Fused Deposition Modeling (FDM) since some types are characterized by shrinkage and deformation after cooling [22]. This can lead to configuration errors and the need for intraoperative correction. This complexity is overcome by material with the lowest shrinkage ratio, as well as special software modes to correct the errors during manufacturing.

Skills in automated manufacturing technology and some other specific engineering skills were previously required to create an accurate model. However, today the software interface is becoming more clear and simple for the user without a special education.




***Fig. 6.*** **Patient # 5.**
a — skull model before titanium mesh insertion; b — after titanium mesh insertion; c — implant insertion.

Today, 3D printing technologies have some speed limitations. Accelerated manufacturing the model deteriorates its quality and accuracy. Thus, this technology is limited in emergency surgery.

## Conclusions

1. Preoperative preparation of an implantable titanium plate using 3D printing can reduce surgery time and blood loss.

2. 3D printing for cranioplasty in children contributes to better cosmetic result due to precise preoperative preparation of the implant considering dimensions, location and shape of defect.

3. Preoperative modeling of the implant simplifies manipulations in complex anatomical areas.

**Authors' participation:**
Concept and design of the study — Ivanov V.P., Sulin K.A., Kim A.V., Khachatryan V.A.
Collection and analysis of data — Ivanov V.P., Sulin K.A.
Statistical analysis — Sulin K.A.
Writing the text — K.A. Sulin
Editing — Ivanov V.P., Kim A.V., Khachatryan V.A.

**No conflict of interests to declare.**

## REFERENCES

1. *Posttravmaticheskiye defekty cherepa. Klinicheskoye rukovodstvo po cherepno-mozgovoy travme.* M.: Antidor; 2002. (In Russ.).
2. Kaiser A, Illi OE, Sailer HF, Stauffer UG. Cranioplasties for Congenital and Acquired Skull Defects in Children — Comparison of New Concepts with Conventional Methods. *European Journal of Pediatric Surgery*. 1993;3(4):236-240. https://doi.org/10.1055/s-2008-1063551
3. Grant FC, Norcross NC. Repair of cranial defects by cranioplasty. *Annals of Surgery*. 1939;110(4):488-512. https://doi.org/10.1097/00000658-193910000-00002
4. Yamaura A, Makino H. Neurological deficits in the presence of the sinking skin flap following decompressive craniectomy. *Neurologia Medico-Chirurgica*. 1977;17(1 pt 1):43-53. https://doi.org/10.2176/nmc.17pt1.43
5. Annan M, De Toffol B, Hommet C, Mondon K. Sinking skin flap syndrome (or Syndrome of the trephined): A review. *British Journal of Neurosurgery*. 2015;29(3):314-318. https://doi.org/10.3109/02688697.2015.1012047
6. Halani SH, Chu JK, Malcolm JG, Rindler RS, Allen, JW, Grossberg JA, Ahmad FU. Effects of Cranioplasty on Cerebral Blood Flow Following Decompressive Craniectomy: A Systematic Review of the Literature. *Neurosurgery*. 2017;81(2):204-216. https://doi.org/10.1093/neuros/nyx054
7. Ashayeri K, M Jackson E, Huang J, Brem H, Gordon CR. Syndrome of the Trephined. *Neurosurgery*. 2016;79(4):525-534. https://doi.org/10.1227/neu.0000000000001366
8. *US Patent for Apparatus for production of three-dimensional objects by stereolithography* (Patent N 4,575,330 issued March 11, 1986). Accessed September 07, 2020. https://patents.justia.com/patent/4575330
9. Ivanov VP, Kim AV, Khachatryan WA. 3D printing in craniofacial surgery and neurosurgery. Experience of the Almazov National Research Center. *Nejrohirurgiya i nevrologiya detskogo vozrasta*. 2018;3(57):28-39. (In Russ.).
10. Klimek L, Klein HM, Schneider W, Mösges R, Schmelzer B, Voy ED. Stereolithographic modelling for reconstructive head surgery. *Acta Oto-Rhino-Laryngologica Belgica*. 1993;47(3):329-334.
11. Kravchuk AD, Potapov AA, Panchenko VY, Komlev VS, Novikov MM, Okhlopkov VA, Maryakhin AD, Duvidzon VG, Latyshev YA, Chelushkin DM, Chobulov SA, Aleksandrov AP, Shkarubo AN. Additive technologies in neurosurgery. *Voprosy neirokhirurgii imeni N.N. Burdenko.* 2018;82(6):97-104. (In Russ.). https://doi.org/10.17116/neiro20188206197
12. Miller JL, Ahn ES, Garcia JR, Miller GT, Satin AJ, Baschat AA. Ultrasound-based three-dimensional printed medical model for multispecialty team surgical rehearsal prior to fetoscopic myelomeningocele repair. *Ultrasound in Obstetrics and Gynecology*. 2018;51(6)836-837. https://doi.org/10.1002/uog.18891
13. Zheng JP, Li CZ, Chen GQ, Song GD, Zhang YZ. Three-Dimensional Printed Skull Base Simulation for Transnasal Endoscopic Surgical Training. *World Neurosurgery*. 2018;111:e773-e782. https://doi.org/10.1016/j.wneu.2017.12.169
14. Zhang F, Hong W, Guo Y, Guo Q, Hu X. Multimodal Neuronavigation in Microsurgery Resection of BrainStem Tumors. *Journal of Craniofacial Surgery*. 2016;27(8):769-772. https://doi.org/10.1097/SCS.0000000000003123
15. Chen J, Li N, He D, Wu M, Long H, Yang K, Qi S, Zhang W, Wang J. 3-D printing for constructing the burr hole ring of lead fixation device in deep brain stimulation. *Journal of Clinical Neuroscience*. 2018;58:229-233. https://doi.org/10.1016/j.jocn.2018.10.086
16. Borghi A, Rodgers W, Schievano S, Ponniah A, Jeelani O, Dunaway D. Proof of Concept Study for the Design, Manufacturing, and Testing of a Patient-Specific Shape Memory Device for Treatment of Unicoronal Craniosynostosis. *Journal of Craniofacial Surgery*. 2017;29(1):45-48. https://doi.org/10.1097/scs.0000000000004025
17. Eolchiyan SA. Complex skull defects reconstruction with CAD/CAM titanium and polyetheretherketone (PEEK) implants. *Voprosy nejrohirurgii im. N.N. Burdenko.* 2014;78(4):3-13. (In Russ.).
18. Raisian S, Fallahi HR, Khiabani KS, Heidarizadeh M, Azdoo S. Customized Titanium Mesh Based on the 3D Printed Model vs. Manual Intraoperative Bending of Titanium Mesh for Reconstructing of Orbital Bone Fracture: A Randomized Clinical Trial. *Reviews on Recent Clinical Trials*. 2017;12(3):154-158. https://doi.org/10.2174/1574887112666170821165206
19. Cho YJ, Kang SH. Review of Cranioplasty after Decompressive Craniectomy. *Korean Journal of Neurotrauma*. 2017;13(1):9-14. https://doi.org/10.13004/kjnt.2017.13.1.9
20. Ng ZY, Ang WJ, Nawaz I. Computer-designed polyetheretherketone implants versus titanium mesh (±acrylic cement) in alloplastic cranioplasty: a retrospective single-surgeon, single-center study. *Journal of Craniofacial Surgery*. 2014;25(2):185-189. https://doi.org/10.1097/SCS.0000000000000623
21. Ma IT, Symon MR, Bristol RE, Beals SP, Joganic EF, Adelson PD, Shafron DH, Singh DJ. Outcomes of Titanium Mesh Cranioplasty in Pediatric Patients. *Journal of Craniofacial Surgery*. 2017;29(1):99-104. https://doi.org/10.1097/scs.0000000000004045
22. Ligon SC, Liska R, Stampfl J, Gurr M, Mülhaupt R. Polymers for 3D Printing and Customized Additive Manufacturing. *Chemical Reviews*. 2017;117(15):10212-10290. https://doi.org/10.1021/acs.chemrev.7b00074

Received 23.03.2020
Accepted 28.08.2020