Burdenko's Journal of Neurosurgery
2020, №6, pp. 15-24
https://doi.org/10.17116/neiro20208406115

# Comparison of transpedicular endoscopic sequestrectomy and discectomy in the treatment of lumbar intervertebral disc herniation with a high degree of migration

© I.V. BASANKIN, V.A. PORKHANOV, A.A. GYULZATYAN, S.B. MALAKHOV, K.K. TAKHMAZYAN, M.I. TOMINA, E.G. SHEVCHENKO

Ochapovsky Regional Clinical Hospital, Krasnodar, Russia

**ABSTRACT**

Background. Surgical treatment of intervertebral disc herniation with a high degree of migration (beyond the vertebral pedicle) is a difficult problem without an unambiguous solution. In this manuscript, we compare the effectiveness of transpedicular endoscopy and standard discectomy in the treatment of patients with this disease.

**Objective.** To compare transpedicular endoscopic sequestrectomy and discectomy in the treatment of lumbar intervertebral disc herniation with a high degree of migration.

**Material and methods.** There were 28 patients divided into 2 groups: group 1 — 13 patients after transpedicular endoscopic sequestrectomy, group 2 — 15 patients after discectomy.

**Results.** Transpedicular endoscopic sequestrectomy ensured significantly better intraoperative parameters (incision length, blood loss, surgery time) ($p<0.01$). In both groups, postoperative VAS score of leg pain was significantly reduced within a day after surgery from 7.4±1.3 to 0.7±0.7 and from 7.1±1 to 0.8±0.5, respectively. In the 1st group, VAS score of back pain regressed from 5.2±0.7 to 1.1±0.89 by the end of the 1st postoperative day. This value was 0.6±0.5 a year later. In the 2nd group, VAS score of back pain regressed from 4.9±1 to 2.5±0.9 by the end of the 1st postoperative day. This value was 2.8±2.3 a year later. According to McNab clinical outcome scale, excellent and good results after transpedicular endoscopic sequestrectomy were obtained in all 13 (100%) patients, after discectomy — in 80% of cases.

**Conclusion.** Transpedicular endoscopic sequestrectomy is optimal for intervertebral disc herniation with a high degree of migration due to fast postoperative recovery and no complications.

***Keywords:*** *lumbar spine hernia, endoscopy, transpedicular approach.*

**INFORMATION ABOUT THE AUTHORS:**
Basankin I.V. — https://orcid.org/0000-0003-3549-0794; e-mail: basankin@rambler.ru
Porkhanov V.A. — https://orcid.org/0000-0003-0572-1395
Takhmazyan K.K. — https://orcid.org/0000-0003-4146-6790
Gyulzatyan A.A. — https://orcid.org/0000-0003-1260-4007
Malakhov S.B. — https://orcid.org/0000-0002-5315-1713
Tomina M.I. — https://orcid.org/0000-0001-9388-5220
Shevchenko E.G. — https://orcid.org/0000-0003-0437-9460

**Corresponding author:** Basankin I.V. — e-mail: basankin@rambler.ru

**TO CITE THIS ARTICLE:**
Basankin IV, Porkhanov VA, Gyulzatyan AA, Malakhov SB, Takhmazyan KK, Tomina MI, Shevchenko EG. Comparison of transpedicular endoscopic sequestrectomy and discectomy in the treatment of lumbar intervertebral disc herniation with a high degree of migration. *Burdenko's Journal of Neurosurgery = Zhurnal voprosy neirokhirurgii imeni N.N. Burdenko*. 2020;84(6):15–24. (In Russ.).
https://doi.org/10.17116/neiro20208406115

**Abbreviations**
VAS — visual analogue scale
ODI — Oswestry Disability Index

Degenerative-dystrophic spine diseases are pandemic in the XXI century [1]. Lumbosacral hernia occurs in 61% of patients with degenerative spine diseases [2, 3]. Employable people prevailed among the patients. Therefore, the choice of the most effective treatment of lumbosacral spine hernia is an actual problem [4].

Microdiscectomy, endoscopic microdiscectomy and percutaneous endoscopic hernia removal are currently applied [5].

In 1934, W.J. Mixter and J.S. Barr reported that rupture of annulus fibrosus of intervertebral disc and subsequent nucleus pulposus slippage into epidural space is a main cause of back and lower extremity pain. In addition, the authors first described laminectomy and discectomy for intervertebral hernia [6].

Standard discectomy procedure without any technical changes has been used for many years for root decompression. W. Caspar and M. Yasargil modified hemilaminectomy and discectomy into microdiscectomy along with development of microscopic techniques [7, 8].

Like many other surgical areas, neurosurgery has evolved towards minimizing of surgical approach for reduction of tissue trauma. Improvement of fiber-optic equipment resulted a new stage in spine surgery. It is endoscopic minimally invasive discectomy.

In 1988, R. Kambin et al. first presented intraoperative discoscopic view of herniated disc [9]. Later (in 1990), R. Kambin described a safe zone ("Kambin's triangle") for effective transforaminal discectomy [10]. The next stage was appearance of lenses with different viewing angles and surgical ports that improved endoscopic technique. As a result, T. Hoogland et al. [11] developed the Thomas Hoogland endoscopic spinal system (THESSYS) in 1994. In 1997, A.T. Yeung and P.M. Tsou created the YESS endoscopic system for the treatment of degenerative spine diseases (Yeung Endoscopic Spine System) [12]. K.T. Foley and M.M. Smith [13] first described microendoscopic discectomy using advanced optical techniques in 1997. Percutaneous endoscopic discectomy can be performed through transforaminal, interlaminar and transpedicular approaches [14-16]. In the last decade, percutaneous endoscopic discectomy became popular among surgeons, because this technique ensures precise discectomy under visual control and local anesthesia. Currently, numerous researches are devoted to comparison of microsurgical and percutaneous endoscopic treatment of patients with lumbar spine hernia. However, we found no studies comparing the effectiveness of microdiscectomy and transpedicular endoscopic removal of hernia with high degree of migration (beyond vertebral pedicle) [17, 18]. In this research, we evaluate the effectiveness of these techniques in patients with spine hernias and high degree of migration (follow-up 1 year).

The purpose of the study was to determine the optimal treatment of patients with lumbar spine hernia and high degree of migration (transpedicular endoscopic sequestrectomy vs. microdiscectomy).

***Table 1.*** **Preoperative characteristics of patients.**

| Variable | | Number of patients | |
|---|---|---|---|
| | | Group 1 | Group 2 |
| Hernia | $L_{II}$—$L_{III}$ | 2 | 4 |
| | $L_{III}$—$L_{IV}$ | 4 | 3 |
| | $L_{IV}$—$L_{V}$ | 7 | 8 |
| Hernia migration | caudal | 9 | 10 |
| | cranial | 4 | 5 |
| VAS score of leg pain, $M \pm m$ | | 7,4± 1,3 | 7,1± 1 |
| VAS score of back pain, $M \pm m$ | | 5,2± 0,7 | 4,9± 1 |
| Neurological deficit (paresis, hypesthesia) | yes | 10 | 9 |
| | no | 3 | 6 |

*Note.* VAS — visual analogue scale.

## Material and methods

There were 28 patients with lumbar spine hernia and high degree of migration for the period 2016–2019. All hernias were localized within the Macnab's hidden zone. The last one has clear anatomical landmarks: anterior wall — vertebra, lateral wall — vertebral pedicle, posterior wall — pars interarticularis, medial wall — dural sac. Patients were divided into 2 groups depending on surgical approach: group 1 ($n$=13) — transpedicular endoscopic sequestrectomy, group 2 ($n$=15) — microdiscectomy. There were 11 men and 17 women aged 27 — 72 years (mean 49.5 ± 6.4). Baseline characteristics of spine hernia and patients in both groups are shown in **Table 1**.

In both groups, patients were comparable by age, duration of disease, localization and dimensions of hernia, pain syndrome severity. Pain syndrome intensity was assessed using a 10-point visual analogue scale (VAS). We also used Oswestry Disability Index (ODI) before and after surgery to assess the quality of life in back and lower limb pain. Postoperative outcomes were assessed in both groups using a modified Macnab scale. The following grading system was used: excellent result (no pain and impaired mobility, patient is able to return to normal work and activity); good result (rare non-radicular pain, is able to return to modified work); satisfactory result (some functional improvement, disability); unsatisfactory result (ongoing radiculopathy, additional surgery at this level).

## Results

The main pre-, intra- and postoperative parameters were studied in both groups **(Table 2)**. Postoperative outcomes were assessed within the 1st postoperative day and in 1 year after surgery.

Preoperative leg and back pain and ODI score were similar in both groups.

Intraoperative characteristics (incision length, blood loss, surgery time) were significantly better ($p$ <0.01) for transpedicular endoscopic discectomy (group 1). Indeed, skin incision length was 4 times less, blood loss — 7 times less, surgery time — by 30% less in the 1st group **(Table 2)**. However, irradiation time was significantly higher in the 1st group (by 10 times) (20 ± 5.26 vs. 2 ± 1.13 min). It should be noted that blood loss and incision length are not significant for a patient despite between-group differences since they have no any clinical effect.

VAS score of lower limb pain was significantly decreased within the 1st postoperative day (from 7.4±1.3 to 0.7±0.7 in group 1 and from 7.1±1 to 0.8±0.5 in group 2). We also observed significant neurological improvement. Complete regression of preoperative neurological deficit occurred in 24 (78.9%) patients. Mild residual L3, L5 hypesthesia persisted in another 4 (21.1%) patients.

In the 1st group, VAS score of back pain was significantly reduced within the first postoperative day (from 5.2±0.7 to 1.1±0.89). One year later, this value was 0.6 ±

***Table 2.*** **Clinical characteristics of patients.**

| Variable | Group 1 | Group 2 | *p-value* |
|---|---|---|---|
| Preoperative and intraoperative data | | | |
| VAS score of leg pain, *M±m* | 7,4± 1,3 | 7,1± 1 | 0,5 |
| VAS score of back pain, *M±m* | 5,2± 0,7 | 4,9± 1 | 0,3 |
| ODI score | 62,7± 14,8 | 60± 13,1 | 0,25 |
| Incision length, cm | 0,6± 0,3 | 2,5± 1,1 | 0,01 |
| Blood loss, ml | 4,6± 2,33 | 32,7± 17,5 | 0,01 |
| Surgery time, min | 45,1±7,7 | 64± 18,9 | 0,01 |
| Irradiation time during intraoperative X-ray navigation, s | 20± 5,26 | 2± 1,13 | 0,005 |
| Early postoperative data | | | |
| VAS score of leg pain within the first postoperative day | 0,7± 0,7 | 0,8± 0,5 | 0,5 |
| VAS score of back pain within the first postoperative day | 1,1± 0,89 | 2,5± 0,9 | 0,5 |
| Hospital-stay, days | 1,5± 1 | 3,5± 1,5 | 0,3 |
| Long-term postoperative data (after 1 year) | | | |
| VAS score of leg pain | 0,4± 0,5 | 0,5± 0,5 | 0,5 |
| VAS score of back pain | 0,6± 0,5 | 2,8± 2,3 | 0,01 |
| ODI score | 15,8± 6 | 23± 12,7 | 0,05 |
| Complications | no | 1 | — |
| Redo surgeries | no | 2 (TLIF) | — |

*Note.* VAS — visual analogue scale; ODI — Oswestry disability index; TLIF — transforaminal lumbar interbody fusion.

0.5 scores. All patients returned to usual physical activity. Moreover, many of them resumed active sports in the near future after surgery.

In the 2nd group, microdiscectomy was also followed by relief of pain syndrome. However, regression was less significant compared to the 1st group. Baseline VAS score in this group was 4.9± 1. Within a day after surgery, this value decreased up to 2.5± 0.9 scores, after 1 year — 2.8± 2.3 scores. In our opinion, this is due to iatrogenic damage to posterior support complex associated with approach to the migrated hernia rather soft tissue trauma per se (skin incision length 2.5 cm vs. 0.6 cm). Most of patients in the 2nd group had more significant back pain compared to the 1st group despite overall satisfaction with leg pain relief. In 2 (13.3%) out of 15 patients in this group, back pain persisted in long-term period (within 6.5 months). A detailed examination revealed segmental instability at the intervention level. Therefore, redo fusion surgery was required. Segmental instability in these cases was caused by weakening of posterior column following excessive resection of vertebral arch and facet joint as the only possible way to approach the abnormal substrate.

ODI scores also significantly regressed in both groups after surgery that indicates an improved postoperative quality of life. This value decreased from 62.7± 14.8 to 15.8± 6 scores in the 1st group and from 60± 13.1 to 23± 12.7 scores in the second group. This parameter was better by 21% in the 1st group.

No damage to dura mater and nerve root was observed in both groups. In the 2nd group, one patient had postoperative superficial wound infection with effective conservative treatment. Other complications were absent.

Treatment outcomes were analyzed in both groups using a modified Macnab scale **(Table 3)**. Thus, excellent and good postoperative results after transpedicular endoscopic discectomy (group 1) were obtained in all 13 (100%) patients while microdiscectomy (group 2) ensured similar results in 80% of cases. Two (13.3%) patients in the 2nd group required redo surgery for spinal segment instability and severe vertebrogenic syndrome.

## Discussion

As a rule, hernias with a high degree of migration are localized within the pars interarticularis of the vertebra (medial to vertebral pedicle) [19]. I. Macnab first described this area in 1971 (“hidden zone” or “Macnab zone”) [20]. Optimal approach to this area is discussed in multiple researches [21—24]. According to various authors, standard Caspar microdiscectomy is traumatic in this case, since facet joint resection or hemilaminectomy is required for approach to “Macnab zone” [25, 26]. As a result, spinal segment instability can occur and require redo fusion surgery with possible adverse events typical for these procedure [23, 27, 28]. Moreover, A. Ivanov and A. Faizan reported a higher risk of stress-fractures in this area due to insufficient strength of bone tissue after lateral resection of pars interarticularis [29].

We report a 54-year-old patient S. with left-sided $L_{II}$ — $L_{III}$ sequestered disc herniation and caudal migration

***Table 3.*** **Postoperative outcomes in both groups according to modified Macnab scale.**

| Outcome | Group 1 | Group 2 |
|---|---|---|
| Excellent, *n* (%) | 12 (92,3) | 10 (66,7) |
| Good, *n* (%) | 1 (7,7) | 2 (13,3) |
| Satisfactory, *n* (%) | — | 1 (6,7) |
| Unsatisfactory, *n* (%) | — | 2 (13,3) |

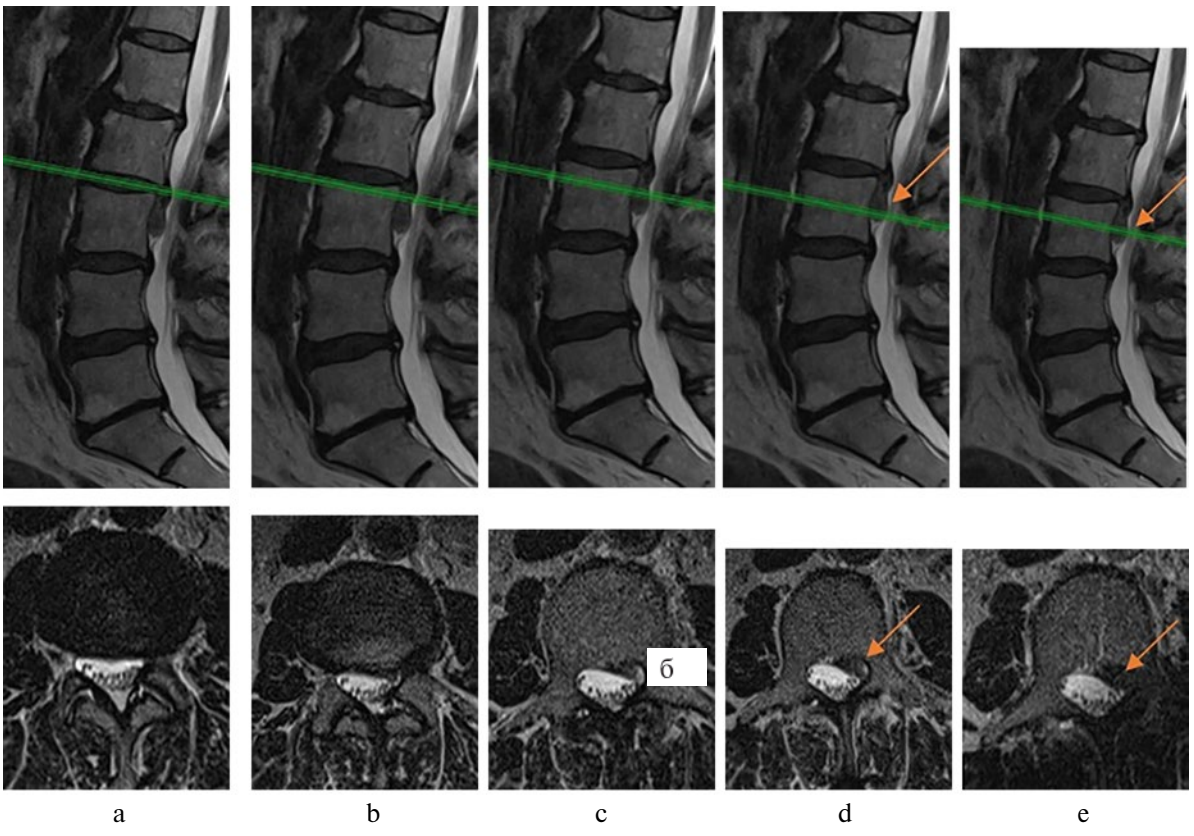


***Fig. 1.*** **MR scans (a-e) of patient S. with lumbar spine hernia and advanced caudal migration behind $L_{III}$ pedicle on the left (arrow).**

towards the "Macnab zone" **(Fig. 1)**. Hernia with a high degree of caudal migration (beyond the vertebral pedicle) is almost not visualized in axial scans up to the upper third of the $L_{III}$ vertebra **(Fig. 1a-c)**. Hernia is predominantly localized within the lateral recess of spinal canal immediately behind the pedicle **(Fig. 1d, e)**. Distal pole of hernia passes beyond ½ of vertebra height.

There were quadriceps muscle paresis up to 3 points, positive left-sided Lasegue symptom at the angle 40°, left-sided $L_{II}$ — $L_{III}$ hypesthesia with hyperpathy.

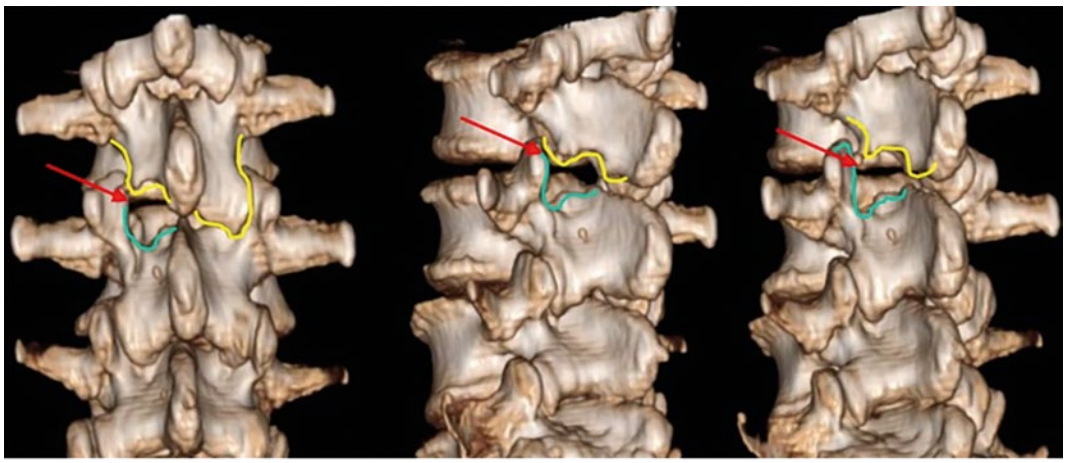


***Fig. 2.*** **Postoperative 3D CT scans (a-c) of patient S.**

$L_{II}$ arch and inferior articular process are shown by yellow line on the right, on the left — resected part of the arch and articular process, green line shows the resected part of $L_{III}$ superior articular process and part of the arch. Red arrow indicates the formed «hole» for approach to sequestration.

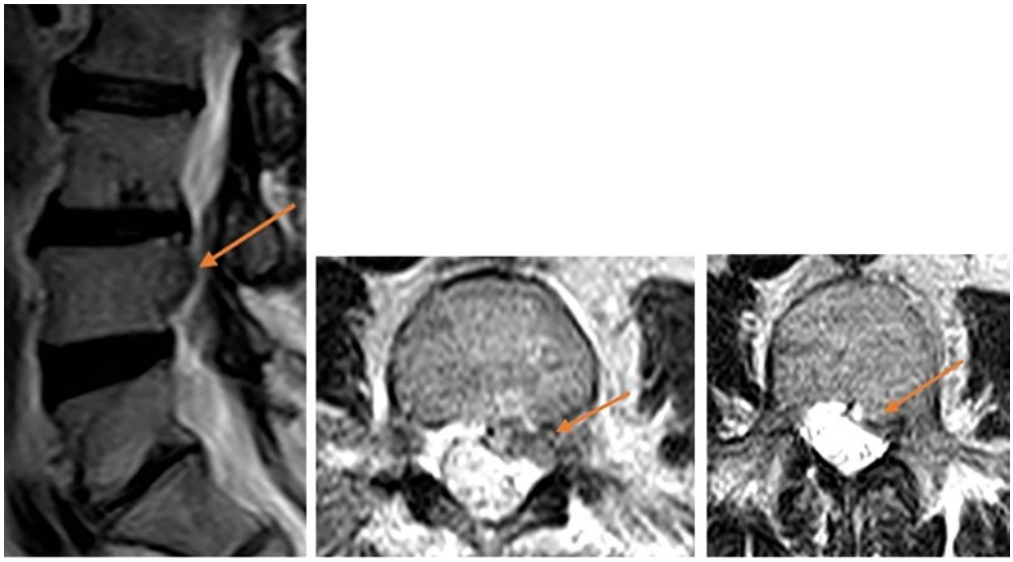

a b c

***Fig. 3.*** **MR scans (a-c) of patient D. with a left-sided hernia (arrow) and advanced caudal migration at the level of $L_{III}$ — $L_{IV}$.**

The patient underwent $L_{II}$ — $L_{III}$ sequestrectomy via standard microsurgical approach. There were certain intraoperative difficulties associated with advanced caudal migration of sequestrum and limited interlaminar approach to the hernia at $L_{II}$ — $L_{III}$ level, bleeding from varicose epidural veins. An approach required resection of the lower part of $L_{II}$ arch and superior articular process of $L_{III}$. As a result, the sequestration was available and removed. Surgery time was 130 min, blood loss — 90 ml.

In postoperative period, complete regression of radicular pain syndrome was observed, within 6 months — complete regression of baseline neurological deficit. Moderate vertebral syndrome (VAS score 4) occurred immediately after surgery. Subsequently, this syndrome aggravated up to 7 scores. Segmental instability following excessive resection of posterior column structures caused progressive vertebrogenic pain syndrome. Considering ineffective conservative treatment, transforaminal $L_{II}$ — $L_{III}$ fusion surgery was performed. Painful vertebral syndrome complete regressed after surgery.

Segmental instability and vertebral pain were caused by damage to $L_{II}$ medial facet during sequestrectomy **(Fig. 2)**.

In 2016, G. Krzok et al. [16] first described transpedicular approach to "Macnab zone". They confirmed an effectiveness and safety of this technique in a retrospective analysis of treatment outcomes in 9 patients. Later, $L_{III}$ — $L_{IV}$ and $L_{IV}$ — $L_{V}$ hernias were described by P. Uniyal et al. [30] and J. Quillo-Olvera et al. [31]. Their data confirmed the findings of G. Krzok et al. about the effectiveness of transpedicular technique.

In 2020, I.V. Basankin et al. retrospectively analyzed the treatment outcomes in patients with lumbar spine hernia and high degree of migration. The authors comprehensively described endoscopic discectomy and favorable postoperative outcomes [32].

Our comparative analysis showed that transpedicular endoscopic removal of hernia in Macnab zone is optimal approach and may be effectively used in routine clinical practice.

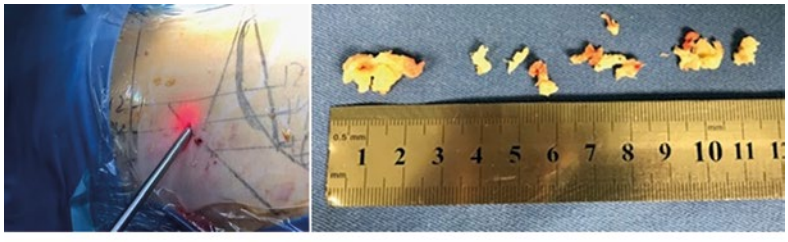


a b

***Fig. 4.*** **Patient D.**

a — approach to intervertebral hernia $L_{III}$ — $L_{IV}$ and view of endoscopic equipment; b — fragments of removed sequestration.

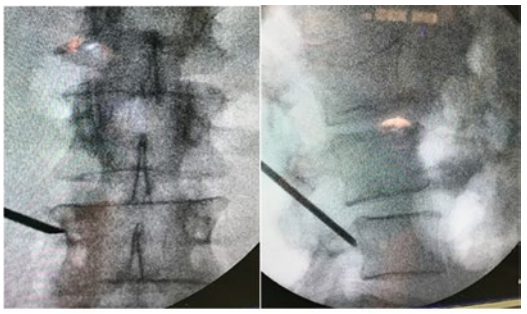

a b

*Fig. 5.* **Intraoperative X-ray scan of lumbar spine of patient D. in frontal (a) and lateral (b) planes. Jamshidi needle is visualized on the lateral surface of the vertebral pedicle.**

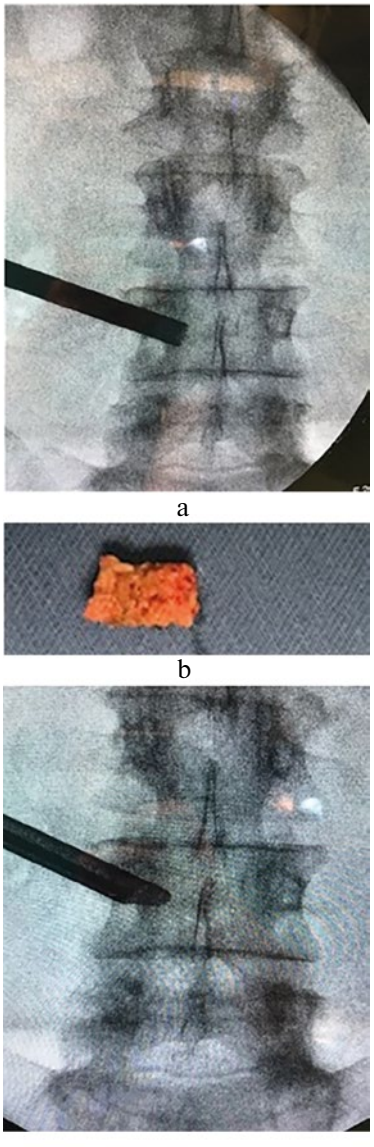

a

b

c

***Fig. 6.*** **Intraoperative X-ray scan of lumbar spine of patient D.**

a — rimmer in the vertebral pedicle; b — bone fragment 5 cm3 after "excision" of $L_{IV}$ pedicle; c — endoscopic port in $L_{IV}$ pedicle.

We report a 55-year-old patient D. with left-sided $L_{III}$ — $L_{IV}$ disc herniation, caudal migration towards the "hidden zone" and severe radicular pain syndrome (VAS score 7) **(Fig. 3)**. Neurological status included compression-ischemic $L_{IV}$ radiculopathy, paresis of extensor muscles of the left foot up to 4 scores, dorsal numbness of the left foot.

Complex conservative therapy for 4 weeks resulted only mild regression of pain syndrome (from 7 to 5—6 scores). Considering clinical and instrumental data, minimally invasive transpedicular endoscopic hernia removal was applied **(Fig. 4)**.

Under X-ray control in frontal and lateral projections, 11G Jamshidi needle 15.2 cm was injected through the muscles at an angle of 20° and placed on the lateral surface of $L_{IV}$ pedicle between the vertebral body and transverse process **(Fig. 5)**.

After that, the needle was advanced through the vertebral pedicle using light hammer blows until the inner cortical plate was perforated. Then, the mandrin was removed and a guidewire was inserted into the needle. The needle was removed. Next, an 8-mm skin incision was made, and appropriate color dilators were applied for approach to the lateral surface of the vertebral pedicle. After that, we used a standard 8-mm rimmer **(Fig. 6a)** for cutting out the bone fragment of the vertebral pedicle using the installed dilators **(Fig. 6b)**. The guide dilators were removed, and the hole was widened and deepened with a high-speed drill. A 7.2-mm endoscopic port was installed **(Fig. 6c)**. "Joimax GmbH" endoscope (Germany) 3.8 mm was passed through the port and hernia was visualized.

Surgery time was 40 min, blood loss — 5 ml. Complete regression of leg and back pain was observed in early postoperative period. Computed tomography in 1 week after surgery revealed the canal in the vertebral pedicle **(Fig. 7)**.

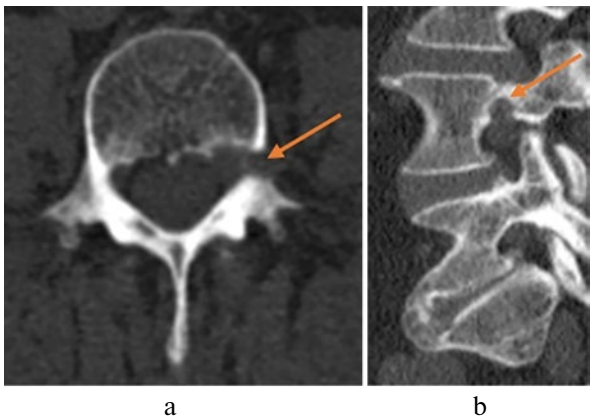

a b

***Fig. 7.*** **CT scans (a, b) of the lumbar spine of patient D.**

The canal inside the vertebral pedicle is visualized, sequestration was removed through this canal (arrow).

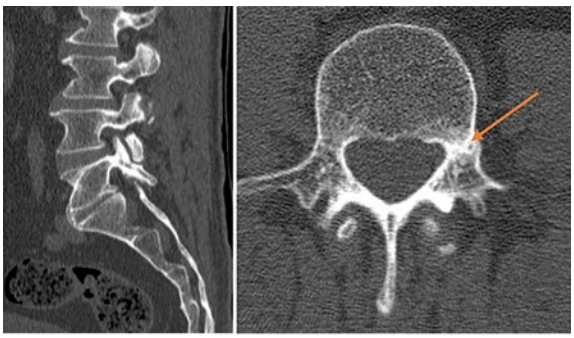

a b

***Fig. 8.*** **MR scans of the lumbar spine of patient D. in 3 months after transpedicular endoscopic sequestrectomy (a, b).**
No hernia at the level of $L_{IV}$ pedicle.



a b

***Fig. 9.*** **CT scans of the lumbar spine of patient D. in sagittal (a) and axial (b) planes in 3 years after surgery.**
Left-sided vertebral pedicle defect closure (arrow).

Three months later, MRI revealed no hernia at the level of pedicle and total decompression of the roots and dural sac **(Fig. 8)**. The patient feels well 3 years after surgery. CT confirmed bone defect occlusion in the vertebral pedicle **(Fig. 9)**.

These cases demonstrate the effectiveness and potential of transpedicular endoscopic method for spine hernia with advanced migration. Dimensions of vertebral pedicle should be considered in this surgery since the diameter of endoscopic tubular retractor is 7.5 mm. F. Torun et al. reported the greatest pedicle height at $L_V$ level (17.1 ± 4.2 mm), the narrowest one — at $L_I$ level (8.4 ± 1.8 mm) [33]. Thus, transpedicular endoscopy has limitations for $L_I$ and $L_{II}$ levels since the pedicles of these vertebrae are characterized by minimal height. Therefore, there is a high risk of intra- and postoperative vertebral pedicle fracture.

## Conclusion

Transpedicular endoscopic sequestrectomy is optimal method for spine hernia with advanced migration (beyond the vertebral pedicle). This method is effective, minimally traumatic and reproducible, ensures fast postoperative recovery. This technique may be recommended for various specialists considering rare complications in case of impeccable surgical technique and adequate selection of patients.

**Authors' participation:**
Concept and design of the study — Basankin I.V., Porkhanov V.A.
Collection and analysis of data — Gyulzatyan A.A., Malakhov S.B., Takhmazyan K.K., Tomina M.I., Shevchenko E.G.
Statistical analysis — Tomina M.I.
Text writing — Basankin I.V., Gyulzatyan A.A.
Editing — V.A.Porkhanov

**No conflict of interests to declare.**

## REFERENCES

1. Kirienko AN, Sorokovikov VA, Pozdeeva NA. Degenerative-dystrophic disorders of the cervical spine. *Sibirskij medicinskij zhurnal*. 2015;7:21-25. (In Russ.).
2. Schroeder GD, Guyre CA, Vaccaro AR. The epidemiology and pathophysiology of lumbar disc herniations. *Seminars in Spine Surgery*. 2016;28(1):2-7. https://doi.org/10.1053/j.semss.2015.08.003
3. Cummins J, Lurie JD, Tosteson TD, Hanscom B, Abdu WA, Birkmeyer NJO, Herkowitz H, Weinstain J. Descriptive Epidemiology and Prior Healthcare Utilization of Patients in the Spine Patient Outcomes Research Trial's (SPORT) Three Observational Cohorts. *Spine*. 2006;31(7):806-814. https://doi.org/10.1097/01.brs.0000207473.09030.0d
4. Konovalov NA, Nazarenko AG, Asyutin DS, Zelenkov PV, Onoprienko RA, Korolishin VA, Cherkiev IU, Martynova MA, Zakirov BA, Timonin SYu, Kosyrkova AV, Pimenova AF, Pogosyan AA, Batyrov AA. Modern treatments for degenerative disc diseases of the lumbosacral spine. A literature reviews. *Voprosy nejrokhirurgii im. N.N. Burdenko*. 2016;4:102-108. (In Russ.). https://doi.org/10.17116/neiro2016804102-108
5. Arestov SO, Vershinin AV, Gushcha AO. Comparative analysis of the effectiveness and potential of endoscopic and microsurgical resection of disc herniations in the lumbosacral spine. *Voprosy nejrokhirurgii im. N.N. Burdenko*. 2014;78(6):9-14. (In Russ.). https://doi.org/10.17116/neiro20147869-14
6. Mixter WJ, Barr JS. Rupture of the intervertebral disc with involvement of the spinal canal. *The New England Journal of Medicine*. 1934;211:210-215. https://doi.org/10.1056/nejm193408022110506
7. Caspar W. A new surgical procedure for lumbar disc herniation causing less tissue damage through a microsurgical approach. In: Wüllenweber R, Brock M, Hamer J, et al, eds. *Advances in Neurosurgery 4. Lumbar Disc. Adult Hydrocephalus*. Berlin: Springer; 1977. https://doi.org/10.1007/978-3-642-66578-3_15
8. Yasargil M. Microsurgical operation of herniated lumbar disc. In: Wüllenweber R, Brock M, Hamer J, et al, eds. *Advances in Neurosurgery 4. Lumbar Disc. Adult Hydrocephalus*. Berlin: Springer; 1977. https://doi.org/10.1007/978-3-642-66578-3_16

9. Kambin P, Nixon JE, Chait A, Schaffer JL. Annular protrusion: pathophysiology and roentgenographic appearance. *Spine*. 1988;13(6):671-675. https://doi.org/10.1097/00007632-198813060-00013
10. Kambin P. Arthroscopic microdiskectomy. *The Mount Sinai Journal of Medicine*. 1991;58(2):159-164. https://doi.org/10.1016/s1529-9430(02)00558-2
11. Hoogland T, van den Brekel-Dijkstra K, Schubert M, Miklitz B. Endoscopic transforaminal discectomy for recurrent lumbar disc herniation: a prospective, cohort evaluation of 262 consecutive cases. *Spine*. 2008;33(9):973-978. https://doi.org/10.1097/brs.0b013e31816c8ade
12. Yeung AT, Tsou PM. Posterolateral endoscopic excision for lumbar disc herniation: surgical technique, outcome, and complications in 307 consecutive cases. *Spine*. 2002;27(7):722-731. https://doi.org/10.1097/00007632-200204010-00009
13. Foley KT, Smith MM. Micro endoscopic discectomy. *Techniques in Neurosurgery*. 1997;3:301-307. https://doi.org/10.1097/00006123-199809000-00303
14. Schubert M, Hoogland T. Endoscopic transforaminal nucleotomy with foraminoplasty for lumbar disk herniation. *Operative Orthopadie und Traumatologie*. 2005;17(6):641-661. https://doi.org/10.1007/s00064-005-1156-9
15. Ruetten S, Komp M, Merk H, Godolias G. Surgical treatment for lumbar lateral recess stenosis with the full endoscopic interlaminar approach versus conventional microsurgical technique: a prospective, randomized, controlled study. *Journal of Neurosurgery. Spine*. 2009;10(5):476-485. https://doi.org/10.3171/2008.7.17634
16. Krzok G, Telfeian AE, Wagner R, Iprenburg M. Transpedicular lumbar endoscopic surgery for highly migrated disk extrusions: preliminary series and surgical technique. *World Neurosurgery*. 2016;95:299-303. https://doi.org/10.1016/j.wneu.2016.08.018
17. Righesso O, Falavigna A, Avanzi O. Comparison of open discectomy with micro endoscopic discectomy in lumbar disc herniations: results of a randomized controlled trial. *Neurosurgery*. 2007;61(3):545-549. https://doi.org/10.1227/01.neu.0000290901.00320.f5
18. Garg B, Nagraja UB, Jayaswal A. Microendoscopic versus open discectomy for lumbar disc herniation: a prospective randomised study. *Journal of Orthopaedic Surgery*. 2011;19(1):30-34. https://doi.org/10.1177/230949901101900107
19. McCulloch JA, Young PH. *Essentials of Spinal Microsurgery*. Lippincott-Raven; 1998;329-382. https://doi.org/10.2106/00004623 199907000-00023
20. Macnab I. Negative disc exploration. An analysis of the causes of nerve-root involvement in sixty-eight patients. *The Journal of Bone and Joint Surgery. American Volume*. 1971;53(5):891-903. https://doi.org/10.2106/00004623-197153050-00004
21. Bernucci C, Giovanelli M. Translaminar microsurgical approach for lumbar herniated nucleus pulposus (HNP) in the «hidden zone»: clinical and radiologic results in a series of 24 patients. *Spine*. 2007;32(2):281-284. https://doi.org/10.1097/01.brs.0000249527.17105.aa
22. Di Lorenzo N, Porta F, Onnis G, Cannas A, Arbau G, Maleci A. Pars interarticularis fenestration in the treatment of foraminal lumbar disc herniation: a further surgical approach. *Neurosurgery*. 1998;42(1):87-89. https://doi.org/10.1097/00006123-199801000-00018
23. Kunogi J, Hasue M. Diagnosis and operative treatment of intraforaminal and extraforaminal nerve root compression. *Spine*. 1991;16(11):1312-1320. https://doi.org/10.1097/00007632-199111000-00012
24. Papavero L, Langer N, Fritzsche E, Emami M, Kothe R. Westphal M. The translaminar approach to lumbar disc herniations impinging the exiting root. *Neurosurgery*. 2008;62(3 suppl 1):173-177. https://doi.org/10.1227/01.neu.0000317389.83808.16
25. Epstein NE. Foraminal and far lateral lumbar disc herniations: surgical alternatives and outcome measures. *Spinal Cord*. 2002;40(10):491-500. https://doi.org/10.1038/sj.sc.3101319
26. Siebner HR, Faulhauer K. Frequency and specific surgical management of far lateral lumbar disc herniations. *Acta Neurochirurgica*. 1990;105(3-4):124-131. https://doi.org/10.1007/bf01669995
27. Abumi K, Panjabi MM, Kramer KM, Duranceu J, Oxland T, Cristo JJ. Biomechanical evaluation of lumbar spinal stability after graded facetectomies. *Spine*. 1990;15:1142-1147. https://doi.org/10.1097/00007632-199011010-00011
28. Afaunov AA, Basankin IV, Kuzmenko AV, Shapovalov VK. Complications of surgical treatment of degenerative lumbar stenosis. *Hirurgiâ Pozvonočnika*. 2016;13(4):66-72. (In Russ.). https://doi.org/10.14531/ss2016.4.66-72
29. Ivanov AL, Faizan A. Minimally invasive decompression for lumbar spinal canal stenosis in younger age patients could lead to higher stresses in the remaining neural arch a finite element investigation. *Minimally Invasive Neurosurgery*. 2007;50(1):18-22. https://doi.org/10.1055/s-2006-947996
30. Uniyal P, Choi G, Khedkkar B. Percutaneous trans-pedicular lumbar endoscopy: a case report. *International Journal of Spine Surgery*. 2016;10:31. https://doi.org/10.14444/3031
31. Quillo-Olvera J, Akbary K, Kim JS, Percutaneous endoscopic transpedicular approach for high-grade down-migrated lumbar disc herniations. *Acta Neurochirurgica*. 2018;160(8):1603-1607. https://doi.org/10.1007/s00701-018-3586-9
32. Basankin IV, Porkhanov VA, Takhmazyan KK, Giulzatyan AA, Malakhov SB, Kalugin LYu, Tomina MI, Shapovalov VK. Transpedicular endoscopic removal of highly migrated disc herniations of lumbar spine. *Neirokhirurgiya*. 2020;22(3):42-50. https://doi.org/10.17650/1683-3295-2020-22-3-42-50
33. Torun F, Tuna H, Buyukmumcu M, Caglar S, Baysefer A. The lumbar roots and pedicles: a morphometric analysis and anatomical features. *Journal of Clinical Neuroscience*. 2008;15(8):895-899. https://doi.org/10.1016/j.jocn.2007.08.006


Received 04.03.2020
Accepted 28.08.2020

## Commentary

Endoscopy-assisted surgical treatment of patients with degenerative spine diseases dates back to 1988 and is associated with researches by P. Kambin. For more than 20 years, endoscopic discectomy has been widely used in the Russian Federation along with microendoscopic and microsurgical techniques. According to classification by G. Choi et al. (Lee S, Kim SK, Lee SH, Kim WJ, Choi WC, Choi G, Shin SW. Percutaneous endoscopic lumbar discectomy for migrated disc herniation: classification of disc migration and surgical approaches. European Spine Journal. 2007; 16 (3): 431-437), spinal canal is divided into 4 zones in sagittal plane. These areas are conditionally limited by intervertebral disc and vertebral pedicle. Anatomical Macnab zone is localized within G. Choi zone 4-1. Sequestered fragments with this localization are found in 20-30% of cases in cranial migration and extremely difficult for surgical approach. Conventional posterior approach implies hemilaminectomy. Transforaminal endoscopy ensures visualizing and eliminating craniolateral hernia within the intervertebral foramen and correction of median protrusion. However, this approach may be insufficient for subligamental sequestration

above and below the vertebral pedicle. In this case, additional manipulations or conversion to interlaminar approach may be required. As a result, surgeons often abandon totally endoscopic technique in favor of microsurgical approach. In this article, the authors propose transpedicular approach to visualize hernia with advanced migration. This method is relatively new and first discussed by G. Choi (2005) when the author described partial pediculotomy. In modern manuscripts, the authors propose complete passage of instruments through the vertebral pedicle that makes this approach less traumatic (R. Wagner et al., 2016). In this manuscript, the authors compare transpedicular endoscopic and microsurgical posterior approaches. An obvious advantage of transpedicular approach is reduced risk of traction and injury of the nerve root during discectomy through posterior approach. In addition, vertebral pedicle recovery lasts for a few weeks in normal bone tissue repair that was confirmed in previous studies. The authors prove the advantages of transpedicular approach regarding postoperative pain syndrome. It is unlikely that quality of life could change depending on approach. Nevertheless, it would be interesting in the future to assess the long-term results of "extremely lateral" approach to far-migrated herniated disc regarding postoperative spine instability and deformities. Undoubtedly, this report is valuable for physicians involved in surgical treatment of patients with degenerative spine diseases. Transpedicular endoscopy in practice of vertebrologists will be useful to avoid various complications and increase surgical efficiency. The manuscript is written in a simple, understandable fashion and demonstrates the authors' main idea. The authors' own results are compared with literature data, there are multiple foreign and own references devoted to this issue. The abstract completely reflects the essence of research. All data are comprehensively described; statistical analysis is adequate.

*N.A. Konovalov, D.S. Asyutin (Moscow, Russia)*