Burdenko's Journal of Neurosurgery
2020, №6, pp. 5-14
https://doi.org/10.17116/neiro2020840615

Visual fluorescence combined with laser spectroscopy in surgery for intramedullary spinal cord tumors

© N.A. KONOVALOV, S.Yu. TIMONIN, P.V. ZELENKOV, S.A. GORYAINOV, D.S. ASYUTIN, B.A. ZAKIROV, S.V. KAPROVOY

Burdenko Neurosurgical Center, Moscow, Russia

ABSTRACT

Surgical treatment of intramedullary spinal cord tumors is aimed at total resection of tumor with maximum preservation of neurological and functional status. In some cases, intramedullary tumors have unclear dissection plane or gliosis zone. This area is not a tumor and does not require resection. However, it is difficult to distinguish visually intact spinal cord tissue and tumor at the last surgical stages. Thus, we evaluated the effectiveness of fluorescence combined with laser spectroscopy in surgical treatment of intramedullary spinal cord tumors.

Objective. To determine the effectiveness of visual fluorescence combined with laser spectroscopy in surgery for intramedullary spinal cord tumors.

Material and methods. There were 850 patients with intramedullary spinal cord tumors for the period 2001—2019. In 35 cases, intraoperative fluoroscopy with laser spectroscopy were used. All patients underwent a comprehensive pre- and postoperative clinical and instrumental examination (general and neurological status, McCormick grade, spinal cord MRI). Carl Zeiss OPMI Pentero microscope with a fluorescent module was used for intraoperative fluorescence diagnosis. A domestic preparation 5-ALA «ALASENS» (State Research Center NIOPIK, Moscow, Russia) was used for induction of visible fluorescence. Laser spectroscopy was carried out using a LESA-01-BIOSPEK spectrum analyzer. Morphological analysis of intramedullary spinal cord tumors was performed in the neuromorphology laboratory of the Burdenko Neurosurgery Center.

Results. Intramedullary anaplastic ependymoma and astrocytoma, as well as conventional ependymoma were characterized by the highest index of 5-ALA accumulation. Intramedullary hemangioblastoma and cavernoma do not accumulate 5-aminolevulinic acid due to morphological structure of these tumors. In particular, there are no cells capable of capturing and processing 5-ALA in these tumors. Sensitivity of visual fluorescence combined with laser spectroscopy varies from 0% to 100% depending on the histological type of tumor: hemangiogblastoma and cavernoma — 0%, low-grade astrocytoma — 70%, high-grade astrocytoma — 80%, ependymoma — 92%, anaplastic ependymoma 100%. Dissection plane is absent in anaplastic ependymoma, high-grade astrocytoma. We often observed gliosis during resection of ependymoma. This tissue is not a part of tumor. Intraoperative metabolic navigation with neurophysiological monitoring are advisable for total tumor resection in case of unclear dissection plane and peritumoral gliosis.

Conclusion. Visual fluorescence combined with laser spectroscopy is a perspective method for intraoperative imaging of tumor remnants and total resection of intramedullary spinal cord tumors with minimum risk of neurological impairment.

Keywords: *spinal cord tumors, fluorescence, laser spectroscopy, intramedullary spinal cord tumors, proliferation index.*

INFORMATION ABOUT THE AUTHORS:
Konovalov N.A. — https://orcid.org/0000-0002-9976-948X
Timonin S.Yu. — https://orcid.org/0000-0003-3982-4560; e-mail: md.timonin@gmail.com
Zelenkov P.V. — https://orcid.org/0000-0002-3897-7787
Asyutin D.S. — https://orcid.org/0000-0002-0015-1488
Goryainov S.A. — https://orcid.org/0000-0002-6480-3270
Zakirov B.A. — https://orcid.org/0000-0002-8782-850X
Kaprovoy S.V. — https://orcid.org/0000-0001-8813-2793

Corresponding author: Timonin S.Yu. — e-mail: md.timonin@gmail.com

TO CITE THIS ARTICLE:
Konovalov NA, Timonin SYu, Zelenkov PV, Goryainov SA, Asyutin DS, Zakirov BA, Kaprovoy SV. Visual fluorescence combined with laser spectroscopy in surgery for intramedullary spinal cord tumors. *Burdenko's Journal of Neurosurgery = Zhurnal voprosy neirokhirurgii imeni N.N. Burdenko*. 2020;84(6):5—14. (In Russ.). https://doi.org/10.17116/neiro2020840615

Abbreviations
5-ALA — 5-aminolevulinic acid
MRI — magnetic resonance imaging

Primary spinal cord tumors make up 4.3% among all primary and glial tumors of the central nervous system. Ependymoma is the most common neoplasm, while astrocytoma occupies the second place. Both these neoplasms account about 80% of intramedullary tumors [1, 2].

Important objectives of routine neurosurgery are maximum quality of tumor resection and minimal postoperative neurological de-ficit. Total resection of tumor is often

complicated by unclear dissection plane between the intact spinal cord tissue and the tumor [3]. In addition, decrease in evoked electrophysiolo-gical potentials can force the surgeon to reject total resection [3, 4]. In this regard, intraope-rative visualization of tumor remnants is required because these fragments are difficult to be distinguished for light operating microscope [5—7]. Visual fluorescence is based on fluorescent contrast enhancement of tumor with a photosensitizer (protoporphyrin IX). The last one is selectively accumulated in the tumor after injection of 5-aminolevulinic acid (5-ALA). In turn, laser fluorescence spectroscopy is based on ultrafast detection of reflected laser and laser-induced fluorescent eradiation from tumor surface [8].

Visual fluorescence combined with laser spectroscopy and electrophysiological monitoring ensure more complete resection of intramedullary tumors with on-line control of other spinal cord structures [9, 10].

Currently, 5-ALA is one of the most common photosensitizers. It is a white crystalline powder intended for preparation of aqueous solution for oral and intracavitary administration [11]. 5-ALA is a natural source for synthesis of protoporphyrin IX. The last one is a light-absorbing mitochondrial chromophore and precursor of heme. This method is based on selective conversion of 5-ALA to protoporphyrin IX in tumor cells under conditions of excessive 5-ALA concentration. Intact brain cell metabolizes insignificant amount of 5-ALA or does not metabolize at all [12].

Protoporphyrin IX accumulation occurs within a few hours. In tumor cells, high concentration of protoporphyrin IX persists for 1—2 days. At the same time, this agent is rapidly utilized in normal cells via conversion to fluorescence-inactive heme. This results a high fluorescent contrast enhancement of tumor and surrounding tissue that is important factor for identifying and clarifying the boundaries of tumor.

The permeability of intact blood-brain barrier for 5-ALA is very low, and the main transport mechanism is passive diffusion [3].

Tumor growth followed by local blood-brain barrier lesion results a penetration of 5-ALA into tumor cells and perifocal brain area. However, intensive synthesis of protoporphyrin IX is observed only in tumor cells. This feature favorably distinguishes 5-ALA from other photosensitizers whose effect was based on blood-brain barrier damage [10].

Specially designed attachments for operating microscopes ensure intraoperative visualization of red-pink luminescence of protoporphyrin IX. This effect is valuable to determine tumor boundaries. Fluorescence intensity depends on cellular accumulation of protoporphyrin IX and eradiation energy [12].

Intraoperative fluorescence of tumor ensures identification of its true edge during resection of glial tumors that improves quality of resection [3, 12].

Intraoperative laser spectroscopy on a spectrum analyzer is used for quantitative assessment. Fluorescence index and fluorescence contrast are used for quantitative description of protoporphyrin IX accumulation.

Fluorescence index is a ratio of fluorescence intensity in 690—730 nm range to scattered laser signal intensity. Fluorescence contrast is a ratio of fluorescence index of the examined tissue to fluorescence index of the intact spinal cord.

Visual assessment of fluorescence and spectroscopy are performed on intact spinal cord, after myelotomy throughout the entire visible surface of tumor, at the stages of resection, after resection and hemostasis.

The purpose of the study was to determine the effectiveness of visual fluorescence navigation combined with laser spectroscopy in surgical treatment of various spinal cord tumors.

Material and methods

There were more than 850 patients with various intramedullary spinal cord tumors at the Burdenko Neurosurgery Center for the period from 2001 to 2019. Intraoperative fluoroscopy with laser spectroscopy was applied in 35 patients for the period from 2018 to 2020.

Inclusion criteria:
- age 16—75 years;
- primary intramedullary spinal cord tumors confirmed by MRI data;
- Karnofsky index ⩾ 70;
- no severe liver and kidney diseases;
- informed consent.

Exclusion criteria:
- porphyria;
- increased serum creatinine (over 100 μmol/l in women and 110 μmol/l in men) and urea (over 6.4 μmol/l), increased levels of alanine aminotransferase, aspartate aminotransferase, gamma-glutamyl transpeptidase by 2 times or more;
- previous liver disease (hepatitis, cirrhosis);
- previous nephrectomy;
- pregnancy and lactation;
- refusal to take part in research at any stage.

All patients underwent the following examinations:

1. Comprehensive pre- and postoperative clinical and instrumental survey with assessment of general and neurological status, McCormick score, spinal cord MRI. T1 MRI data with contrast enhancement were used for further analysis.

2. Intraoperative fluorescence diagnosis (OPMI Pentero 900 microscope (Carl Zeiss, Germany) with a fluorescent module). Russian remedy of 5-ALK (Alasens, State Research Center NIOPIK, Russia) was used for induction of visible fluorescence.

3. Laser spectroscopy (LESA-01-BIOSPEK spectrum analyzer, "Biospek" CJSC, Russia).

4. Morphological analysis of intramedullary spinal cord tumors at the neuromorphology laboratory of the Burdenko Neurosurgery Center.

Drug administration protocol

Alasens (20 mg/kg) in 50—100 ml of still drinking water was orally administered 3 hours before induction of anesthesia.

Fluorescence survey and laser spectroscopy protocol

The most favorable conditions for intraoperative examination are thorough hemostasis, as well as the absence of blood or cerebrospinal fluid on the examined tissue.

At the first stage, we have visually assessed tumor fluorescence using fluorescent mode of operating microscope. Surgeon performed this procedure using the terms "no fluorescence", "mild fluorescence", "bright fluorescence".

At the second stage, laser spectroscopy was performed using a spectrum analyzer. Surgeon brings a sterile optical fiber to the areas of interest, and spectra were saved in a computer program upon the surgeon's command for further analysis. Fluorescence intensity was estimated in relative units for subsequent analysis of contrast ratio (ratio of tumor fluorescence to the baseline fluorescence of the intact spinal cord).

There are several points for examining the fluorescence:

- intact tissues — skin, muscles;
- spinal cord outside the tumor;
- tumors at different stages of resection;
- walls of post-resection cavity.

Mean value of skin spectroscopy was 1–3 units, muscle tissues — 3–4 units. Spectroscopy of intact spinal cord tissue did not exceed 5 units. For intramedullary neoplasms, this value was typically over 5 units regardless the morphological type. We did not reveal a clear upper limit for abnormal tissue due to different spectroscopy values. Mean values for intramedullary neoplasms ranged from 7 to 28 units. However, anaplastic ependymomas were characterized by 50–60 units.

Statistical analysis was carried out using the Microsoft Excel and Statistica 8.0 software packages (StatSoft Inc., USA).

The study was carried out in accordance with the Declaration of Helsinki of the World Medical Association "Ethical Principles for Human Medical Research". All participants signed an informed consent for personal data processing.

Results

Descriptive statistics included 35 patients with intramedullary tumors who underwent treatment with intraoperative fluorescence and laser spectroscopy.

Incidence of various histological types of intramedullary spinal cord tumors was similar in men and women **(Fig. 1)**.

Quality of resection depending on Ki-67 proliferation index is shown in **Fig. 2**.

Thus, total resection was performed in 80% of patients with low (< 5%) Ki-67 index, 5–10% — in 40% of cases, only subtotal resection was possible in patients with Ki-67 index ⩾ 10%. Ki-67 index was not assessed in patients with hemangioblastoma and cavernoma.

Patients with intramedullary anaplastic ependymoma and conventional ependymoma had the highest fluorescence index (mean value varied from 20 to 30 units, max 60 units).

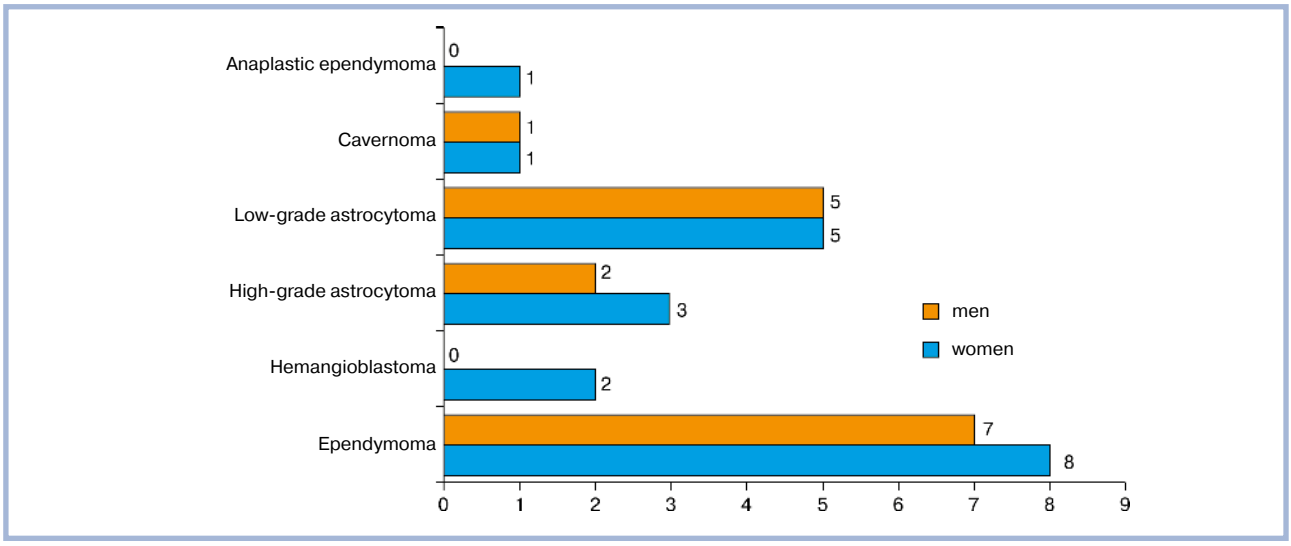

Fig. 1. **Number of men and women with various histological types of tumors.**

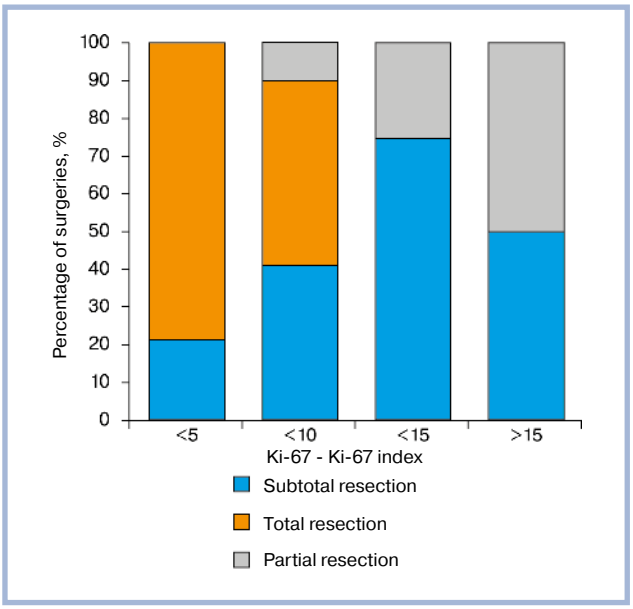

Fig. 2. **Quality of tumor resection depending on Ki-67 index.**

The fluorescence index depended on the histological type of tumor **(Fig. 3)**.

Intramedullary hemangioblastoma and cavernoma do not accumulate 5-ALA.

Sensitivity of visual fluorescence combined with laser spectroscopy depending on the histological type of tumor is shown in the **Table**.

We should note such intraoperative feature as surgical dissection plane between the intact spinal cord and the tumor tissue. Such a plane is common for spinal cord ependymoma. At the same time, astrocytomas (with the exception of piloid ones) do not usually have a clear dissection plane. Vascular spinal cord tumors (hemangioblastoma and cavernoma) demonstrate a clear dissection plane from intact spinal cord tissue almost in 100% of cases.

In case of unclear dissection plane and infiltrative tumor growth, intraoperative metabolic navigation combined with neurophysiological monitoring is the most advisable approach to ensure the maximum quality of resection and minimum risk of postoperative neurological impairment.

Gliosis and residual tumor tissue may be similar under the light of operating microscope even in visual fluorescence. In this situation, we used laser spectroscopy for quantitative assessment of metabolite accumulation. This approach was valuable for surgeon to make a decision on the need for further resection or completion of surgery **(Fig. 4)**.

According to our data, hemangioblastoma and cavernoma are characterized by clear dissection plane. At the same time, dissection plane is absent in anaplastic ependymoma and high-grade astrocytoma.

Visual fluorescence of the tumor (BLUE 400 mode, OPMI Pentero 900 intraoperative microscope, Carl Zeiss, Germany) is shown in **Fig. 5**.

Software interface for laser spectroscopy data recording is presented in **Fig. 6**. 5-ALA accumulation index scale is on the left. The measured spectra from different tumor loci (designated as "Tumor 1, 2, 3 ... 13") are on the right. Spectra of the intact spinal cord (designated as "Spinal cord mediana") are also measured.

According to contrast-enhanced MRI in early postoperative period, intraoperative fluorescence and laser spectroscopy ensured total resection of intramedullary neoplasms in 85% of cases (30 out of 35). In 15% of cases, we preferred subtotal resection of intramedullary tumor due to diffuse growth of the neoplasm and high risk of persistent neurological deficit.

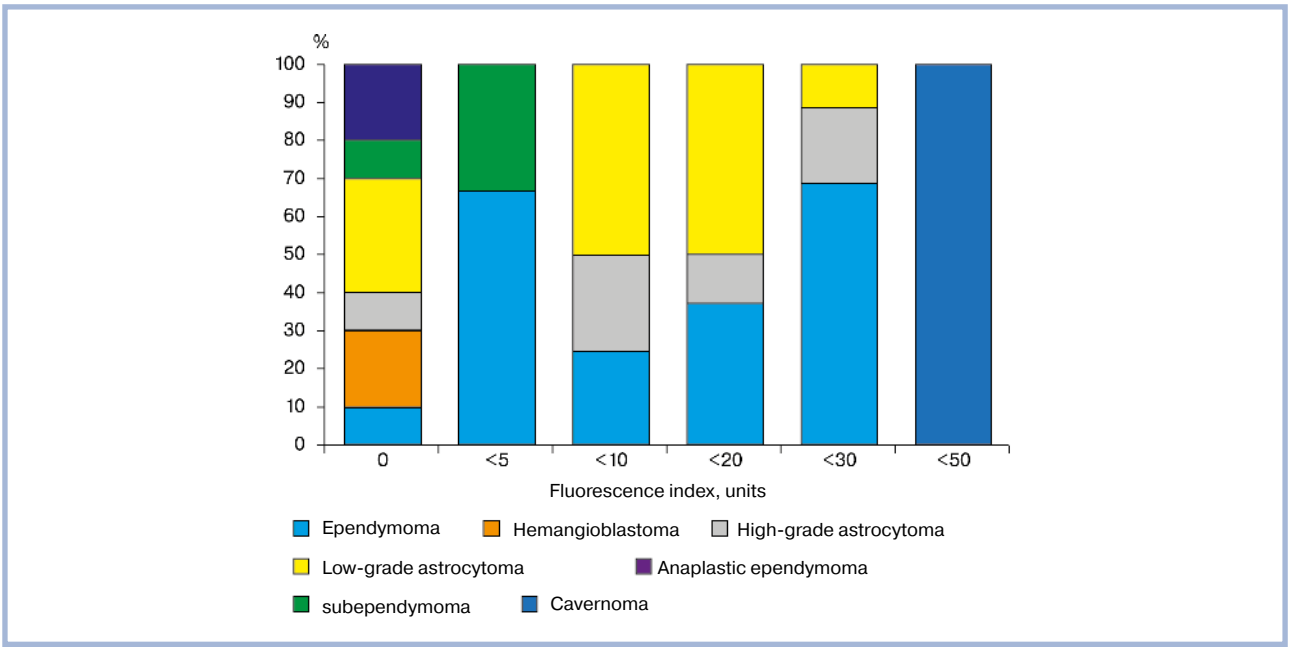

Fig. 3. **Fluorescence index depending on the histological type of tumor.**

Sensitivity of visual fluorescence combined with laser spectroscopy depending on the histological type of tumor.

Histological type of tumor	Number of patients	Sensitivity, %
Ependymoma	15	92
Hemangioblastoma	2	0
High-grade astrocytoma	5	80
Low-grade astrocytoma	10	70
Cavernoma	2	0
Anaplastic ependymoma	1	100

Discussion

The use of 5-ALA has become a new stage in the development of metabolic navigation. The first reports on the use of 5-ALA for photodynamic diagnosis of erythroleukemia cells date back to 1979 [6, 7, 13].

In the late 90s of the last century, various authors reported the use of 5-ALA in neurosurgery. W. Stummer et al. [14] studied 5-ALA in a model of malignant C6 glioma in rats. They showed that 5-ALA is able to penetrate the blood-brain barrier in sufficient quantities for synthesis of protoporphyrin in malignant tumors. At the same time, there is no significantly increased concentration of protoporphyrin in intact tissues.

This research contributed to new studies on the use of 5-ALA in neurosurgery [14—17].

Aminolevulinic acid has low toxicity. No mortality or internal organ dysfunction were obtained in experimental and clinical studies. The drug is usually administered orally at a dose of 20 mg/kg in 50 ml of drinking water 2-3 hours before surgery [18]. Peak serum concentration is achieved 4 hours later [19]. Maximum fluorescence is observed in 6 hours after 5-ALA administration. W. Stummer et al. [20, 21] showed that the fluorescence effect does not decrease 12—16 hours later. Short-term photosensitization (solar erythema) occurs in some cases, transient increase of liver enzyme concentration is rare. Aminolevulinic acid is completely excreted in urine within 24 hours after oral administration and not accumulated in body tissues [14].

Aminolevulinic acid is not compatible with potential phototoxic substances, in particular, tetracycline, sulfonamides, and contraindicated in patients with porphyria and pregnant women. Methotrexate can neutralize the effect of 5-ALA in vitro [22]. Side effects of 5-ALA can include nausea, vomiting, mild hypotension, and elevated liver enzymes [19].

D.W. Roberts et al. [23] do not recommend to take the drug in patients with more than 2.5 times elevated liver enzymes.

Fluorescence navigation significantly improved postoperative outcomes in patients with glioblastoma. Tumor

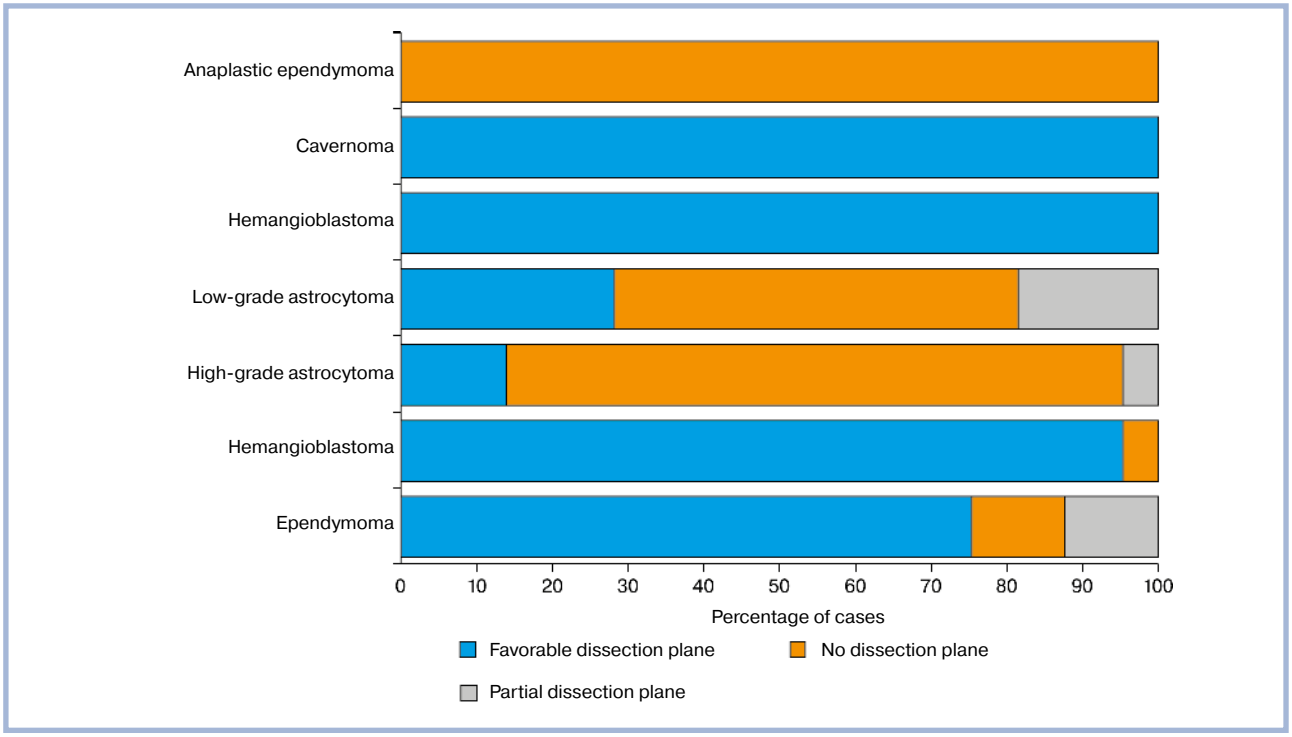

Fig. 4. **Quality of tumor dissection plane depending on the histological type of tumor.**

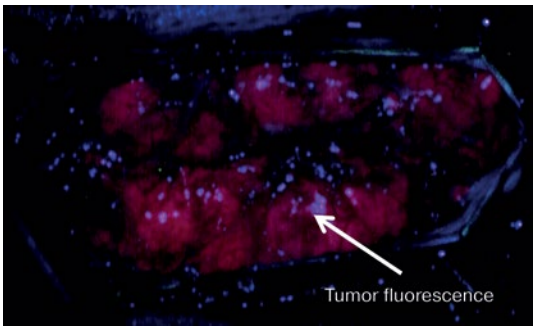

Fig. 5. **Visual fluorescence of tumor in BLUE 400 mode (OPMI Pentero 900 microscope, Carl Zeiss, Germany).**

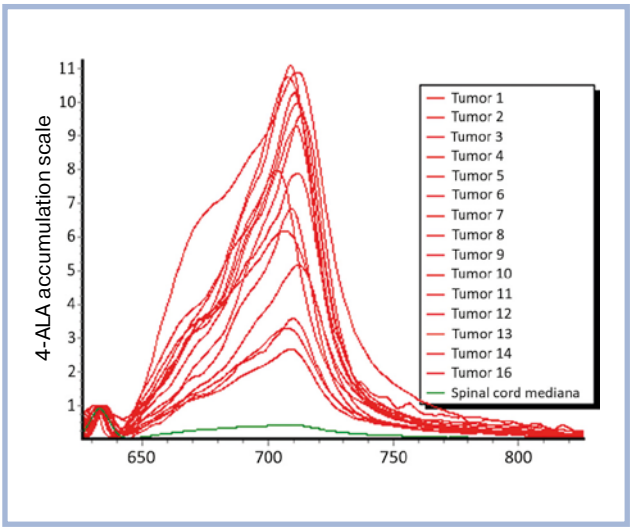

Fig. 6. **Software interface for laser spectroscopy data recording (explanations in the text).**

fluorescence makes it possible to define clearly the tumor growth border and perform adequate resection [24].

Thus, the incidence of the use of fluorescence diagnosis and photodynamic therapy in complex treatment of malignant glial tumors has recently shown a positive trend. Various authors believe that these techniques should be used for malignant gliomas to improve the quality of resection, postoperative outcomes and life expectancy [8, 11, 18, 25, 26].

We have found several foreign manuscripts devoted to application of this technique in surgery of spinal cord tumors (primarily intramedullary ones). These are 2 case reports, 3 patients with intramedullary tumors are described in another article. All patients underwent tumor resection under visual fluorescence control [3, 27, 28].

Significant accumulation of photosensitizer inside the tumors, in particular, in ependymoma and glioblastoma, is described in these articles. Surgical treatment of a patient with malignant astrocytoma grade III was reported in 2010. This patient underwent total resection of intramedullary tumor, and intraoperative navigation made it possible to minimize the resection area [12].

In 2012, T. Inoue et al. [29] reported surgical treatment of 9 patients with intramedullary ependymoma using 5-ALA fluorescence navigation. Tumor fluorescence was obtained in 7 cases (ependymoma Grade II and III). In 2 cases, there was no fluorescence (ependymoma Grade II).

We found a clear correlation between the morphological type of tumor, intensity and nature of intraoperative fluorescence.

Intramedullary hemangioblastoma and cavernoma do not accumulate 5-ALA. This is primarily due to morphological features of tumor stroma (no cells capable for 5-ALA capturing and processing).

5-ALA fluorescence is a safe and useful intraoperative tool for detecting tumor tissue and resection margins in patients with intramedullary or extramedullary spinal cord tumors with infiltrative growth (glioma, ependymoma, infiltrative meningioma).

Nevertheless, the advantage of this technique should still be confirmed by prospective large-scale studies of patients with intramedullary tumors, clinical data, postoperative examination and neuroimaging, as well as long-term outcomes [28, 30].

Conclusion

Visual fluorescence combined with laser spectroscopy is a perspective method of intraoperative imaging of tumor remnants for adequate resection of intramedullary spinal cord tumors with minimum postoperative neurological deficit.

Authors' participation:
Concept and design of the study — Konovalov N.A., Timonin S.Yu., Zelenkov P.V., Goryainov S.A., Asyutin D.S.
Collection and analysis of data — Asyutin D.S., Zakirov B.A., Kaprovoy S.V., Zelenkov P.V., Timonin S.Yu.
Statistical data analysis — Asyutin D.S., Zakirov B.A., Kaprovoy S.V., Zelenkov P.V., Timonin S.Yu.
Writing the text — Timonin S.Yu.
Editing — Konovalov N.A., Goryainov S.A., Asyutin D.S.

No conflict of interests to declare.

REFERENCES

1. Samartzis D, Gillis CC, Shih P, O'Toole JE, Fessler RG. Intramedullary spinal cord tumors: part I — epidemiology, pathophysiology, and diagnosis. *Global Spine Journal*. 2015;5(5):425-435. https://doi.org/10.1055/s-0035-1549029
2. Maklygina YuS, Ryabova AV, Loshenov VB, Sokolov EN,Nevzorov DI, Grigorieva NYu, Dolgushin BI. Use of Vavilov—Cherenkov radiation for destruction of rat glioma C6 cells under combined exposure to 18F-FDG and 5-ALA induced protoporphyrin IX (pilot experimental study).*Vestnik RONC im. N.N. Blohina RAMN*. 2016;4:160-166. (In Russ.).
3. Hebeda KM, Saarnak AE, Olivo M, Sterenborg HJ, Wolbers JG. 5-Aminolevulinic acid induced endogenous porphyrin fluorescence in 9L and C6 brain tumors and in the normal rat brain. *Acta Neurochirurgica*. 1998;140(5):503-513. https://doi.org/10.1007/s007010050132
4. Hamilton KR, Lee SS, Urquhart JC, Jonker BP. A systematic review of outcome in intramedullary ependymoma and astrocytoma. *Journal of Clinical Neuroscience*. 2019;63:168-175. ttps://doi.org/10.1016/j.jocn.2019.02.001
5. Goryajnov SA, Potapov AA, Pickhelauri DI, Kobyakov GL, Ohlopkov VA, Gavrilov AG, Shurhaj VA, Zhukov VYu, Shishkina LV, Loshchenov VB, Savel'eva TA, Kuz'min SG, Chumakova AP, Spallone A. Intraoperative fluorescence diagnostics upon recurrent operations for brain gliomas. *Voprosy nejrohirurgii im. N.N. Burdenko.* 2014;78(2):22-31.
6. Kucia EJ, Bambakidis NC, Chang SW, Spetzler RF. Surgical technique and outcomes in the treatment of spinal cord ependymomas, part 1: intramedullary ependymomas. *Operative Neurosurgery.* 2011;68(suppl 1):57-63. https://doi.org/10.1227/NEU.0b013e318208f181
7. McGirt MJ, Goldstein IM, Chaichana KL, Tobias ME, Kothbauer KF, Jallo GI. Extent of surgical resection of malignant astrocytomas of the spinal cord: outcome analysis of 35 patients. *Neurosurgery*. 2008;63(1):55-61. https://doi.org/10.1227/01.NEU.0000335070.37943.09
8. Loschenov VB, Konov VI, Prokhorov AM. Photodynamic therapy and fluorescence diagnostics. *Laser Physics*. 2000;10(6)1188-1207.
9. Arai T, Tani S, Isoshima A, Nagashima H, Joki T, Takahashi-Fujigasaki J, Abe T. Intraoperative photodynamic diagnosis for spinal ependymoma using 5-aminolevulinic acid: technical note. *Neurological Surgery*. 2006;34(8):811-817.
10. Acerbi F, Cavallo C, Schebesch KM, Akçakaya MO, de Laurentis C, Hamamcioglu MK, Broggi M, Brawanski A, Falco J, Cordella R, Ferroli P, Kiris T, Höhne J. Fluorescein-guided resection of intramedullary spinal cord tumors: results from a preliminary, multicentric, retrospective study. *World Neurosurgery*. 2017;108:603-609. https://doi.org/10.1016/j.wneu.2017.09.061
11. Ennis SR, Novotny A, Xiang J, Shakui P, Masada T, Stummer W, Keep RF. Transport of 5-aminolevulinic acid between blood and brain. *Brain Research*. 2003;959(2):226-234. https://doi.org/10.1016/s0006-8993 (02) 03749-6
12. Nägele M, Hofstetter D, Faist J, Sigrist MW. Low power quantum-cascade laser photoacoustic spectrometer for trace-gas monitoring. *Analytical Sciences.* 2001;17:497-499. https://doi.org/10.14891/analscisp.17icpp.0.s497.0
13. Malik Z, Djaldetti M. 5-aminolevulinic acid stimulation of porphyrin and hemoglobin synthesis by uninduced friend erythroleukemic cells. *Cell Differentiation*. 1979;8(3):223-233. https://doi.org/10.1016/0045-6039 (79) 90049-6
14. Stummer W, Novotny A, Stepp H, Goetz C, Bise K, Reulen HJ. Fluorescence-guided resection of glioblastoma multiforme utilizing 5-ALA-induced porphyrins: a prospective study in 52 consecutive patients. *Journal of Neurosurgery*. 2000;93(6):1003-1013. https://doi.org/10.3171/jns.2000.93.6.1003
15. Novotny A, Xiang J, Stummer W, Teuscher NS, Smith DE, Keep RF. Mechanisms of 5-aminolevulinic acid uptake at the choroid plexus. *Journal of Neurochemistry*. 2000;75(1):321-328. https://doi.org/10.1046/j.1471-4159.2000.0750321.x
16. Ostrom QT, Gittleman H, Liao P, Rouse C, Chen Y, Dowling J, Wolinsky Y, Kruchko C, Barnholtz-Sloan J. CBTRUS statistical report: primary brain and central nervous system tumors diagnosed in the United States in 2007—2011. *Neuro-Oncology.* 2014;16(4):1-63. https://doi.org/10.1093/neuonc/nou223
17. Singh K, Kouli O, Kanodia A, Goodman C, Eadie E, Ibbotson S, Hossain-Ibrahim K. P01.142 Comparing Outcomes in Glioblastoma Multiforme patients undergoing Photodynamic Therapy with a Second-Generation Photosensitiser vs 5-Aminolevulinic Acid — A Single Site Retrospective Analysis. *Neuro-Oncology*. 2018;20(suppl 3):265-265. https://doi.org/10.1093/neuonc/noy139.187
18. Stummer W, Stepp H, Möller G, Ehrhardt A, Leonhard M, Reulen HJ. Technical principles for protoporphyrin-IX-fluorescence guided microsurgical resection of malignant glioma tissue. *Acta Neurochirurgica*. 1998;140(10):995-1000. https://doi.org/10.1007/s007010050206
19. Webber J, Kessel D, Fromm D. On-line fluorescence of human tissues after oral administration of 5-aminolevulinic acid. *Journal of Photochemistry and Photobiology. B, Biology.* 1997;38(2-3):209-214. https://doi.org/10.1016/s1011-1344(96)07445-3
20. Stummer W, Reulen HJ, Novotny A, Stepp H, Tonn JC. Fluorescence-guided resections of malignant gliomas — an overview. *Acta Neurochirurgica. Supplement*. 2003;88:9-12. https://doi.org/10.1007/978-3-7091-6090-9_3
21. Stummer W, Pichlmeier U, Meinel T, Wiestler OD, Zanella F, Reulen HJ; ALA-Glioma Study Group. Fluorescence-guided surgery with 5-aminolevulinic acid for resection of malignant glioma: a randomised controlled multicentre phase III trial. *The Lancet. Oncology*. 2006;7(5):392-401. https://doi.org/10.1016/S1470-2045(06)70665-9
22. Sinha AK, Anand S, Ortel BJ, Chang Y, Mai Z, Hasan T, Maytin EV. Methotrexate used in combination with aminolaevulinic acid for photodynamic killing of prostate cancer cells. *British Journal of Cancer*. 2006;95(4):485-495. https://doi.org/10.1038/sj.bjc.6603273
23. Roberts DW, Valdés PA, Harris BT, Fontaine KM, Hartov A, Fan X, Ji S, Lollis SS, Pogue BW, Leblond F, Tosteson TD, Wilson BC, Paulsen KD. Coregistered fluorescence-enhanced tumor resection of malignant glioma: relationships between δ-aminolevulinic acid-induced protoporphyrin IX fluorescence, magnetic resonance imaging enhancement, and neuropathological parameters. *Journal of Neurosurgery*. 2011;114(3):595-603. https://doi.org/10.3171/2010.2.JNS091322
24. Byval'cev VA, Sorokovikov VA, Panasenkov SYu, Belyh EG, Ivanov NA, Cyganov PYu. CO2 laser in surgery of volume formations of the Central nervous system. *Lazernaya medicina*. 2013;17(2):34-39. (In Russ.).
25. Stummer W, Stocker S, Novotny A, Heimann A, Sauer O, Kempski O, Plesnila N, Wietzorrek J, Reulen HJ. *In vitro* and *in vivo* porphyrin accumulation by C6 glioma cells after exposure to 5-aminolevulinic acid. *Journal of Photochemistry and Photobiology B: Biology*. 1998;45(2-3):160-169. https://doi.org/10.1016/s1011-1344(98)00176-6
26. Tsai YC, Vijayaraghavan P, Chiang WH, Chen HH, Liu TI, Shen MY, Omoto A, Kamimura M, Soga K, Chiu HC. Targeted delivery of functionalized upconversion nanoparticles for externally triggered photothermal/photodynamic therapies of brain glioblastoma. *Theranostics*. 2018;8(5):1435. https://doi.org/10.7150/thno.22482
27. Akimoto J. Photodynamic therapy for malignant brain tumors. *Neurologia Medico-Chirurgica*. 2016;56(4):151-157. https://doi.org/10.2176/nmc.ra.2015-0296
28. Ewelt C, Stummer W, Klink B, Felsberg J, Steiger HJ, Sabel M. Cordectomy as final treatment option for diffuse intramedullary malignant glioma using 5-ALA fluorescence-guided resection. *Clinical Neurology and Neurosurgery*. 2010;112(4):357-361. https://doi.org/10.1016/j.clineuro.2009.12.013
29. Inoue T, Endo T, Nagamatsu K, Watanabe M, Tominaga T. 5-aminolevulinic acid fluorescence-guided resection of intramedullary ependymoma: report of 9 cases. *Operative Neurosurgery*. 2013;72(2):159-168. https://doi.org/10.1227/NEU.0b013e31827bc7a3
30. Valdés PA, Leblond F, Kim A, Harris BT, Wilson BC, Fan X, Tosteson TD, Hartov A, Ji S, Erkmen K, Simmons NE, Paulsen KD, Roberts DW. Quantitative fluorescence in intracranial tumor: implications for ALA-induced PpIX as an intraoperative biomarker. *Journal of Neurosurgery*. 2011;115(1):11-17. https://doi.org/10.3171/2011.2.JNS101451

Received 09.07.2020
Accepted 28.08.2020

Commentary

N.A. Konovalov et al. reported successful use of intraoperative fluorescence combined with laser spectroscopy. The problem of intraoperative tumor remnant identification is very relevant in patients with intramedullary tumors because some neoplasms are characterized by infiltrative growth or have no clear dissection plane. Moreover, gliosis within the tumor bed is difficult to be differentiated from tumor tissue in a light operating microscope after resection of ependymal tumors. In these cases, total resection with minimal neurological deficit is a difficult objective.

The authors applied intraoperative fluorescence in combination with laser spectroscopy. This technique is valuable to identify residual tumor tissue thanks to 5-ALA accumulation by the tumor cells. There were 35 interventions in patients with different neoplasms (ependymoma, astrocytoma, hemangioblastoma and cavernoma). The authors concluded high efficacy of this technique for astrocytic and ependymal tumors. This technology is not effective for cavernoma and hemangioblastoma since there are no cells capable for 5-ALA uptake in these tumors.

The authors carried out a comprehensive statistical analysis of the entire group of intramedullary tumors. Therefore, representative assessment of the entire group of patients with intramedullary tumors who were operated at the Burdenko Neurosurgery Center is possible.

The manuscript is relevant, characterized by scientific novelty and great practical importance, since intraoperative fluorescence combined with laser spectroscopy ensures total resection of tumor with minimum risk of persistent postoperative neurological deficit.

G.Yu. Evzikov (Moscow, Russia)