Burdenko's journal of neurosurgery
2020, №3, pp. 88-96
https://doi.org/10.17116/neiro20208403188

Resection of a giant fusiform aneurysm of the pericallosal artery with «hemi-bonnet bypass» procedure (case report and literature review)

© V.A. LUKYANCHIKOV[1, 4], I.V. SENKO[3], N.A. POLUNINA[1, 2], M.S. STAROVEROV[1], I.V. GRIGORIEV[3], M.V. SINKIN[1], I.V. TIKHOMIROV[1], G.K. GUSEYNOVA[1]

[1]Sklyfosovsky Research Institute for Emergency Care, Moscow, Russia;
[2]Evdokimov Moscow State University of Medicine and Dentistry, Moscow, Russia;
[3]Federal Centre for Cerebrovascular Pathology and Stroke, Moscow, Russia;
[4]Medical Institute of the Russian University of People's Friendship, Moscow, Russia

ABSTRACT

A 30-year-old woman with giant fusiform aneurysm of the azygos anterior cerebral artery is reported. Clipping of the aneurysm followed by modeling of pericallosal artery was performed in 2017. However, further enlargement of the aneurysm has been observed for subsequent 2 years. The patient underwent redo surgery with excision of the aneurysm followed by «hemi-bonnet bypass» procedure (anastomosis between superficial temporal artery and anterior cerebral artery with radial artery as an interposition graft). Literature data on reconstructive surgery in the treatment of complex pericallosal artery aneurysms are reviewed.

Keywords: recurrent fusiform aneurysm, «hemi-bonnet bypass», azygos anterior cerebral artery.

INFORMATION ABOUT THE AUTHORS:

Lukyanchikov V.A. — https://orcid.org/0000-0003-4518-9874
Polunina N.A. — https://orcid.org/0000-0001-8439-2109
Senko I.V. — https://orcid.org/0000-0002-4665-6879
Grigoriev I.V. — https://orcid.org/0000-0002-1320-5772
Staroverov M.S. — https://orcid.org/0000-0002-7341-797X; e-mail: staroverov1995@gmail.com
Sinkin M.V. — https://orcid.org/0000-0001-5026-0060
Tikhomirov I.V. — https://orcid.org/0000-0001-7290-7216
Guseynova G.K. — https://orcid.org/0000-0001-8475-3410
Corresponding author: Staroverov M.S. — e-mail: staroverov1995@gmail.com

TO CITE THIS ARTICLE:

Lukyanchikov VA, Senko IV, Polunina NA, Staroverov MS, Grigoriev IV, Sinkin MV, Tikhomirov IV, Guseynova GK. Resection of a giant fusiform aneurysm of the pericallosal artery with «hemi-bonnet bypass» procedure (case report and literature review). *Burdenko's Journal of Neurosurgery = Zhurnal voprosy neirokhirurgii im. N.N. Burdenko.* 2020;84(3):88-96. (In Russ.). https://doi.org/10.17116/neiro20208403188

Abbreviations

EMP — evoked motor responses
IONM — intraoperative neurophysiological monitoring
CT angiography — computed tomography of the vessels
CT — computed tomography
ECA — external carotid artery
STA — superficial temporal artery
PCA — pericallosal artery
ACA — anterior cerebral artery
SAH — subarachnoid hemorrhage
ICG — indocyanin green

Brain revascularization in the treatment of cerebral aneurysms is still actual in modern vascular neurosurgery. Indeed, certain aneurysms are available only for complex neurosurgical interventions despite the development of endovascular techniques and new types of occlusive materials and stents. For example, these are patients with complex saccular and fusiform aneurysms characterized by several efferent vessels originating from the cupola or cervical part of the aneurysm. Reconstruction of the damaged vascular pool with total occlusion of the aneurysm is preferred in these cases. Various types of anastomoses and shunts are used for adequate replacement of regional blood supply after aneurysm trapping. Aneurysms of anterior cerebral and pericallosal arteries are ones of the most difficult for revascularization.

These interventions are sporadic and their description is rarely found in the literature.

Case report

A 30-year-old patient *A.* became ill acutely in January 2017. Acute headache was followed by subsequent short-term loss of consciousness. The patient was hospitalized. Computed tomography (CT) revealed basal subarachnoid hemorrhage (SAH). According to MRI and CT-angiography data, there was a fusiform-saccular aneurysm of the right anterior cerebral artery (ACA). The patient was scheduled for surgery.

The patient was hospitalized to the emergency neurosurgery department of the Sklifosovsky Research Institute for Emergency Care in March 2017. Clinical deterioration was accompanied by transient numbness and weakness in the left leg. Complaints of pressing headaches mainly in the frontal region, clear consciousness and no focal and meningeal symptoms were observed upon admission. According to CT- and MR-angiography, digital subtraction angiography data, anomaly of brain arterial circle was diagnosed (absence of the right ACA including segment A1, the only segment A2 divided into two segments A3, aneurysm was localized on the right segment). This aneurysm of the right pericallosal artery (PCA) was characterized by complex fusiform-saccular shape and measures 20×16×20 mm. Right PCA and medial frontal artery originated from the aneurysmal sac (**Fig. 1a, b**).

Elective surgery was scheduled. Considering fusiform shape of aneurysm, we clipped the aneurysm by eight fenestrated clips, ensured right PCA lumen and patency of functionally important arteries (**Fig. 2a, b**). Intraoperative transcranial Doppler ultrasound and angiography with indocyanine green (ICG) confirmed these data. Postoperative period was uneventful. There was no neurological deterioration.

Digital subtraction angiography in 5 days after surgery confirmed occlusion of the aneurysm, patent right PCA and functionally significant arteries (**Fig. 3**). There was insignificant residual fragment of the aneurysmal sac within the ostia of the right pericallosal and medial frontal arteries. The patient was discharged in 2 weeks after surgery (GOS score 5).

Postoperative 2-year follow-up included annual examinations with angiography. Gradual aneurysm enlargement by 4 mm per year was observed. Headache recurred in 2019. Thus, the patient was hospitalized to the neurosurgical department of the Sklifosovsky Research Institute for Emergency Care. Examination revealed no neurological dysfunction. CT-angiography revealed a fusiform aneurysm 26×17×12 mm of A3 segment of the right PCA tunneled by clips. Digital angiography confirmed patent aneurysm and monkey's type of the left ACA (unpaired ACA) (**Fig. 4**).

Considering continued aneurysm growth and high risk of rupture, aneurysm trapping with subsequent revascularization of distal segment of PCA was preferred. Superficial temporal artery (STA) and radial artery were used as a donor and graft, respectively. We applied intraoperative neurophysiological monitoring (IONM) to control functional integrity of corticospinal tract and select the optimal recipient artery. IONM included continuous monitoring of evoked motor responses (EMR) of the muscles contralateral to the aneurysm. Direct electrical cortical stimulation by a flexible electrode was applied for this purpose (**Fig. 5**).

Two surgical teams performed operation (the main stage and radial artery harvesting). Considering intraoperative control of EMR, anesthesia implied minimal doses of muscle relaxants; propofol was the leading anesthetic drug. Patient's supine position was used, head was rigidly fixed in the middle position. Skin incision was made along the previous scar with preservation of the parietal branch of the right STA. Craniotomy and dura mater incision were followed by dissection of interhemispheric fissure and aneurysm. Severe adhesive process was noted.

Proximal segment of the right PCA with aneurysm, left PCA and distal efferent branches emerging from the aneurysm (right medial frontal and continuing right PCA) were dissected in step-by-step fashion. Testing with temporary clipping of the arteries was made under neurophysiological control and ICG. A good tolerance to cross-clamping of both branches of PCA within 30 minutes was observed. Fluorescence angiography revealed good retrograde blood flow in both efferent vessels. Pericallosal segment of the right ACA was chosen as a recipient considering larger diameter and region of blood supply. Trapping and excision of the fusiform aneurysm together with previously applied fenestrated clips were performed (**Fig. 6**).

The second surgical team performed simultaneous harvesting of the left radial artery and its hydrostatic dilatation with heparin solution. Anastomosis between the distal end of the radial artery and PCA was performed in end-to-end fashion (**Fig. 7**). Next, anastomosis of the proximal end of the graft with STA was performed.



Fig. 1. **Preoperative CT-angiography.**

a, b — structural features of the aneurysm: 1 — distal fusiform-saccular aneurysm of the right pericallosal artery, 2 — unpaired anterior cerebral artery (segment A2), 3 — right medial frontal artery, 4 — right pericallosal artery, 5 — bifurcation of unpaired segment A2 into 2 arteries, 6 — left pericallosal artery.

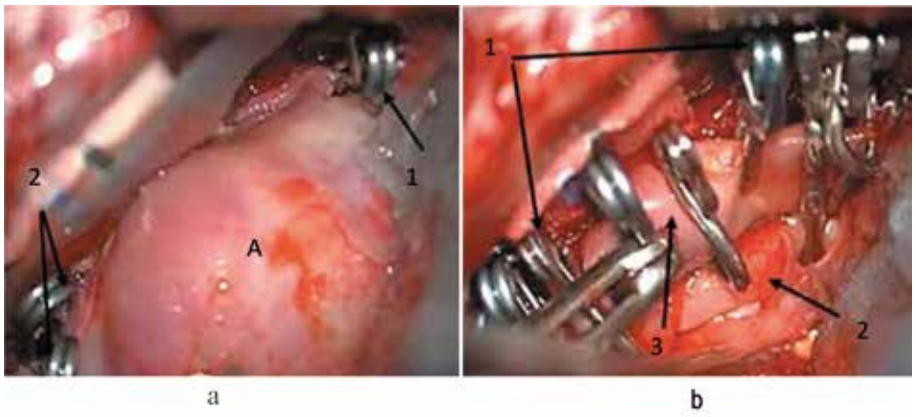

Fig. 2. **Clipping of fusiform-saccular aneurysm of the right pericallosal artery with fenestrated clips.**

Intraoperative images. a — 1 — temporary clip on the proximal segment of the right anterior cerebral artery, 2 — temporary clip on two efferent vessels originating distally from the aneurysm (right medial frontal and pericallosal arteries), A — aneurysm; b —1 — tandem of fenestrated clips, 2 — clipped segment of the aneurysm, 3 — lumen of the major vessel (anterior cerebral artery).

Considering less diameter of STA compared to diameter of the graft, the ends of both arteries were prepared by using of double fish-mouth technique (**Fig. 8**).

Clear pulsation of the graft was noted after suturing the anastomosis and blood flow release. Overall cross-clamping time was 259 min. Vascular occlusion was accompanied by continuous functional monitoring of corticospinal and corticobulbar tracts throughout the entire period of cross-clamping. Moreover, direct electrical cortical stimulation ensured complete immobility of surgical field. Graft patency was confirmed by Acland test, ICG, Doppler flowmetry. Blood flow velocity through the graft was 18 ml/min (**Fig. 9**). There was no reduced EMR amplitude from the contralateral muscles at the end of surgery. Bone channel for the shunt was formed by using of high-speed drill. The wound was sutured in layer-by-layer fashion (**Fig. 10**).

Postoperative period was uneventful. The patient woke up without focal neurological deficit and was activated on the 2nd day. Wound healing through primary intention was observed. Control CT-angiography and cerebral angiography confirmed adequate function of the shunt with filling of the pool of the right PCA. Blood flow velocity through the shunt was 46 ml/min in postoperative period (the 7th day after surgery) (**Fig. 11**). There was no neurological deficit. The patient was discharged in 12 days after surgery. Recommendations on lifestyle and protecting the graft from compression and injuries are given (**Fig. 12**).

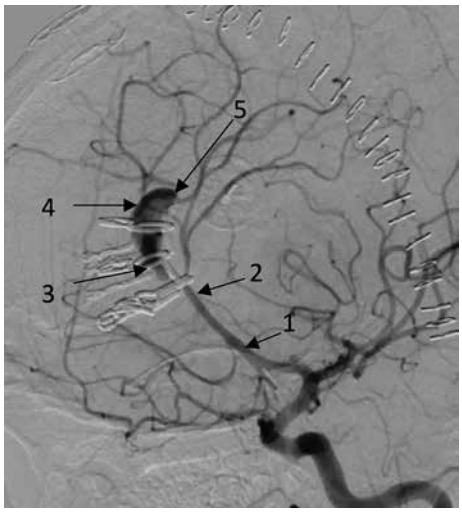

Fig. 3. **Digital subtraction angiography after the first surgery, lateral plane.**

1 — unpaired segment A2 of anterior cerebral artery, 2 – bifurcation of unpaired segment A2 into the right and left trunks, 3 – reconstructed lumen of the right pericallosal artery, 4 — residual fragment of the aneurysmal sac, 5 – discharge of the right pericallosal and right callosomarginal arteries..

Reconstructive interventions in the treatment of complex aneurysms of pericallosal artery

Multiple authors emphasized the need for brain revascularization in surgery of distal cerebral aneurysms [1—3]. Both extra-intracranial and intra-intracranial anastomoses are used in surgery of distal aneurysms [1, 2, 4]. Extra-intracranial anastomoses are divided into low-flow and high-flow ones, intra-intracranial anastomoses are divided into anastomosis in situ, re-anastomosis, reimplantation and interposition bypass [1, 2, 4, 5].

Considering deep localization of PCA aneurysms, most revascularization procedures in ACA pool are predominantly performed by using of intra-intracranial bypass [6–9]. A. Abla et al. (2014) reported an algorithm for brain revascularization in ACA pool. The authors identified three types of bypass techniques: longitudinal — "anterior to posterior" (from segment A1 to segments A2—A3 on the same ACA), transverse — "left to right" (from one ACA to the opposite one within any segment), centripetal — "lateral to medial" (from the pool of external carotid artery or middle cerebral artery to ACA) [6]. Anastomoses in surgery of PCA aneurysms are reported only in 3 cases; other aneurysms were localized within segment A1 of ACA and anterior communicating artery. All PCA anastomoses were intra-intracranial [6]. Occlusion of the aneurysms of unpaired ACA without revascularization procedures is also possible [10].

All types of intra-intracranial anastomoses reported in the literature are applicable for complex PCA aneurysms [2—5, 7, 8]. However, extra-intracranial bypass of ACA with different insertion vessels have recently become a full-fledged alternative to intra-intracranial bypass [11—16].

There are two main extracranial donors for ACA revascularization: external carotid artery (ECA) and STA. ECA is rarely used as a donor due to its remoteness from ACA and need to use great saphenous vein (length of radial artery is insufficient) [8, 12, 14].

We focused on STA as the main donor for distal ACA. The length of STA branches is insufficient PCA revascularization. Therefore, interposition of vascular graft is necessary as in the case of ECA. Radial artery [9, 11, 13, 15, 17, 18] or branches of contralateral STA [8, 16, 19] are more often used to increase the length of STA. Brain revascularization with vascular insert on the side of STA is called "hemi-bonnet bypass" in the literature [16, 18, 20].

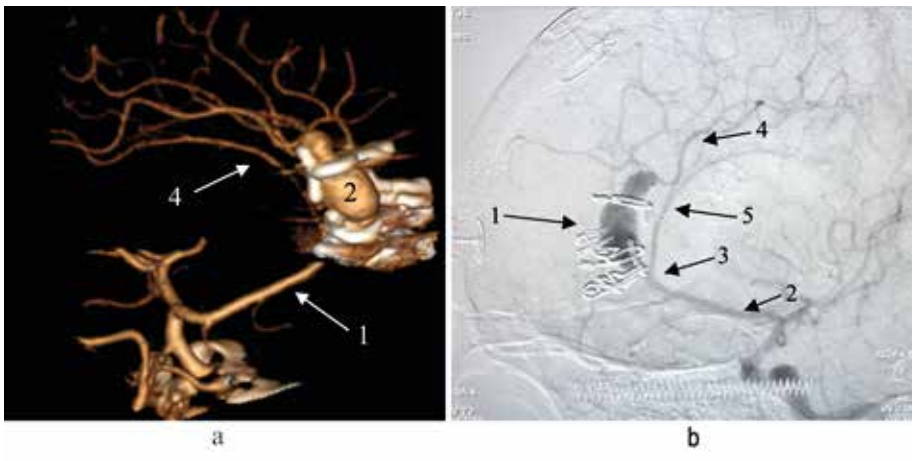

Fig. 4. **Survey data in 2 years after the first surgery.**

a — CT-angiography: 1 — unpaired anterior cerebral artery; 2 – recurrent fusiform aneurysm of the right pericallosal artery; 4 — left pericallosal artery; b — digital subtraction angiography: 1 — fusiform aneurysm of segment A3 of the right pericallosal artery tunneled with clips; 2 — unpaired left anterior cerebral artery; 3 — bifurcation of the left anterior cerebral artery; 4 — right pericallosal artery; 5 — left pericallosal artery.

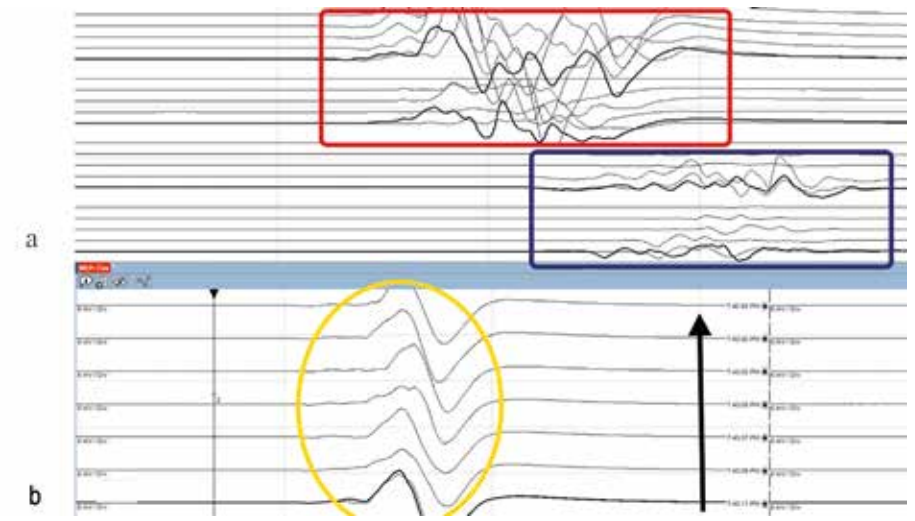

Fig. 5. **Evoked motor responses following intraoperative transcranial stimulation during occlusion of the giant fusiform aneurysm of pericallosal artery.**

a — evoked motor responses from the muscles of the hands — red rectangle, evoked motor responses from the muscles of the legs — blue rectangle; b — evoked motor responses from the abductor digiti minimi contralateral to the aneurysm (yellow oval). A vertical arrow indicates direction and time of sequential stimulation.

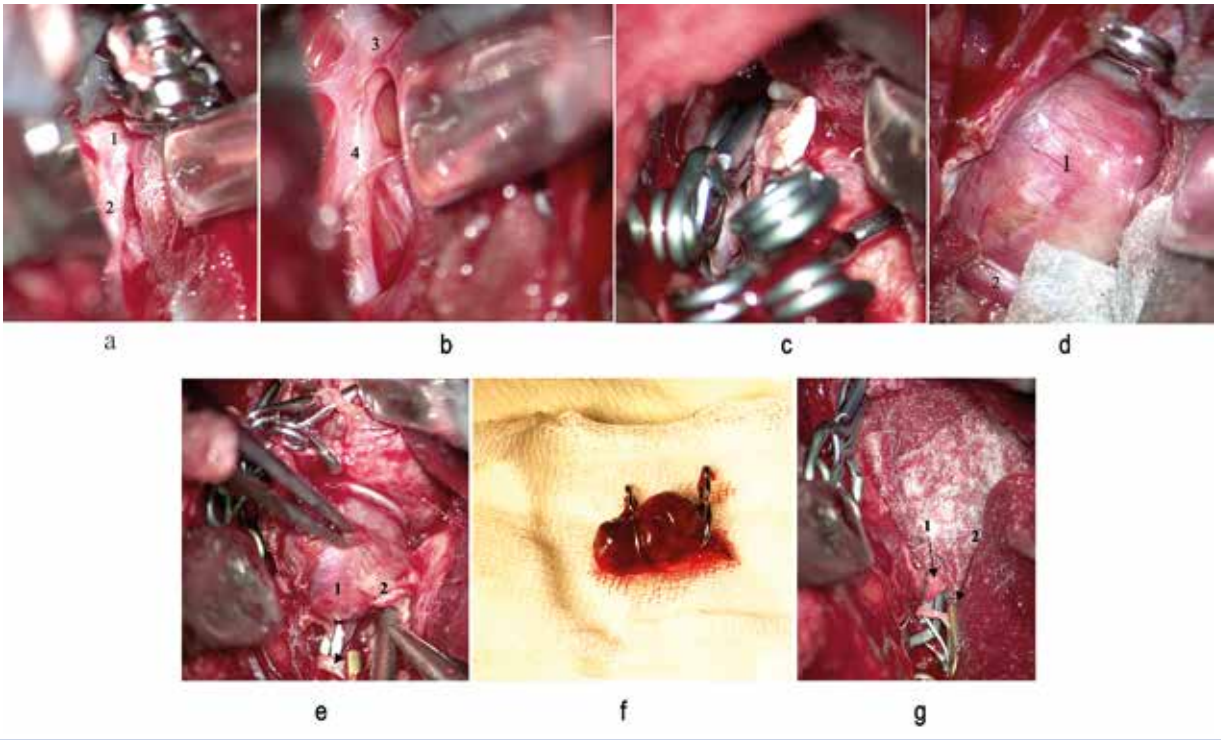

Fig. 6. **Aneurysm trapping followed by distal revascularization of pericallosal artery. Stage of aneurysm excision.**

Intraoperative images. a, b – aneurysm of the right pericallosal artery and its arteries mobilized from adhesions: 1 — trunk of unpaired anterior cerebral artery, distal part; 2 — bifurcation of segment A2 of anterior cerebral artery, 3 — proximal part of the right pericallosal artery with aneurysm; 4 — left pericallosal artery; c — proximal part of the aneurysm mobilized from adhesions, its cavity is tunneled by clips; d — 1 — distal part of the aneurysm, 2 – efferent medial frontal branch; e — 1 — aneurysm, 2 – intersected right pericallosal artery; f — resected aneurysm; g — aneurysm bed after its excision and evacuation: 1 — permanent clip on the medial frontal branch, 2 — temporary clip on the distal part of the right pericallosal artery.

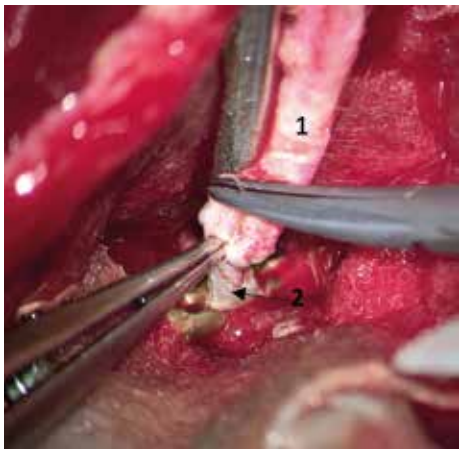

Fig. 7. **Aneurysm trapping followed by distal revascularization of pericallosal artery.**

Suturing the anastomosis between the distal end of the graft and the right pericallosal artery: 1 — graft (radial artery), 2 — right pericallosal artery.

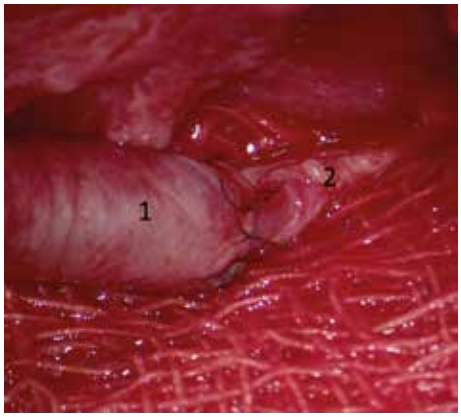

Fig. 8. **Patent anastomosis between the proximal part of the radial artery (1) and superficial temporal artery (2).**

The two main advantages of hemi-bonnet bypass over intra-intracranial bypass are less technical difficulty and no risk of bilateral lesion of ACA pool. The main disadvantages of extra-intracranial bypass with vascular grafts are large length with increased risk of thrombosis and superficial placement of the shunt followed by risk of mechanical damage [8, 17, 18, 20]. There are only 5 case reports on STA-PCA anastomosis with radial artery insertion in surgery of ACA aneurysms. All patients had favorable clinical outcomes with good function of anastomosis [11, 13, 15, 18].

Another feature of this clinical case was monitoring of motor functions by using of direct cortical stimulation [21]. Unlike transcranial electrical stimulation as conventional method of IONM, direct cortical stimulation eliminates significant motor reaction after electrical impulse delivery. Thus, we were able to use microsurgical technique of anastomosis throughout the entire surgical stage without pauses for functional assessment of corticospinal and corticobulbar tracts.

Conclusion

We reported favorable outcome of hemi-bonnet bypass surgery in a patient with complex aneurysm of pericallosal artery. The use of superficial temporal artery combined with radial artery may be a good alternative to intra-intracranial bypass in surgery of cerebral aneurysms. Moreover, this approach may be single possible in some situations.

Authors' participation:

Concept and design of the study — V.L.

Collection and analysis of data — V.L., I.G., M.S., M.S., I.V., G.K.

Writing the text — I.S., M.S., M.S.

Editing — V.L.

The authors declare no conflicts of interest.

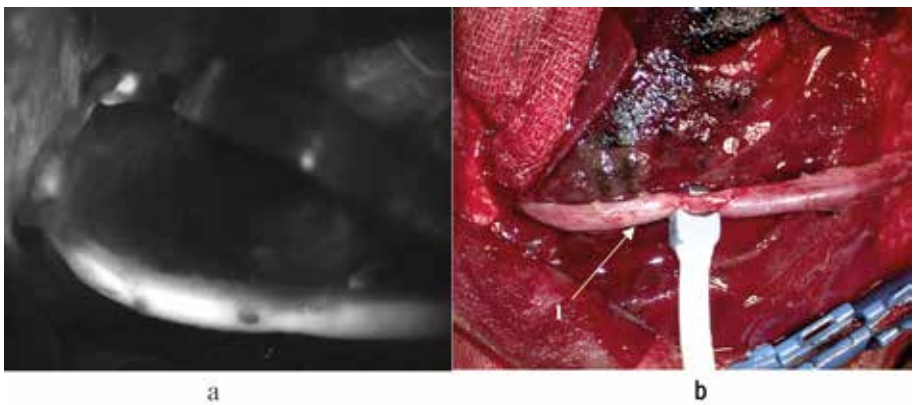

Fig. 9. **Assessment of the anastomosis.**

a — contrast enhancement of the graft during intraoperative fluorescence angiography; b — intraoperative flowmetry, transducer is deployed on the graft, 1 — filling of the graft from the radial artery.



Fig. 10. **Shunt placed within the bone canal of the cranial vault.**
1 — filling of the graft from the radial artery.



Fig. 12. **Patient *A.* at discharge.**

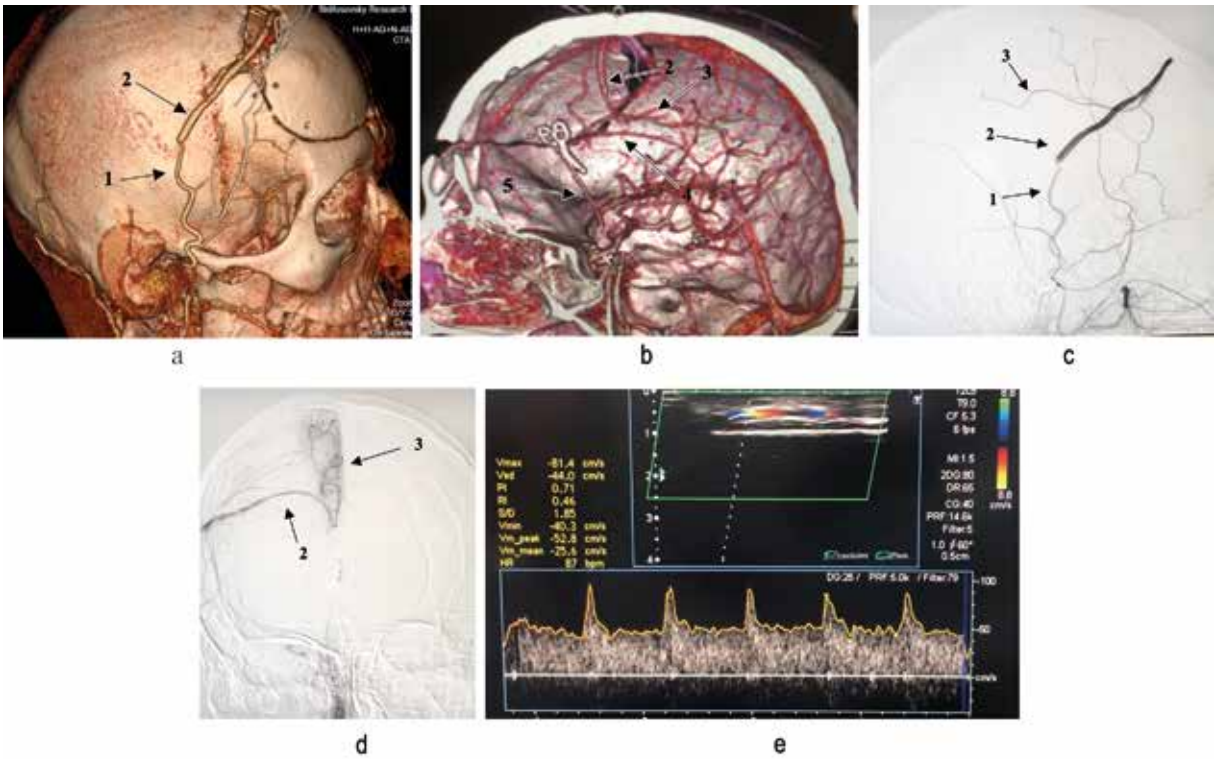

Fig. 11. **Control examination.**
a, b — CT-angiography: 1 — superficial temporal artery, 2 — patent graft, 3 — right pericallosal artery, 4 — left pericallosal artery, 5 — unpaired anterior cerebral artery; c, d — selective angiography of the right external carotid artery: 1 — superficial temporal artery, 2 — patent graft, 3 — right pericallosal artery pool; e – ultrasound of the graft: linear blood flow rate — 50 cm/s, blood flow velocity — 46 ml / min.

REFERENCES

1. Rodriguez-Hernandez A, Zador Z, Rodriguez-Mena R, Lawton M. Distal aneurysms of intracranial arteries: application of numerical nomenclature, predilection for cerebellar arteries, and results of surgical management. *World Neurosurgery.* 2013;80:103-112. https://doi.org/10.1016/j.wneu.2012.09.010
2. Nussbaum E, Madison M, Goddard J, Lassiq J, Nussbaum L. Peripheral intracranial aneurysms: management challenges in 60 consecutive cases. *Journal of Neurosurgery.* 2009;110(1):7-13. https://doi.org/10.3171/2008.6.JNS0814
3. Wu C, Sun Z, Wang F, Xu B, Zhou D. Surgical managements of peripheral intracranial aneurysms. *Zhonghua Yi Xue Za Zhi.* 2014;94(9):698-700.
4. Kalani MYS, Ramey W, Albuquerque FC, McDougall CG, Nakaji P, Zabramski JM, Spetzler RF. Revascularization and aneurysm surgery: techniques, indications, and outcome in the endovascular era. *Neurosurgery.* 2014;74(5):482-498. https://doi.org/10.1227/NEU.0000000000000312
5. Polunina NA. Revascularizing operations in surgery of cerebral aneurysms. *Nejrohirurgiya.* 2012;1:82-85. (In Russ.). https://doi.org/10.17650/1683-3295-2012-12-1-82-87
6. Abla A, Lawton M. Anterior cerebral artery bypass for complex aneurysms: an experience with intracranial-intracranial reconstruction and review of bypass options. *Journal of Neurosurgery.* 2014;120(6):1364-1376. https://doi.org/10.3171/2014.3.JNS132219
7. Chen PR, Abla AA, McDougall CG, Spetzler RF, Albuquerque FC. Surgical techniques for unclippable fusiform A2-anterior cerebral artery aneurysms and description of a frontopolar-to-A2 bypass. *World Neurosurgery.* 2014;81(2):9-15. https://doi.org/10.1016/j.wneu.2012.10.019
8. Ota N, Tanikawa R, Miyama M, Matsumoto T, Miyazaki T, Matsukawa H, Tsuboi T. Surgical strategy for complex anterior cerebral artery aneurysms: retrospective case series and literature review. *World Neurosurgery.* 2016;87:328-345. https://doi.org/10.1016/j.wneu.2015.10.079
9. Nakajima H, Kamiyama H, Nakamura T, Takizawa K, Ohata K. Direct surgical treatment of giant intracranial aneurysms on the anterior communicating artery or anterior cerebral artery. *Neurologia Medico-Chirurgica.* 2013;53(3):153-156. https://doi.org/10.2176/nmc.53.153
10. Krylov VV, Evzikov GYu, Zakharov AG. Surgical treatment of an aneurysm of the unpaired anterior cerebral artery. *Voprosy neirokhirurgii imeni N.N. Burdenko.* 1994;3:31-32. (In Russ.).
11. Dengler J, Kato N, Vajkoczy P. The Y-shaped double-barrel bypass in the treatment of large and giant anterior communicating artery aneurysms. Technical note. *Journal of Neurosurgery.* 2013;118(2): 444-450. https://doi.org/10.3171/2012.11.JNS121061
12. Brilstra EH, Rinkel GE, Klijn CM, van der Zwan A, Algra A, Lo RH, Tulleken CF. Excimer laser-assisted bypass in aneurysm treatment: short-term outcomes. *Journal of Neurosurgery.* 2002;97(5):1029-1035. https://doi.org/10.3171/jns.2002.97.5.1029
13. Kim K, Mizunari T, Mizutani N, Kobayashi S, Takizawa K, Kamiyama H, Teramoto A. Giant intracranial aneurysm of the anterior communicating artery treated by direct surgery using A3-A3 side-to-side anastomosis and A3-RA graft-STA anastomosis. *Acta Neurochirurgica.* 2006;148(3):353-357 https://doi.org/10.1007/s00701-005-0685-1
14. Ewald C, Kuhne D, Hassler W. Bypass-surgery and coil-embolisation in the treatment of cerebral giant aneurysms. *Acta Neurochirurgica.* 2000;142(7):731-738. https://doi.org/10.1007/s007010070
15. Inoue T, Tsutsumi K, Ohno H, Shinozaki M. Revascularization of the anterior cerebral artery with an A3-A3 anastomosis and a superficial temporal artery bypass using an A3-radial artery graft to trap a giant anterior communicating artery aneurysm: technical case report. *Neurosurgery.* 2005;57(suppl 1):E207. https://doi.org/10.1227/01.neu.0000163682.31075.28
16. Park ES, Ahn JS, Park JC, Kwon DH, Kwun BD, Kim CJ. STA-ACA bypass using the contralateral STA as an interposition graft for the treatment of complex ACA aneurysms: report of two cases and a review of the literature. *Acta Neurochirurgica.* 2012;154(8):1447-1453. https://doi.org/10.1007/s00701-012-1410-5
17. Lukyanchikov VA, Staroverov MS. Revascularization of the brain using the Bonnet method. *Nejrohirurgiya.* 2019;21(2):85-91. (In Russ.). https://doi.org/10.17650/1683-3295-2019-21-2-85-93
18. Wada K, Otani N, Toyooka T, Takeuchi S, Tomiyama A, Mori K. Superficial temporal artery to anterior cerebral artery hemi-bonnet bypass using radial artery graft for prevention of complications after surgical treatment of partially thrombosed large/giant anterior cerebral artery aneurysm. *Journal of Stroke and Cerebrovascular Diseases.* 2018;27(12):3505-3510. https://doi.org/10.1016/j.jstrokecerebrovasdis.2018.08.020
19. Iwata Y, Mizuta T, Takemoto O, Shimizu K, Nakatani S. An interposed superficial temporal artery graft bypass for anterior cerebral artery ischemia. *Microsurgery.* 1988;9(1):14-17. https://doi.org/10.1002/micr.1920090105
20. Spetzler R, Roski R, Rhodes R, Modic MT. The «bonnet bypass». Case report. *Journal of Neurosurgery.* 1980;53(5):707-709. https://doi.org/10.3171/jns.1980.53.5.0707
21. MacDonald DB, Skinner S, Shils J, Yingling C; American Society of Neurophysiological Monitoring. Intraoperative motor evoked potential monitoring — A position statement by the American Society of Neurophysiological Monitoring. *Clinical Neurophysiology.* 2013;124(12):2291-2316. https://doi.org/10.1016/j.clinph.2013.07.02

Received 17.11.19
Accepted 28.02.20

Commentary

Giant fusiform aneurysms of cerebral arteries is a complex problem in the treatment of hemorrhagic stroke.

The authors reported an interesting case of the treatment of this disease with a rare variant of revascularization approach — extra-intracranial bypass through the anastomosis between superficial temporal artery and pericallosal artery. Surgical technique and interesting technology of intraoperative monitoring of evoked potentials for cerebral ischemia control are comprehensively described. However, an appropriateness of revascularization in this case is debatable considering signs of adequate collateral compensation of cerebral blood flow in distal parts of pericallosal artery. This is confirmed by smooth period of prolonged cross-clamping of pericallosal artery (259 min) and initially low blood flow velocity through the graft (18 ml/min). In this regard, there is also a question about long-term postoperative function of anastomosis.

Nevertheless, successful surgical treatment of giant fusiform aneurysm of pericallosal artery is certainly interesting and allows expanding the arsenal of possible surgical techniques for specialists involved in the treatment of this disease

Yu.V. Pilipenko (Moscow, Russia)