https://doi.org/10.17116/engneiro20198302151

Reproductive Disorders and Preservation of Fertility in Males with Benign and Malignant Brain Tumors

L.I. ASTAF'EVA[1]*, O.B. ZHUKOV[2,3], B.A. KADASHEV[1], I.S. KLOCHKOVA[1], G.L. KOBYAKOV[1], A.A. PODDUBSKIY[1], P.L. KALININ[1,2]

[1]Burdenko Neurosurgical Institute, Moscow, Russia
[2]Peoples' Friendship University of Russia, Moscow, Russia
[3]European Medical Center, Moscow, Russia

Brain tumors rank third in the incidence rate among cancer nosologies. However, improvement of neurosurgical treatment methods and the use of modern regimens of chemotherapy and radiotherapy have increased survival of patients with benign and malignant brain tumors. A significant proportion of patients with brain tumors are young people in the reproductive age who are interested in maintaining their fertility. Surgical removal of tumors, mainly in the hypothalamo-pituitary area as well as the use of chemotherapy and radiotherapy for malignant brain tumors of any localization may be complicated by hypogonadism and infertility. At present, a simple and reliable method of preserving male fertility is sperm cryopreservation. Neurosurgeons as well as oncologists and radiologists should inform patients with brain tumors about a potential risk of hypogonadism and infertility after treatment and about opportunities of sperm cryopreservation, which increases the chances of having future genetic progeny.

Keywords: hypogonadism, male infertility, brain tumors, hypothalamo-pituitary tumors, spermatozoa cryopreservation.

Abbreviations:

ART — assisted reproductive technologies
LH — luteinizing hormone
MRI — magnetic resonance imaging
FSH — follicle stimulating hormone
CNS — central nervous system

Increased incidence of benign and malignant tumors including brain tumors is observed in recent decades. Annually incidence of primary CNS tumors in young patients is 10.94 cases per 100,000. Over 50% of brain tumors are benign in patients of reproductive (15—39 years) age. These are pituitary tumors (29%), meningiomas (14%) and neuromas (9%), etc. Gliomas account 1/3 of all brain tumors, while 74% of them are malignant [1].

Survival rate in patients with benign and malignant brain tumors is increasing due to improved neurosurgical techniques, the use of modern modes of chemo- and radiotherapy. Five-year survival after diagnosis of benign CNS tumor is 90%. In patients with malignant CNS tumors this value is 74% for patients aged 0—19 years and 62% for patients aged 20—44 years [1].

It is known that neurosurgery for brain tumors (especially in hypothalamic-pituitary area), chemo- and radiotherapy of malignant brain tumors of any localization may be complicated by hypogonadism and infertility. Preservation of fertility is particularly important in young and childless patients.

Cryopreservation of spermatozoa is currently the main method of preserving male fertility [2]. It is an easy and reliable method to have your own children in the future. Sperm cryobanks allow long-term storage of frozen ejaculate in liquid nitrogen at a temperature of –196 ° C. There are cases of birth of healthy children as a result of fertilization of an egg by cryopreserved spermatozoa of patients who underwent treatment for cancer. Sperm has been preserved for 21 and 28 years [3, 4].

Only 20% of patients use cryopreservation although almost half of the patients are concerned about preservation of fertility. This is due poor informing of patient by neurosurgeon and/or oncologist about the possibilities of germ cells preservation and socio-psychological reasons of patients.

In the Russian Federation, the use of fertility preservation technologies including in patients with cancer is regulated by the order of the Ministry of Health of Russia No. 107n dated August 30, 2012 "On the procedure for using assisted reproductive technologies, contraindications and restrictions to their application" [5]. However, standards of interaction between oncologists and specialists for reproduction have not been developed yet [6, 7].

Special centers for cryopreservation have own sites describing cryopreservation of sperm and transport kits for transportation of material from home or clinic (including remote areas). In the USA, 5-year preservation of three ejaculates costs from $ 25 to $ 35 per month. There are 47 addresses in Moscow for similar procedure of sperm preservation. Minimum price is 2,000 rubles, mean — 8,939 rubles. The cost of sperm cryopreservation is 300—1,000 rubles per month [8].

Reproductive disorders in patients with hypothalamic-pituitary benign tumors. Reproductive dysfunction may be directly caused by hypothalamic-pituitary tumor followed by

© Group of authors, 2019

*e-mail: LAst@nsi.ru

impaired secretion of gonadoliberins and/or gonadotropins and secondary hypogonadism. These tumors are usually hormone-producing and inactive pituitary adenomas, craniopharyngiomas, etc. Clinical symptoms of hypogonadism are impaired sexual function (decreased libido, erectile dysfunction) and spermatogenesis (infertility). Long-term androgen deficiency also results osteoporosis, metabolic and cardiovascular disorders.

Prevalence of hypogonadism in patients with pituitary adenoma is over 60% [9—11]. Adenoma results compression of pituitary gland and impairment of its gonadotropic function. Excessive hormonal secretion followed by reduced level of testosterone and impaired spermatogenesis is another negative result of hormone-producing tumors besides mass effect. As a rule, these tumors release prolactin (prolactinoma) and ACTH (corticotropinoma followed by clinical signs of Cushing disease). Growth hormone-secreting adenomas are rarer (somatotropinoma followed by clinical symptoms of acromegaly). Endocrine-inactive pituitary adenomas are not accompanied by clinical symptoms of hormonal hypersecretion. These neoplasms are characterized by slow grow and result pituitary gland dysfunction (hypopituitarism). The most common primary symptoms of disease are decreased libido and erectile dysfunction. However, patients with these disorders rarely appeal to the doctor. As a result, these tumors remain undiagnosed for a long time until appearance of visual and neurological disorders caused by mass effect of the tumor. Long-term compression of pituitary gland may be followed by atrophy of gonadotropin-secreting cells and persistent hypogonadism.

Hyperprolactinemia is caused by prolactinoma in most cases. It is one of the leading causes of male infertility [12]. Therapy with dopamine agonists is highly effective for prolactinoma and results reduced dimensions or regression of the tumor in 80—85% of patients, significant decrease or normalization of the level of prolactin in 70—80% of cases and recovery of gonadotropic function in 80% of patients. However, persistent hypogonadism caused by atrophy of gonadotropin-secreting pituitary cells is observed in 20% of men with prolactinoma and normoprolactinemia [13]. Asthenoteratozoospermia is characteristic for pituitary adenoma violation of spermatogenesis [3].

Neurosurgery for pituitary adenoma can also result occurrence or aggravation of hypogonadism due to intraoperative injury of pituitary gland. Radiotherapy is used in patients with pituitary adenoma after non-radical neurosurgery. Secondary hypogonadism is diagnosed in 80—90% of cases due to radiotherapy-induced injury of pituitary tissue [14].

The most common endocrine disorders, primarily hypogonadism, are observed in patients with craniopharyngiomas (disembriogenetic hypothalamic-pituitary benign tumors). It is known that these tumors are accompanied by hypogonadism in 60% of cases prior to surgery. Incidence of this complication is increased up to 80—100% after excision of these tumors regardless localization and surgical approach [15, 16].

High incidence of hypogonadism in men with hypothalamic-pituitary tumors is accompanied by significantly reduced quality of life, sexual and reproductive potential.

It is necessary to examine androgenic status (LH, FSH, testosterone) in all men with hypothalamic-pituitary tumors prior to surgery. Moreover, sperm quality assessment is advisable in those interested for preserved fertility. However, these studies are not preoperatively carried out in neurosurgical clinics as a rule.

Testosterone replacement therapy is currently preferred for secondary hypogonadism. Medication eliminates androgen deficiency, normalizes sexual function and significantly improves quality of life. However, these drugs do not affect recovery of reproductive function.

There are no clear literature data regarding feasibility of sperm cryopreservation in patients with benign hypothalamic-pituitary tumors. Indeed, on the one hand, hypogonadism and impaired sperm quality have been already diagnosed at the stage of tumor diagnosis as a rule. On the other hand, stimulating monotherapy with chorionic gonadotropin or combined therapy with follicle-stimulating hormone drugs are possible if reproductive rehabilitation is required. These approaches improve sperm quality and increase the likelihood of pregnancy in a female partner in some cases [17]. Currently, there are no randomized trials devoted to the effectiveness of this therapy in patients with hypothalamic-pituitary tumors. Moreover, therapy is associated with certain risk of tumor progression prior to surgery and after non-radical operation. An important factor is high cost of the treatment.

Gonadotropin therapy is justified in patients after radical excision of tumor. Courses up to 3—6 months are advisable under MRI control of the brain. Sperm cryopreservation is advisable in patients with secondary hypogonadism who are interested for reproductive potential. This procedure should be performed after gonadotropin therapy followed by restoration of sperm quality. Continued testosterone therapy is recommended after induction of pregnancy or sperm cryopreservation.

It is reasonable to preoperatively inform patients with intact gonadotropic function about the risk of various endocrine disorders (including hypogonadism) and potential advisability of preoperative sperm cryopreservation. This strategy should be applied primarily in young men, as well as in all patients who any interested for reproductive potential.

Reproductive disorders in patients with brain malignancies. Malignant tumors may be localized in hypothalamic-pituitary zone (germ cell tumors, malignant gliomas, metastases, etc.) or in other areas without involvement of endocrine structures. However, combined treatment including surgery, chemo- and radiotherapy often results various endocrine disorders including hypogo-

nadism and infertility regardless localization of tumor. S. Shalitin et al. [18] reported various endocrine disorders in 57% of patients who underwent treatment for brain tumors. At the same time, complications of antitumor therapy can develop during treatment, immediately after therapy and in long-term period.

Cranial irradiation can cause pituitary gland injury with the loss of all pituitary functions (including gonadotropic). Incidence of radiotherapy-induced secondary hypogonadism in patients with brain tumors is 5—61% depending on the dose and mode of irradiation. Standard scheme of irradiation in patients with brain tumors implies overall dose of 30—50 Gy. The most significant risk factor of hypogonadism is the dose of cranial irradiation over 30—40 Gy [19]. Thus, clinically significant secondary hypogonadism occurs in 20—50% of patients exposed to a dose of more than 30—40 Gy [20]. Cranial and spinal irradiation is used in some treatment modes for brain tumors and can result primary lesion of gonads [21].

Chemotherapy has a direct gonadotoxic effect. Alkylating drugs are the most toxic for male fertility because these medicines damage spermatogenic epithelium. Therefore, sperm sampling should be carried out before radio- and/or chemotherapy onset, since sperm quality is significantly impaired during the treatment. Testicular tissue cryopreservation is being developed for boys in prepubertal age [22—24].

Case report No. 1

A 30-year-old patient *K.* noted headache 6 months ago. Deterioration of visual function occurred within the last 3 months that required survey. MRI of the brain revealed giant multinodular endosupralaterosellar pituitary adenoma. The patient is married and has not children. Impairment of libido and erectile dysfunction are not noted.

Examination at the Neurosurgery Center: chiasmatic syndrome (bitemporal violation of visual acuity and visual fields), no hormonal disorders, prolactin 430 mU/l (60—510), FSH 3.4 mU/l (1.55—9.74), LH 4.5 mU/l (2.5—11.0), testosterone 12.2 nmol/l (12—35).

The patient was informed about the high risk of hypopituitary disorders/hypogonadism after surgery and the possibility of sperm cryopreservation. Patient turned to a cryobank prior to surgery for analysis of spermogram. Examination found no abnormalities, and spermatozoa were cryopreserved.

The patient underwent subtotal endonasal transsphenoidal endoscopic removal of endocrine-inactive pituitary adenoma on January, 30, 2015. Recovery of visual function was observed after surgery. However, postoperative panhypopituitarism (secondary hypothyroidism, hypocorticism, and hypogonadism) and diabetes insipidus required therapy with hydrocortisone, levothyroxine and desmopressin. A control MRI 6 months later revealed a large residual tumor within the cavernous sinus.

In August — September 2015, a course of stereotactic radiotherapy was performed for residual tumor (Novalis linear accelerator with a photon energy of 6 MeV). There were 30 fractions by 1.8 Gy up to overall dose of 53.7 Gy.

Control examination in 6, 12 and 24 months after surgery confirmed persistent panhypopituitarism and diabetes insipidus. Hormonal blood test (12 months after surgery): FSH 0.8 mU/l (1.55—9.74), LH 0.2 mU/l (2.5—11.0), testosterone 2,1 nmol/l (12—35). Spermogram: 5 million spermatozoa in 1 ml of ejaculate (WHO norm ⩾15 million/ml), normal forms — 0% (WHO norm according to strict Kruger's criteria ⩾4%), progressive motile A + B — 0% (WHO norm ⩾32%). Asthenoteratozoospermia was confirmed.

Gonadotropin therapy was not prescribed considering possible stimulating effect on residual tumor. Testosterone replacement therapy was prescribed (testosterone undecanoate). Treatment of infertility using ART and cryopreserved sperm in 2.5 years after surgery resulted birth of a healthy child.

Case report No. 2

In October 2013, a 21-year-old patient *S.* noted headache, periodic dizziness, nausea and vomiting. Contrast-enhanced MRI of the brain revealed a pineal tumor with initial signs of occlusive hydrocephalus. He was hospitalized for an open biopsy. The result of a biopsy is a germinoma. The patient was informed about the risks of treatment and potential impairment of fertility. However, the patient refused cryopreservation. Treatment was initiated according to the protocol for germinoma. There were 4 courses of chemotherapy (cisplatin + etoposide) followed by radiotherapy with irradiation of the entire ventricular system (overall dose of 24 Gy). Spermogram was analyzed in 3.5 years after the treatment. There was a significantly reduced number of spermatozoa up to 7 million per 1 ml of ejaculate (WHO norm ⩾15 million/ml), progressive motile (A + B) — 36% (WHO ⩾32%), immotile 50% (WHO norm ⩽ 30%), normal forms — 1% (Kruger's strict criteria ⩾4%). So, asthenoteratozoospermia was confirmed. Hormonal blood test: FSH 9.9 mU/l (1.4—18.1), LH 5.92 mU/l (1.5—9.3), testosterone 9.52 nmol/l (12—35), inhibin B 78 pg/ml (120—470). Prospects for restoration of reproductive function are clearly reduced in a patient considering significant deterioration of sperm quality after chemoradiotherapy.

Case report No. 3

A 28-year-old patient *S.* has noted headache and rare difficulties in words pronouncing since October 2014. MRI of the brain on September 5th, 2015 revealed a small tumor in the left frontal lobe without contrast uptake.

Tumor was removed on November 30th, 2015 (anaplastic astrocytoma, WHO Grade III).

Chemoradiotherapy was applied considering tumor morphology. Patient was informed about the risk of infertility and the possibility of sperm cryopreservation be-

fore the treatment. Patient turned to a cryobank prior to surgery for analysis of spermogram. Examination found no abnormalities, and spermatozoa were cryopreserved.

In February — April 2016, a course of stereotactic radiotherapy was performed (Primus linear accelerator with a photon energy of 6 MeV). There were 30 fractions by 2.1 Gy at the isocenter up to overall dose of 63 Gy. Subsequent 6 courses of chemotherapy included lomustine + vincristine + natulan. The last course was conducted in December 2016. All three chemotherapeutic agents have a negative effect on spermatogenesis, but natulan is characterized by the most significant toxic effect.

The patient appealed to a doctor in April 2018 with a desire to have a baby. There were complaints about impaired libido and erectile dysfunction. Analysis of spermogram showed a complete absence of spermatozoa in ejaculate (azoospermia). Hormonal blood test: FSH 14.79 mMe/ml (0.95—11.95), testosterone 25.53 nmol/l (12—35), inhibin B 65 pg/ml (42—392). There was reduced total volume of testes up to 14 cm^3 (norm 30 cm^3). Azoospermia caused by primary lesion of germinal epithelium after chemotherapy may be supposed considering high level of FSH combined with low level of inhibin B, as well as reduced testicular volume. Prospects for restoration of reproductive function are very doubtful. However, the patient has a chance to have genetic progeny considering presence of cryopreserved sperm in a cryobank.

Conclusion

Neurosurgeons, oncologists and radiologists should inform patients with brain tumors about the possible risk of hypogonadism, infertility and advisability of sperm cryopreservation. This approach increases the chance to have genetic progeny in the future.

Sperm cryopreservation is advisable in young patients, as well as in those who are interested for reproductive potential:

1) benign hypothalamic-pituitary tumors (pituitary adenoma, craniopharyngioma, etc.);

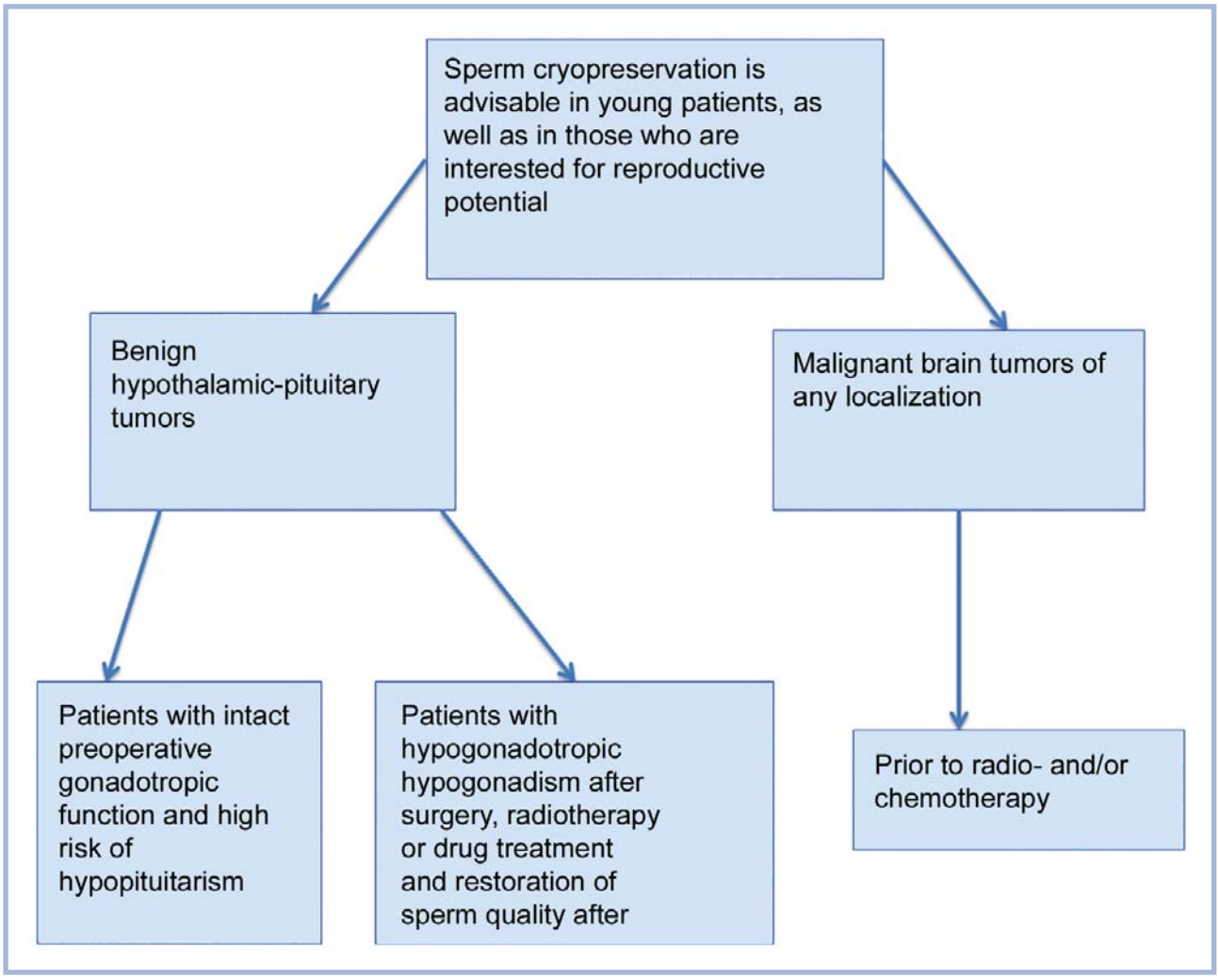

Algorithm for fertility preservation in men with brain tumors.

— with intact preoperative gonadotropic function and high risk of hypopituitarism (including hypogonadism);

— patients with hypogonadotropic hypogonadism after surgery, radiotherapy or drug treatment and restoration of sperm quality after gonadotropin therapy;

2) malignant brain tumors of any localization:

— prior to radio- and/or chemotherapy **(Figure).**

Preservation of fertility in men with benign and malignant brain tumors is a private, but urgent medical objective aimed at reduction of reproductive losses in these patients. It is necessary to develop the forms of informed consent of patients with proposal of cryopreservation if impaired fertility is supposed. It is advisable to conduct educational seminars for doctors whose specialties and possible methods of treatment are associated with the effect on fertility in men. Introduction of physician's responsibility as a "subject of law" for the preservation of male fertility is necessary.

Authors declare no conflict of interests.

REFERENCES

1. Ostrom QT, Gittleman H, Xu J, Kromer C, Wolinsky Y, Kruchko C, Barnholtz-Sloan JS.CBTRUS Statistical Report: Primary Brain and Other Central Nervous System Tumors Diagnosed in the United States in 2009—2013. *Neuro Oncol*. 2016 Oct 1;18(suppl_5):v1-v75. https://doi.org/10.1093/neuonc/now207
2. Lambertini M, Del Mastro L, Pescio MC, Andersen CY, Azim HA Jr, Peccatori FA, Costa M, Revelli A, Salvagno F, Gennari A, Ubaldi FM, La Sala GB, De Stefano C, Wallace WH, Partridge AH, Anserini P. Cancer and fertility preservation: international recommendations from an expert meeting. *BMC Med*. 2016 Jan 4;14:1. https://doi.org/10.1186/s12916-015-0545-7
3. Horne G, Atkinson AD, Pease EH, Logue JP, Brison DR, Lieberman BA. Live birth with sperm cryopreserved for 21 years prior to cancer treatment: Case report. *Hum Reprod*. 2004 Apr 22;19(6):1448-1449. https://doi.org/10.1093/humrep/deh249 PMID: 15163644
4. Feldschuh J, Brassel J, Durso N, Levine A. Successful sperm storage for 28 years. *Fertil Steril*. 2005 Oct;84(4):1017.e3-1017.e4. https://doi.org/10.1016/j.fertnstert.2005.05.015 PMID: 16213859
5. Ministerstvo zdravookhraneniya Rossiiskoi Federatsii. Prikaz Minzdrava Rossii №107n on 30.08.12 № 107n (red. on 11.06.15) «O poryadke ispol'zovaniya vspomogatel'nykh reproduktivnykh tekhnologii, protivopokazaniyakh i ogranicheniyakh k ikh primeneniyu». URL: http://www.consultant. ru/document/cons_doc_LAW_142595/
6. Bystrova OV, Kalugina AS, Tsybatova EV, Tapil'skaya NI, Dinikina YuV, Lisyanskaya AS, Manikhas GM. Sposoby vosstanovleniya fertil'nosti u onkologicheskikh bol'nykh. *Prakticheskaya onkologiya*. 2009;10:4(40):245-253. (In Russ.).
7. Makarova NP, Romanov AYu, Dus TA, Kalinina EA. Possibilities and problems of clinical embryology in IVF-patients with oncological diseases. *Prakticheskaya onkologiya*. 2017;18(3): 275-284. (In Russ.).
8. Sokhranenie fertil'nosti muzhchin. Pod red. Zhukova OB. M.: Spetsial'noe izdatel'stvo meditsinskikh knig. 2017. (In Russ.).
9. Dedov I, Rozhivanov R, Rozhinskaya L, Vorontsov A, Kurbatov D. Sexual function in men with functioning and nonfunctioning pituitary adenomas. *Vrach*. 2011;7:90-92. (In Russ.).
10. Cury ML, Fernandes JC, Machado HR, Elias LL, Moreira AC, Castro M. Non-functioning pituitary adenomas: clinical feature, laboratorial and imaging assessment, therapeutic management and outcome. *Arq Bras Endocrinol Metabol*. 2009;53(1):31-39.
11. Ferrante E, Ferraroni M, Castrignanò T, Menicatti L, Anagni M, Reimondo G, Del Monte P, Bernasconi D, Loli P, Faustini-Fustini M, Borretta G, Terzolo M, Losa M, Morabito A, Spada A, Beck-Peccoz P, Lania AG. Non- functioning pituitary adenoma database: a useful resource to improve the clinical management of pituitary tumors. *Eur J Endocrinol*. 2006;155(6):823-829. https://doi.org/10.1530/eje.1.02298
12. Giniyatullina EN, Dzeranova LK, Rozhinskaya LYa, Grigor'ev AYu. Reproduktivnye narusheniya pri giperprolaktinemii opukholevogo geneza u muzhchin (klinicheskie sluchai). *Vestnik reprod. zdorov'ya*. 2008;2:59-63. (In Russ.).
13. Astaf'eva LI, Kadashev BA, Kalinin PL, Kutin MA, Shkarubo AN, Fomichev DV, Faĭzullaev RB, Alekseev SN, Sidneva YuG, Tenedieva VD, Tropinskaya OF. Clinical presentation, diagnostics and results of primary conservative treatment of large and giant prolactin-secreting pituitary adenomas. *Zh Vopr Neirokhir Im NN. Burdenko*. 2008;(4):36-39; discussion 39. (In Russ.).
14. Rush S, Cooper PR. Symptom resolution, tumor control, and side effects following postoperative radiotherapy for pituitary macroadenomas. *Int J Radiat Oncol Biol Phys*. 1997 Mar 15;37(5):1031-1034.
15. Honegger J, Buchfelder M, Fahlbusch R. Surgical treatment of craniopharyngiomas: endocrinological results. *J Neurosurg*. 1999 Feb;90(2):251-257. https://doi.org/10.3171/jns.1999.90.2.0251
16. Klochkova IS, Astafieva LI, Konovalov AN, Kalinin PL, Kutin MA, Fomichev DV, Sharipov OI. Endocrine disorders with craniopharyngioma in adults before and after surgery. *Problems of endocrinology*. 2016;62(5):61-62. (In Russ.). https://doi.org/10.14341/probl201662561-62
17. Jungwirth A, Giwercman A, Tournaye H et al. European Association of Urology Working Group on Male Infertility. European Association of Urology guidelines on Male Infertility: the 2012 update. *Eur Urol*. 2012 Aug;62(2):324-332. https://doi.org/ 10.1016/j.eururo.2012.04.048
18. Shalitin S, Gal M, Goshen Y, et al. Endocrine outcome in long-term survivors of childhood brain tumors. *Horm Res Paediatr*. 2011;76(2):113-122. https://doi.org/ 10.1159/000327584
19. Constine LS, Woolf PD, Cann D, et al. Hypothalamic -pituitary dysfunction after radiation for brain tumors. *N Engl J Med*. 1993 Jan 14;328(2):87-94.
20. Agha A, Sherlock M, Brennan S, O'Connor SA, O'Sullivan E, Rogers B, Faul C, Rawluk D, Tormey W, Thompson CJ. Hypothalamic-pituitary dysfunction after irradiation of nonpituitary brain tumors in adults. *J Clin Endocrinol Metab*. 2005 Dec;90(12):6355-6360. https://doi.org/10.1210/jc.2005-1525
21. Gubernatorova EE, Pavlova MG, Melnichenko GA, Mazerkina NA, Sych YuP, Zheludkova OG, Tenedieva VD, Pogorelova AS, Kotlyarevskaya EYu. Endocrine and reproductive abnormalities in the men treated for medulloblastoma and acute lymphoblastic leukemia in the childhood. *Problems of endocrinology*. 2014;60(1):18-23. (In Russ.). https://doi.org/10.14341/probl201460118-23
22. Lee SJ, Schover LR, Partridge AH, Patrizio P, Wallace WH, Hagerty K, Beck LN, Brennan LV, Oktay K; American Society of Clinical Oncology; American Society of Clinical Oncology recommendations on fertility preservation in cancer patients. American Society of Clinical Oncology. *J Clin Oncol*. 2006 Jun 20;24(18):2917-2931. https://doi.org/10.1200/JCO.2006.06.5888
23. Oktay K, Harvey BE, Partridge AH, Quinn GP, Reinecke J, Taylor HS, Wallace WH, Wang ET, Loren AW. Fertility Preservation in Patients With Cancer: ASCO Clinical Practice Guideline Update. *J Clin Oncol*. 2018 Jul 1;36(19):1994-2001. https://doi.org/10.1200/JCO.2018.78.1914
24. Mueller BA, Chow EJ, Kamineni A et al. Pregnancy outcomes in female childhood and adolescent cancer survivors: a linked cancer-birth registry analysis. *Arch Pediatr Adolesc Med*. 2009 Oct;163(10):879-886. https://doi.org/10.1001/archpediatrics.2009.112

Received: 13.08.18

Commentary

The authors noted that neurosurgery for CNS tumors, mainly hypothalamic-pituitary neoplasms, as well as chemo- and radiotherapy for brain malignancies of any localization can cause hypogonadism and infertility. Cryopreservation of spermatozoa is currently a reliable method to preserve male fertility increasing the chance to have genetic progeny in the future. However, there are still no standards for interaction between oncologists and specialists for reproductive technologies. Therefore, this article is relevant. The authors described the causes of reproductive disorders in patients with benign hypothalamic-pituitary tumors. Moreover, they emphasized that high incidence of hypogonadism in patients with hypothalamic-pituitary tumors is accompanied by a significant deterioration of quality of life, sexual and reproductive potential in men. There are no clear literature data about the feasibility of sperm cryopreservation in patients with benign hypothalamic-pituitary tumors. The authors showed the advantages of sperm cryopreservation in contrast to long-term treatment with gonadotropins. An important aspect of the article is information about reproductive disorders in patients with brain malignancies. These disorders can develop either during treatment, immediately after it or in long-term period. The authors reported 3 clinical cases with different severity of reproductive disorders.

O.G. Zheludkova (Moscow, Russia)

Commentary

Socially significant problem of infertility in men with brain tumors is considered in the article. Infertility may be potentially followed by destruction of family, impairment of the quality of life, including significant emotional and personal disorders.

Patients with brain tumors usually appeal to a neurosurgeon. Neurosurgeon determines further tactics of diagnosis and treatment of a patient with brain tumor. Unfortunately, the majority of neurosurgeons do not always inform patients about possible reproductive disorders after removal of benign hypothalamic-pituitary tumors and during various modes of treatment of brain and spinal cord malignancies.

Currently, cryopreservation of ejaculate, oocytes and embryos is considered as a standard method of preserving fertility in general oncology.

Neurosurgeon and oncologist should discuss with the patient of reproductive age all methods of fertility preservation before neurosurgery, chemo- and radiotherapy. Patient should be referred to a specialist for reproductive technologies if it is necessary.

Three case reports of benign and malignant brain tumors in men are presented in the article. Treatment of tumors was complicated by infertility in all cases. Sperm cryopreservation was carried out in 2 cases. Therefore, 1 patient has become a father.

The article is extremely important and interesting because modern and relevant issue of preservation of reproductive function in men with brain tumors is discussed for the first time.

A.Kh. Bekyashev (Moscow, Russia)