doi: 10.17116/engneiro201680690-97

Use of Surgical Approaches to the Posterior Cranial Fossa in Patients in a Lying Position

V.N. SHIMANSKIY[1], V.V. KARNAUKHOV[1], S.V. TANYASHIN[1], V.K. POSHATAEV[1,2], K.V. SHEVCHENKO[1], D.A. ODAMANOV[1], S.V. KONDRAKHOV[2]

[1]Burdenko Neurosurgical Institute, Moscow, Russia; [2]Clinical Hospital №1 (Volynskaya) of the Presidential Administration of the Russian Federation, Moscow, Russia

Background. Various suboccipital approaches are extensively used in modern neurosurgery for treatment of posterior cranial fossa disorders. The main patient's positions on the operating table during surgery are the half-sitting and lying ones.
Material and Methods. The article provides a detailed description and the methodology of the suboccipital retrosigmoid and median suboccipital approaches in the lying position.
Conclusion. The suboccipital retrosigmoid and median suboccipital approaches in the lying position, when used correctly, provide a good view of the operating field with the minimal risk of complications associated with the patient's position on the operating table.

Keywords: suboccipital retrosigmoid approach, median suboccipital approach, posterior cranial fossa tumors, skull base surgery, skull base tumors.

Various suboccipital approaches are extensively used in modern neurosurgery to treat posterior cranial fossa (PCF) pathologies, such as skull base, cerebellar, and brainstem tumors, cranial nerve compression syndromes, and vascular disorders of the vertebrobasilar basin [1—8]. The main patient's positions on the operating table during surgery are the half-sitting and lying ones. Each of them has its own advantages and drawbacks. The half-sitting position ensures more adequate ventilation and provides good visualization of the anatomical structures of the posterior cranial fossa due to the natural passage of fluid from the surgical wound under gravity. Meanwhile, this position is associated with a high risk of air embolism and hemodynamic disorders caused by shifting patient's positioning (orthostatic hypotension), as well as results in pneumocephalus and other complications. Air embolism is the key life-threatening complication associated with the semi-sitting position. It can result in severe cardiovascular disorders, ischemic injury to cardiac muscle and brain. These complications can be almost entirely prevented if using the horizontal position [9]. This circumstance makes many surgeons avoid using the semi-sitting position for posterior cranial fossa surgeries. We provide a detailed description and illustration to the methodology of the main surgical approaches to the PCF structures in the lying position.

Materials and Methods

More than 450 surgeries for PCF pathologies are performed annually at the Department of Peri-brainstem Tumors (Burdenko Neurosurgical Institute). The main approaches used are the suboccipital retrosigmoid and the median suboccipital approaches.

The suboccipital retrosigmoid approach (SRSA) has been used by neurosurgeons for more than 100 years [1].

It is currently employed in surgeries of the following PCF pathologies:

— tumors of the base of the PCF: neurinomas of cranial nerves (auditory, germinal, and facial nerves and the nerves passing in the jugular foramen area), meningiomas, chordomas, etc.

— epidermoid cysts (cholesteatomas) of the posterior fossa cisterns;

— syndromes of cranial nerve hyperfunction: trigeminal and glossopharyngeal neuralgia, hemifacial spasm, positional vertigo (the neurovascular conflict of the vestibulocochlear nerve);

— tumors of the brainstem and cerebellar hemispheres;

— vascular disorders of the vertebrobasilar basin.

For the lying position, a patient is placed in either supine or lateral position.

Positioning the patient on the operating table in the supine position. A surgeon, a surgeon's assistant, and an anesthetist are engaged in positioning the patient. The anesthetized and intubated patient is lying in the supine position, with his/her head secured with a head rest. While the anesthetist slightly raises the patient off his/her position, the surgeon's assistant places a roll under the patient's ipsilateral shoulder, trunk, and the gluteal region, thus ensuring a 30° angle. The surgeon rotates the patient's head towards the trunk bending (**Fig. 1a, b**). The assistant places a support into the ipsilateral shoulder to prevent the patient from sliding as his/her position may be corrected during the surgery by tilting the operating table (**see Fig. 1a**). The anesthetist simultaneously bends the ipsilateral leg at knee and hip joints to an angle of 30° and rotates it inward.

© Group of authors, 2016

e-mail: shimava@nsi.ru

This ensures the required position of the body axis by compensating for spine rotation around its axis as a roll is placed. A foam pad is placed between the legs to prevent soft tissue atrophy. The arm is placed on the patient's chest ipsilaterally to the approach side. The surgeon and surgeon's assistant perform head fixation using the Mayfield skull clamp: while one of them holds the patient's head raised, the other one places the pins. Pin positioning is performed as follows: a single pin is ipsilaterally placed onto the frontal protuberance, while the paired ones are contralaterally positioned into the superior temporal line and the occipital bone above the asterion (**see Fig. 1a, b**). The pins are tightly secured in the outer table of skull; one should avoid placing the pins above thin regions of calvarial bones (above the frontal sinuses, mastoid air cells, and along the anterior margin of the temporal muscle). Pin position must provide an unencumbered view of the operative field and leave a possibility for bone skeletonization to a required extent.

The surgeon then rotates the patient's head secured with the Mayfield–Kees skull clamp 30 degrees towards the side contralateral to the pathological process and maximally bends it forward , leaving no less than the thickness of two transverse fingers between the patient's chin and chest. One needs to make sure that the sagittal suture is parallel to the floor (**see Fig. 1a, b**). This position of the head ensures the best view of the structures of the cerebellopontine angle. When rotating or bending the head, it is also important to maintain the longitudinal body axis (the line running through the *external occipital protuberance* and the apices of spinous processes of cervical vertebrae must be straight). Allowance should be made for the risk of compression of jugular veins associated with excessive head flexion, which is particularly topical in hypersthenic overweight patients having a short thick neck.

Description of the surgical approach. The SRSA is performed in the cervico-occipital region below the superior nuchal line. Blood is supplied to this region from the occipital and posterior auricular arteries. Blood outflows from the soft tissues of the occipital region via the veins accompanying the aforementioned arteries and draining into the external jugular vein. Soft tissues of the occipital region are innervated by the greater occipital nerve accompanying the occipital artery [1].

The mastoid notch and the line of transition of the occipital squama into the horizontal part are the landmarks for incision of the soft tissues. In SRSA, skin incision is often made parallel to the auricular concha, 1.5–2.5 cm posterior to the mastoid notch (**see Fig. 1d**). The upper one-third of the skin incision is made above the transverse sinus projection line. The border between the middle and the lower one-thirds of the incision runs at the level of the mastoid notch (**see Fig. 1d**).

Once skin and subcutaneous fat were dissected, muscles are transected at a point where they are attached to the superior nuchal line and the occipital plane. It is reasonable to perform the musclectomy stage using

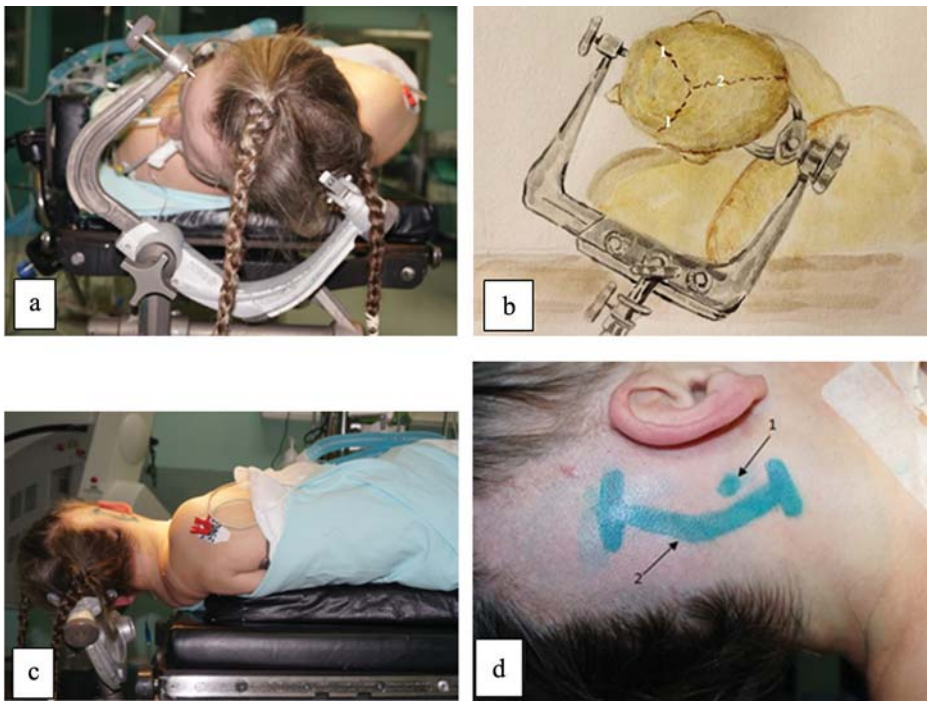

Fig. 1. **Suboccipital retrosigmoid approach in the supine position with a roller placed under the ipsilateral shoulder.**

a, b — positions of rigid fixation pins. The sagittal sinus is parallel to the operating room floor: 1 — the coronal suture; 2 — the sagittal suture; c — lateral view of the positions of the patient and the rigid fixation system. Landmarks for skin incision (d): 1 — mastoid notch, 2 — incision running parallel to the auricular concha.

monopolar coagulation, which allows one to significantly reduce capillary hemorrhage. The portion of the occipital bone, from the mastoid process to the median line in a medial direction (tentatively until the anticipated midpoint of the cerebellar hemisphere is reached) and from the superior nuchal line down to the foramen magnum, needs to be skeletonized.

When dissecting the soft tissues, one should not forget about the occipital artery whose injury causes profound bleeding. It is reasonable to begin with identifying the occipital artery in the soft tissues and to transect it only after precoagulation. Skeletonization of the occipital squama is typically accompanied by opening the emissaria located lateral and superior to the mastoid notch and, in the inferior regions, in the foramen magnum area. The opened emissaria need to be sealed with wax.

Asterion, the point where the lambdoid, the occipitomastoid, and the parietomastoid sutures meet, is a landmark for making the burr hole. Transition between the sigmoid sinus and the transverse sinus is located in the projection of this point (**Fig. 2a**). The asterion most typically lies 3—4 cm above the mastoid notch. The burr hole is made 5 mm below the asterion. After dura mater is separated from the bone around the burr hole, osteoplastic trepanation is performed using a pneumatic trephine (**see Fig. 2b**). In some cases, when there is significant coherence between the dura mater and the bone (which is often observed in patients older than 60 years), resection trepanation using bone-cutting forceps followed by closing the bone defect with a graft is performed.

Special care is needed when cutting the bone above or near the transverse and sigmoid sinuses, since injury to these structures causes profound venous bleeding. The injured sinus should be sealed with a hemostatic sponge or the TachoComb material by placing them on the surface of the injured sinus wall. By no way should the hemostatic agents be placed into the cavity of an opened sinus, since this may result in sinus thrombosis and severe neurological deficit or even death.

In order to prevent injury to venous sinuses, the bone should be cut 5 mm away from the tentative inferior border of the transverse sinus and 5 mm medial to the sigmoid sinus. The craniotomy is usually followed by additional lateral resection of the bone to expose the margin of the sigmoid sinus. Mastoid air cells often become opened as a result of additional resection of the lateral margin of the trepanation window. The disruption of their continuity may cause nasal liquorrhea during the postoperative period, which, in its turn, is associated with the risk of meningitis. Therefore, they need to be sealed with autotissue at the final stage of surgery. Adipose tissue harvested from the patient's hip or fragments of muscle tissue from the surgical wound on the neck can be used for this purpose. TachoComb material or fibrin sealant can be additionally used.

Most often, a trepanation window up to 4 cm in diameter is sufficient for managing cerebellopontine angle tumors. The borders of the trepanation window correspond to the following structures: the upper border, to the inferior margin of the transverse sinus; the lower border, to the line of transition from the vertical portion of the occipital bone to its horizontal portion; the lateral border, to the medial margin of the sigmoid sinus; and the medial border, to the midline of the cerebellar hemisphere [1]. Craniotomy size varies depending on the type of the pathological process;

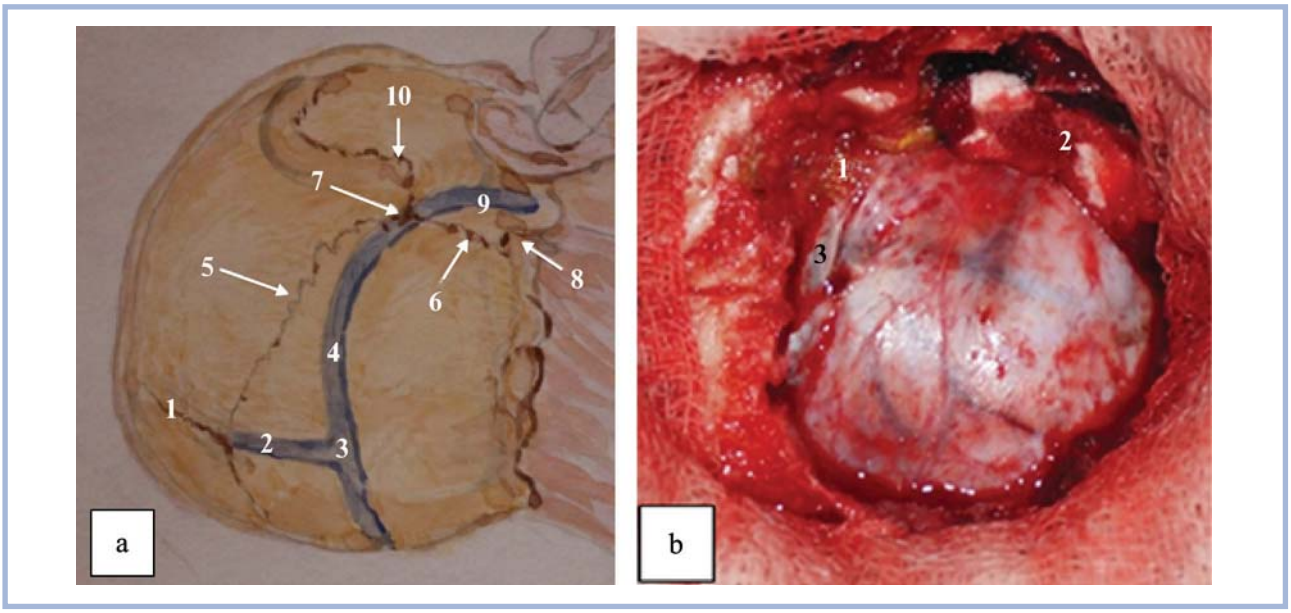

Fig. 2. **Right-sided suboccipital retrosigmoid approach.**

a — schematic view of the main landmarks in the occipital region: 1 — coronal suture, 2 —superior sagittal sinus, 3 — confluence of sinuses, 4 — transverse sinus, 5 — lambdoid suture, 6 — occipitomastoid suture, 7 — asterion, 8 — mastoid notch, 9 — sigmoid sinus, and 10 — parietomastoid suture; b — general right-side view of the craniotomy: 1 — transition from the transverse to the sigmoid sinus, 2 — projection of the sigmoid sinus (with a hemostatic sponge placed on it), and 3 — the inferior margin of the transverse sinus.

however, visualization of the site of transition of the sigmoid sinus to the transverse sinus is a prerequisite.

Lateral positioning on the operating table. The key indication for this positioning is the hypersthenic body habitus of a patient, namely, the short neck and broad shoulders.

After the patient had been intubated, a surgeon and surgeon's assistant roll him/her laterally onto one side contralateral to the surgery side; the anesthetist is simultaneously controlling the head position. Patient's arms are secured using specialized holders (**Fig. 3b, c**); the ipsilateral leg is bent at knee and hip joints to an angle of 30° and rotated inward. The surgeon's assistant places a support under the lumbar region. Soft pads are placed between the patient's legs and underarms to prevent soft tissue atrophy. Maximum head flexion is achieved similar to the position described previously; the distance between the chest and chin is supposed to be equal to at least two thicknesses of fingers in the transverse direction. The head is then secured by the surgeon using a Mayfield skull clamp (**see Fig. 3a**).

If needed, patient's shoulders can be stabilized using adhesive tape (**Fig. 4b**). One should not forget about the risk of stretch injury to the brachial plexus.

One should also bear in mind that the sagittal suture must be parallel to the floor (**see Fig. 3a**). This head position ensures the optimal approach angle for manipulations within the cerebellopontine angle during surgical intervention.

Description of the surgical approach

The landmarks for incision and the principles of performing craniotomy are similar to those used for supine positioning (**see Fig. 2**).

The median suboccipital approach. The key indications for using the median suboccipital approach are as follows:

— PCF neoplasms of median and craniovertebral localization, including tumors of the fourth ventricle and the brainstem;

— decompression of the craniovertebral junction in patients with Chiari malformation and acute circulatory failure in the brainstem; and

— vascular disorders of the vertebrobasilar basin.

Different positions on the operating table are used to perform the median suboccipital approach in lying patients are used: the prone and the three-quarter prone positions.

First, let us discuss the prone position, patient's position on the operating table that is used most frequently when performing this surgical approach.

Patient's position on the operating table. The patient is intubated and anesthetized while lying on a patient transport cart. Next, the surgeon and the surgeon's assistant rotate the patient into the prone position onto the operating table (the anesthetist is simultaneously controlling the head position).

The patient is usually placed by rolling onto a specialized foam frame, with its position controlled by a nurse anesthetist (**see Fig. 4a**). The foam frame ensures proper chest excursion during mechanical ventilation (see **Fig. 4a, 1**). Additional corrugated foam rollers or underpads are placed under the sites where the patient's body and limbs may be subjected to positional compression (**see Fig. 4a, 2**). An additional roller can be placed under patient's chest to ensure physiologically adjusted neck flexion. The head is then secured with a Mayfield skull clamp, with the longitudinal body axis strictly maintained. The skull clamp pins need to be positioned in such a manner as to ensure unencumbered view of the operating field and leave a possibility for skeletonizing the occipital bone to a required extent.

There are two modifications of the median suboccipital approach: the inferior and the superior median approaches (**see Fig. 4c, d**). The key difference is that both transverse sinuses and the confluence of sinuses are exposed when the superior median approach is performed (**see Fig. 4d**). The foramen magnum and the arch of the C1 vertebra are not affected by craniotomy performed through this modification of the approach. In the case of the inferior median approach, the upper border of trepanation runs along the inferior margin of both transverse sinuses and the confluence of sinuses until the foramen magnum, and is accompanied by laminotomy of the posterior semi-ring of C1 vertebra if necessary (**see Fig. 4c**).

The inferior median suboccipital approach is used most frequently.

Description of the surgical approach. Skin incision is made along the median line. It provides a minimally invasive access to the target PCF structures.

The upper border of the incision lies 1—2 cm above the external occipital protuberance (the inion); the lower border lies in the projected point of the spinous process of C3 vertebra (**Fig. 5, a**).

First, an incision of skin and subcutaneous fat is made. A wound retractor device is placed, with its handle facing upward. Dissection must be conducted along the cervical white line in the avascular zone. The occipital arteries and greater occipital nerves remain intact.

Once the soft tissues were prepared, the occipital bone squama, the posterior arch of C1 vertebra, and the spinous process of C2 vertebra are skeletonized. Deep cervical and occipital muscles are separated from the nuchal line using monopolar coagulation or a bone scraper and moved downward and sideways.

Venous bleeding from the hypertrophied emissaria may take place as the occipital bone squama is skeletonized. In this case, they need to be closed with bone wax. When skeletonizing the posterior semi-ring of C1 vertebra, one should keep in mind the close proximity of vertebral arteries that run in the posterior portion of the occipital membrane. Bleeding from the venous plexuses of vertebral arteries is stopped using hemostatic sponge.

Two burr holes are made below the inion, on both sides from the external occipital crest (**see Fig. 4c**). "Pear-shaped" craniotomy is then performed with a craniotome

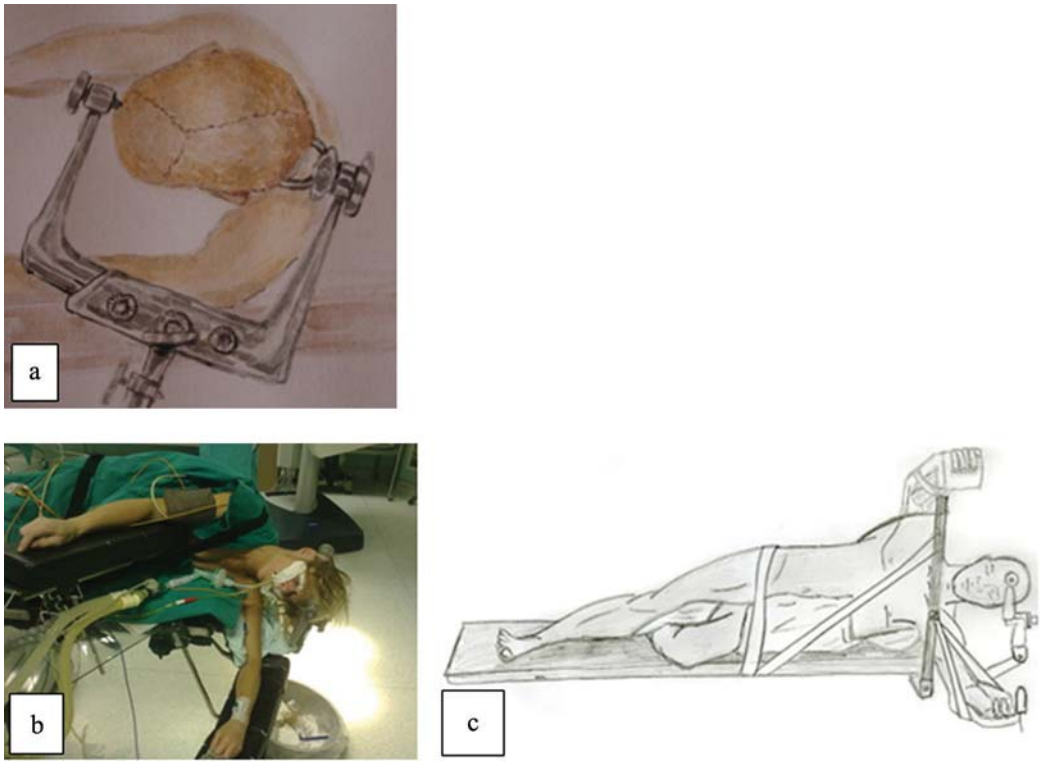

Fig. 3. **Suboccipital retrosigmoid approach in the lateral position.**
a — positioning of rigid fixation pins; b, c — patient's position on the operating table.

(see Fig. 4c). If needed, the trepanation window can be made wider: sideways to the maximum extent allowed by the operating field and to the required extent, and downward until the foramen magnum is reached. Sometimes craniotome cannot pass through thickening in the occipital bone near the margin of the foramen magnum. This bone portion can be ground with a burr or continue trepanation downwards and sideways using bone-cutting forceps.

This approach can be either combined with laminotomy of the posterior semi-ring of C1 vertebra **(see Fig. 5b)** or performed individually. Indications for laminotomy of the arch of C1 vertebra are determined by pathology location, the degree of descent of the cerebellar tonsils and, therefore, by the need to decompress the craniovertebral junction and CPF structures. If decompression of the craniovertebral junction is not required, the posterior semi-ring of C1 vertebra is returned to its original place and tightly secured with silk sutures. The borders of laminotomy of the C1 cervical vertebra lie no further than 1.5 cm sideways from the median line; i.e., its full absolute size is no more than 3 mm **(see Fig. 5b)** due to the close proximity of vertebral arteries and the risk of damaging them upon bone manipulation.

When performing the median suboccipital surgical approach to a patient in the three-quarter prone position, he/she is rolled sideways into the lateral position; the patient's body is inclined by approximately 45 degrees. Supports preventing trunk shifting with respect to the operating table are placed at the level of the chest and lumbar area. Patient's arms are secured with special supports; the ipsilateral leg is bent at knee and hip joints to an angle of 30° and rotated inward. Soft pads are placed between the legs and in the underarm area to prevent the development of soft tissue atrophy. The head is bent to a maximum possible extent and then secured using a Mayfield skull clamp **(see Fig. 4b)**. Taking into account the manipulation angle required to access the anatomical structures of the fourth ventricular area and the craniovertebral junction, no additional rotation of the patient's head is required **(see Fig. 4b)**.

Discussion

When choosing patient's position on the operating table and performing the suboccipital approaches, a number of questions may arise pertaining to the risks for a patient, which are related only to his/her position rather than to the existing neurosurgical pathology. Having evaluated the experience of performing suboccipital approaches to the patient in the lying and semi-sitting positions that has been gained over the many years, we have arrived at conclusion that performing these approaches to the patient in the lying position is the most safe procedure, since it allows one to avoid such life-threatening complication as air embolism. An analysis of 200 vascular decompression procedures performed in patients in different positions demonstrates that the semi-

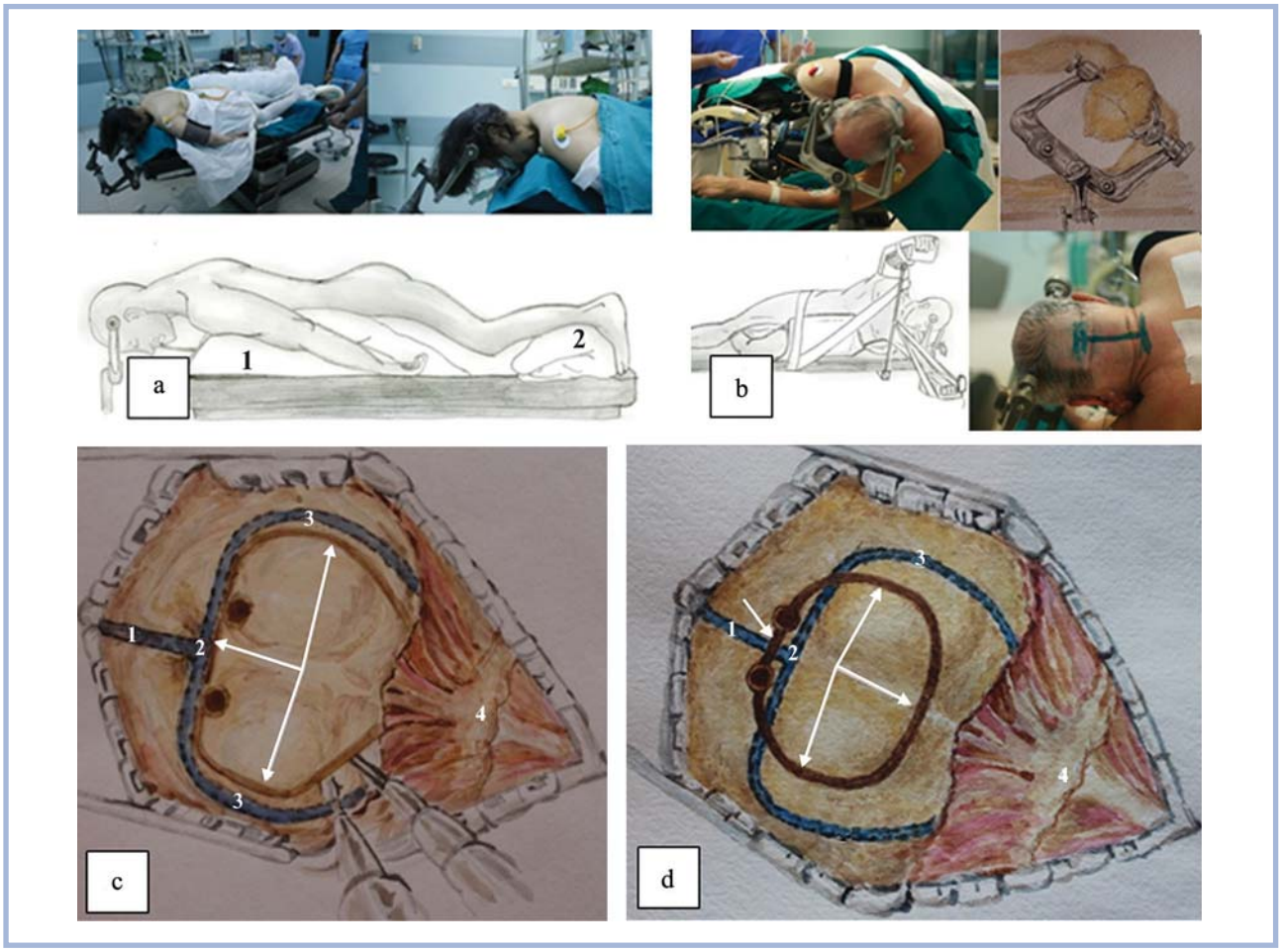

Fig. 4. **The lying position for performing the suboccipital median approach.**

a — prone position (Concorde position); b — three-quarter prone position; c, d — the modified median suboccipital approach; c — the inferior median suboccipital approach. The arrows show the craniotomy borders: 1 — the sagittal sinus, 2 — the confluence of sinuses, 3 — the sigmoid sinus, 4 — C1 vertebral arch, d — superior median suboccipital approach. The arrows show the craniotomy borders. The remaining notation is identical to that in Fig. 4c.

sitting position increases the risk of air embolism 25-fold [9]. Nevertheless, it is reasonable to use the suboccipital approaches in some patients in the semi-sitting position using intraoperative transesophageal Doppler to control possible development of air embolism. This category includes obese patients (in whom the lying position blocks chest excursion), patients with giant-size tumors and cervical osteochondrosis that prevents adequate head rotation and/or flexion.

The use of the "lying" position makes it necessary to accurately follow the landmarks when making a skin incision and osteoplastic trepanation, since a deviation from the trepanation performing standards narrow the operating field and make the main surgical stage infeasible. In its turn, this fact discredits the idea of using the lying position that is safe if performed properly. Hence, when using the suboccipital retrosigmoid approach, proper mapping of the operating field ensures patient's safety.

The methods for sealing sinuses if damaged during a surgery are often of concern. If a sinus was injured in the "semi-sitting position", one should prevent the contact between the sinus defect and air by all means, since the sinus defect will become a source of air embolism in this case. In this situation, a surgeon's assistant or a nurse must continuously irrigate the sinus defect with normal saline and subsequently seal its wall using a hemostatic sponge or TachoComb.

Furthermore, a frequent question often is "what type of trepanation should be performed, the resection or the osteoplastic one?" When using the suboccipital retrosigmoid approach, one should always prefer the osteoplastic craniotomy. However, if pronounced cohesion between the dura mater and the bone (especially in elderly patients) is detected when a burr hole is drilled, resection trepanation can be performed to avoid the emergence of defects in the dura mater and sinuses; the bone defect can be subsequently closed with a graft. Osteoplastic trepanation should be preferred when using the median suboccipital approach, excluding the cases when decompression of the PCF structures are needed, e.g., in surgeries for Chiari malformation [10].

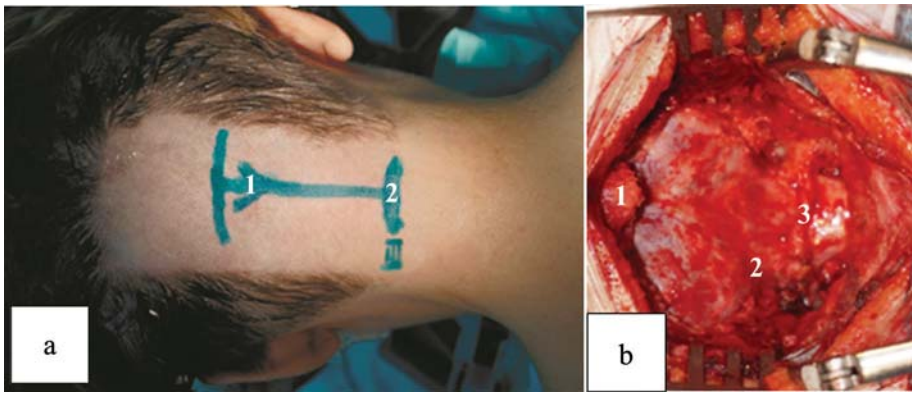

Fig. 5. **The inferior median approach.**

a — the landmarks for skin incision: 1 — the external occipital protuberance, 2 — the inferior incision line (the level of the spinous process of the C3 cervical vertebra); b — the final view of the inferior median suboccipital approach: 1 — the occipital bone and the C1 vertebral arch were resected, 2 — additional lateral resection of the occipital bone near the foramen magnum was performed using bone cutting forceps, and 3 — the anlantooccipital membrane is visualized.

Conclusion

When used properly, the suboccipital retrosigmoid and median suboccipital surgical approaches in the patient in a lying position provide a good view of the operating field, while leaving the risks of complications associated with the patient's position on the operating table minimal. A neurosurgeon must have a perfect command of these approaches. The proper use of the approaches ensures a broad view of the cerebellopontine angle and the craniovertebral junction area, while the traction of the cerebral tissue is minimal and usually causes no complications associated with their application.

Authors declare no conflict of interest.

REFERENCES

1. Makhmudov UB, Shimanskiy VN, Tanyashin SV, Murusidze NA. Suboccipital retrosigmoid approach. *Voprosy neirokhirurgii im. NN Burdenko*. 2001;3:25-28. (In Russ.).
2. Ribas GC, Rhoton ALJr, Cruz OR, Peace D. Suboccipital burr holes and craniectomies. *Neurosurgical Focus*. 2005;19(2):1-12.
   doi:10.3171/foc.2005.19.2.2
3. Rhoton ALJr. *Cranial Anatomy and Surgical Approaches*. Baltimore, MD: Lippincott Williams & Wilkins. 2003;525-587.
4. Sekhar LN, Fessler RG. *Atlas of neurosurgical techniques: brain*. New York—Sruttgart: Thieme Medical Publishing. 2006;860-870.
5. Shimanskiy VN, Karnaukhov VV, Odamanov DA, Kolycheva MV. Surgical treatment of trigeminal neuralgia in patients with multiple sclerosis. *Zhurnal nevrologii i psikhiatrii im. SS Korsakova*. 2015;2:66-70. (In Russ.).
6. Poshataev VK, Shimanskiy VN, Tanyashin SV, Karnaukhov VV. The use of endoscopic assistance in surgery of cerebellopontine angle tumors. *Voprosy neirokhirurgii im. NN Burdenko*. 2014;4:42-49. (In Russ.).
7. Shimanskiy VN, Karnaukhov VV, Sergienko TA, Poshataev VK, Semenov MS. Endoscopic assistance in vascular decompression of cranial nerves. *Voprosy neirokhirurii im. NN Burdenko*. 2012;2:3-10. (In Russ.).
8. Shimanskiy VN, Karnaukhov VV, Sergienko TA, Poshataev VK, Semenov MS. Endoscopic assistance in single-stage resection of posterior cranial fossa meningioma and vascular decompression of trigeminal nerve root. *Voprosy neirokhirurii im. NN Burdenko*. 2011;4:70-74. (In Russ.).
9. Israelyan LA, Shimanskiy VN, Otamanov DA, Poshataev VK, Lubnin AYu. Patient's position on the operating table in neurosurgery: the sitting or lying position. *Anesteziologiya i reanimatologiya*. 2013;4:18-26. (In Russ.).
10. Reutov AA. Principles of diagnosis and tactics of surgical management of patients with type I Chiari malformation [dissertation]. Moscow; 2012. (In Russ.). Accessed July 20, 2016.
    http://medical-diss.com/medicina/printsipy-diagnostiki-i-taktika-hirurgicheskogo-lecheniya-bolnyh-s-malformatsiey-kiari-i-tipa#ixzz4EvyZpoGT

Commentary

The article by V.N. Shimanskiy et al. is highly relevant, since the approaches being analyzed (the suboccipital retrosigmoid and the median suboccipital approaches) are most commonly used in surgical treatment of subtentorial pathological neoplasms. While being rather simple, these approaches ensure direct and the most convenient access to all the posterior cranial fossa structures. However, only the meticulous adherence to all the procedure nuances, starting from proper patient positioning, allows one to achieve the objectives of surgical management. It is the analysis of all miniscule details of the aforementioned approaches that makes this paper a thorough manual for using them in a patient in the lying position. The criteria for selecting the patients for whom these approaches are recommended were properly justified and clearly stated. The authors placed special focus on prevention of complications, in particular, postoperative liquorrhea. Numerous schemes and figures that meticulously demonstrate proper patient's position on the operating table as well as the features of skin incision and skull trepanation are provided in addition to description of the sequence of actions of an operating surgeon.

This work is important, especially for young neurosurgeons, since it teaches them how to perform a proper surgical approach, which, along with good microsurgical skills, is a prerequisite of successful surgery.

V.I. Smolanka (Uzhgorod, Russia)