doi: 10.17116/engneiro201680684-89

Infant Form of Alexander Disease (Clinical Case and Literature Review)

R.A. VASIN, M.A. KRASNIKOV, S.V. VASINA

Regional Children's Hospital, Lipetsk, Russia

We present a case of the infant form of Alexander disease. The case is unique because the patient's examination was started at the preclinical stage and continued during the manifestation and fastigium of the disease. We present rare images obtained during neurosonography at the preclinical stage of the disease as well as the unique findings of MRI studies. The MRI findings at disease onset and 3 years later indicate that the infant form of Alexander disease is characterized by clinical stages.

Keywords: Alexander disease, leukodystrophy, hydrocephalus.

Alexander's disease is a rare hereditary disease, characterized by progressive degeneration of white matter of the brain. The disease is caused by mutation in a gene, which encodes GFAP (glial fibrillar acidic protein) protein. Russo et al. (1976) distinguish three forms of the disease based on the time of its manifestation: infant form, which manifests at the age from 0 to 2 years, adolescent form, from 2 to 12 years, and adult form, after 12 years of age [1]. Some authors [2—4] also describe neonatal form. The infant form accounts for 63 to 80% of all cases [3, 5, 6].

Recently, another classification scheme has been gaining traction which is based on the localization of the lesion and clinical presentation. Prust et al. (2011) identify types I and II of the disease. Type I includes early forms with predominantly frontal leukodystrophy, while type II includes mainly cerebellar lesions and lesions of stem structures. The median survival for type I is 14 years, for type II, 25 years [1]. It is believed that the earlier the disease manifests, the more malignant is its course. This is especially true of the neonatal form [2, 3]. At the same time, some experts note unpredictable course of the disease at any age and do not consider age-based classification to be relevant [2].

S. Marjo van der Knaap et al. [7] offer five MRI criteria for establishing the diagnosis of Alexander's disease:

- extensive changes in the white matter of the cerebral hemispheres, mainly in the frontal lobes;
- periventricular rim with high intensity T1 signal and low level of T2 signal;
- changes in basal ganglia and thalamus;
- damage to the brainstem;
- increase the contrast of gray and white matter.

Four of the five criteria are sufficient for the diagnosis [7].

Some patients develop hydrocephalus due to compression of the Sylvian aqueduct; therefore these patients require neurosurgical intervention [1—3, 8].

Clinical observation

We present the clinical case of the girl *T.*, who first came to the attention of neurologists and neurosurgeons at the age of 2 months.

The child was from the first pregnancy, with urgent delivery at 42 weeks, which proceeded on its own, without complications. Body weight at birth, 3310 g, height, 53 cm. No anomalies were observed before the age of 2 months, the child grew and developed normally. At the age of 2 months, preventive neurosonography (NSG) was prescribed. At the time of the examination, the mother had no complaints, noting only minor episodes of the child's anxiety.

The results of the NSG are shown in **Fig. 1.** Frontal standard projection. The arrows indicate cloudy hyperechoic zones in the periventricular sections of the anterior horns of the lateral ventricles. The ventricular system is not enlarged. There is a narrowing of the anterior horns of the lateral ventricles at the point of contact with areas of increased echogenicity due to mass effect of pathological foci.

Given the unusual nature of the NSG findings, were in-hospital examination to clarify the diagnosis was proposed to the parents. On June 28, 2011 the baby was admitted to the nursing department. The NSG data were regarded as possible ischemic lesion of the natal period or expansive process. The child's state drastically deteriorated in the hospital: she lost ability to hold her head, there were choreoid movements in the facial musculature and athetoid movements in the distal parts of the limbs, she suffered from expressed anxiety attacks. On July 07, 2011 magnetic resonance imaging (MRI) of the brain without contrast and with contrast enhancement by Magnevist was performed. The results are shown in **Fig. 2** and **3**.

In general, focal changes identified by MRI coincided with those identified by NSG. A focus in the quadrigeminal plate area is clearly visible. The beginning of

© Group of authors, 2016

e-mail: vasinlodb@yandex.ru



Fig.1 **Patient *T.* NSG at the age of 2 months.**

ventriculomegaly can already be clearly seen from these pictures. The mass effect of pathological foci on the anterior horns of the lateral ventricles is observed and its lumen is practically invisible.

From July 26, 2011 there was further worsening of the condition in the form of increase in anxiety, vomiting and fits of "fading". According to the NSG, there is a progressive expansion of the ventricular system. On July 27, 2011, ventriculoperitoneostomy was performed. The surgery had certain features dictated by the disease: due to the narrowing of the anterior horns of the lateral ventricles, caused by mass effect of the pathological foci, it was decided to perform ventriculostomy not from the Kocher point but through the horn (Dandy point) by moving a catheter beyond the vascular plexus using ultrasound control. Improvement was noted in the postoperative period. General cerebral symptoms regressed, hyperkinesis decreased. Genetic analysis (genetic laboratory of the Russian Children's Clinical Hospital, Moscow) revealed a mutation

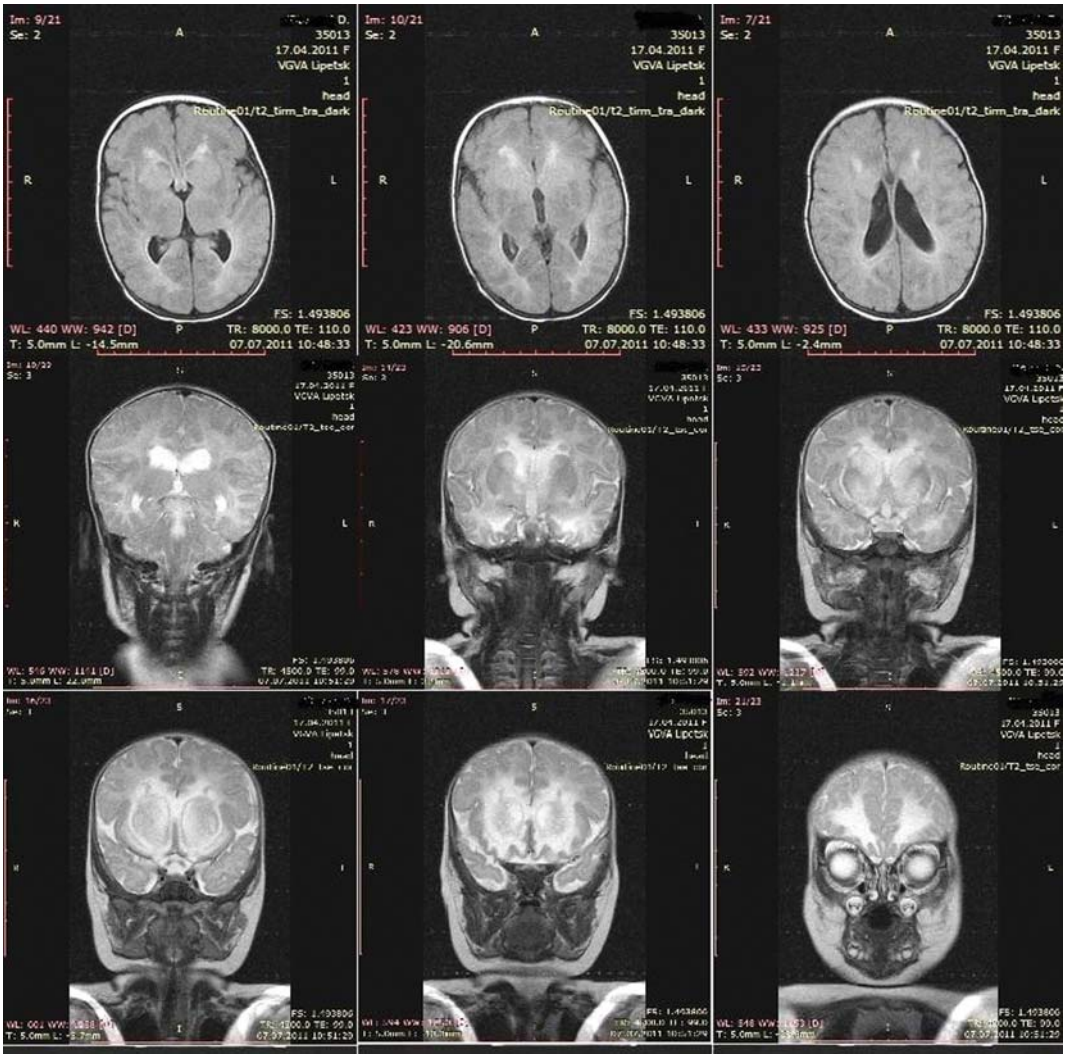

Fig. 2. **Patient *T.*, age 2.5 months. MRI of the head without contrast enhancement in T1 and T2-modes. The primary lesion of the white matter of the frontal lobes with the involvement of the subcortical ganglia is visible. There is a moderate expansion of the lateral ventricles.**

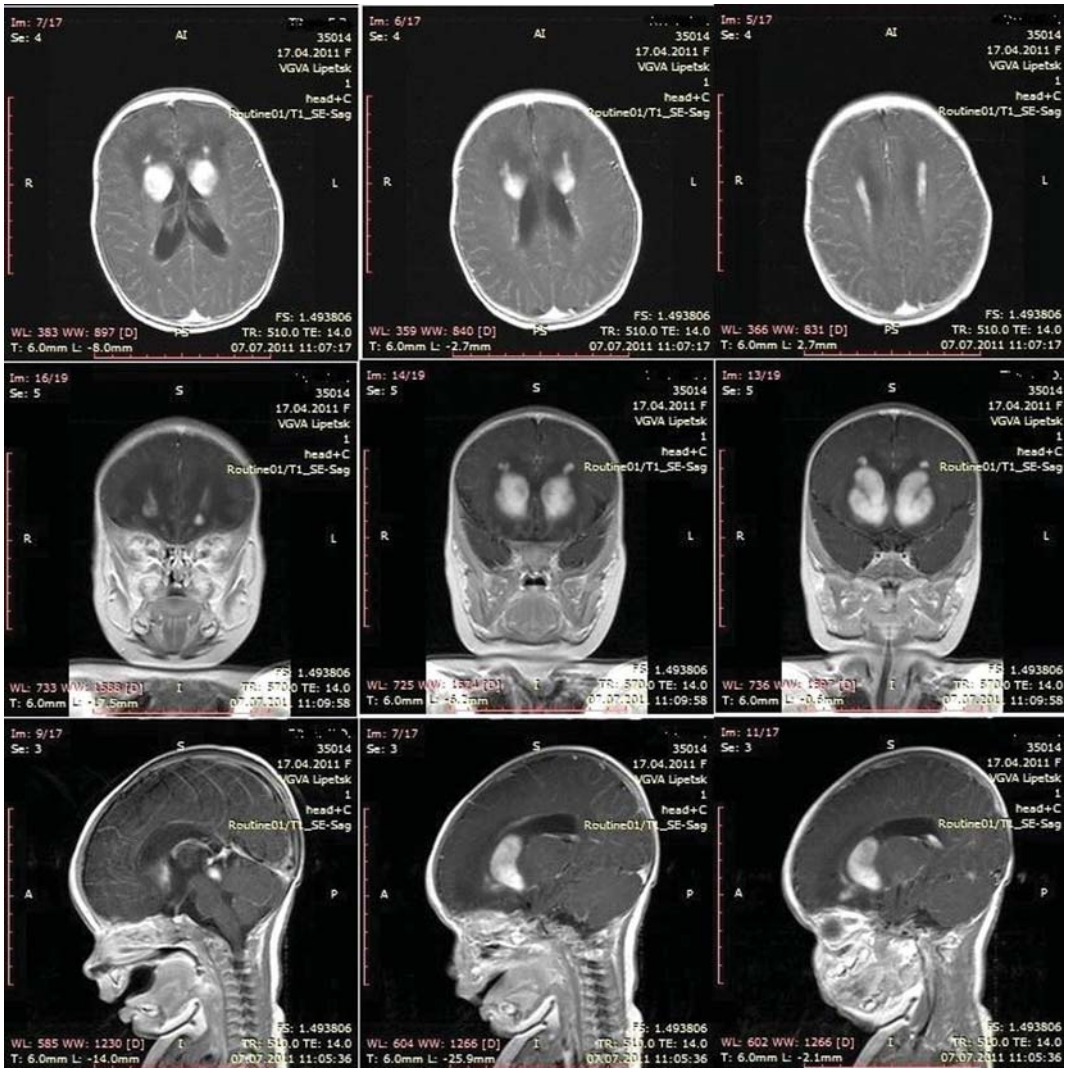

Fig. 3. **Patient *T.*, age 2.5 months. MRI of the head with contrast enhancement. Symmetrical accumulation of contrast in the frontal lobes, visual cusps and quadrigeminal plate.**

c1117C>a(pClu373Lys) in the gene GFAP (Alexander's disease), which is described in the mutation database (cm023075) in the heterozygous state.

Later the child was observed by a neurologist and received anticonvulsant therapy. A repeated in-depth examination was conducted at the age of 3 years. The general condition of the child was regarded as satisfactory. There was marked delay in psychomotor development. The child experienced epileptic seizures 1—2 times a week in the form of a short-term "fading". At the time of the examination the child was sane, had speech at the level of babbling, reacted to the examination positively, could 'fixate' the eyesight, was interested in toys, took them in hands and examined them for long time, sat without support, did not walk. Exotropia. Choreoid-like movements in the extremities. Pronounced muscular hypotension.

MRI without contrast and with contrast enhancement was performed. The results are shown in **Fig. 4**.

Discussion

This case is interesting in several aspects. Since the first description of the disease back in 1949 and until 2011, there were less than 100 described cases, and only ca. 50 of them were described with the use of modern neuroimaging. In 2011, S.V. Serkov et al. [8] described two cases of juvenile form of the disease for the first time in Russia. Our case, perhaps, is the third case identified in the Russian Federation.

We had a rare opportunity to obtain neuroimaging of Alexander disease using NSG at the preclinical stage. It should be noted that such NSG findings are difficult to interpret, but they can point the clinician in the right

a

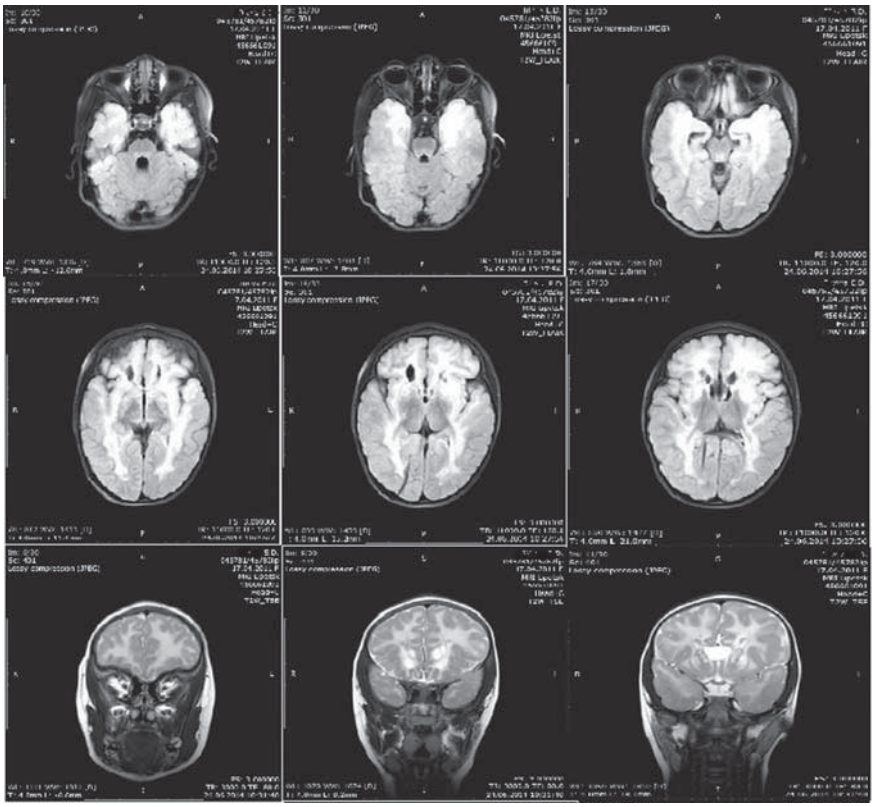

b

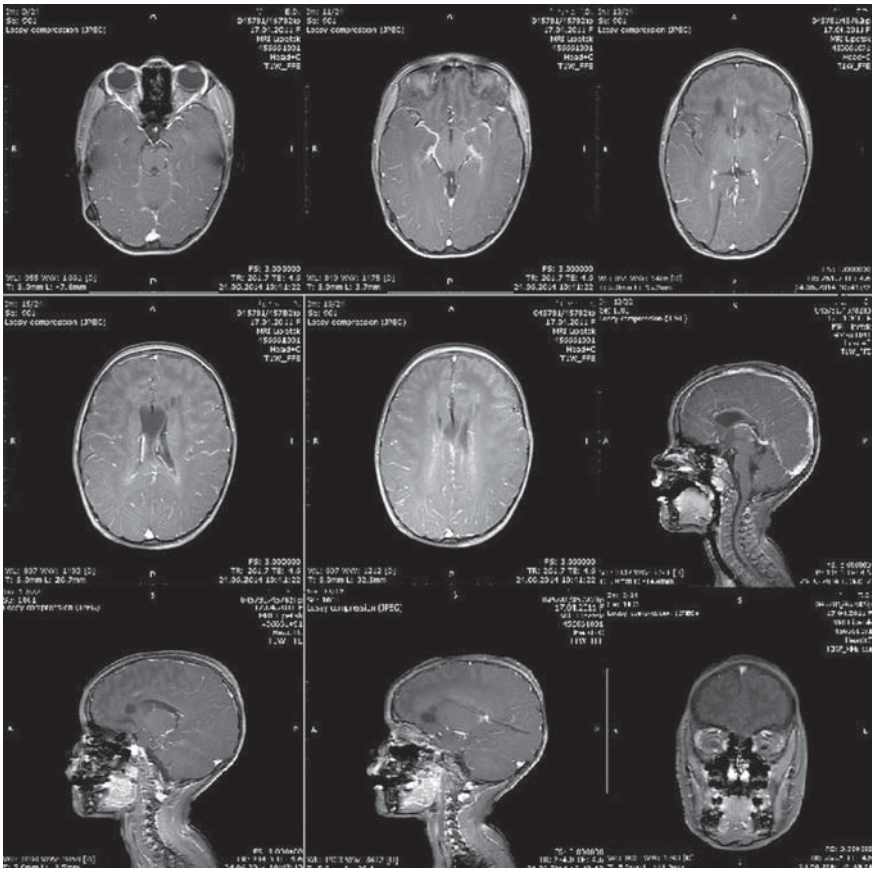

Fig. 4. **Patient *T.*, age 3 years 2 months. MRI of the head. The condition after ventriculo-peritoneal bypass (VPS).**

a — MRI without contrast. The affected zones retain the former localization, but are less extensive. There are no indications of mass effect of pathological foci. The luminaire of the anterior horns is visible together with the cavity of the transparent septum; b — MRI of the brain with contrast. There are not foci of contrast accumulation.

direction. Localization of foci in the frontal lobes with spreading into the visual cups and their mass effect is probably pathognomonic for Alexander's disease. We have not found similar neurosonographic findings in the literature.

The second important observation is the data obtained with MRI with contrast enhancement. The nature of the accumulation of contrast and the period of the disease in which this accumulation occurs are important. Intense accumulation of the contrast was recorded in the lesions at the onset of clinical symptoms. In addition to the intensity of contrast accumulation, the symmetry of the foci is also notable. Another feature is the lack of accumulation 3 years after the manifestation of the disease during the stabilization period. It can be assumed that the accumulation of contrast in the leukodystrophy foci is typical for onset and height of the disease, and that the period of remission can be characterized by the absence of such accumulation. In case of juvenile form of the disease described by S.V. Serkov et al. [8], the intensity of contrast accumulation was constant. The change in contrast accumulation observed in our case has not been described in the literature and may be characteristic of the infant form of the disease.

During the manifestation of the disease, MRI presentation fully complied with the criteria proposed by Marjo S. van der Knaap et al. [7], however, during the stabilization of clinical symptoms, no more than 3 out of the 5 described criteria were present.

The third important fact concerns the course of the infant form of the disease. The disease can last from several months to 8 years. The average duration of the disease is 2—3 years [8]. Our case demonstrates long period of stabilization. It can be assumed that timely shunt surgery in other cases can contribute to the stabilization of the patient's condition and the prolongation of his or her life.

Analysis of the described observations allows proposal that there are distinct stages of the infant form of Alexander's disease.

Conclusions

Focal changes detected in neurosonography in the form of hyperechoic cloud-like foci that spread from the periventricular sections of the anterior horn of the lateral ventricles to the basal ganglia can be specific for the infant form of Alexander's disease. Leukodystrophy foci in the period of onset and height of the disease present as mass process. Leukodystrophy foci identified during MRI examination can intensively accumulate contrast during the onset of the disease, and, on the contrary, do not accumulate contrast during the period of the absence of clinical manifestations, which may indicate the presence of at least two distinct stages of the disease.

The infant form of the disease does not always lead to a fatal outcome. At the same time, the severity of white matter lesions inevitably leads to disability of the patient. A timely shunt surgery is likely to prolong the life of these patients.

There is no conflict of interest.

REFERENCES

1. Messing A, Brenner M, Feany MB, Nedergaard M, Goldman JE. Alexander Disease. *The Journal of Neuroscience*. 2012 11 April;32(15):5017-5023.
   doi: 10.1523/JNEUROSCI.5384-11.2012
2. Springer S, Erlewein R, Naegele T, Becker I, Auer D, Grodd W, Krägeloh-Mann I. Alexander disease — classification revisited and isolation of a neonatal form. *Neuropediatrics*. 2000;31(2):86-92.
   doi:10.1055/s-2000-7479
3. Vazquez A, Macaya N, Mayolas S, Arevalo MA, Enrıquez PG. Alexander Disease: MR Imaging Prenatal Diagnosis. Case reporte. *AJNR Am J Neuroradiol*. 2008 Nov;29(10):1973-1975.
   doi: 10.3174/ajnr.A1215. Epub 2008 Jul 24
4. Ashrafi MR, Tavasoli A, Aryani O, Alizadeh H, Houshmand M. Alexander Disease: Report of Two Unrelated Infantile Form Cases, Identified by GFAP Mutation Analysis and Review of Literature; The First Report from Iran. *Iran J Pediatr*. 2013 Aug;23(4):481-484.
   PMID:24427505 [PubMed]
5. Kumar KJ, Suryaprakash H, Manjunath VG, Harsha S. Infantile Alexander disease: a rare leukodystrophy. *J Pediatr Neurosci*. 2012 May;7(2):117-119.
   doi: 10.4103/1817-1745.102573
6. Ozkaya H, Akcan AB, Aydemir G, Kul M, Aydinoz S, Karademir F, Suleymanoglu S. Juvenile Alexander disease: a case report. *Eurasian J Med*. 2012;44:46-50.
   doi: 10.5152/eajm.2012.10
7. Marjo S. van der Knaap, Sakkubai Naidu, Breiter SN, Blaser S, Stroink H, Springer S, Begeer JC, van Coster R, Barth PG, Thomas NH, Valk J, Powers JM. Alexander Disease: Diagnosis with MR Imaging. *AJNR Am J Neuroradiol*. 2001 Mar;22(3):541-552.
   PMID:11237983
8. Serkov S.V., Pronin I.N., Bembeeva R.S., Kornienko V.N. Alexander's Disease. Literature Review and Personal Observations. *Luchevaya diagnostika and terapiya*. 2011;4(2):17-32 (in Russ.).

Commentary

The work is devoted to a rare genetic disease. The observations are unique due to good neuroimaging of various stages of the development of the disease and rare data of neurosonography with the observed pathology. The literature review cited by the authors in the discussion is also interesting. Undoubtedly, the work is worthy of publication in the neurosurgical journal, as it broadens the horizons of neurosurgeons in terms of differential diagnosis. In addition, as the authors have shown, the presented disease sometimes requires neurosurgical interventions to alleviate the patient's condition.

Yu.V. Kushel (Moscow, Russia)