doi: 10.17116/engneiro201680679-83

Extradural Spinal Cord Hemangioblastoma (a Case Report and Literature Review)

N.A. KONOVALOV, L.V. SHISHKINA, D.S. ASYUTIN, R.A. ONOPRIENKO, V.A. KOROLISHIN, B.A. ZAKIROV, M.A. MARTYNOVA, I.U. CHERKIEV, A.L. POGOSYAN, S.YU. TIMONIN

Burdenko Neurosurgical Institute, Moscow, Russia

Hemangioblastoma is a rare CNS vascular tumor that develops sporadically and can also be associated with von Hippel—Lindau disease. Hemangioblastomas account for 2—6% of all spinal cord tumors and rank third in the structure of intramedullary space-occupying lesions of the spinal cord. For the first time in our practice, we observed a dumbbell paravertebral hemangioblastoma. The international literature reports only 3 cases of the tumor with this growth type.

Keywords: hemangioblastoma, von Hippel—Lindau disease, extradural dumbbell tumor.

Case report

Patient N., 56 years old, was admitted to the Burdenko Neurosurgical Institute on 03.09.14 with complaints of pain in the lumbosacral region irradiating to the left leg, as well as sensory disorders in the form of hypesthesia along the posterior surface of the left femur and tibia. The history showed that the patient suffered from back pain for a long time, pain gradually increased over time and became permanent. The patient repeatedly received drug therapy aimed at treatment of degenerative disc disease, which did not result in improvement. Since 2006, the pain intensified and occurred in the rest, sitting, and lying positions. In August 2013, the pain became very intense and conservative therapy still was ineffective. In this regard, MRI of the lumbosacral spine was carried out, which revealed extradural mass lesion having paravertebral spread at L4 —L5 into the intervertebral foramen on the left. The mass was oval-shaped, sized 16x25x10 mm. Spinal angiography with contrasting of tumor's own vascular network at the level of L4 vertebra was carried out (images are not shown). The patient was admitted to neurosurgical department at the place of residence for surgical treatment. The attempt of tumor resection was unsuccessful. Histological examination of resected fragment led to conclusion that it was ganglioneuroma.

Control MRI 12 months after surgery showed the same MR pattern as preoperative one (**Fig. 1**).

Resection of extradural paravertebral dumbbell tumor on the left at L4—L5 was carried out at the Burdenko Neurosurgical Institute on 11.09.14.

Operation

Patient's position on the operating table: prone position under a combination anesthesia with endotracheal ventilation. Tumor level was localized using O-arm intraoperative CT tomograph, images were taken in the lateral and frontal planes in 2D-mode.

Paramedian skin incision was performed a few centimeters to the left from the scar resulting from the previous surgery. Caspar surgical microscope and retractor system were used to approach the tumors. The use of this expander minimized trauma to surrounding tissues. Hemilaminectomy on the left at the level of L4 vertebral arch was carried out using microsurgical instruments and Zimmer high-speed bur. Orange elongated tumor sized 3x2 cm was observed. The tumor was located in the L4—L5 intervertebral foramen and was shaped similar to neurinoma. Extradural portion of the L4 root on the left was determined to be the growth origin. Major arterial vessel supplying the tumor was detected during tumor separation along its perimeter. It was coagulated and transected. Proximal part of the tumor and root were ligated and then the tumor and nerve root were coagulated and removed en bloc. Hemostatic material was placed to the bed of resected tumor (**Fig. 2**). The wound was closed using the standard scheme.

In the postoperative period, pain regression was observed. The patient was aroused on day 1 after the operation. After 7 days, the patient was discharged home in satisfactory condition. Histological diagnosis: hemangioblastoma. Follow-up MRI study was carried out 3 months after the operation (**Fig. 3**).

The histological characteristics of the tumor

Histological examination (**Fig. 4**) confirmed the microscopic diagnosis of hemangioblastoma. Tumor consisted of two types of cells: stromal cells with optically empty cytoplasm and a large number of vascular cells. The tumor was surrounded by a thin layer of fibrous tissue closely bordered by nervous tissue fragments and clusters of ganglion cells (**Fig. 5**).

During the study, adjacent nerve stem was discovered (**Fig. 6**); the same finding was reported by R. Pluta et al. [2].

Comparative analysis of the results of surgical treatment of hemangioblastomas

Spinal hemangioblastomas belong to the group of highly vascularized tumors, which are often characterized by intramedullary localization. Hemangioblastoma

© Group of authors 2016

e-mail: nkonovalov@nsi.ru

account for 2—6% of all spinal cord neoplasms and rank third in the structure of intramedullary space-occupying lesions of the spinal cord [1]. In our case, the tumor was paravertebral, dumbbell-shaped, and was not connected to the dura mater. In the international literature [2—4], we found three case reports describing patients with similar localization of a space-occupying mass. The Table shows some information about these patients, in particular, clinical status and results of surgical treatment (cases 1—3) and compares these data to the case descried in our study (case 4).

When evaluating data shown in the **Table**, it is clear that there were certain differences in the clinical presentation of the disease. Thus, case 3 was characterized by acute onset of the disease, where strong pain evolved within 2 weeks, followed by admission of the patient to neurosurgical hospital. In two other cases, (cases 1 and 2), as well as in our patient (case 4), there was a 2—20 years-long history. The tumor mainly manifested in the form of radiculopathy characterized by pain in the lumbosacral spine radiating to the leg, and also radicular sensory disorders. Dysfunction of pelvic organs (urinary incontinence) was observed in the case 3, possibly due to compression of the roots of "cauda equina".

The **Table** shows that preoperative clinical and X-ray examination suggested correct histological diagnosis

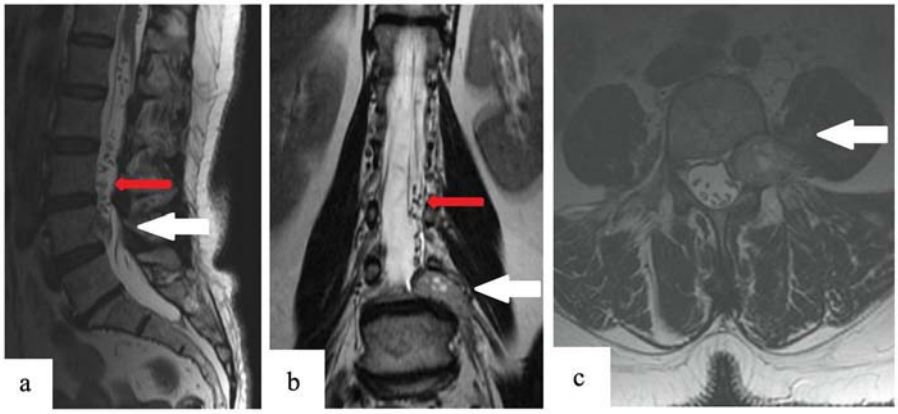

Fig. 1. **Hemangioblastoma of L4 root.**

The series of T2-weighed MRI scans in the sagittal, frontal and axial projections (a, b, c) shows extradural hypointense space-occupying mass at L4—L5 vertebrae characterized by hyperintense foci and dumbbell-shaped paravertebral growth to the left (the tumor is shown by white arrows). The sagittal and frontal views (a, b) show pronounced vasculature (indicated by red arrows), which corresponds to multiple areas of hypointense signal in T2-weighed mode.

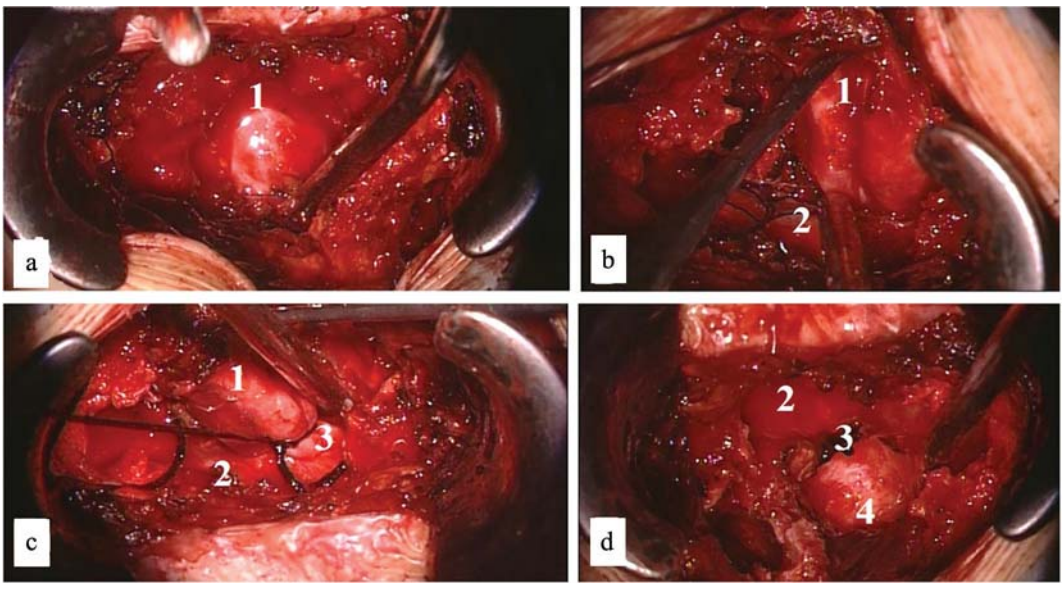

Fig. 2. **Operation stages.**

a, b — exposure and mobilization of the solid part of the tumor; c — ligation of the neck of the tumor of the L4 root; d — tumor resection along with the root. 1 — solid portion, 2 — L4 root, 3 — gaine radiculaire, 4 — tumor bed.

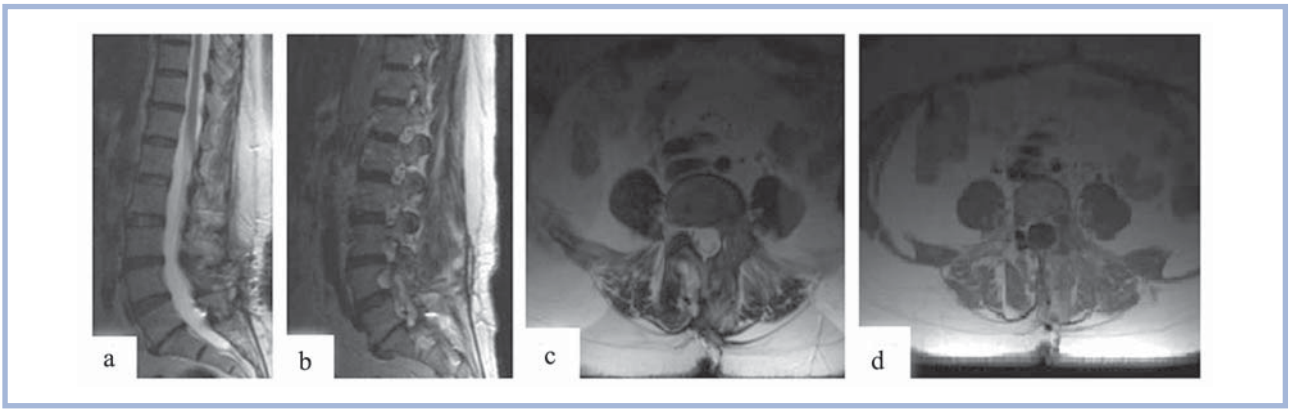

Fig. 3. **T2-weighed MRI, sagittal and axial views (a, b, c, d) after resection of hemangioblastoma.**

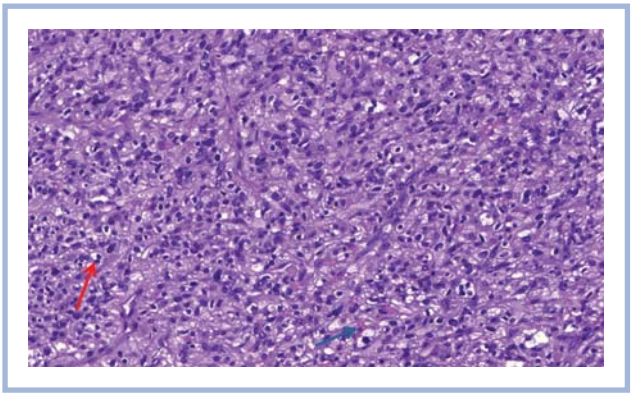

Fig. 4. **Hemangioblastoma. Stromal cells with optically empty cytoplasm (shown by red arrow) and vascular cells (shown by blue arrow).**
H & E stain, magnification x200.

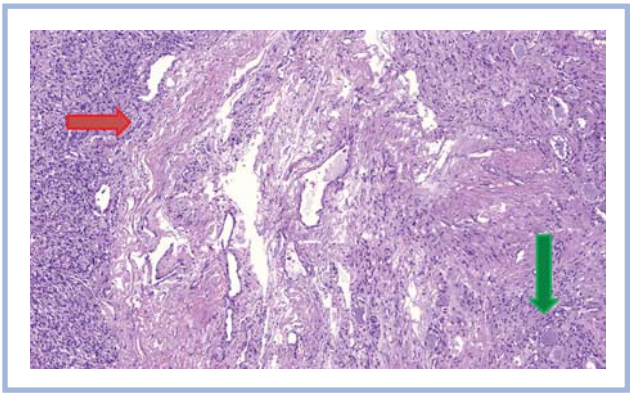

Fig. 5. **Hemangioblastoma (shown by red arrow) and clusters of ganglion cells (shown by green arrow).**
H & E stain, magnification x100.

only in one case (case 1) owing to the fact that this patient with von Hippel—Lindau disease was diagnosed with multiple CNS hemangioblastoma. In 2 cases (cases 2 and 3) preoperative MRI study led to a presumable diagnosis of radicular neurogenic tumor, neuroma (schwannoma). In our case (case 4), the tumor was considered as paravertebral ganglioneuroma of the L4 root, corresponding histological diagnosis was made after the first operation at the place of residence.

Our analysis of X-ray data led to the following conclusions. Firstly, the studies should be contrast-enhanced. Second, detection of pathologically dilated tortuous vessels within the spinal canal around the neoplasm is a pathognomonic sign of hemangioblastoma. The vessels are best visualized in T2-weighted mode. Thirdly, the solid component of the tumor has hypo-intensive or iso-intensive T1-weighed MR signal, and cystic cavities have T1- and T2-weighed signal similar to that of the CSF or brighter T2-weighed signal. At least one of the above MRI features suggests a vascular tumor, and in this connection selective angiography can be recommended [4, 5].

When evaluating the outcomes of surgical treatment, we should note that tumors were completely resected in all four cases (**see Table**). This was accompanied by regression of pain syndrome. Possible occurrence of minor neurological deficit should be considered as an inevitable consequence of the operation rather than a complication, since the tumor is most often removed together with the root, where it originates from.

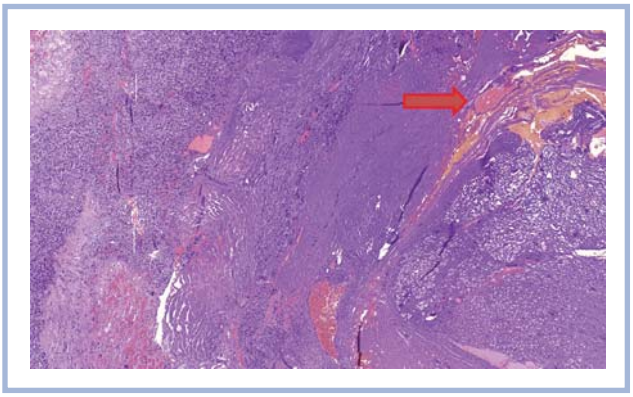

Fig. 6. **Hemangioblastoma and adjacent nerve stem (arrow).**
H & E stain, magnification x 50.

Review of publications on the surgical treatment of radicular hemangioblastoma of the spinal cord

Author and year of publication	Case No	Sex	Age (years)	Anamnesis morbi, months	Location	HL (Von Hippel–Lindau)	Presumable preoperative diagnosis	AG with emboli–zation	Clinical presentation	History, months	Treatment outcome
Ryszard M. Pluta, 2003	1	F	38	120	EL S1-S2 left	+	Hemangio-blastoma	+	RPS at S1—S2, SD	12	Regression RPS
Masaaki chazo NO, 1999	2	F	48	24	EL-DS L5 left	—	Neurogenous tumor (Neuro-fibroma, schwannoma)	–	MD, SD	12	Regression MD
María Román-de Aragón, 2014	3	M	48	1	EL-DS L4 right	—	Neuri-noma	+	PS, RPS, SD, DPO	36	Regression PS, RPS, SD, DPO
N.A. Konovalov, 2016	4	F	56	240	EL-DS L4 left	—	Para-ganglioma	—	PS, RPS	3	Regression PS, RPS

Footnotes. EL — extradural location, DS — dumbbell-shaped tumor, PS — pain syndrome, RPS — radicular pain syndrome, SD — sensory disorders, MD — motor disorders, DPO — dysfunction of pelvic organs.

Discussion

Extramedullary hemangioblastomas are a fairly rare pathology and there are no standards for their resection. Since the aforementioned case was the first case of extradural hemangioblastoma in our practice, we applied microsurgical resection technique similar to that used for resection of dumbbell tumors. Unfortunately, we did not embolized the vessel supplying the tumor, which resulted in bleeding from that vessel, the radicular artery, during separation of the paravertebral portion of the tumor, going beyond the intervertebral foramen. The bleeding was successfully stopped using bipolar coagulation.

As the second stage, we exposed tumor poles, while maintaining the dilated tumor draining veins, since we believe that it is a string requirement. Hemangioblastomas are well encapsulated and can be easily separated from the surrounding tissue. Manipulations inside the tumor capsule are dangerous since pronounced bleeding is possible, which is usually difficult to control and can completely obscure the entire field of view. Next, we exposed the part of the tumor adjacent to the dura; the root entering the tumor was ligated to prevent liquorrhea from the gaine radiculaire. In our case, hemangioblastoma could not be separated from the root because they were adhered to each other. Therefore, hemangioblastoma has been removed together with the L4 root. Despite the transection of the root, no negative symptoms in the form of increasing muscle weakness were observed in patient's left foot in the postoperative period. Tumor resection resulted in formation of a deep bed. We carefully examined the bed and suppressed hemorrhage from small blood vessels. In this situation, hemostasis should be carried out with hemostatic material without the use of bipolar coagulation.

Conclusions

Extradural hemangioblastoma is a very rare disease. However, in the cases, where MRI signs of a vascular tumor are detected, further examination in required, which may include CT perfusion study, as well as selective angiography, when necessary. In the case of hemangioblastoma with clearly differentiated supplying vessels, embolization is advisable to reduce the risk of intraoperative hemorrhage.

In our view, resection technique for extradural hemangioblastomas is similar to operations carried out for other tumors characterized by mostly paravertebral dumbbell growth.

There is no conflict of interest.

REFERENCES

1. Mehta GU, Asthagiri AR, Bakhtian KD, Auh S, Oldfield EH, Lonser RR. Functional outcome after resection of spinal cord hemangioblastomas associated with von Hippel—Lindau disease: Clinical article. *Journal of Neurosurgery Spine.* 2010;12(3):233-242.
2. Pluta RM, Wait SD, Butman JA, Leppig KA, Vortmeyer AO, Oldfield EH, Lonser RR. Sacral hemangioblastoma in a patient with von Hippel—Lindau disease: case report and review of the literature. *Neurosurgical focus.* 2003;15(2):1-4.
3. Chazono M, Shiba R, Funasaki H, Soshi S, Hattori A, Fujii K. Hemangioblastoma of the L-5 nerve root: Case illustration. *Journal of Neurosurgery Spine*. 1999;90(1):160-160.
4. Román-de Aragón M, Márquez T, Isla A, Gómez-de la Riva Á. Hemangioblastoma radicular extraforaminal de la raíz L4 derecha. *Neurocirugía*. 2014;25(6):286-289.
5. Kornienko VN, Pronin IN. *Diagnosticheskaya neiroradiologiya*. T 5;307-314.

Commentary

Hemangioblastoma is a highly vascularized benign tumor, consisting of clustered thin-walled vessels of various calibers, whose interstitial cells contain lipid-rich cytoplasm. In most cases, spinal hemangioblastomas are intramedullary and account for 2 to 8% of all intramedullary neoplasms, being exceeded in incidence only by ependymomas and astrocytomas. Spinal hemangioblastoma account for up to 20% of all CNS hemangioblastomas. In rare cases, these tumors can be extramedullary, and, in exceptional cases, even extradural. Despite the preferential location of the tumor within the central nervous system, no histological relationship between this tumor and glial tissue was found. This explains the fact that the disease occurs not only in the boundary zone between the central and peripheral part of the nervous system (intradural extramedullary hemangioblastomas are usually connected with the dorsal surface of the spinal cord or intradural portion of the posterior root), but also in the distant areas. The literature describes hemangioblastomas of radial and sciatic nerves.

Cases of extramedullary tumors are extremely rare, which complicates the choice of correct diagnosis and surgical treatment of this pathology.

In the present article, the authors describe the clinical presentation, diagnostic algorithm, and preoperative preparation of patients with extradural hemangioblastomas, taking into account available literature. Special attention is paid to the surgical techniques of tumor node resection.

The article is of great interest to a wide range of neurosurgeons.

G.Yu. Evzikov (Moscow, Russia)