doi: 10.17116/engneiro201680674-78

Extrapontine Myelinolysis Developed After Aneurysmal Subarachnoid Hemorrhage (a Case Report and Literature Review)

S.A. GOROSHCHENKO, A.YU. IVANOV, L.V. ROZHCHENKO, N.E. IVANOVA, YU.M. ZABRODSKAYA, O.YU. RAZMOLOGOVA, A.N. KONDRAT'EV, E.G. POTEMKINA, A.YU. DMITRIEVSKAYA, G.P. BLAGORAZUMOVA, S.D. RADZHABOV, A.E. PETROV, A.A. IVANOV, P.S. SINITSYN, V.V. BOBINOV

Polenov Russian Scientific Research Institute of Neurosurgery, the Branch of the Almazov Federal North-West Medical Research Centre, St. Petersburg, Russia

Topicality. Central pontine and extrapontine myelinolysis is a rare and dangerous form of the demyelinating process of unknown origin, the development of which is associated with abrupt changes in the serum sodium level (hypernatremia).
Objective — to describe a rare case of extrapontine myelinolysis complicating the hemorrhagic period of anterior communicating artery aneurysm rupture as well as to demonstrate the ability to intravitally diagnose this condition.
Conclusions. Clinical vigilance of extrapontine myelinolysis may promote the timely diagnosis and treatment of this disease that is a potential cause of death. Pulse-therapy with glucocorticoids alleviates neurological symptoms and stabilizes the patient's condition.

Keywords: hypernatremia, subarachnoid hemorrhage, extrapontine myelinolysis, glucocorticoids.

The paper is published to describe the development, diagnostic capabilities, and treatment of a rare life-threatening complication of subarachnoid hemorrhage.

Clinical case

A 58-year-old female patient was transferred to the Department of Cerebral Vascular Surgery of the Polenov Russian Scientific Research Institute of Neurosurgery (PRSRIN) from a city hospital on the 15th day after subarachnoid hemorrhage (SAH) from an anterior communicating artery (AComA) aneurysm. The patient was admitted with a WFNS grade 1 SAH. Neurological status: the patient had clear consciousness and cerebral symptoms with signs of intracranial hypertension and focal lesions of the frontal lobes. Spiral computed tomography (SCT) of the head revealed narrowing of the subarachnoid spaces in the right cerebral hemisphere. There was no hydrocepalus and deformity of the ventricles. The patient had a concomitant disease, rheumatoid polyarthritis, and constantly received 20 mg of methotrexate per week. Spiral computed tomographic angiography of the brain revealed a saccular aneurysm and diverticula of the AComA (**Fig. 1**).

The patient underwent urgent osteoplastic craniotomy and microsurgical clipping of the AComA aneurysm. In the postoperative period, there was no worsening of cerebral and focal symptoms. The patient received antibacterial, anti-edematous, and cerebroprotective therapy (medocef, nimotop, cytoflavin, mexidol). In a blood chemistry panel, the sodium level changed between 144—152 mmol/L; there were no other changes. On the 14th postoperative day, the patient's condition sharply deteriorated: the consciousness level worsened to profound obtundation with development of spastic tetraparesis of up to 1 point. A CT examination revealed signs of right hemisphere edema with a brain displacement of 7 mm to the left. Magnetic resonance imaging (MRI) of the brain detected multiple areas of a hyperintense T2-weighted image (T2-WI) signal, having clear contours in the area of the corpora quadrigemina, both cerebral peduncles, and oral pons (**Fig. 2**). A blood chemistry panel revealed hypernatremia of up to 170 mmol/L as well as elevated AST (58.5 U/L) and ALT (103 U/L) levels.

The patient's condition was assessed as the development of pontine and extrapontine myelinolysis. Pulse-therapy with glucocorticoids (solu-medrol for 3 days according to the schedule) provided a pronounced positive effect: recovery of the consciousness, partial restoration of limb movements (up to 4 points), and normalization of natremia. However, a week later (on day 28 of the postoperative period), negative changes again occurred in the patient's condition: bulbar symptoms, tetraplegia, and locked-in syndrome. An EEG examination revealed gross diffuse changes clearly predominating in the diencephalic brainstem structures. A blood test again detected hypernatremia (172 mmol/L). A cerebrospinal fluid test demonstrated a significant increase in the myelin basic protein level (460 ng/mL, with the normal level being less than 1 ng/mL) as well as a sharp increase in the anti-myelin-associated glycoprotein level (4,850 U/mL, with the normal level being 1000 U/mL); the S100 protein and neuron-specific enolase levels were not significantly increased. Repeated pulse-therapy with glucocorticoids had no significant effect. The patient's condition progressively worsened, multiple organ failure (bilateral pneumonia and renal, hepatic, and cardiovascular failure) deteriorated, which led to death of the patient.

Autopsy findings: the white matter of the brain was of a pale color, soft elastic in its texture, with bulging over

© Group of authors, 2016

e-mail: goroschenkos@gmail.com

the cut surface in the subcortical nuclei area and in the pons; the grey matter of the subcortical nuclei and thalami was of a heterogeneous color, with small yellowish foci (**Fig. 3**).

A histological examination of fragments of the subcortical nuclei, thalami, and white matter of the hemispheres as well as a cross-section of the pons, staining with hematoxylin and eosin, and Nissl (for detection of the Nissl substance in neurons) and Spielmeyer (for myelin) staining were performed. In all the examined fragments, diffuse foci of complete demyelination were detected; edema in the form of a spongy transformation of the white matter was present in the perifocal area of the foci (**Fig. 4**).

In the demyelination foci, there was destruction of the brain tissue, disintegration of neuropils, neuronal shrinkage, the presence of eosinophilic bodies, moderate gliosis with the microglial response, and swollen oligodendrocytes (**Fig. 5**).

Neurons in these foci had dystrophic changes: pericellular edema, moderate neuronophagia, foci of neuronal dropout, and granular disintegration of the Nissl substance (**Fig. 6**).

Therefore, the patient had diffuse microfocal demyelination in the white matter of the hemispheres and brainstem.

Discussion

Central pontine myelinolysis (CPM) was first described by R. Adams et al. [1] (1959) in a patient with chronic alcoholism, which was defined as osmotic demyelination syndrome. Later, CPM was detected in patients with diabetes mellitus, systemic lupus erythematosus, renal failure, pituitary adenoma, and cerebellar astrocytoma [2, 3]. The development of CPM after liver transplantation was reported. As it was demonstrated in an experimental model of CPM in rats, rapid administration of hypertonic saline (rapid hypernatremia) resulted in extracellular edema of the brain, provoking swelling of oligodendrocytes and destruction of the myelin sheath [4]. Damage to the myelin sheath can develop not only in the pons but also in other brain structures, both in combination with CPM and alone [5]. These disorders were called extrapontine myelinolysis (EPM); in this case, demyelination foci can occur in the brain peduncles, thalamus, corpus callosum, geniculate bodies, and other brain structures [5]. Pontine and extrapontine myelinolysis may be caused by other hyperosmolar states [6].

The pathogenesis of this rare demyelinating process has not been sufficiently studied. Currently, its development is believed to be associated with a sharp disturbance of the electrolyte (sodium) balance and blood osmolarity [3, 6].

The major regulator of electrolyte metabolism in the body is the hypothalamus. Studies of researchers guided by Prof. M.V. Ugryumov (neurohistological, neurohistochemical, and ultrastructural studies) at the PRSRIN proved involvement of the hypothalamus in the genesis of the degenerative-dystrophic process in the nervous system and internal organs [7, 8]. The development of the pathological process may involve decreased functional activity of the hypothalamic neurosecretory centers, which leads to deficiency of viscerotropic peptide neurohormones in the general circulation. The hormones maintain homeostasis, change permeability of biological membranes, and affect various aspects of metabolism, which, in turn, may cause gross disturbances of electrolyte metabolism (hypo- and hypernatremia).

The clinical picture of myelinolysis includes spastic tetraparesis, pseudobulbar palsy and mental disorders [9],

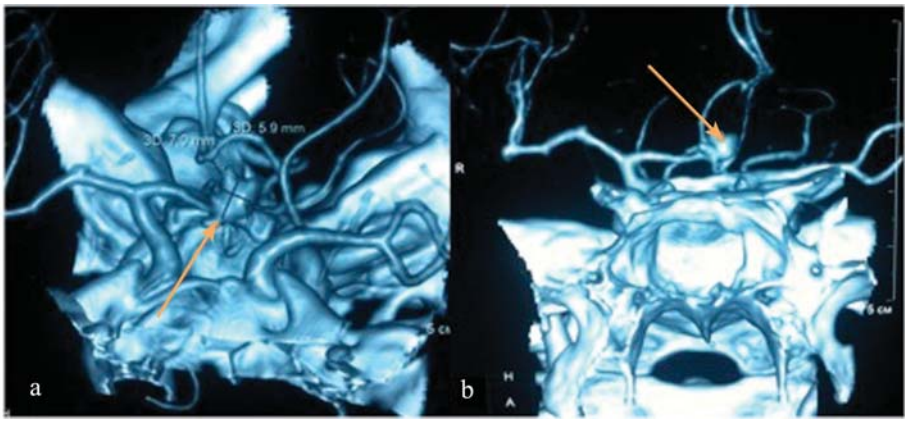

Fig. 1. **SCT angiography of the brain.**

a, b — a ruptured saccular aneurysm of the AComA (indicated by arrows).

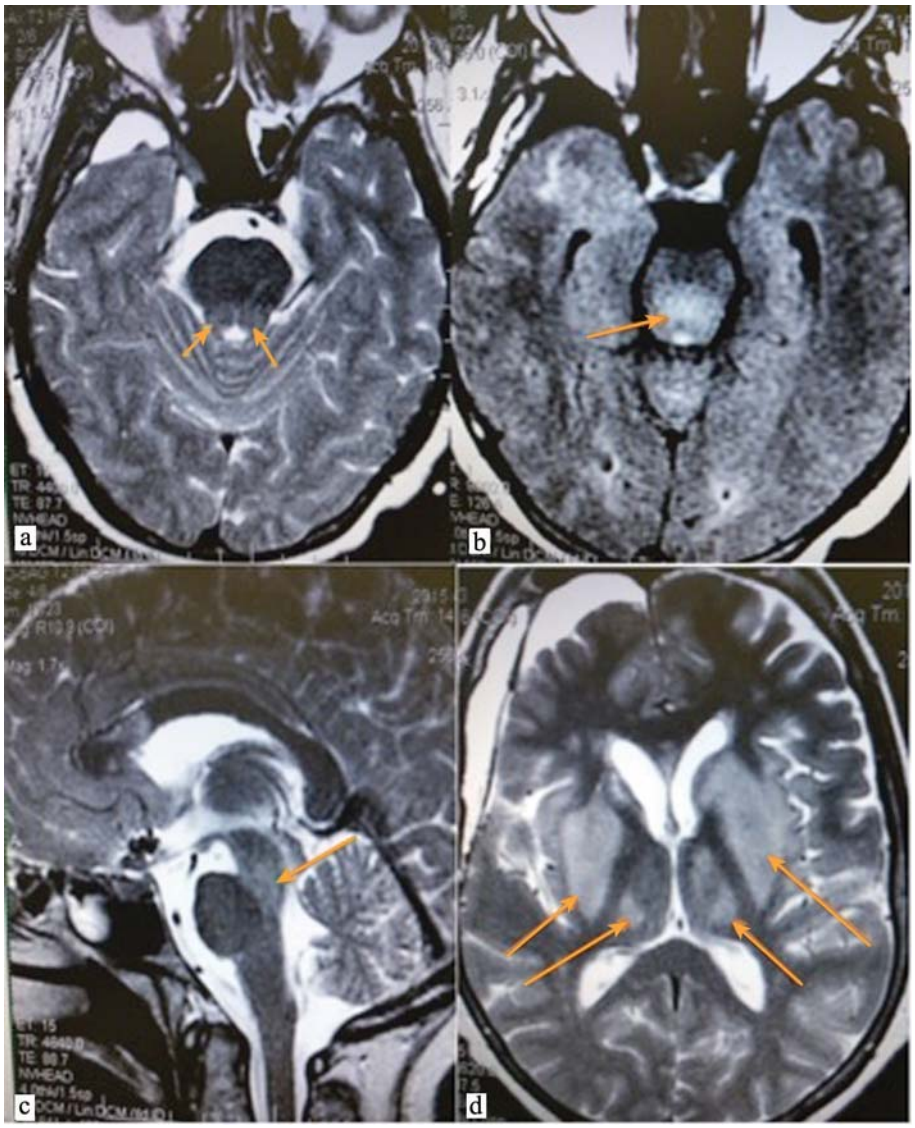

Fig. 2 (a—d). **T2-WI and FLAIR MRI of the brain.**
Arrows indicate changes in the brainstem and subcortical nuclei.

epileptic seizures [10], Parkinson's syndrome, and locked-in syndrome [12—14].

CPM and EPM are primarily diagnosed based on neuroimaging data. Myelinolysis appears as a high H2O content area on the X-ray film and can resemble infarction on the SCT scan. The method of differential diagnosis of myelinolysis is MRI. Brain lesion areas are characterized by a homogeneous high signal on T2-WI MR images and by a low signal, the absence of perifocal edema, and mass-effect signs on T1-WI MR images. A characteristic feature of this pathology is non-involvement of the pontine tegmentum and anterolateral pontine structures. The affected area can involve the midbrain, periventricular white matter, internal and external capsules, and corpora callosa. MRI findings of bilateral symmetric lesions of the thalami and basal nuclei in combination with brainstem lesions facilitate the correct clinical interpretation of myelinolysis [15].

A significant contribution to the differential diagnosis in the present case was made by the data of chemistry blood and cerebrospinal fluid panels that revealed elevated levels of the demyelination markers — the myelin basic protein (its level was increased hundreds-fold) and antimyelin-associated glycoprotein, with no increase in the S100 protein (a marker of damage and inflammation of the brain) and neuron-specific enolase (a marker of ischemia) levels. This indicates the demyelinating process in the brain, developing without signs of ischemia and inflammation.

In the literature, there are separate reports on the use of high doses of corticosteroid hormones [16] and plasmapheresis for the treatment of EPM [17—19]. The

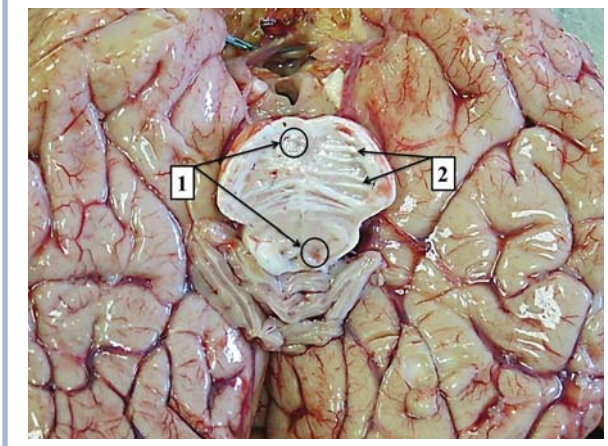

***Fig. 3.* A gross specimen.**

A cross section of the pons: 1 — developing microcysts; 2 — bulging of the white matter.

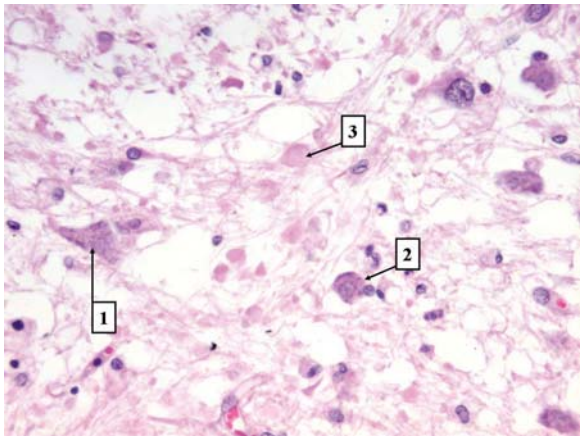

***Fig. 5.* A microspecimen of the white matter from the subcortical nuclei area.**

1 — neuronal death; 2 — neuronal shrinkage; 3 — eosinophilic bodies. Staining with hematoxylin and eosin, ×400.

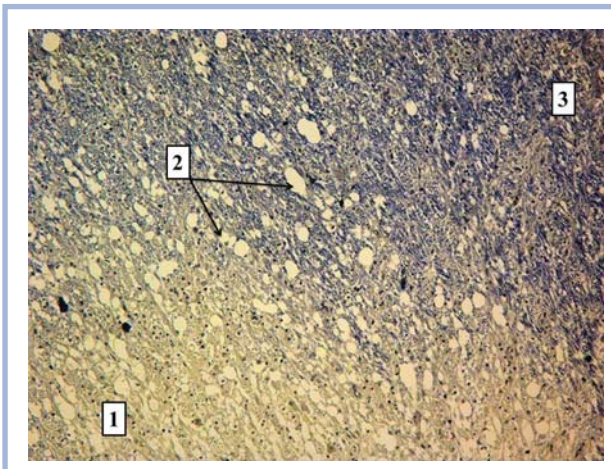

***Fig. 4.* A microspecimen of the white matter from the subcortical nuclei area.**

1 — demyelination area; 2 — edema in the perifocal area with spongy transformation; 3 — area of positive staining of myelin fibers. Spielmeyer staining, ×200.

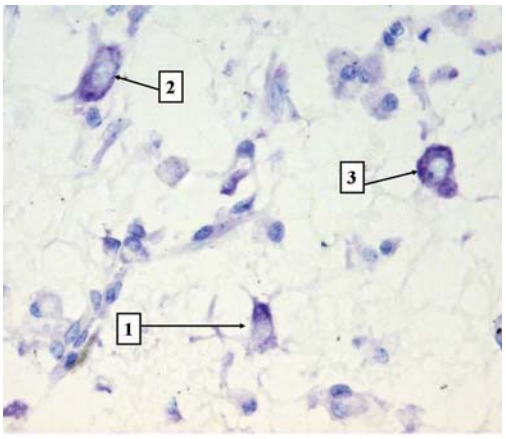

***Fig. 6.* A microspecimen of the white matter from the subcortical nuclei area.**

1 — a dead neuron; 2 — granular disintegration of the Nissl substance, initial neuronal karyolysis; 3 — a deformed neuron with chromatolysis. Nissl staining, ×400.

use of pulse-therapy with glucocorticoids enabled us to slow down the process in the presented case as well as to achieve pronounced regression of the neurological symptoms. However, the intravital diagnosis of this rare complication did not help stop the development of severe neurodystrophic lesions of internal organs, which led to multiple organ failure that caused patient's death.

There is no conflict of interest.

REFERENCES

1. Adams RD, Victor M, Mancall EL. Central pontine myelinolysis: a hither to undescribed disease occurring in alcoholic and malnourished patients. *AMA Arch Neurol Psychiatry*. 1959 Feb;81(2):154-172.
doi: 1959.02340140020004
2. Atkin JJ, Coady AM, White MC, Mathew B. Hyponatraemia secondary to cerebral salt wasting syndrome following routine pituitary surgery. *Eur J Endocrinol*. 1996;135:245-247.
doi 10.1530/eje.0.1350245
3. Stakhovskaya LV, Erokhina LG, Leskova NN, Gubskiy LV. Central pontine and extrapontine myelinolysis. *Zhurnal nevrologii i psikhiatrii*. 2000; 100: 2: 55-58. (In Russ.).
4. Norenberg MD, Papendick RE. Chronicity of hyponatremia as a factoir in experimental myelinolysis. *Ann Neurol*. 1984;15:544-547.
doi 10.1002/ana.410150606
5. Hadfield MG, Kubal WS. Extrapontine myelinolysis of the basal ganglia without central pontine myelinolysis. *Clin Neuropathol*. 1996 Mar-Apr;15(2):96-100.
doi 10.1007/3-540-27660-2_89
6. Bourgouin PM, Chalk C, Richardson J, Duang H, Vezina JL. Subcortical white matter lesions in osmotic demyelination syndrome. *Am J Neuroradiol*. 1995;16:1495-1497.

7. Polenov AL. *The problem of central neurodystrophies of internal organs*. Leningrad: Meditsina. 1972. (In Russ.).
8. Tayushev KG. *Hypothalamogenic degenerative-dystrophic process*. Saint Petersburg: Eskulap. 2002; 202. (In Russ.).
9. Laureno R, Karp BI. Myelinolysis after correction of hyponatremia. *Ann Intern Med*. 1997;126:1:57-62.
   doi 10.7326/0003-4819-126-1-199701010-00008
10. Girmenia F, Colasimo Di Biasi C, Faroni J, Pozzilli C. Central pontine myelinolysis: report of an asymptomatic case. *Ann Ital Med Int*. 1995;10(1):53-54.
11. Greenberg WM, Shah PJ. CPM in polydipsic psychiatric patients. *Am J Psychiat*. 1993;150:842-843.
   doi 10.1176/ajp.150.5.842-b
12. Go M, Amino A, Shindo K, Tsunoda S, Shiozawa Z. A case of central pontine myelinolysis and extrapontine myelinolysis during rapid correction of hypernatremia. *Kinsho Shinkeigaku*. 1994;34:11:1130-1135.
13. Morlan L, Rodriguex E, Gonzalez J, Jimene-Ortiz C, Escartin P, Liano H. Central pontine myelinolysis following correction of hyponatremia: MRI diagnosis. *Eur Neurol*. 1990;30:1:149-152.
   doi 10.1159/000117333
14. Ardizzone G, Arrigo A, Schellino MM, Stratta C, Valzan S, Skurzak S, Andruetto P, Panio A, Ballaris MA, Lavezzo B, Salizzoni M, Cerutti E. Neurological complications of liver cirrhosis and orthotopic liver transplant. *Transplant Proc*. 2006;38(3):789-792.
   doi: 10.1016/j.transproceed.2006.01.039
15. Ho VB, Fitz CR, Yoder CC, Geyer CA. Resolving MR features in osmotic myelinolysis (central pontine and extrapontine myelinolysis). *Am J Neuroradiol*. 1993;14(1):163-167.
16. Kallakatta RN, Radhakrishnan A, Fayaz RK, Unnikrishnan JP, Kesavadas C, Sarma SP. Clinical and functional outcome and factors predicting prognosis in osmotic demyelination syndrome (central pontine and/or extrapontine myelinolysis) in 25 patients. *J Neurol Neurosurg Psychiatry*. 2011;82(3):326-331.
   doi: 10.1136/jnnp.2009.201764
17. Ludwig KP, Thiesset HF, Gayowski TJ, Schwartz JJ. Plasmapheresis and Intravenous Immune Globulin Improve Neurologic Outcome of Central Pontine Myelinolysis Occurring Post Orthotopic Liver Transplant. *Ann Pharmacother*. 2011;45(2):e10.
   doi: 10.1345/aph.1P371
18. Saner FH, Koeppen S, Meyer M, Kohnle M, Hergel-Rosenthal S, Sotiropoulos GC, Paul A, Radtke A, Malago M, Broelsch CE. Treatment of central pontine myelinolysis with plasmapheresis and immunoglobulins in liver transplant patient. *Transpl Int*. 2008;21(4):390-391.
   doi: 10.1111/j.1432-2277.2007.00608.x
19. Dzyadz'ko AM, Katin ML, Rummo OO, Shcherba AE, Santotskiy EO, Minov AF, Gurova MYu, Chugunova OA, Slobodin YuV, Zubritskiy SM, Avdey LL. Central pontine myelinolysis after orthotopic liver transplantation (two case reports). *Vestnik transplantologii i iskustvennykh organov*. 2013; 15 (1): 89-95. (In Russ.).
   doi 10.15825/1995-1191-2013-1-89-95

Commentary

The article presents a case of surgical treatment of a patient during the subacute stage of subarachnoid hemorrhage from an anterior cerebral (communicating) artery aneurysm, which was complicated by the development of pontine and extrapantine myelinolysis in the late postoperative period, discusses this rare complication, and reviews the literature. The article describes the clinical course of the disease, data of CT and MRT examinations in the postoperative period, results of chemistry blood and cerebrospinal fluid panels (including tests for markers of demyelination, inflammation, and ischemia), as well as results of pathomorphological and histological examinations of the brain after the patient's death. On the basis of these data, the authors conclude that the patient had the demyelinating process in the brainstem and basal ganglia caused by osmotic disorders.

Acute pontine and extrapontine myelinolysis is a rare condition; however, the international and domestic literature reports a sufficient number of clinical cases of this condition as well as studies of its pathogenesis. In most studies, this condition is considered to result from hyponatremia or rapid and abrupt electrolyte changes during correction of hyponatremia that, in turn, is often caused by various somatic pathologies.

In the presented case, it is difficult to reliably conclude on the causes of demyelination because the data on electrolyte disturbances and infusion therapy are fragmentary. There is also no information about the presence and severity of angiospasm in the preoperative and, particularly, postoperative periods, which may also be a cause of diencephalic disorders, especially given postoperative edema of the right hemisphere and postoperative hypernatremia. It is not entirely clear what led to the patient's death because it is not indicated on what day after surgery she died, and the cause of death is not cerebral disorders but multiple organ failure typical of patients being in a serious condition for a long time. There is no discussion of a relationship between the revealed changes and the patient's autoimmune disease as well as long-term therapy with immunosuppressors. There are questions about quality of the morphological study and its description that does not provide an unambiguous confirmation of demyelination and may also indicate ischemia.

However, the article is of undoubted interest, drawing attention to the problem of pathogenesis of various complications in neurosurgical patients and their differential diagnosis. In this regard, of great interest are chemistry blood and cerebrospinal fluid panels for demyelination markers, which are rarely used in neurosurgical practice.

O.B. Belousova, I.A. Savin, O.A. Gadzhieva, L.V. Shishkina
(Moscow, Russia)