doi: 10.17116/engneiro201680649-51

Application of Resorbable Plates for Fixation of a Laminotomy Flap

YU.V. KUSHEL', YU.D. BELOVA, A.R. TEKOEV

Burdenko Neurosurgical Institute, Moscow, Russia

The paper describes a new technology — application of resorbable plates and pins for securing a laminotomy flap in children's neurosurgery. Four patients were operated on at our clinic. We describe in detail a surgical technique and compare it with a traditional fixation technique using ligatures.

Keywords: fixation, resorbable plates and pins, ultrasonic tip, laminotomy.

Laminotomy is widely used for surgical access to pathologies of the spinal canal [1]. The duration of laminotomy, especially in case of multilevel access, is rather short (much shorter than standard laminectomy). However, the process of fixing the laminotomy flap can take a lot of time, often as much as the time required for all previous stages of the surgery. The technology used for fixing the laminated flap is either ligatures through each arch or titanium mini-plates [1, 2]. We deliberately did not use titanium mini-plates in our practice for several reasons: difficulty of achieving good fixation of screws in children's thin and soft vertebrae arches and issues with relaminotomy in the event of relapse of the disease. Therefore, until recently our main method of fixation was ligatures [1, 3].

Resorbable plates and pins (biodegradable plates and special screws for them) are made of amorphous polymer consisting of D-lactide and L-lactide in equal proportions [4, 5]. Biodegradation requires about 90 days and occurs by hydrolysis. The screws used for this method differ from the "true" ones by the absence of threads and therefore there is no need use a screwdriver. In essence, they are pins that can be softened using a special ultrasonic nozzle and subsequently "flow into" the bone's diploque, which allows them to become fixated in it once the ultrasonic action is stopped and they solidify. The technology is simple and convenient. In addition, the plate itself is also softened by heating at a temperature of 60 °C and can be modeled "in situ". The manufacturer positions these products for cranial and maxillofacial surgery [5, 6]. Our experience with the use of resorbable plates and screws in the surgery of craniosynostosis and complex skull defects in children led to the idea of using the same fixation technology for laminotomy.

Material and Methods

Resorbable plates and screws were used to fix laminotomy flaps in 4 patients aged 4 to 11 years (at 3, 4, 5, and 9 levels). In total, the fixation was performed at 21 levels. The operations were performed for intradural tumors and cysts of the spinal cord. The average time of fixation was 15 minutes (which is approximately 2.5 times shorter than the duration of traditional fixation by ligatures). There were no complications, flap displacements or tissue reactions. The minimal follow up period was 3 months.

Operation technique

In all cases laminotomy was performed after subperiosteal dissection, following the procedure described previously by the first author [1]. The intradural stage of the surgery was performed using microsurgical techniques and depended on a specific pathology. The stage of fixing the flap began after tight sealing of the dura mater. We used 1-mm thick plates with 4 holes in all cases (the length and arrangement of holes was always sufficient for our purpose) and pins with a diameter of 2.4 mm and a length of 5 mm. Plates were bent "in situ" to produce the required configuration, just before they were fixed. The fixation of all plates to the flap was carried out immediately afterwards (**Fig. 1**).

Further, the flap was put in place and, if necessary, the plates were additionally bent to ensure their optimal contact with the base of the arches. Then most cranial and caudal arches were fixed, which ensured correct position of the flap in the wound. Finally, all the other plates were fixed (**Fig. 2**). The wound was sutured layer by layer in accordance with general surgical principles.

A schematic depiction of the method for fixing a laminated bone flap is shown in **Fig. 3**.

Discussion

Literature search for use of resorbable plates and screws in neurosurgery produced only results related to cranial application [4, 6—8]. Therefore, it was not possible to compare our experience with the literature data. Nevertheless, it should be noted that resorbable materials are gradually getting traction in traumatology, orthopedics and spinal surgery and there are already relevant publications. However, the main issues that are discussed in these papers are mechanical strength and

© Group of authors, 2016

e-mail: ubelova@nsi.ru

reliability of fixation in comparison with metallic analogs [5].

In our clinical study, this comparison is not determinative. It is well known that the purpose of laminotomy and fixation of the flap is not so much immediate "stabilization" as restoration of the place of fixation of the paraspinal musculature and prevention of gross epidural fibrosis. In this situation, the main goal of fixation is to position the flap "*in situ*", where the mechanical load on it is minimal, so even ligature fixation is sufficient. We have been successfully using ligatures to fix the laminotomy flaps since 2003 (more than 270 laminotomies were performed), and we have never noted any issues related to insufficient rigidity of fixation or flap displacement. The only significant drawback of this technique is that it is labor-intense and time-consuming, especially in case of laminotomies of more than 3 levels. For example, the process of fixing a 5-level flap in the thoracic spine can take up to 40 minutes. This procedure becomes even more time-consuming in case of narrow canal and thick arches. In addition, the process of drilling holes in the roots of the arches often leads to additional venous bleeding from the epidural veins, which also leads to unnecessary waste of time and resources. The use of resorbable plates is more promising in this situation. The use of standard titanium plates in children is less desirable for reasons we have already mentioned above: difficulty in achieving good fixation of screws in thin and soft arches of children's vertebrae and issues with relaminotomy in the event of relapse of the disease. In addition, the classical technology of drilling holes and tightening the screws does not provide any benefits in terms of technology or convenience (in a narrow and deep wound it is even more difficult) than imposing ligatures.

Therefore, we became interested in resorbable plates with ultrasonic "welding" of "screws". Our preliminary experience with the use of resorbable plates and pins was positive. This technology provides reliable and fast fixation for fixing a laminotomy flap. In addition, by bending the plates in a specific manner, one can slightly increase the transverse dimension of the spinal canal to ensure decompression. The biggest drawback and the main obstacle to the wide application of the described technology, are the price of implantable products and special equipment required for their installation.

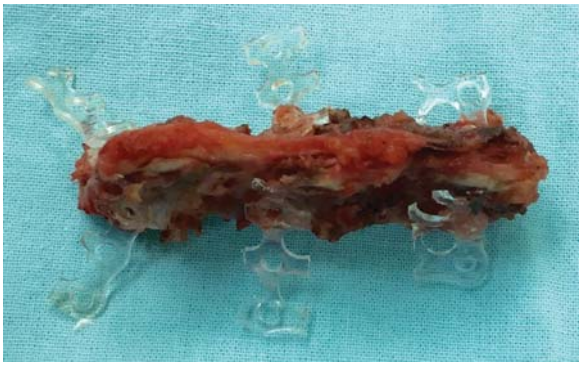

Fig. 1. **Laminotomy flap with fixed plates.**

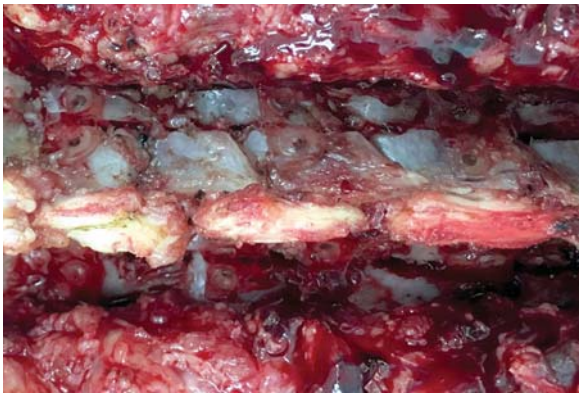

Fig. 2. **Laminotomy flap fixed in place.**

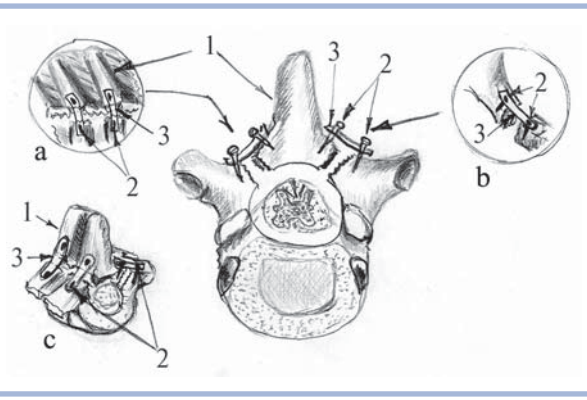

Fig. 3. **Scheme of the flap fixation.**

a — sagittal projection; b — frontal projection; c — general view in three projections. 1 — laminotomy flap, fixed in its place; 2 — resorbable pins (screws); 3 — resorbable plates.

Conclusion

The paper presents the initial experience of using resorbable plates and pins (screws) for fixing a laminotomy flap. We describe the surgical technique and provide comparative evaluation of the proposed technology with those already commonly used in practice.

The local ethical committee of the Burdenko Neurosurgical Institute of the Ministry of Health of the Russian Federation at the meeting of 09.06.16 (protocol No 06/2016) approved the publication of this paper in a specialized medical journal.

There is no conflict of interest.

REFERENCES

1. Kuschel YV. The role of laminotomy and laminoplasty in reducing the frequency of post-operative kyphoscoliosis in children operated on for intramedullary tumors. *Problems of neurosurgery named after N.N. Burdenko*. 2007;20-24..
2. Ruggeri A, Pichierri A, Marotta N, Tarantino R, Delfini R. Laminotomy in adults: technique and results. *Eur Spine J*. 2012;21:364-372.
   doi: 10.1007/s00586-011-1826-2
3. Kuschel YV. «Open-door» laminoplasty to remove common intramedullary tumors in children — a new approach to intradural spinal pathology. *Problems of neurosurgery named after N.N. Burdenko*. 2007;45-46.
4. Acosta HL, Stelnicki EJ, Rodriguez L, Slingbaum LA. Use of absorbable poly (d,l) lactic acid plates in cranial-vault remodeling: presentation of the first case and lessons learned about its use. *Cleft Palate Craniofac J*. 2005;42:333-339.
5. Vaccaro AR, Madigan L. Spinal applications of bioabsorbable implants. *J Neurosurg*. 2002;97:407-412.
6. Freudlsperger C, Castrillon-Oberndorfer G, Baechli H, Hoffmann J, Mertens C, Engel M. The value of ultrasound-assisted pinned resorbable osteosynthesis for cranial vault remodelling in craniosynostosis. *J Cranio-maxillofac Surg*. 2014;42:503-507.
7. Salokorpi N, Sinikumpu JJ, Iber T, Zibo HN, Areda T, Ylikontiola L, Sandor GK, Serio W. Frontal cranial modeling using endocranial resorbable plate fixation in 27 consecutive plagiocephaly and trigonocephaly patients. *Childs Nerv Syst*. 2015;31:1121-1128.
8. Stendel R, Krischek B, Pietila TA. Biodegradable implants in neurosurgery. *Acta Neurochir (Wien)*. 2001;143:237-243.

Commentary

This work is devoted to the use of resorbable plates and pins for laminoplasty in children. The process described by the authors was previously used only for cranioplasty, so its application in spinal surgery is off-label.

The laminoplasty is widely used in treatment of cervical spondylogenic myelopathy in Japan (Hirobayashi, Kurokava), and in Russia (A.O. Guscha, O.A. Dreval). At present, there are titanium plates of special shape for fixing the arches available for carrying out this operation. Of course, the use of resorbable products is an attractive alternative to metal ones, especially when ultrasonic "welding" is used for fixing pins in place.

It remains unclear whether it is possible to use these products in the elderly, given the frequency of laminoplasty in the stenosis of the spinal canal at the cervical level and the frequent sclerosis and fragility of the arches in this category of patients.

A.O. Guscha (Moscow, Russia)