doi: 10.17116/engneiro201680637-48

Phase Contrast MRI-based Evaluation of Cerebrospinal Fluid Circulation Parameters in Patients with Foramen Magnum Meningiomas

S.V. KONDRAKHOV, N.E. ZAKHAROVA, L.M. FADEEVA, S.V. TANYASHIN

Burdenko Neurosurgical Institute, Moscow, Russia

Background. Meningiomas of the foramen magnum (FM) region account for 1.8 to 3.2% of all meningiomas. The international literature provides insufficient data describing the state of cerebrospinal fluid (CSF) circulation in these patients.
Material and methods. We studied 38 patients with FM meningiomas aged 35 to 79 years (mean age, 56.7 years). Meningioma size averaged 30 mm (10—60 mm). Anterolateral meningiomas were observed in 29 patients, ventral — in 5 patients, and dorsal — in 4 patients. Twenty nine patients underwent surgery. All operated patients were examined before and after surgery. CSF circulation was studied using phase contrast MRI (PC-MRI).
Results. The size and localization of FM meningiomas do not significantly affect CFS circulation parameters. Pyramidal symptoms, sensory disorders, and XIth cranial nerve dysfunction correlate with CFS circulation parameters. According to preoperative PC-MRI data, CFS circulation parameters were significantly higher in all patients with FM meningioma compared to normal values. Surgery was followed by decrease in the peak positive velocity, peak negative velocity, and range of maximum linear velocity amplitude. Positive and negative volumes and stroke volume did not change. Recovery dynamics of CFS circulation parameters was similar, regardless of surgery completeness. According to PC-MRI data, CFS circulation parameters did not reach normal values in all groups of operated patients.
Conclusion. The results of investigation of CFS circulation in patients with FM meningiomas support the use of palliative surgery (partial resection, dural plasty, craniovertebral junction decompression) in the case of inoperable meningiomas.

Keywords: foramen magnum meningioma, surgery, cerebrospinal fluid circulation, phase contrast magnetic resonance imaging.

Meningiomas of the foramen magnum (FM) region account for 1.8 to 3.2% of all meningiomas [1,2].

FM meningiomas are among the most challenging pathologies in neurosurgery in connection with the fact that the main arteries, cranial nerves, and medulla oblongata are located in this area. Growing tumor displaces and, in many cases, involves vertebral arteries in its stroma.

Completeness of resection of meningiomas located in this area depends on the location of the original growth, density, and size of the tumor, arachnoid membrane integrity, tumor invasion of vertebrobasilar system vessels and caudal group of cranial nerves, applied approach, and many other factors [3—7]. According to different authors, total resection of FM meningiomas was achieved in 70—96% of cases [8—11]. Therefore, the rate of non-radical removal of meningiomas located in his region is high.

Most publications dealing with craniovertebral meningiomas describe the degree of completeness of tumor resection. Available literature provides no reports demonstrating the effect of tumor size and location on the state of CSF circulation, severity and dynamics of its impairment in patients with FM meningiomas and after resection of these meningiomas.

The issues of the effect of the extent of meningioma resection or decompressive surgery on the passability of the subarachnoid cisterns of the craniovertebral junction and the role of impairment and recovery of the CSF circulation in the development of clinical manifestations of this pathology and their changes were almost not covered so far.

According to available preliminary data, the effectiveness of tumor resection characterized by various extent can be assessed based on both clinical signs and reliable quantitative values of CSF circulation.

Phase-contrast MR is the main non-invasive imaging method for CSF spaces. As opposed to MR and CT cisternography, this technique can be used to assess not only anatomical characteristics of the CSF system and geometry of CSF spaces with slow CSF motion, but also to visualize fast CSF motion [12—16]. Thus, phase contrast MRI provides the most adequate assessment of CSF dynamics without limitation to the craniovertebral junction [17—22]. The literature [23] provides data on the evaluation of CSF circulation using phase contrast MRI in patients with syringomyelic and arachnoid cysts. Elucidation of the mechanisms of CSF circulation disorders in patients with FM meningiomas will clarify the pathogenesis of clinical manifestations of the disease caused by direct tumor action on the neural structures and impaired CSF circulation.

The research was aimed at studying the characteristics of the CSF circulation in patients with meningiomas of the craniovertebral junction and changes in the CSF circulation parameters depending on the extent of the surgery.

The study was aimed at:

— Evaluating CSF circulation disturbances depending on the size of FM meningiomas;

— Assessing CSF circulation disturbances depending on the location of meningiomas (anterior, anterolateral, posterior);

© Group of authors, 2016

e-mail: skondrahov@nsi.ru

— Assessing the impact of CSF circulation disorders on the severity and dynamics of clinical symptoms in patients with FMR meningiomas;

— Assessing the severity of CSF circulation disorders before and after surgery and the nature of changes in CSF circulation parameters, depending on the extent of surgical intervention.

Materials and methods

The study was based on the results of examination of 38 patients with FM meningiomas aged 35 to 79 years (mean age, 56.7 years). In our series, most patients were 45—50 and 60 —65 years old (**Fig. 1**).

Maximum tumor size was calculated based on contrast enhanced T1-weighed MRI anatomical slices in three projections. Maximum size of meningiomas ranged 10 to 60 mm, median 30 mm. Distribution of the maximum size of meningiomas is shown in **Fig. 2**.

Most patients in our series had anterolateral FM meningiomas, a total of 29 cases. Ventral meningiomas were detected in 5 patients, dorsal — 4 (**Fig. 3**).

Surgery was conducted in 28 patients. The extend of the surgery varied from total resection to biopsy accompanied by dural plasty with aponeurosis. One patient underwent ventriculoperitoneal shunting due to occlusive hydrocephalus. Nine patients had not been operated on. Five of them underwent radiotherapy. In 1 patient, operation was canceled due to the burdened somatic status. In 3 cases, surgery was not proposed due to small tumor size and minimal symptoms. These patients were followed. We used the classification proposed by K. Amautovic [24, 25] to assess the completeness of tumor resection:

— total resection (gross-total resection) — complete tumor resection, including the involved DM fragments. It corresponds to grade I tumor resection according to Simpson's classification (Simpson I);

— almost total resection (near-total resection) — in the case of preservation and coagulation of the tumor at the DM matrix. It corresponds to grade II tumor resection according to Simpson's classification (Simpson II);

— subtotal resection — resection of more than 60% of tumor volume It corresponds to grade III tumor resection according to Simpson's classification (Simpson III);

— partial resection — resection of less than 60% of the tumor, including biopsies and simple decompression. It corresponds to grade IV—V tumor resection according to Simpson's classification (Simpson IV—V).

The examples of total and subtotal resection of meningiomas are shown in **Fig. 4** and **5**.

Distribution of patients according to the extent of tumor resection is shown in **Fig. 6**.

All operated patients underwent preoperative and postoperative (in 3—6 months) examination. Nine

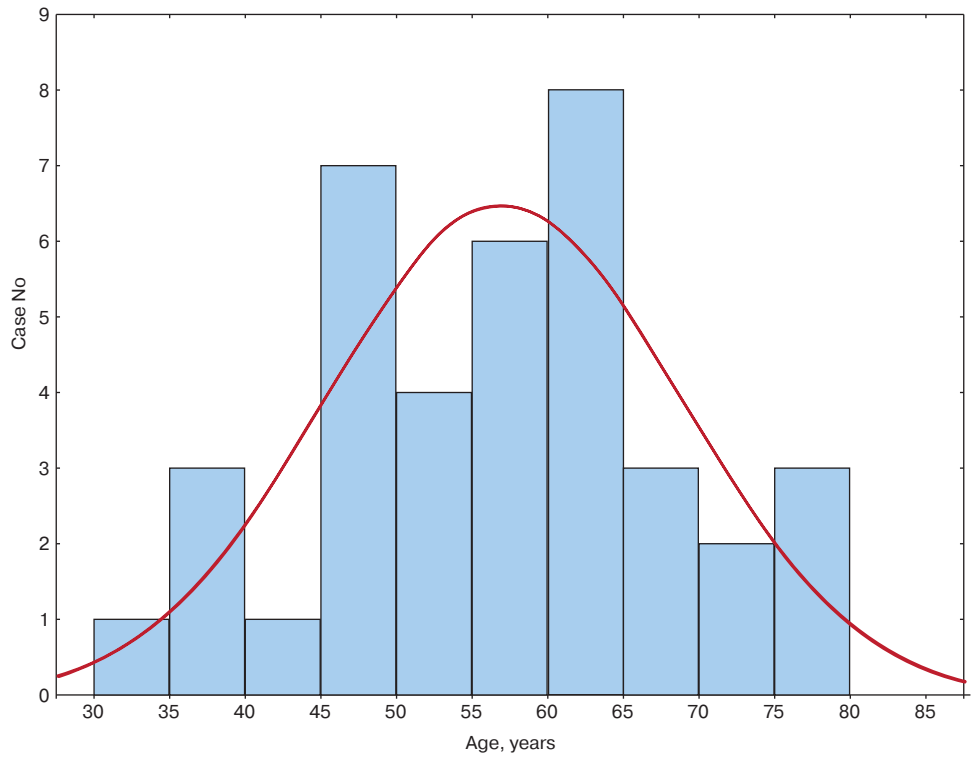

Fig. 1. **Patients' age distribution.**

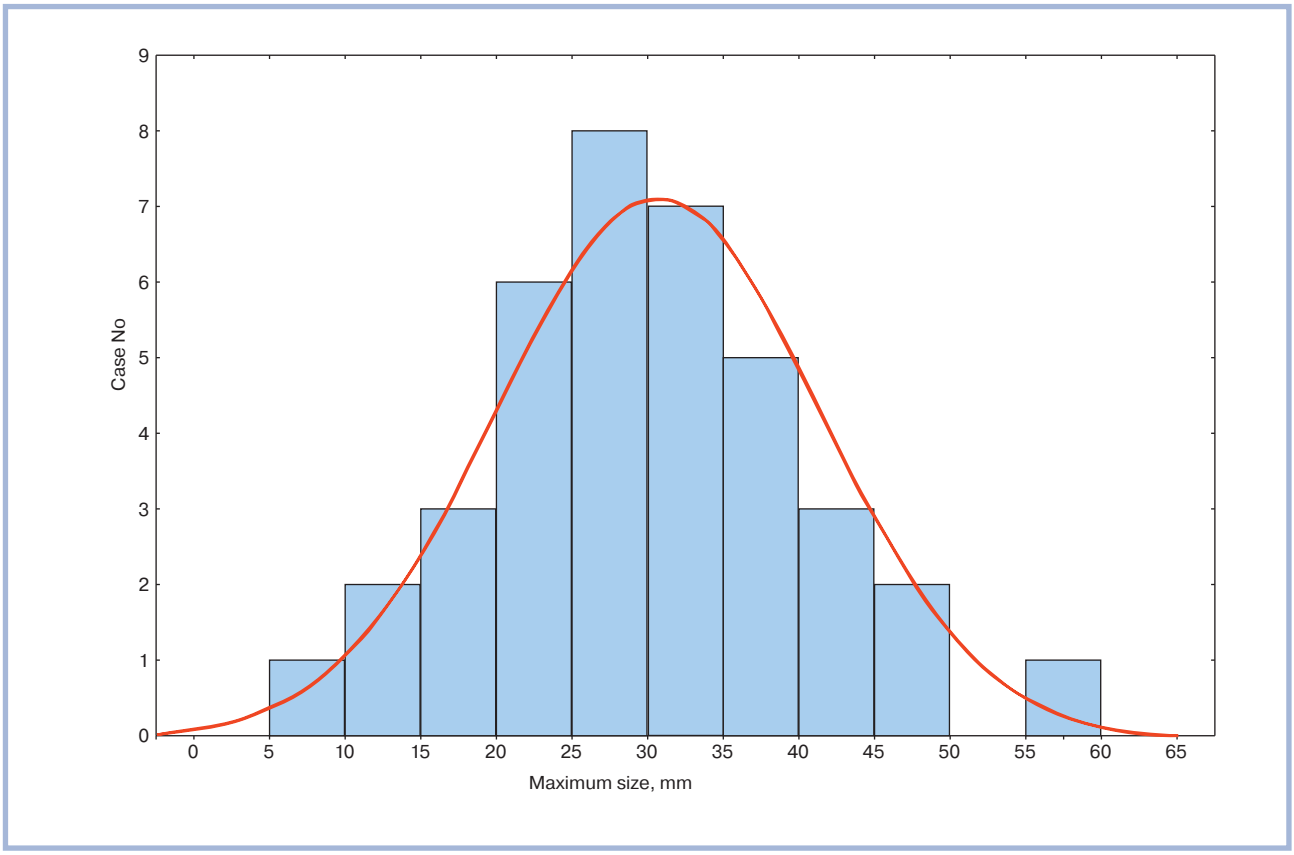

Fig. 2. **Distribution of the maximum size of meningiomas.**

patients, who had not been operated on, were examined once.

The studies were carried out on Signa HDxt MR tomograph (General Electric Medical Systems) using the magnetic field strength of 1.5 T.

All patients underwent MRI in the following modes:

– standard T1 and T2-weighted MRI in the axial and sagittal planes; they were obtained using spin echo pulse sequence, SE (600/20) and FastSE (4500/84);

— 3D T2-weighed MRI modes (3D-CUBE mode, which provides a clear view of the outline of the subarachnoid spaces, and FIESTA mode, showing pulsatile CSF movement);

— phase contrast MRI (PC-MRI) with reference to the cardiac cycle based on the PC-MRI pulse sequence with parameters TR 26/TE 11/FA 20 gy, 256/160 image matrix, in two replicates. The slice (4 mm thick) was selected at C2—C3 level, perpendicular to the vertebral canal, with FOV = 200 mm. The average scan time was 3—4 min.

Heart contraction curve was recorded using peripheral plethysmograph. A total of 16 images per cardiac cycle were recorded, corresponding to the different phases of the cardiac cycle. Spin velocity encoding (VENC-Velocity encoding) averaged 15 cm/s. In the case of artifacts, VENC could be changed in the range from 0 to 20 cm/s. Data were processed in offline mode based of the Report Card software package. Region of interest in the intradural space was selected based on PC-MRI (**Fig. 7**), stroke volume, linear and volumetric velocity of CSF circulation were calculated as a function of the cardiac cycle phase (**Fig. 8**).

Data processing using Report Card software provided the following characteristics of the CSF circulation: positive peak velocity, negative peak velocity, positive volume, negative volume, amplitude range of the maximum linear velocity, and stroke volume. The physical meaning of CSF circulation parameters obtained by PC-MRI is as follows:

— positive peak velocity — maximum linear velocity of CSF in the craniocaudal direction;

— negative peak velocity — maximum linear velocity of the CSF in the caudocranial direction;

— amplitude range of the peak velocity — the range of maximum linear velocity variation in one cardiac cycle.

These three parameters represent velocity characteristics of CSF circulation, wherein the latter one is derived from the positive and negative velocities.

Positive volume — the amount of CSF passing through the axial slice at C2—C3 during systole.

Negative volume — the amount of CSF passing through the axial slice at C2—C3 during diastole.

Stroke volume — the amount of CSF passing through the axial slice at C2—C3 during one cardiac cycle.

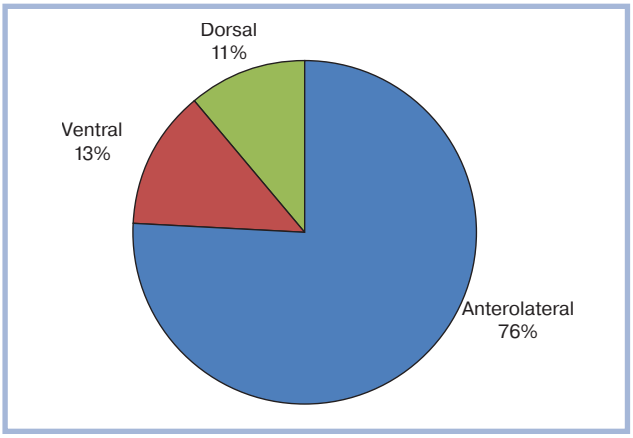

Fig. 3. **Location of FM meningiomas in the analyzed series.**

Positive and negative volume and stroke volume are volumetric characteristics of CSF circulation. As in the case of linear velocity, stroke volume is derived from the positive and negative volume.

Normal values of the main indices at C2—C3 were obtained based the study including healthy volunteers, which was previously performed at the Burdenko Neurosurgical Institute (**Table 1**) [26].

Statistical processing of the material used Descriptive Statistics methods (scattering diagram, distribution of variables, mean and standard deviation) and nonparametric statistics methods describing the ordinal values (linear relationship between the Spearman's parameters, group analysis with calculation of confidence probability of intergroup differences using Mann Whitney test, medians, and percentiles). The data were processed using Statistica v.10 software.

Results

Preoperative characteristics of CSF circulation in patients with FMR meningiomas.

We used MRI to visualize CSF movement through the third ventricle, cerebral aqueduct, large cistern, and spinal canal. **Fig. 9** shows an example of the preoperative examination of patient *S.*, 46 years old, who was diagnosed with FM meningioma.

Table 2 shows the average and median values of CSF circulation parameters in 38 patients.

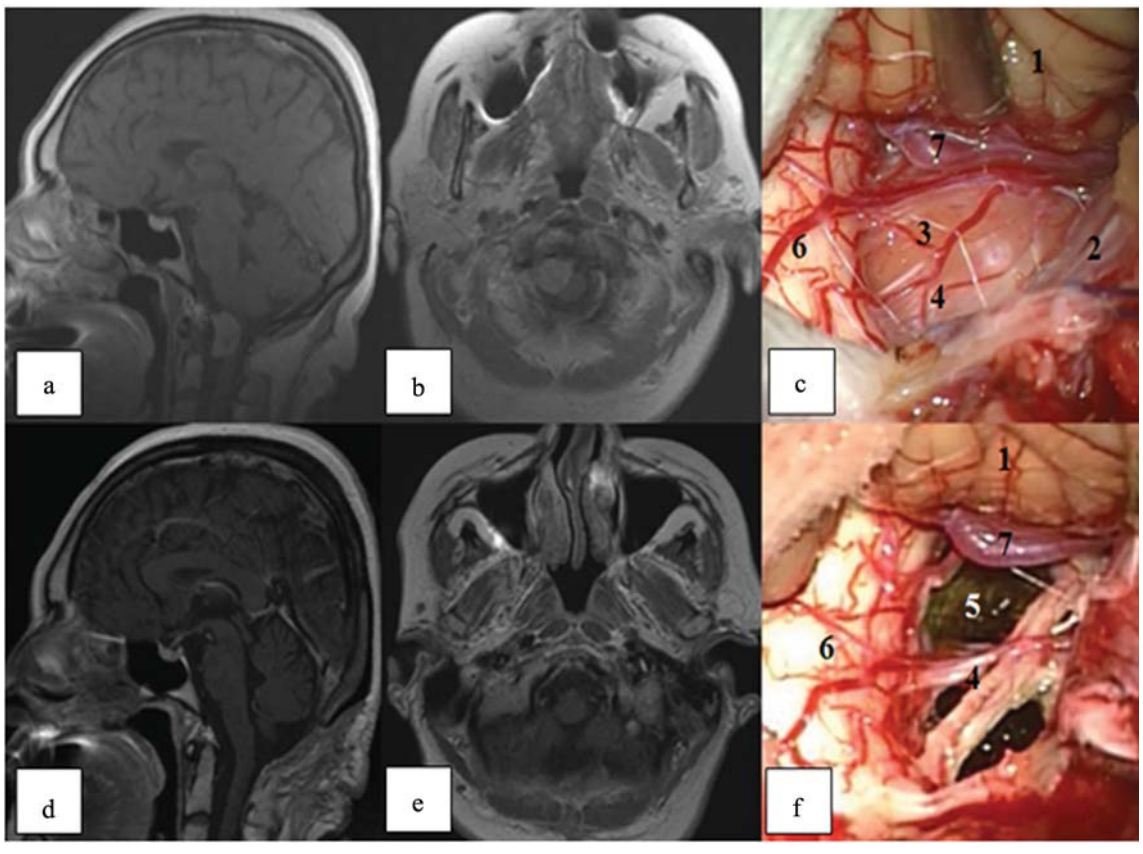

Fig. 4. **Total resection of FM meningioma.**

a, b — preoperative contrast enhanced T1-weighed MRI of the brain (sagittal and axial projections); d, e — contrast enhanced T1-weighed MRI of the brain after total resection (gross-total resection, sagittal and axial projection); c —overall view of the tumor after opening of the dura mater and arachnoid membranes; f — after total removal of the tumor node (1 — cerebellum, 2 — arachnoid, 3 — tumor, 4 — caudal group of cranial nerves, 5 — resected tumor bed, 6 — medulla oblongata, 7 — loop of the posterior inferior cerebellar artery).

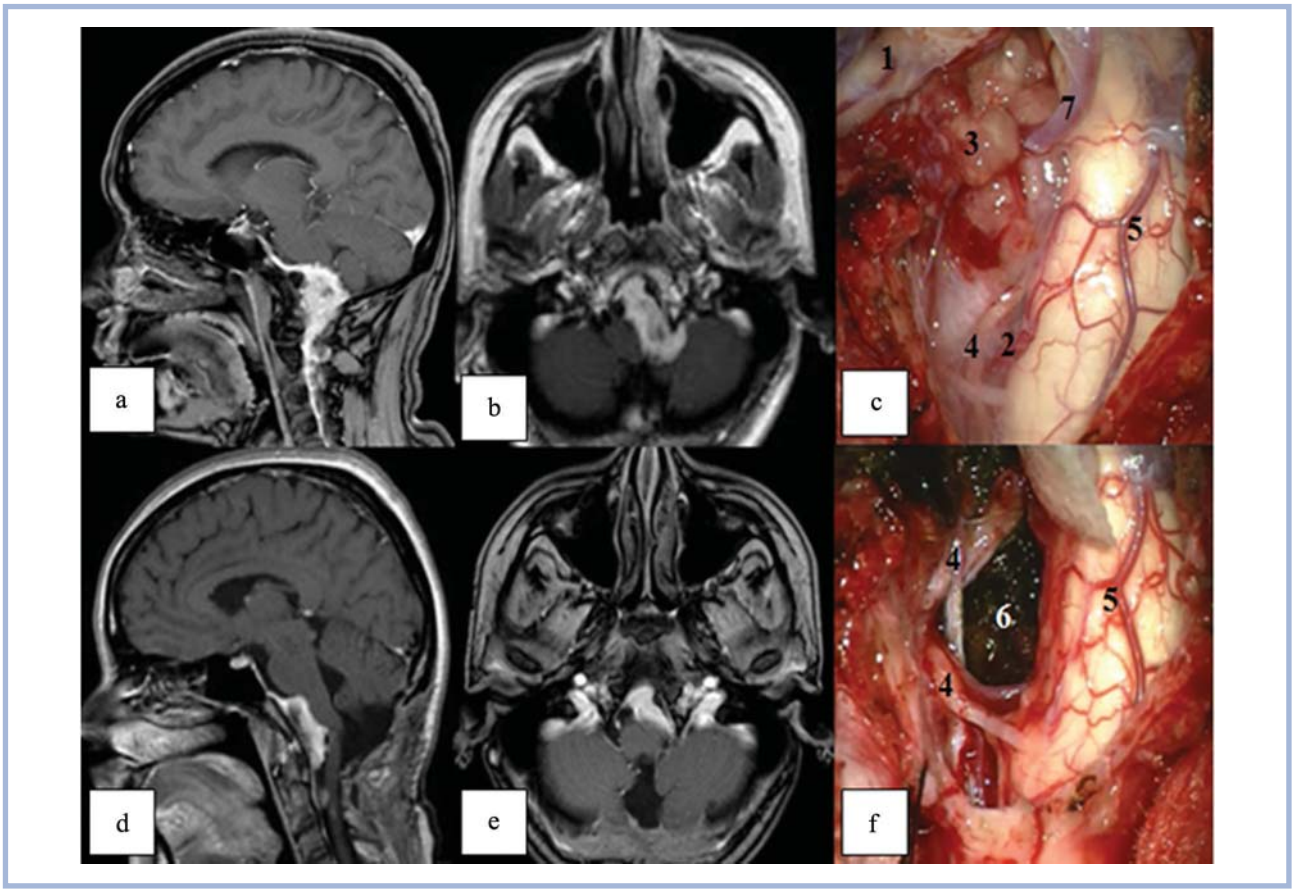

Fig. 5. **Subtotal resection of FM meningioma.**

a, b — preoperative contrast enhanced T1-weighed MRI of the brain (sagittal and axial projections); d, e — contrast enhanced T1-weighed MRI of the brain after subtotal resection (subtotal resection, sagittal and axial projections); c —overall view of the tumor after opening of the dura mater and arachnoid membranes; f — intraoperative view after subtotal removal of the tumor (1 — cerebellum, 2 — arachnoid, 3 — meningioma, 4 — caudal group of cranial nerves, 5 — medulla oblongata, 6 — meningioma remnants tightly adherent to the vertebral artery, 7 — loop of the posterior inferior cerebellar artery).

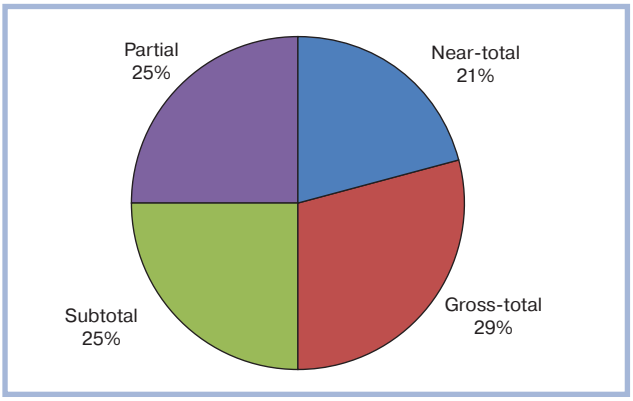

Fig. 6. **The completeness of meningioma resection in 28 patients.**

Comparative analysis of quantitative characteristics of CSF circulation at C2—C3 in apparently healthy individuals and patients with CSF meningiomas showed CSF circulation disorders in the form of statistically significant increase in all investigated parameters ($p<0.05$) in patients with meningioma.

The relationship between meningioma size and CSF circulation parameters

We found no correlation between meningioma size and CSF circulation parameters.

Examples of various relationships between tumor size and CSF circulation parameters are shown in **Fig. 10** and **11**.

The relationship between CSF circulation and location of meningiomas

CSF circulation parameters were compared in three groups of patients depending on tumor location (ventral, anterolateral, and dorsal) based on Mann-Whitney test. The analysis found that tumor location, as well as FM meningioma size, has no significant effect of CSF circulation parameters.

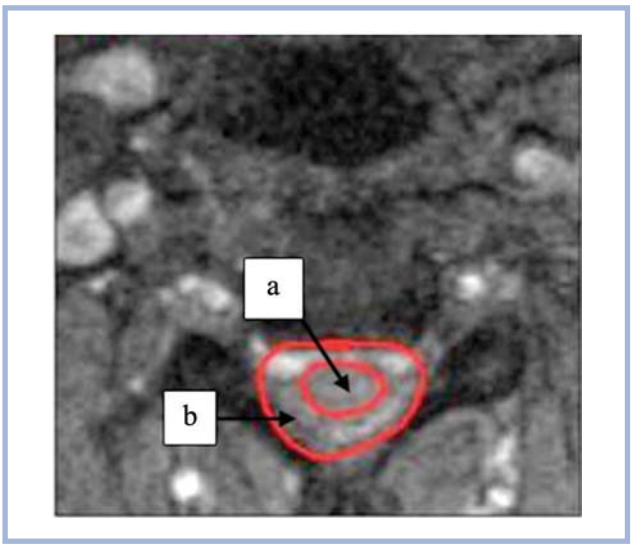

Fig. 7. **Axial slice at C2—C3.**
a — the spinal cord; b — "area of interest" in the intradural space.

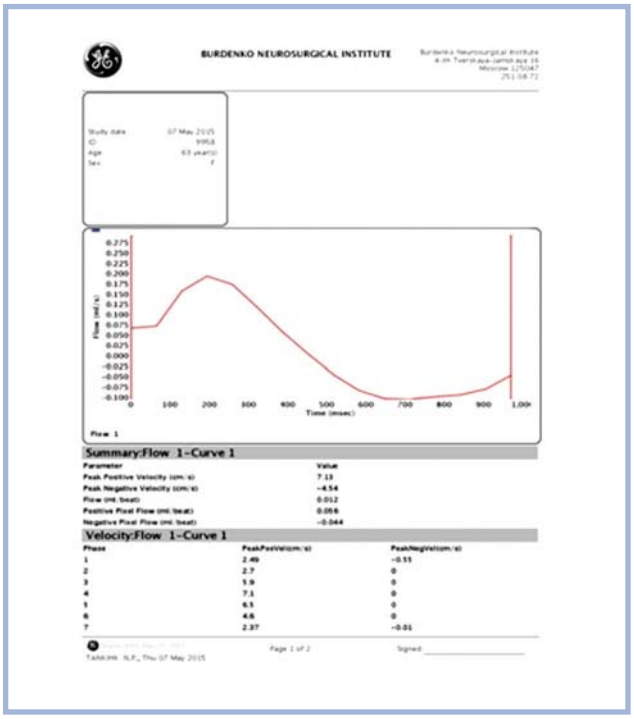

Fig. 8. **PC-MRI study protocol.**

Clinical manifestations and their correlation with CSF circulation parameters

Clinical presentation of FM meningiomas consists of various symptoms. We combined these symptoms into several characteristic syndromes:

1) cerebellar syndrome — dizziness, cerebellar ataxia, impaired statics, gait, and coordination;

2) cerebral symptoms are caused by increased intracranial pressure. They manifest in the forms of headache, dizziness, nausea, and vomiting;

3) bulbar syndrome — hoarseness, nasal voice, decreased palatal and pharyngeal reflexes, choking when swallowing, tongue deviation toward the affected muscle, atrophy and fibrillar twitching of a half of the tongue. This syndrome is associated with a direct effect of the tumor on the medulla oblongata and exiting roots of the IX, X, and XII pairs of cranial nerves;

4) pyramidal disorders — symptom resulting from tumor compression of the pyramidal pathways at the level of medulla oblongata and spinal cord and manifesting in the form of various severity of conduction motor disorders;

5) sensitivity disorders. These disorders are mainly caused by direct effect of meningiomas on the afferent pathways of the medulla oblongata and superior cervical spinal cord;

6) cervical syndrome — presents with restricted neck mobility, pain in the cervico-occipital area, head tilt;

7) dysfunction of the XIth pair of cranial nerves presents with paresis, plegia, atrophy of sternocleidomastoid and trapezius muscles.

Preoperative and postoperative distribution of the incidence of the aforementioned syndromes and their relationship to the CSF circulation parameters, as well as the significance of differences in the subgroups are summarized in **Tables 3** and **4**.

Preoperative positive and negative volume and stroke volume significantly differ ($p<0.05$) in the subgroups of patients with/without pyramidal symptoms. In the subgroup of patients having pyramidal symptoms, these values are significantly lower compared to patients without pyramidal disturbances. In our opinion, this may be due to the characteristics of the tumor node configuration. Local effect on the anterolateral surface of the medulla oblongata is characterized by more pronounced clinical manifestations in the case of smaller tumor compared to larger tumor volume, having no direct contact with the anterolateral surface of the medulla oblongata. Positive and negative peak velocity and range of maximum velocity amplitude do not depend on the neurological symptoms ($p> 0.05$).

Postoperative values (29 patients) of the positive and negative peak velocity and range of the maximum velocity amplitude are significantly higher ($p<0.05$) in patients having sensory disorders and dysfunction of the XIth pair of cranial nerves. No statistically significant correlation

Table 1. **Quantitative characteristics of CSF circulation at C2—C3 in healthy volunteers**

CSF circulation parameter according to PC-MRI	Values
Amplitude range of the maximum linear velocity, cm/s	7,2±0,68
Stroke volume, ml	1,04±0,37

Table 2. **Preoperative quantitative characteristics of CSF circulation at C2—C3 in patients with FM meningiomas**

CSF circulation parameter	Median	Std. Dev.	Median	25,000 th	75,000 th
Positive peak velocity, cm/s	10,97	4,7	12,2	6,67	14,8
Negative peak velocity, cm/s	9,89	4,59	9,77	5,33	14
Positive volume, ml	0,99	0,48	0,93	0,75	1,39
Negative volume, ml	0,84	0,49	0,92	0,38	1,16
Amplitude range of the maximum linear velocity, cm/s	20,86	8,61	21,38	16,23	29
Stroke volume, ml	1,83	0,83	1,83	1,43	2,41

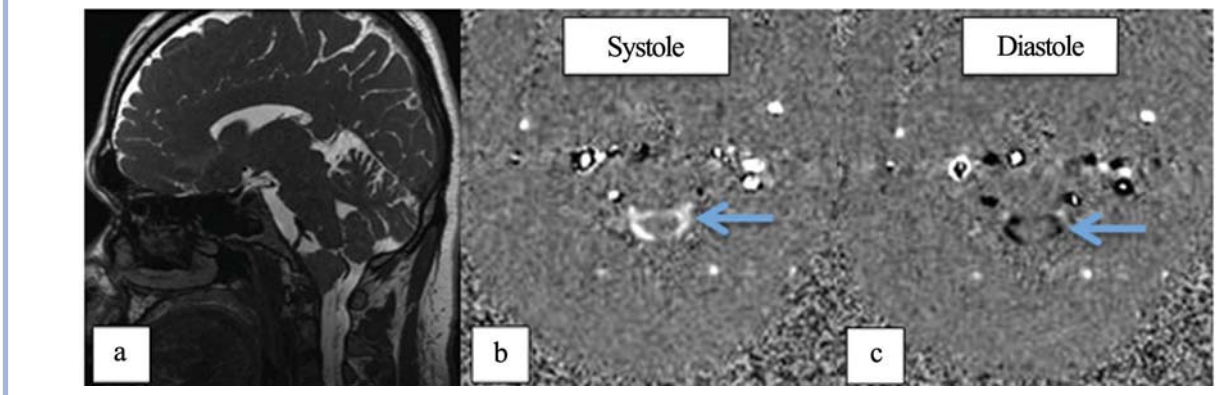

Рис. 9. **a — FIESTA MRI: CSF circulation unit is visualized on the anterior surface of the brain stem (at the FM); b — axial peak PC image at C2—C3 during systole. A narrow high-signal band in the intradural space (shown by arrow) corresponds to CSF movement in the craniocaudal direction during systole; c — axial peak PC image at C2—C3 during diastole. A narrow high-signal band in the intradural space (shown by arrow) corresponds to CSF movement in the caudocranial direction during diastole.**

of other CSF circulation parameters with clinical presentation was found ($p>0.05$). In some cases, this is due to the small number of observations. For example, only one patient was initially diagnosed with hypertensive-hydrocephalic syndrome, which regressed after surgery, and therefore this parameter could not be reliably evaluated.

Postoperative dynamics of CSF circulation in patients with FM meningiomas

Examination of 28 patients before and 3—6 months after tumor resection resulted in the following quantitative values of the main CSF circulation parameters at C2—C3 (**Tables 5** and **6**).

Comparative analysis of preoperative and postoperative medians of the main CSF circulation parameters showed that positive peak velocity, negative peak velocity, and amplitude range of the maximum linear velocity are significantly lower after surgery. There is no significant differenced in the positive and negative volume and stroke volume ($p>0.05$). Therefore, CSF circulation improves after surgery in terms of velocity characteristics and remains unchanged in terms of volumetric characteristics (**Table 7**).

The effect of the extent of surgical intervention on the recovery of CSF circulation

We compared the medians of all significantly varying parameters of CSF circulation (peak positive velocity, peak negative velocity, amplitude range of maximum linear velocity) between the four groups of patient according to completeness of tumor resection (**Table 8**, **Fig. 12**).

The resulting values demonstrate that significant improvement of CSF circulation parameters was achieved in the case of total resection; they were better than postoperative values after almost total and subtotal tumor resection. The group with partial resection was the second best in terms of recovery of CSF circulation parameters.

Comparative analysis of the medians of the main parameters of preoperative and postoperative CSF circulation has shown that surgery results in significantly reduced positive peak velocity, negative peak velocity, amplitude range of the maximum linear velocity. There was no significant changes in the positive and negative volume and stroke volume ($p>0.05$). Therefore, CSF circulation improves after surgery in terms of velocity

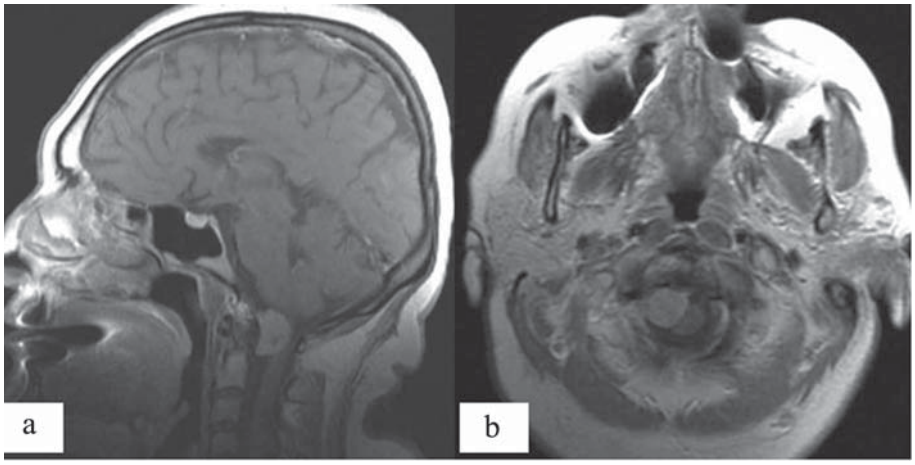

Fig. 10. **Anterolateral FM meningioma sized 24 mm. All CSF circulation characteristics are 2—3-fold higher than normal.**
a — contrast-enhanced T1-weighed MRI, sagittal view; B — contrast-enhanced T1 MRI, axial view.

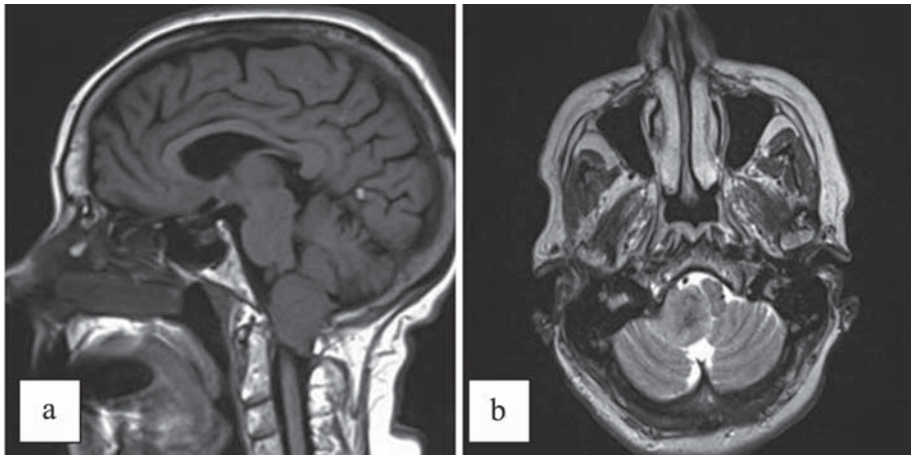

Fig. 11. **Anterolateral FM meningioma sized 38 mm. All CSF circulation characteristics are within the normal range.**
a — T1-weighed MRI, sagittal view; b — T2-weighted MRI, axial view.

characteristics and remains unchanged in terms of volumetric characteristics (**Table 7**).

It should be noted that postoperative velocity characteristics of CSF circulation improve according to PC-MRI, but does not reach normal values, regardless of the completeness of resection.

Discussion

Publications dealing with investigation of CSF circulation based on PC-MRI studies are dominated by studies in patients with Chiari malformation [13—16] and hydrocephalus [22, 27]. Available literature provides no studies of CSF circulation in patients with FM meningioma.

Chiari malformation is the most similar to FM tumors in terms of the pathogenetic basis of CSF circulation changes. Analysis of the literature demonstrates conflicting data on CSF circulation parameters at the superior cervical level in both healthy volunteers and patients with type I Chiari malformation before and after the operation [13—16, 28, 29]. This may be caused by the following reasons: different specifications of MR imager; measurements at different levels; heterogenous age composition of the patients under study; the study did not take into account the degenerative-dystrophic changes affecting CSF circulation processes; many authors provide not all CSF circulation parameters, which makes it difficult to compare the results.

Table 3. **Preoperative neurological symptoms in 38 patients with FM meningiomas. Medians of CSF circulation parameters at C2—C3 depending on the presence/absence of a certain symptom complex, as well as the significance of differences between the subgroups.**

Symptom complex			Peak positive velocity			Peak negative velocity			Positive volume			Negative volume			Amplitude range, max.			Stroke volume	
	n	%	Median+	Median–	*p*	Median+	Median–	*p*	Median+	Median–	*p*	Median+	Median–	*p*	Median+	Median–	*p*	Median+	Median–
Cerebellar syndrome	26	68,4	10,20	14,65	0,25	9,64	10,84	0,95	1,86	1,78	0,64	0,96	0,85	0,72	20,60	23,70	0,51	1,86	1,78
Cerebral syndrome	16	42,1	10,74	13,45	0,99	10,94	9,62	0,48	0,99	0,87	0,37	1,06	0,79	0,37	21,38	20,93	0,70	1,96	1,71
Bulbar syndrome	6	15,8	11,77	12,20	0,78	10,71	9,77	0,83	0,63	0,97	0,36	0,90	0,92	0,95	23,48	21,38	0,96	1,54	1,87
Pyramidal disorders	10	26,3	11,65	12,54	0,84	11,90	9,62	0,62	0,79	1,00	0,04	0,49	1,00	0,03	23,55	20,64	0,87	1,47	1,91
Sensory disorders	11	28,9	14,70	10,20	0,41	13,60	9,56	0,15	0,84	0,99	0,26	0,84	0,93	0,84	28,00	19,889	0,22	1,81	1,91
Cervical syndrome	10	26,3	11,63	12,19	0,45	8,09	9,87	0,49	1,07	0,92	0,52	0,87	0,92	0,83	20,60	21,30	0,43	1,71	1,87
Dysfunction of XI	5	13,2	12,99	11,29	0,60	13,30	9,60	0,35	0,95	0,90	0,86	1,06	0,90	0,52	28,00	20,13	0,43	2,02	1,81

Note. In Tables 3 and 4: *n* — the number of patients, % — syndrome occurrence rate; median+ — median of respective indices in patients having the complex of symptoms; median– — median of respective indices in patients without symptom complex; $p<0.05$.

Table 4. **Postoperative neurological symptoms in 29 patients with FM meningiomas. Medians of CSF circulation parameters at C2—C3 depending on the presence/absence of a certain symptom complex, as well as the significance of differences between the subgroups**

Symptom complex			Peak positive velocity			Peak negative velocity			Positive volume			Negative volume			Amplitude range, max..			Stroke volume	
	n	%	Median+	Median–	*p*	Median+	Median–	*p*	Median+	Median–	*p*	Median+	Median–	*p*	Median+	Median–	*p*	Median+	Median–
Cerebellar syndrome	11	37,9	8,21	9,7	0,6	8,5	9,68	0,67	0,56	0,8	0,76	0,7	0,6	0,59	17,86	19,31	0,62	1,2	1,47
Cerebral syndrome	7	24,1	9,8	9,63	0,85	9,65	9,65	0,85	0,62	0,8	0,7	0,88	0,6	0,45	17,3	19,31	0,99	1,31	1,2
Bulbar syndrome	9	31	8,21	9,7	0,6	8,5	9,68	0,68	0,8	0,62	0,82	0,87	0,52	0,28	17,86	19,31	0,63	1,52	1,2
Pyramidal disorders	4	13,8	11,85	8,88	0,1	10,25	8,92	0,36	0,3	0,77	0,17	0,52	0,61	0,7	21,3	17,52	0,19	0,82	1,21
Sensory disorders	8	27,6	11,55	7,46	0,03	11,65	8,35	0,02	0,75	0,73	0,83	0,65	0,61	0,55	24	17,03	0,02	1,14	1,26
Cervical syndrome	3	10,3	13,6	9,63	0,34	12,9	9,65	0,43	1,42	0,73	0,23	0,48	0,61	0,98	26,5	17,86	0,37	1,47	1,2
Dysfunction of XI	14	48,3	10,79	6,19	0,01	10,15	8,34	0,08	0,86	0,57	0,19	0,86	0,5	0,09	20,69	14,54	0,03	1,57	1,15

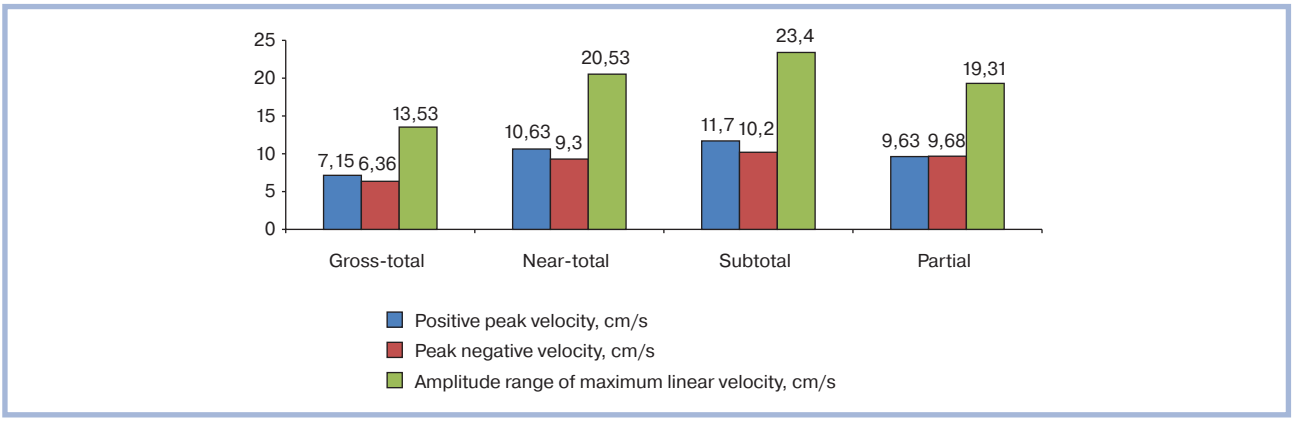

Fig. 12. **CSF circulation recovery as a function of the extent of tumor resection according to PC-MRI.**

We used the technique that was previously developed at the Burdenko Neurosurgical Institute and demonstrated in the article of N.V. Arutyunov reporting the study of CSF circulation in patients with type I Chiari malformation [26]. According to the findings of N.V. Arutyunov et al. (2009), all preoperative CSF circulation parameters in patients with type I Chiari malformation were significantly lower than normal values. After surgery, all CSF circulation characteristics significantly increase and reach normal level. In our study, the reverse trend was observed in patients with FM meningiomas before surgery: all CSF circulation parameters were above normal. Our data, demonstrating increase in velocity values of CSF circulation, are in agreement with hydrodynamic continuity law (Castelli's law), whereby the flow rate of the fluid in pipes is inversely proportional to their cross-section. In our opinion, increase in volumetric characteristics of CSF circulation is due to turbulent motion of the CSF below meningiomas (C2—C3). After surgery, velocity characteristics of CSF circulation (peak positive and negative velocity, amplitude range of the maximum linear velocity) in patients with FM meningiomas significantly decreased, but did not reach normal values; volumetric parameters (positive and negative volume, stroke volume) did not changed. Since the follow-up study was conducted 3—6 months after the operation, these CSF circulation characteristics can be attributed to the development of postoperative cicatrical changes.

Conclusion

According to PC-MRI, all preoperative CSF circulation parameters in patients with FMR meningiomas exceed normal values. The relationship between these parameters and tumor size and location was not established. We found only correlations between some parameters and clinical manifestations of the disease, which can indirectly indicate the role of tumor configuration in CSF circulation disorders. After the operation, velocity characteristics of CSF circulation decrease, volumetric characteristics remain unchanged.

Table 5. **Quantitative characteristics of CSF circulation at C2—C3 in 28 patients with FM meningiomas before tumor resection**

CSF circulation parameter	Median	Std.Dev.	Median	25,000 th	75,000 th
Positive peak velocity, cm/s	12,12	4,35	14,20	10,05	15,05
Peak negative velocity, cm/s	10,85	4,47	11,90	6,46	14,52
Positive volume, ml	1,06	0,47	1,01	0,82	1,44
Negative volume, ml	0,85	0,51	0,97	0,46	1,16
Amplitude range of maximum linear velocity, cm/s	22,97	8,16	23,70	17,27	29,26
Stroke volume, ml	1,92	0,80	1,91	1,56	2,28

Table 6. **Quantitative characteristics of CSF circulation at C2—C3 in 28 patients with FM meningiomas after tumor resection**

CSF circulation parameter	Median	Std.Dev.	Median	25,000 th	75,000 th
Positive peak velocity, cm/s	8,96	3,95	9,75	4,66	12,45
Peak negative velocity, cm/s	8,88	3,87	9,67	4,96	11,40
Positive volume, ml	0,80	0,48	0,78	0,42	1,18
Negative volume, ml	0,70	0,51	0,66	0,21	1,14
Amplitude range of maximum linear velocity, cm/s	17,84	7,65	19,56	9,71	24,05
Stroke volume, ml	1,50	0,90	1,27	1,04	2,15

Table 7. **Median of preoperative and postoperative quantitative characteristics of the CSF circulation at C2 —C3 and probability values in patients with FM meningiomas**

CSF circulation parameter	Median	25,000 th	75,000 th	Median	25,000 th	75,000 th	*p*-value
Positive peak velocity, cm/s	14,20	10,05	15,05	9,75	4,66	12,45	0,0058
Peak negative velocity, cm/s	11,90	6,46	14,52	9,67	4,96	11,40	0,039
Positive volume, ml	1,01	0,82	1,44	0,78	0,42	1,18	0,096
Negative volume, ml	0,97	0,46	1,16	0,66	0,21	1,14	0,29
Amplitude range of maximum linear velocity, cm/s	23,70	17,27	29,26	19,56	9,71	24,05	0,0072
Stroke volume, ml	1,91	1,56	2,28	1,27	1,04	2,15	0,12

Table 8. **Quantitative characteristics of CSF circulation (median and percentiles) at C2—C3 as a function of the extent of surgical intervention**

Parameter	Extent of tumor resection			
	Total	Near-total	Subtotal	Partial
Positive peak velocity, cm/s	7,15 (4,39—11,7)	10,63 (5,15—12,6)	11,7 (6,71—13,2)	9,63 (3,93—9,88)
Peak negative velocity, cm/s	6,36 (4,77−10,56)	9,3 (4,9—10,1)	10,2 (9,65—14,30)	9,68 (3,25—10,4)
Amplitude range of maximum linear velocity, cm/s	13,53 (9,25—22,13)	20,53 (9,88—21,5)	23,4 (16,36—27,4)	19,31 (7,27—20,28)

Decrease in these values does not depend on the completeness of tumor resection.

The small number of patients and differently directed changes in the velocity and volumetric parameters complicate interpretation of the results and indicate that routine use of PC-MRI in the treatment of FM meningiomas is inappropriate at this stage.

The lack of correlation between the completeness of tumor resection and recovery of CSF circulation parameters pathogenetically justifies the use of palliative surgery (partial resection, dural plasty, decompression of the craniovertebral junction) in the case of inoperable FM meningiomas.

There is no conflict of interest.

REFERENCES

1. Borba LA, de Oliveira JG, Giudicissi-Filho M, Colli BO. Surgical management of foramen magnum meningiomas. *Neurosurg Rev*. 2009;32:49-60.
   doi: 10.3171/2009.3.focus0924
2. Komotar RJ, Zacharia BE, McGovern RA, Sisti MB, Bruce JN, D'Ambrosio AL. Approaches to anterior and anterolateral foramen magnum lesions: a critical review. *J Craniovertebr Junction Spine*. 2010;1:86-99.
   doi: 10.4103/0974-8237.77672
3. George B, Lot G, Boissonnet H. Meningioma of the foramen magnum: A series of 40 cases. *Surg Neurol*. 1997;47:371-379.
   doi: 10.1016/s0090-3019(96)00204-2
4. Bassiouni H, Ntoukas V, Asgari S, Sandalcioglu EI, Stolke D, Seifert V. Foramen magnum meningiomas: clinical outcome after microsurgical resection via a posterolateral suboccipitalretrocondylar approach. *Neurosurgery*. 2006;59:1177-1187.
   doi: 10.1227/01.neu.0000245629.77968.37
5. Boulton MR, Cusimano MD. Foramen magnum meningiomas: Concepts, classifications, and nuances. *Neurosurg Focus*. 2003;14:10.
   doi: 10.3171/foc.2003.14.6.10
6. Goel A, Desai K, Muzumdar D. Surgery on anterior foramen magnum meningiomas using a conventional posterior suboccipital approach: a report on an experience with 17 cases. *Neurosurgery*. 2001;49:102-107.
   doi: 10.1227/00006123-200107000-00016
7. Kano T, Kawase T, Horiguchi T, Yoshida K. Meningiomas of the ventral foramen magnum and lower clivus: factors influencing surgical morbidity, the extent of tumour resection, and tumour recurrence. *Acta Neurochir (Wien)*. 2009;152:79-86.
   doi: 10.1007/s00701-009-0511-2
8. Flores BC, Boudreaux BP, Klinger DR, Mickey BE, Barnett SL. The far-lateral approach for foramen magnummeningiomas. *Neurosurg Focus*. 2013;35(6):E12.
   doi: 10.3171/2013.10.FOCUS13332
9. Kandenwein JA, Richter HP, Antoniadis G. Foramen magnum meningiomas − experience with the posterior suboccipital approach. *Br J Neurosurg*. 2009;23:3-39.
   doi: 10.1080/02688690802545932
10. Della Puppa A, Rustemi O, Scienza R. The suboccipital midline approach to foramen magnum meningiomas. *Acta Neurochir (Wien)*. 2015;157:869-873.
    doi: 10.1007/s00701-015-2381-0
11. Samii M, Gerganov VM. Surgery of extra-axial tumors of the cerebral base. *Neurosurgery*. 2008;62(3):1153-1168.
    doi: 10.1227/01.neu.0000333782.19682.76
12. Kornienko VN, Pronin IN. *Diafnosticheskaya neiroradiologiya*. M. 2008;1327. (In Russ.).
13. Martin BA, Labuda R, Royston TJ, Oshinski JN, Iskandar B, Loth F. Spinal subarachnoid space pressure measurements in an in vitro spinal stenosis model: implications on syringomyelia theories. *J Biomech Eng*. 2010;132:111007-111017.
    doi: 10.1115/1.4000089
14. Bogdanov EI, Heiss JD, Mendelevich EG, Mikhaylov IM, Haass A. Clinical and neuroimaging features of «idiopathic» syringomyelia. *Neurosurgery*. 2004;62:791-794.
    doi: 10.1212/01.wnl.0000113746.47997.ce
15. Haughton VM, Korosec FR, Medow JE, Dolar MT, Iskandar BJ. Peak systolic and diastolic CSF velocity in the foramen magnum in adult patients

with Chiari I malformations and in normal control participants. *AJNR Am J Neuroradiol*. 2003;24:169-176.

16. Armonda RA, Citrin CM, Foley KT, Ellenbogen RG. Quantitative cine-mode magnetic resonance imaging of Chiari I malformations: an analysis of cerebrospinal fluid dynamics. *Neurosurgery*. 1994;35:214-223.
doi: 10.1097/00006123-199408000-00006
17. Edelman R, Wedeen V, Davis K, Widder D, Hahn P, Shoukimas G, Brady TJ. Multiphasic MR imaging: a new method for direct imaging of pulsatile CSF flow. *Radiology*. 1986;161(3):779-783.
doi: 10.1148/radiology.161.3.3786732
18. Enzmann D, Pelc N. Normal flow patterns of intracranial and spinal cerebrospinal fluid defined with phase-contrast cine MR imaging. *Radiol*. 1991;178(2):467-474.
doi: 10.1148/radiology.178.2.1987610
19. Enzmann D, Pelc N. Cerebrospinal fluid flow measured by phase-contrast cine MR. *AJNR*. 1993;14(6):1301-1310.
20. Nitz W, Bradley W, Watanabe A, Lee RR, Burgoyne B, O'Sullivan RM, Herbst MD. Flow dynamics of cerebrospinal fluid: assessment with phase-contrast velocity MR imaging performed with retrospective cardiac gating. *Radiol*. 1992;183(2):395-405.
doi: 10.1148/radiology.183.2.1561340
21. Lisanti C, Carlin C, Banks K, Wang D. Normal MRI appearance and motion-related phenomena of CSF. *AJR*. 2007;188:716-725.
doi: 10.2214/ajr.05.0003
22. Stoquart EL, Sankari S, Lehmann P, Gondry-Jouet C, et al. Phase-Contrast MR Imaging Support for the Diagnosis of Aqueductal Stenosis. *AJNR*. 2009;30:209-214.
doi: 10.3174/ajnr.a1308
23. Battal B, Kocaoglu M, Bulakbasi N, Husmen G, Tuba Sanal H, Tayfun C. Cerebrospinal fluid flow imaging by using phase-contrast MR technique. *Br J Radiol*. 2011;84(1004):758-765.
doi: 10.1259/bjr/66206791
24. Gupta SK, Khosla VK, Chhabra R, Mukherjee KK. Posterior midline approach for large anterior/anterolateral foramen magnum tumours. *Br J Neurosurg*. 2004;18:164-167.
doi: 10.1080/02688690410001681028
25. Arnautović KI, Al-Mefty O, Husain M. Ventral foramen magnum meningiomas. *J Neurosurg*. 2000;92:71-80.
doi: 10.3171/spi.2000.92.1.0071
26. Arutyunov NV, Korniyenko VN, Reutov AA, Fadeyeva LM. Cerebrospinal fluid flow at the upper cervical spinal level in health and Chiari I malformation. *Vestnik Rentgenplogii i radiologii*. 2009;4-6:37-42. (In Russ.).
27. Henry-Feugeas M, Idy-Peretti I, Baledent O, Cornu P, Lejay H, Bittoun J, Schouman-Claeys AE. Cerebrospinal fluid flow waveforms: MR analysis in chronic adult hydrocephalus. *Invest Radiol*. 2001;36:146-154.
doi: 10.1097/00004424-200103000-00003
28. Hofman E, Warmuth-Metz M, Bendszus M, Solymosi L. Phase-contrast MR imaging of the cervical CSF and spinal cord volumetric motion analysis in patients with Chiari I Malformation. *AJNR*. 2000;21:151-158.
29. Meadows J, Kraut M, Guarnieri M, Haroun RI, Carson BS. Asymptomatic Chiari type I malformations identified on magnetic resonance imaging. *J Neurosurg*. 2000;92:920-926.
doi: 10.3171/jns.2000.92.6.0920

Commentary

In this article, the authors focus on a rare pathology, namely meningioma of the foramen magnum (FM) region, which accounts for 3.2% of all meningiomas, and CSF circulation status after surgical treatment, which is scarcely described in the literature.

The Materials and Methods summarizes the experience in 38 patients with anterolateral (29 patients), ventral (5), and dorsal (4) FM meningiomas. A total of 29 patients were operated on. All operated patients were examined before and after surgery. CSF circulation was studies using phase contrast MRI (PC-MRI).

The study demonstrated that the size and location of FM meningiomas did not significantly affect the characteristics of CSF circulation. Neurologic deficit correlated with CSF circulation parameters. Most importantly, the dynamics of recovery of CSF circulation parameters is the same regardless of the completeness of surgery. In all groups of operated patients, CSF circulation characteristics do not reach normal values as evidenced by PC-MRI, which pathogenetically justifies the use of palliative surgery (partial resection, dural plasty, decompression of the craniovertebral junction) in the case of inoperable meningiomas.

The article as a whole, references, and summary provide detailed presentation of the matter under investigation. This study included a sufficient number of patients, which makes it statistically significant, summarizes the experience with PC-MRI and the influence of radical surgery on the CSF circulation parameters in patients with FM meningiomas, and proves the possibility of palliative surgery.

L.M. Zaytsev (Moscow, Russia)