doi: 10.17116/engneiro201680621-31

Clinical and Morphological Characteristics, Diagnostic Criteria, and Outcomes of Surgical Treatment of TSH-secreting Pituitary Adenomas

L.I. ASTAF'EVA[1], B.A. KADASHEV[1], L.V. SHISHKINA[1], P.L. KALININ[1], D.V. FOMICHEV[1], M.A. KUTIN[1], I.A. AREF'EVA[1], L.K. DZERANOVA[2], YU.G. SIDNEVA[1], I.S. KLOCHKOVA[1], D.L. ROTIN[3]

[1]Burdenko Neurosurgical Institute, Moscow, Russia; [2]Endocrinology Research Center, Moscow, Russia; [3]Moscow Scientific Clinical Center, Moscow, Russia

Thyrotropinomas (TSH-secreting tumors) are a rare type of pituitary adenomas, which account for about 0.5—2.0% of all pituitary tumors. The criterion of thyrotropinoma includes visualization of the tumor along with normal or elevated blood level of the thyroid-stimulating hormone (TSH) and high level of free T4 (fT4) and free T3 (fT3).

Objective. The study was aimed at investigating clinical, diagnostic, and morphological characteristics and treatment outcomes of TSH-secreting pituitary tumors.

Material and methods. The study included 21 patients aged 15 to 67 years with pituitary adenoma and normal or elevated blood level of TSH in combination with elevated levels of fT4 and fT3, who were operated on at the Burdenko Neurosurgical Institute in the period between 2002 and 2015. The patients were tested for the levels of TSH, fT4, fT3, prolactin, cortisol, luteinizing hormone (LH), follicle-stimulating hormone (FSH), estradiol/testosterone, and insulin-like growth factor (IGF-1) before surgery, in the early postoperative period, and 6 months after surgery. The thyroid status was evaluated using the following reference values: TSH, 0.4—4.0 mIU/L; fT4, 11.5—22.7 pmol/L; fT3, 3.5—6.5 pmol/L. An immunohistochemical study of material was performed with antibodies to TSH, PRL, GH, ACTH, LH, FSH, and Ki-67 (MiB-1 clone); in 13 cases, we used tests with antibodies to type 2 and 5 somatostatin receptors and D2 subtype dopamine receptors.

Results. Thyrotropinomas were detected in patients aged 15 to 67 years (median, 39 years) with an equal rate in males (48%) and females (52%). Before admission to the Neurosurgical Institute, 11 (52%) patients were misdiagnosed with primary hyperthyroidism; based on the diagnosis, 7 of these patients underwent thyroid surgery and/or received thyrostatics (4 cases). Hyperthyroidism symptoms were observed in 16 (76%) patients. The blood level of TSH was 2.47—38.4 mIU/L (median, 6.56); fT4, 22.8—54.8 nmol/L (median, 36); fT3, 4.24—12.9 pmol/L (median, 9.66). Tumors were endosellar in 4 (19%) cases and the endo-extrasellar in 17 (91%) cases. Total tumor resection was performed in 7 (33%) patients. All these tumors were either endosellar or endo-suprasellar. No total resection was performed in patients with infiltrative growth of adenoma (invading the skull base structures). An immunohistochemical study of resected tumor specimens detected only TSH expression in 3 (14%) cases; 18 (86%) tumors were plurihormonal and secreted TSH and GH and/or PRL. Of 13 tumors, expression of the type 2 dopamine receptor was detected in 9 (69%) cases; expression of type 5 and type 2 somatostatin receptors was found in 6 (46%) and 2 (15%) cases, respectively.

Conclusion. Postoperative decrease in the TSH level to 0.1 mIU/L or less was the criterion of total tumor resection. Total resection was performed in 33% of patients, having only endosellar and endo-suprasellar tumors. In most cases, tumors were plurihormonal and secreted TSH and GH and/or PRL.

Keywords: thyrotropinoma, TSH-secreting pituitary adenoma, central hyperthyroidism, acromegaly, somatostatin analogues.

Abbreviations:

ACTH — adrenocorticotrophic hormone
AB — antibodies
IMH — immunohistochemical study
IGF-1 — insulin-like growth factor-1
LH — luteinizing hormone
OGTT — oral glucose tolerance test
PRL — prolactin
fT3 — free T3
fT4 — free T4
STH — somatotropic hormone
TRH — thyrotropin-releasing hormone
TSH — thyroid stimulating hormone, thyrotropic hormone
TSH-PA — TSH-secreting pituitary adenoma
FSH — follicle stimulating hormone
CAIT — chronic autoimmune thyroiditis
D2DR — D2 subtype dopamine receptors
L-T4 — levothyroxine
SSt2 — type 2 somatostatin receptors
SSt5 — type 5 somatostatin receptors

© Group of authors, 2016

e-mail: Last@nsi.ru

Thyrotropinomas (TSH-secreting tumors) are a rare type of pituitary adenomas, which account for about 0.5—2.0% of all pituitary tumors. The criterion of thyrotropinoma includes visualization of the tumor along with normal or elevated blood level of the thyroid-stimulating hormone (TSH) and high level of free T4 (fT4) and free T3 (fT3). Overproduction of TSH by these tumors leads to hyperstimulation of the thyroid gland and clinical presentation of so-called central hyperthyroidism. This TSH production is autonomous due to impaired down-regulation of thyroid hormones, which affects the hypothalamic-pituitary-thyroidal system. Low incidence of these tumors as well as sometimes insufficient doctors' awareness of clinical features and diagnosis of central hyperthyroidism can lead to hyperdiagnosis of Basedow's disease or other thyroid diseases involving hyperthyroidism, which can result in unreasonable thyroid surgery and/or therapy with radioactive iodine.

Material and methods

The study included patients with pituitary adenoma and normal or elevated blood level of TSH in combination with elevated levels of fT3 and fT4, who were operated on at the Burdenko Neurosurgical Institute during the period from 2002 to 2015. The group included 21 patients aged 15 to 67 years (median 39 years), 11 females (52%) aged 15 to 63 years (median 30 years) and 10 males (48%) aged 15 to 67 years (median 49 years).

All patients underwent MRI of the brain. All identified tumors were macroadenomas sized 16 to 64 mm in diameter (median 26 mm). We classifies them according to their growth pattern and location (**see Table**). Thus, endo-sellar and endo-suprasellar adenomas not invading skull base structures (10 cases) were considered as non-infiltrative. Endo-extrasellar tumors invading the skull base structures, including cavernous sinus, were considered as infiltrative (11 cases).

The patients were tested for the levels of TSH, fT4, fT3, prolactin, cortisol, LH, FSH, estradiol/testosterone, and, in 13 cases, IGF-1 before surgery and in the early postoperative period. In the case of high level of IGF-1, growth hormone level was additionally studies during oral glucose tolerance test. Thyroid status was evaluated using the following reference values: TSH, 0.4—4.0 mIU/L; fT4, 11.5—22.7 pmol/L; fT3, 3.5—6.5 pmol/L. At admission to the Burdenko Neurosurgical Institute, thyroid status of patients who had a history of thyroidectomy and patients treated with somatostatin analogues or thyrostatics was assessed prior to the thyroidectomy or beginning of medication. In patients with thyrotropinoma and primary hypothyroidism, evaluation was carried out during therapy with levothyroxine; high levels of free thyroid hormone fractions and high levels of TSH were the criteria for inclusion in the study.

The patients were operated on through the transsphenoidal approach in 18 cases, including 14 cases of endoscopic endonasal approach and 3cases of transcranial approach (cases 2, 8, and 9). One patient (case 9) was reoperated at the Burdenko Neurosurgical Institute for continued tumor growth after non-radical transcranial tumor resection 6 years before reoperation. Another patient (case 19) was previously operated on in other clinic and was admitted with tumor recurrence 18 months after surgery. In both cases, hormone level before the first operation is unknown.

Operating material was stained with hematoxylin and eosin using the standard procedure followed by thorough histological examination. Immunohistochemical study of the material was carried out using antibodies (ABs) to TSH, PRL, STH, ACTH, LH, FSH, and Ki-67 proliferation marker (MiB-1 clone). Tumors with Ki-67 MI expression of less than 3% were considered as non-aggressive, 3% or more — aggressive. In 13 cases, AT tests were carried out with type 2 and 5 somatostatin receptors and D2 subtypes dopamine receptors (D2DR).

Follow-up study was carried out in 12 patients. Follow-up time was 1 month to 7 years (median, 6 months).

Results

Clinical presentation of the disease included mainly symptoms of hyperthyroidism in 16 (76%) of patients, whose history was 1 to 13 years (median 4 years). Furthermore, we detected symptoms of mass effect of the tumor: visual impairment in 8 (38%) patients and cephalgic syndrome in 7 (33%). Two patients were admitted in grave condition with large tumors accompanied by occlusive symptoms due to compression of the third ventricle (case 2, 8).

Four of eight reproductive-age females had amenorrhea (in two of them it was primary); 4 female patients had normal menstrual function. Lactorrhea was observed in 3 females. Androgen deficiency was diagnosed in 3 males.

Psychopathology usually fit into the presentation of anxiety and phobic disorders in the form of neurotic syndrome (12 patients) and panic attacks (11). Emotional disturbances in the form of depression were observed only in 3 patients. Eight patients complained of fatigue and weakness, 8 — palpitations, 5 — anxiety, 11 — mood lability, 3 — sleep disorder, 3 — sweating, 3 — tremor, 2 — subfebrile temperature, 2 — weight loss. The patients often had a combination of the aforementioned complaints. Psychiatric symptoms were most often moderate (13 patients).

Seven patients (**see Table**) had a history of thyroid surgery (6 — hemithyroidectomy, one of these patients had been operated on twice; 1 — thyroidectomy).

Four patients received thyreostatic therapy; at the time of admission, 2 of them (cases 9 and 10) still received thyrostatics. In these patients, fT4 levels before treatment with thyrostatics were 27.4 and 54.8 nmol/L and TSH levels were 5.59 and 6.52 mIU/L, respectively. At the time of admission to the Burdenko Neurosurgical Institute, normalization of fT4 level to 17.5 and 22.0 nmol/L was accompanied by increase in TSH levels to 9.72 and 10.2 mIU/L, respectively.

Thyroid ultrasound was performed in 13 patients: diffuse goiter was detected in 4 patients, nodular goiter — 3, diffuse nodular goiter — 1, and thyroid hypoplasia was observed in 1 patient with secondary TSH-PA.

At admission, three patients received levothyroxine: one of them previously underwent thyroidectomy (case 8), two patients with chronic autoimmune thyroiditis (CAIT) had primary hypothyroidism. Despite the high dose of levothyroxine (200 and 175 μg) and high level of free fractions of the thyroid hormones, TSH level was high (cases 16 and 19). We regarded these tumors as secondary thyrotropinomas. One of them had previously been operated on at the other hospital and was admitted to the Burdenko Neurosurgical Institute with recurrent pituitary adenoma.

Three patients had symptoms of acromegaly (change in appearance, growth of extremities, etc), confirmed by the results of hormonal blood test (high levels of IGF-1 and absence of STH suppression below 1.0 ng/ml during the oral glucose tolerance test, OGTT).

In patients with TSH-PA, blood level of TSH was 2.47—38.4 mIU/L (median, 6.56), fT4 level — 22.8—54.8 nmol/L (median, 36), fT4 level — 4.24—12.9 pmol/L (median, 9.66).

We found no correlation between the levels of TSH and fT4 (**Fig. 1**), between the level of TSH and fT3, as well as fT4 and fT3.

IGF-1 was tested in 10 patients with no clinical symptoms of acromegaly, 2 of them had elevated levels of IGF-1. They were tested for STH during OGTT, suppression of STH below 1.0 ng/ml was found. Five (24%) patients had hyperprolactinemia from 528 to 2678 mIU/L (median, 758).

Two patients (one with TSH-PA and the other with mixed TSH-STH-secreting adenoma) were preoperatively treated with prolonged somatostatin analogues, which resulted in normalization of TSH, STH, and IGF-1 levels (cases 12 and 14).

All 21 patients had macroadenomas: 4 cases — endosellar, 6 cases — endo-suprasellar, not invading the skull base structures (non-infiltrative). In 11 patients, tumors invaded the skull base structures, including the cavernous sinus (infiltrative). When comparing the growth pattern of tumors in 7 patients having a history of thyroid surgery, we found that, in this group, infiltrative growth occurred in 5 (71%) cases, whereas in 14 patients, who had no previous thyroid surgery, infiltrative growth occurred in 6 (43%) cases. However, there were no statistical differences, when comparing tumor growth pattern in the groups of patients with and without history of thyroid surgery, as well as in various age and gender groups.

Postoperative TSH level was elevated in only 1 out of 21 patients. It decreased in 20 patients; in 10 cases, it was even lower than normal (0.01 ± 0.19 mIU/L), and in 10 patients it reached the normal range (0.68—2.9 mIU/L). Maximal reduction occurred on day 1 after operation. The rate of decrease in fT4 levels were significantly lower. Thus, fT4 level tested on day 1—3 after surgery remained high in all patients. However, subsequent measurements on day 5—7 days after surgery showed its normalization or reduction in most of the cases.

The tumor was totally resected only in patients with endosellar (3 cases) and endo-suprasellar (4) tumors. In the case of infiltrative tumor, there were no cases of total resection. We studies protocols of operations and concluded that thyrotropinomas were in most cases similar to other typical adenomas, they were rarely dense and well perfused. Intense venous bleeding occurred only in 2 cases during tumor resection from the cavernous sinus. Close adherence of the tumor with vessels and nerves was observed in 2 cases during transcranial operations. One patient had a large hemorrhagic cyst within the tumor.

We compared postoperative TSH levels in patients with radical and non-radical tumor resection. In the first case, TSH level measured in the early postoperative period was not detectable or no more than 0.1 mIU/L.

Normalization of TSH or its reduction to 0.1 mIU/L, as well as transient postoperative hypothyroidism, are not the criteria of completeness of tumor resection. Thus, normalization or reduction of serum level of TSH, fT4, and fT3 was observed in all patients even in the case of subtotal resection. However, further follow up of 5 patients with postoperative euthyroidism and tumors remnants showed that 4 patients had elevated levels of TSH and/or fT4 6—12 months after surgery; one patient with mixed STH-TSH-secreting tumor maintained euthyroidism, but the levels of STH and IGF-1 remained high. These patients underwent stereotactic radiotherapy of residual tumor tissue.

Fig. 2 shows the dynamics of TSH and fT4 in patient *A.*, 21 years old, with non-radical tumor resection, **Fig. 3** shows changes in the level of TSH and fT4 in patient B., 38 years old, with radical tumor resection.

As can be seen from **Fig. 2**, subtotal tumor resection in patient A. led to decrease in TSH level to 0.52 mIU/L on day 1 after the operation and development of transient hypothyroidism. However, euthyroid state was diagnosed in 1 month, and recurrence of hyperthyroidism occurred in 1 year. The patient underwent a course of stereotactic radiation therapy followed by remission of the disease. TSH level below 0.1 mIU/L was considered as the criterion of radical tumor resection.

Summary table of the main data of 21 patients with thyrotropinoma

	Prior to adenomectomy and treatment with thyrostatics and/or SA in the early postoperative period and in 6—18 months								After pituitary adenomectomy					IMG characteristics of resected tumors*						
S/N	Sex	Age, years	History of treatment	Thyroid status	TSH, mIU/L	fT4, pmol/L	PRL, mIU/L	Tumor growth pattern	TSH, mIU/L	fT4, pmol/l	MRI signs of tumor remnants	Thyroid status	Treatment	TSH	PRL	STH	DR-D2	Sst2	Sst5	Ki-67, %
1	F	25	-	HyperT	2,71	43,17	266	Inf	0,19	20,60	ND	ND		+	+	+	+	–	+	0—1
2	F	15	-	HyperT	3,15	37,00	147	Inf	2,35	30,40	Yes	HyperT	RT	+	–	–	+	–	–	0—1
3	F	26	-	HyperT	4,05	31,70	850	Non-inf	<0,01	11,70	No	HypoT	L-T4	+	+	+	ND	ND	ND	2
4	M	38	-	HyperT	4,28	23,60	420	Non-inf	0,06	28,30	No	HypoT	L-T4	+	+	+	ND	ND	ND	3
5	M	67	-	HyperT	4,75	39,50	133	Non-inf	0,09	17,30	No	HypoT	L-T4	+	+	+	ND	ND	ND	3
6	M	45	HME	HyperT +ACRO	5,01	39,20	134	Non-inf	0,92	22,30	ND	ND		+	+	+	ND	ND	ND	5
7	F	30	-	HyperT	5,21	40,50	273	Non-inf	<0,01	10,40	No	HypoT	L-T4	+	+	+	ND	ND	ND	5
8	M	39	-	HyperT	5,59	20,56	420	Inf	2,90	21,50	ND	ND		+	–	–	+	–	–	0—1
9	F	56	HME, TS	HyperT	5,59	27,40	2678	Inf	2,40	21,30	Yes	ND		+	+	+	+	–	–	0—1
10	M	21	TS	HyperT	6,52	54,80	237	Inf	0,52	33,11	Yes	HyperT	RT	+	–	–	–	–	–	0—1
11	M	34	-	HyperT	6,56	36,40	528	Inf	2,13	21,50	ND	ND		+	–	+	–	–	–	0—1
12	M	65	HME, SA	HyperT	7,50	26,90	280	Inf	1,12	11,80	ND	ND		+	+	+	ND	ND	ND	0—1
13	M	59	HME	HyperT +ACRO	7,70	36,10	148	Inf	0,14	10,50	Yes	EuT+ ACRO	SA,RT	+	+	+	ND	ND	ND	5
14	M	53	SA	HyperT	7,96	28,86	151	Non-inf	0,10	15,10	No	EuT	No	+	+	+	+	–	+	2
15	F	33	-	HyperT	10,87	39,73	1909	Inf	0,16	16,90	ND	ND		+	+	+	+	–	+	0—1
16	F	39	-	HypoT	13,50	22,80	705	Non-inf	0,10	13,00	No	HypoT	L-T4	+	+	+	ND	ND	ND	3
17	F	15	-	HyperT	13,96	23,70	540	Non-inf	0,01	10,90	No	HypoT	L-T4	+	–	+	+	–	+	5
18	F	63	TE	HypoT	22,93	28,30	758	Non-inf	1,44	9,80	ND	ND		+	+	–	–	–	+	0—1
19	F	21	-	HypoT	27,90	24,50	288	Non-inf	2,47	27,20	No	EuT	L-T4	+	+	–	+	–	+	5
20	F	56	HME, TS	HyperT	28,10	36,20	483	Inf	4,20	24,90	Yes	HyperT	RT	+	–	+	+	+	–	0—1
21	F	60	HME, TS	HyperT +ACRO	38,40	52,80	499	Inf	1,60	24,50	ND	ND		+	–	+	–	+	–	0—1

Note. HME — hemithyroidectomy; TE — thyroidectomy; TS — thyrostatics; HyperT — hyperthyroidism; HypoT — hypothyroidism; EuT euthyroid; ACRO — acromegaly, the active phase; Inf — infiltrative tumor; Non-inf — non-infiltrative tumor; ND — no data; L-T4 — levothyroxine; SA — somatostatin analogues; RT — radiotherapy. * no cases of expression of LH, FSH, ACTH were detected.

As can be seen from Fig. 3, radical tumor resection in patient B. was accompanied by decrease in TSH level to 0.06 mIU/L on day 1 after surgery and persistent hypothyrosis. Disease remission was observed throughout the whole follow-up period (2 years). The patient was administered with levothyroxine 1 month after surgery.

Four patients with radical tumor resection developed panhypopituitarism, which persisted 6—18 months after surgery (secondary hypothyroidism, hypocorticism, hypogonadism, STH-deficiency); in 3 of them, it occurred in combination with diabetes insipidus.

IMH-study of resected tumor samples showed that all tumor were stained with AB to TSH; expression of only TSH was detected in 3 (14%) cases ("pure" TSH-secreting tumors), in 18 (86%) cases, tumors were plurihormonal: 2 cases demonstrated expression of TSH and PRL, 4 cases — TSH and STH, 12 cases — TSH, STH, and PRL (Fig. 4).

In 4 (29%) out of 14 cases with expression of PRL, there was increased blood level of PRL before surgery (758 mIU/L, 850 mIU/L, 1909 mIU/L, 2678 mIU/L); the remaining 10 (71%) tumors were accompanied by normoprolactinemia (133—288 mIU/L). Tree (19%) out of 16 patients with STH expression in tumor tissue were diagnosed with acromegaly (see Table).

Expression of type 2 dopamine receptors (D2DR) was detected in 9 (69%) of the 13 tumors, type 5 somatostatin receptor (SSt5) — 6 (46%), type 2 somatostatin receptor (SSt2) — 2 (15%) (see Table).

In 5 of 9 cases, D2DR expression occurred in combination with expression of PRL. In 4 of 6 cases, SSt5 expression was accompanied by STH expression. Two tumors with SSt2 expression were also associated with expression of STH, however, there were no cases of adenoma with concomitant expression of SSt5 and SSt2. The patients, who preoperatively received somatostatin analogues with a positive effect in the form of normalization of TSH and fT4 levels, demonstrated expression of TSH and STH (case 12) and SSt5 (case 14) in tumors.

There was no relationship between expression of PRL and dopamine receptors, as well as STH and somatostatin receptors in tumor cells.

The group average Ki-67 MI was 0—5% (median 1%), it was less than 3% in 13 cases, 3% or more in 8 cases. No statistical difference was found when analyzing the proliferative activity of the pituitary tumor (Ki-67 MI) in patients who previously underwent thyroid surgery and not operated patients **(see Table)**.

Discussion

TSH-PA accounts for 0.5—2% of all pituitary tumors [1]. The first case of hyperthyroidism and increase in sella dimensions was described in 1960. [2]. In 1970, S. Hamilton et al. [3] described TSH-PA with proved TSH measurement using radioimmunoassay. Previously, these tumors were considered casuistic and were detected at the stage of large invasive pituitary macroadenomas. However, the discovery of supersensitive hormonal methods and high-resolution neuroimaging techniques facilitated detection of TSH-PA at the stage of small tumors. Recently published data show that the incidence of TSH-PA in European countries may be 0.28 cases per 1 million population [4]. The incidence of TSH-PA is equal in males and females, in contrast to the predominance of females among the patients with thyroid diseases [5]. Familial cases of TSH-PA were described within MEN-1 [6] and in FIPA-families (familial isolated pituitary adenoma associated with AIP gene mutation) [7].

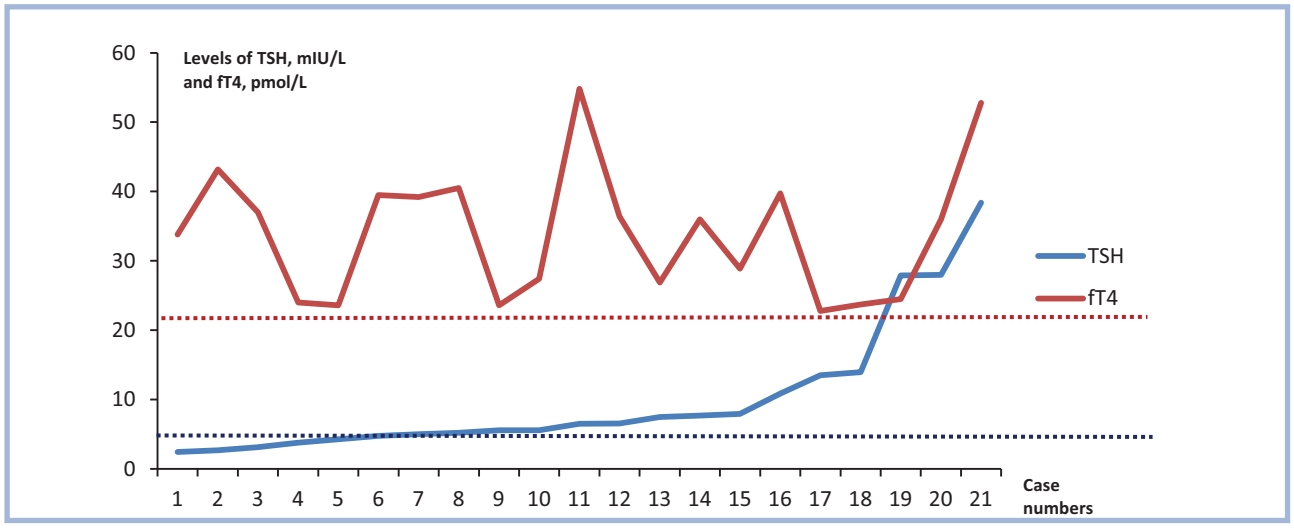

Fig. 1. **Preoperative blood level of TSH and fT4 in patients with thyrotropinoma.**
Dotted lines show the upper limits of reference values for both parameters. No correlation between blood levels of TSH and fT4 were found.

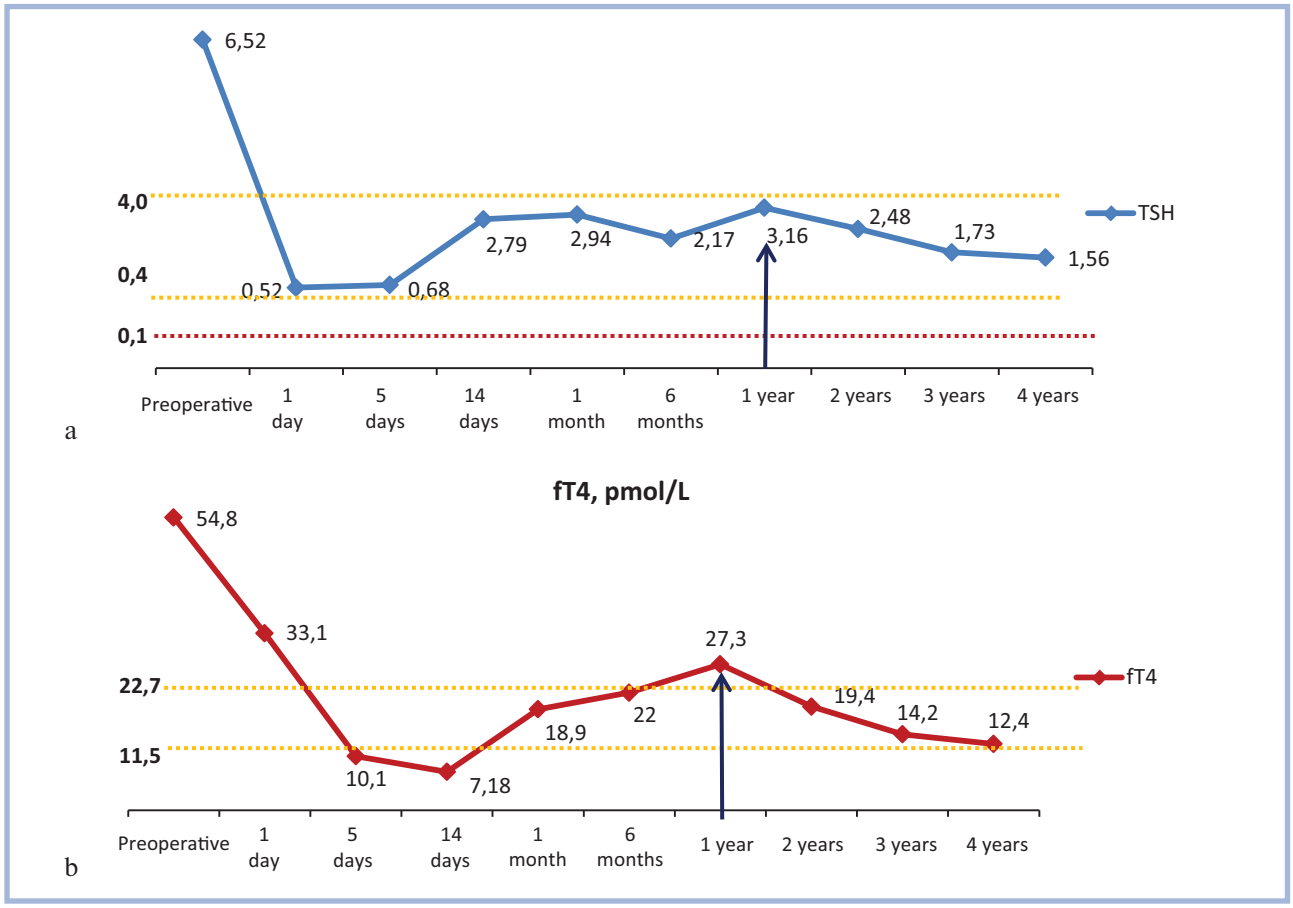

Fig. 2. **Patient *A.*, 21 years old, with non-radical tumor resection (case 10).**

a — dynamics of TSH level; b — dynamics of fT4 level (yellow dotted line show upper and lower limits of reference values of blood level of TSH and fT4, respectively; red dotted line shows the threshold, below which TSH values correspond to completeness of surgery).

TSH-PA occurs in various age groups of patients from 8 to 84 years [8—10]. However, most of the cases described in the literature occurred in patients aged 50—60 years [1]. In our study, the average age of males was 49 years, females were younger, their average age was 30 years.

The criteria of TSH-secreting pituitary tumors include its visualization and normal or elevated blood levels of TSH along with elevated levels of fT4 and fT3. The symptoms of hyperthyroidism in combination with these hormonal values exclude Graves disease [11]. In difficult diagnostic cases, when there is no obvious clinical hyperthyroidism and TSH-PA cannot be reliably diagnosed based on the analysis of basal levels of hormones, functional tests are used (test with thyrotropin-releasing hormone, TSH), triiodothyronine suppression assay, assessment of the molar ratio of α-subunit/TSH). Differential diagnosis with the syndrome of thyroid hormone resistance, which is also characterized by high levels of fT4 and fT3 in combination with high or normal level of TSH is the most challenging problem. This syndrome is characterized by reduced sensitivity of peripheral tissues to thyroid hormones; it is an autosomal dominant hereditary disease caused by mutation in the gene encoding β-type receptor to thyroid hormones [1, 12]. Pituitary adenoma detected by MPT-study in most cases confirms TSH-PA. However, there are reported cases of combination of the syndrome of thyroid hormone resistance with TSH-secreting pituitary microadenomas and pituitary incidentaloma [13].

According to the literature [14], normal level of TSH is detected in approximately 30% of cases of TSH-PA. Despite the TSH-dependent genesis of hyperthyroidism, we found no direct correlation between the level of fT4 and TSH in our study. Similar data are reported in the review by R. Beck-Peccoz [1].

Normal level TSH along with high levels of fT3 and fT4 can be explained by increase in biological activity of TSH molecule [15]. TSH molecules secreted by pituitary tumors are heterogeneous and may have normal, reduced, or increased ratio between their biological and immunological activity, which that can be associated with post-translation changes in the tumor cell [16, 17]. Normal blood level of TSH in some TSH-PA patients justifies the need for testing both TSH and free fractions of thyroid hormones in all patients with pituitary adenoma.

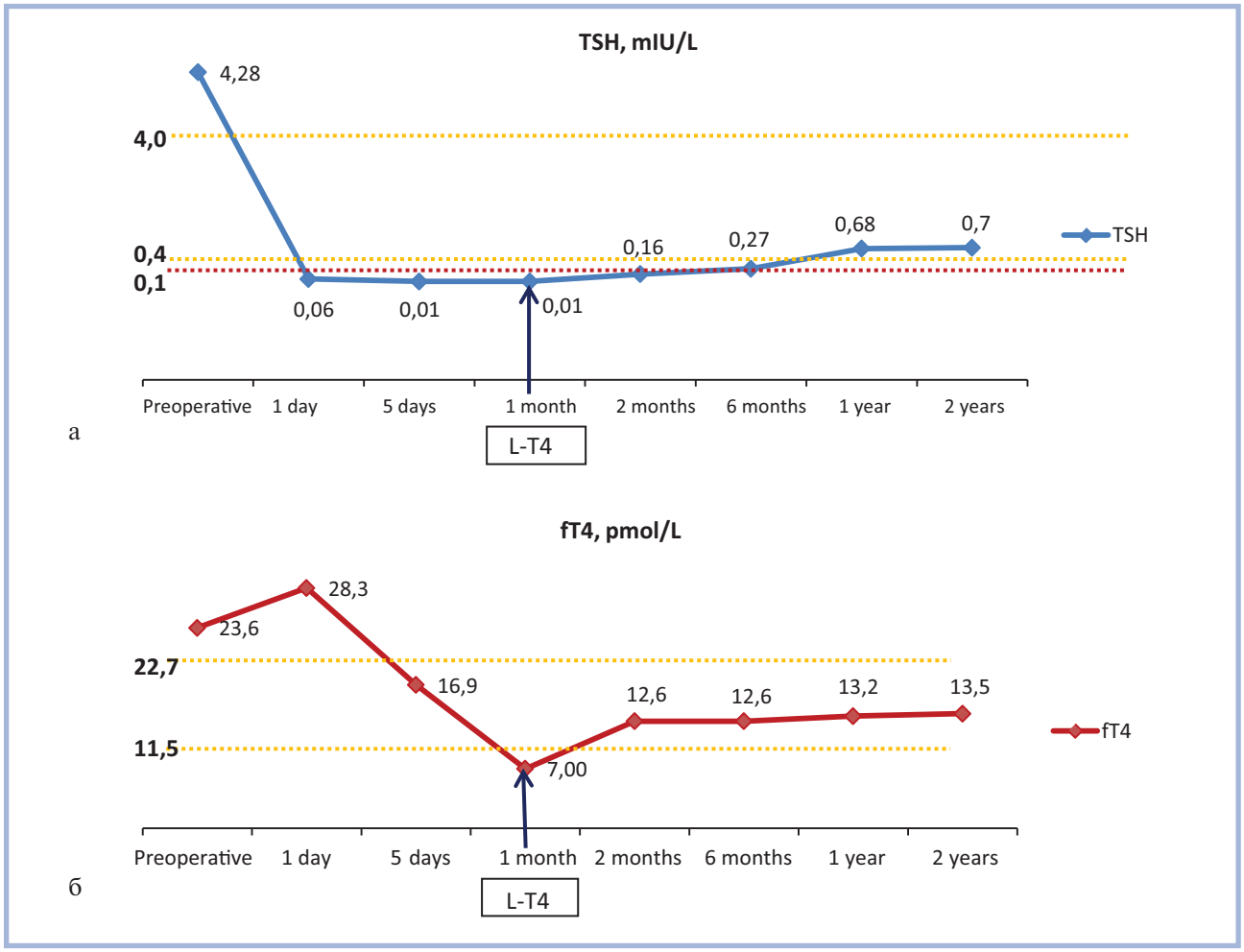

Fig. 3. **Patient *B.*, 38 years old, who underwent radical tumor resection (case 4).**

a — dynamics of TSH level; b — dynamics of fT4 level (yellow dotted line show upper and lower limits of the reference values of blood level of TSH and fT4, respectively, red dotted line shows the threshold, below which TSH values correspond to completeness of surgery).

Cases of TSH-secreting tumors associated with chronic autoimmune thyroiditis have been reposted in the literature [18—20]. Normal or elevated level of TSH along with high level of fT4 and fT3 [18] is also considered a diagnosis criterion of TSH-PA in patients with primary hypothyroidism resulting from CAIT or thyroidectomy, who receive replacement therapy with levothyroxine. We reported 2 cases of TSH-PA in CAIT patients. Despite the high dosed of levothyroxine and elevated level of fT4, TSH level remained high. MRI study detected decrease in tumor size in one case, and relapse after previous pituitary adenomectomy in the other. Histological examination confirmed the presence of mixed pituitary adenoma with expression of TSH, PRL, and STH in both cases. The role of long-lasting increase in TSH level and pituitary hyperplasia in CAIT patients in the pathogenesis of TSH-PA was discussed in the literature [19, 20].

Clinical presentation of TSH-PA consists of symptoms of hyperthyroidism and mass-tumor effect. Symptoms of hyperthyroidism were detected in most (76%) patients and were similar to manifestation of primary hyperthyroidism, but they were characterized by milder course and absence of other autoimmune syndromes, which are common in diffuse toxic goiter (endocrine ophthalmopathy, pretibial myxedema, and acropathy). Prevalence of circulating antibodies to thyreoglobulin and thyroid peroxidase in TSH-PA patients is similar to that in the general population. However, the literature [21, 22] described the patients who developed Graves' disease after resection of pituitary adenoma; bilateral exophthalmos in combination with autoimmune thyroiditis. In most patients, hyperstimulation of thyroid with TSH results in diffuse increase in thyroid size, in 72% of cases — to formation of single or multiple nodules [1]. Goiter is usually detected even in patients who previously underwent partial thyroidectomy due to growth of residual thyroid tissue. Differentiated thyroid cancer was reported in several patients with TSH-PA [23—26]. In patients with thyroid nodules, monitoring of thyroid nodules and thin-needle aspiration biopsy are required.

In most cases of TSH-PA reported in the literature, where patients were first misdiagnosed with primary

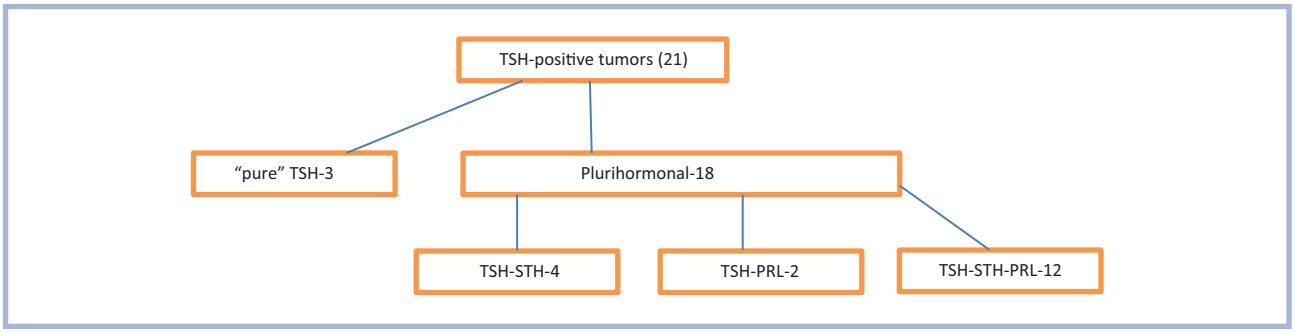

Fig. 4. **Immunohistochemical expression of hormones by TSH-secreting pituitary adenomas.**

hyperthyroidism (Graves' disease), they often had a history of thyroid surgery and/or radioactive iodine therapy. In these cases, tumors often become more aggressive and demonstrate infiltrative growth pattern. Decrease in blood levels of circulating thyroid hormones resulting from this treatment leads to activation of tumor growth by a mechanism similar to development Nelson syndrome after bilateral adrenalectomy during treatment of Cushing's disease [1].

Likewise, more than half (52%) of patients in our study were misdiagnosed with primary hyperthyroidism. For this reason, most of them underwent thyroid surgery and/or received thyreostatic therapy. In our study, we found no clear statistical differences in the infiltrative growth pattern depending on the previous thyroid surgery. This is probably due to the general late diagnosis of TSH-PA, when they are detected at the stage of large tumor. Nevertheless, 7 patients were operated on at our institution over the last 2 years (2014—2015), and only 3 (43%) of them had endosellar adenomas and hyperthyroidism without symptoms of tumor mass effect, whereas during the period from 2002 to 2013, most patients, 13 (93%) of 14, had large tumors and were diagnosed at the stage of tumor mass effect with pronounced visual or other neurological disorders. It is likely that in the future, given the use of ultra-sensitive hormonal methods, as well as better doctors' awareness of these rare tumors, the rate of early detection of TSH-PA at the stage of small-size tumor will increase.

Most of TSH-PA secret not only TSH, but also other pituitary hormones, mainly STH and PRL. This may be due to the fact that somatotropic, lactotropic, and thyrotropic cells have a common progenitor cell. A rare type of mixed TSH/gonadotropin secreting adenoma is described in the literature without hypersecretion of ACTH in the blood; the mechanism of occurrence of these tumors have not been studied, because thyrotropic and gonadotropic cells have different progenitor cells [1]. Clinically silent thyrotropinomas with TSH expression but without increase in blood level of TSH and clinical presentation of hyperthyroidism have been reported [27].

In our study, most tumors, 18 (86%), were plurihormonal with preferential secretion of TSH, STH, and/or PRL. None of the tumors secreted gonadotropin and ACTH. "Pure" TSH-secreting tumors were found only in 3 (14%) cases. Tumors with concomitant expression of PRL or STH were associated with increased blood level of RLP and clinical presentation of acromegaly only in 4 (29%) and 3 (19%) cases, respectively. The absence of clinical presentation of hyperprolactinemia and/or acromegaly in other patients with expression of PRL and/or STH was probably due to secretion of biologically inactive forms of PRL and/or STH.

According to the literature [1], most TSH-PAs demonstrate expression of various receptors, including receptors to TRH, dopamine, and somatostatin. Expression of somatostatin receptors is often detected in TSH-PA, especially in mixed STH-TSH-secreting tumors. This explains the effective ability of somatostatin analogs to lower TSH levels in patients with these tumors [28, 29]. In our study, SSt5 expression was detected in 46% of cases and in most cases, it was accompanied by STH expression in the tumor, while SSt5 expression was rarely detected.

Surgery followed by radiotherapy is the basic method of treatment for TSH-PA in the case of non-radical resection [30, 31]. The literature provides no strict criteria for remission after surgical treatment of thyrotropinomas. However, clinical remission of hyperthyroidism, normalization of thyroid hormone levels, and regression of neurological symptoms are considered as remission criteria. At the same time, these biochemical and clinical criteria can be transitory and are not considered as indicators of complete resection [1]. Normalization of blood level of TSH also cannot be an indicator of completeness, especially in patients with normal preoperative level of TSH. Normalization of α-subunit and/or the molar ratio of α-subunit and TSH may be used to assess the effectiveness of therapy [32, 33]. Nevertheless, these two parameters are of low sensitivity and are not applicable in patients with normal preoperative levels. Triiodothyronine suppression test and TRH stimulation test, which have optimal sensitivity and specificity, were suggested as the most valid tests for completeness of tumor resection [32, 33].

Undetectable blood level of TSH may be a good indicator of radical resection. It is important to clarify

that virtually undetectable TSH level should be understood as its level below the functional sensitivity threshold of detection method (<0.01 mIU/L). Indeed, in our series of observations, postoperative decrease in TSH levels below 0.01 mIU/L was characteristic of completely resected tumors. However, all these cases were accompanied by the development of panhypopituitarism, including hypothyroidism, which required administration of levothyroxine. Patients with postoperative TSH levels of 0.01-0.1 mIU/L remained euthyroid during the follow-up period (6—18 months). Therefore, we arbitrarily defined TSH level of 0.1 mIU/L and below as a marker of radical tumor removal. However, these patients should be followed in the future since delayed relapse of hyperthyroidism can occur.

Although adenomectomy is currently the treatment of choice, treatment with somatostatin analogues is believed to be effective in reducing TSH level, normalization of fT4 and fT3 levels, and restoring euthyrosis in 90% of cases [30, 34, 35]. In our study, preoperative therapy with somatostatin analogues in 2 patients successfully normalized euthyrosis and the levels of TSH and fT4.

The literature provides no data on the incidence of TSH-PA recurrence. We observed 2 cases of continued tumor growth in previously operated patients, which required reoperation. In our series of observations, none of the patients operated on at the Burdenko Neurosurgical Institute had continued tumor growth during the aforementioned follow-up period. Given the possibility of delayed recurrence of hyperthyroidism in patients with non-radical tumor resection, the possibility of stereotactic irradiation of residual tumor tissue should be considered even in the cases of euthyroid state. In the case of complete resection of the tumor and the development of hypothyroidism, tumor recurrence is unlikely at least during the first years after the surgery.

Conclusion

In summary, TSH-secreting tumors are rare representatives of pituitary adenomas. Early diagnosis of these tumors and differential diagnosis, which rule out other conditions accompanied by hyperthyroidism, are of key importance. Surgical treatment is currently the main method of treatment, however radical removal of infiltrative tumors is impossible. Postoperative TSH level of no more than 0.1 mIU/L can be considered as the criterion of radical removal. It should be noted that transient euthyrosis often occurs in patients with non-radical tumor resection. However, the likelihood of recurrence of hyperthyroidism nessessitates considering the question of stereotactic irradiation of residual tumor tissue. Therapy with somatostatin analogs can be effective to achieve euthyrosis.

There is no conflict of interest.

REFERENCES

1. Beck-Peccoz P, Persani L, Lania A. In: De Groot LJ, Beck-Peccoz P, Chrousos G, Dungan K, Grossman A, Hershman JM, Koch C, McLachlan R, New M, Rebar R, Singer F, Vinik A, Weickert MO. (editors). Endotext [Internet]. South Dartmouth (MA): MDText.com, Inc. *Thyrotropin-Secreting Pituitary Adenomas*. 2000-2015 May.
2. Jailer JW, Holub DA. Remission of Graves' disease following radiotherapy of a pituitary neoplasm. *Am J Med*. 1960;28:497-500.
   http://dx.doi.org/10.1016/0002-9343(60)90181-189
3. Hamilton C, Adams LC, Maloof F. Hyperthyroidism due to thyrotropin-producing pituitary chromophobe adenoma. *N Engl J Med*. 1970;283:1077-1080.
   http://dx.doi.org/10.1056/nejm197011122832003
4. Önnestam L, Berinder K, Burman P, Dahlqvist P, Engström BE, Wahlberg J, Filipsson Nyström H. National incidence and prevalence of TSH-secreting pituitary adenomas in Sweden. *J Clin Endocrinol Metab*. 2013 Feb;98(2):626-635.
   http://dx.doi.org/10.1210/jc.2012-3362
5. Beck-Peccoz P, Brucker-Davis F, Persani L, Smallridge RC, Weintraub BD. Thyrotropin-secreting pituitary tumors. *Endocr Rev*. 1996;17:610-638.
   http://dx.doi.org/10.1210/edrv-17-6-610
6. Taylor TJ, Donlon SS, Bale AE, Smallridge RC, Francis TB, Christensen RS, Burma KD. Treatment of a thyrotropinoma with octreotide-LAR in a patient with multiple endocrine neoplasia-1. *Thyroid*. 2000;10:1001-1007.
   http://dx.doi.org/10.1089/thy.2000.10.1001
7. Daly AF, Tichomirowa MA, Petrossians P, Heliövaara E, Jaffrain-Rea ML, Barlier A, Naves LA, Ebeling T, Karhu A, Raappana A, Cazabat L, De Menis E. Clinical characteristics and therapeutic responses in patients with germ-line AIP mutations and pituitary adenomas: an international collaborative study. *J Clin Endocrinol Metab*. 2010 Nov;95(11):E373-E383.
   http://dx.doi.org/10.1210/jc.2009-2556
8. Beck-Peccoz P, Lania A, Persani L. Chapter 24. TSH-producing adenomas. In: Jameson JL, DeGroot LJ (eds). 7th edition. W.B. Saunders Pub. USA. *Endocrinology*. 2015;266-274.
   http://dx.doi.org/10.1016/b978-0-323-18907-1.00015-9
9. Nakayama Y, Jinguji S, Kumakura S, Nagasaki K, Natsumeda M, Yoneoka Y, Saito T, Fujii Y. Thyroid-stimulating hormone (thyrotropin)-secretion pituitary adenoma in an 8-year-old boy: case report. *Pituitary*. 2012 Mar;15(1):110-115.
   http://dx.doi.org/10.1007/s11102-010-0275-y
10. Mazerkina N, Trunin Y, Gorelyshev S, Golanov A, Kadashev B, Shishkina L, Rotin D, Karmanov M, Orlova E. J Pediatr Thyrotropin-secreting pituitary adenoma in an 11-year-old boy with type 1 autoimmune polyglandular syndrome. *Endocrinol Metab*. 2016 Feb 1;29(2):237-240.
    doi: 10.1515/jpem-2015-0018
11. Kadashev BA, Astaf'eva LI. *Adenomy gipofiza (klinika, diagnostika, lechenie)*. Tver'. 2007;31-46. (In Russ.).
12. Prgijalkovskaja EG, Gasisova DO, Grigoriev AYu, Voronkova IA, Tyulpakov AN, Rochinskaja LYa. Thyrotropin-producing adenoma: diagnostic challenges (Case report). *Clinical and experimental thyroidology*. 2011;7(2):68-73. (In Russ.).
    http://dx.doi.org/10.14341/ket20117268-73
13. Teng X, Jin T, Brent GA, Wu A, Teng W, Shan ZA. Patient With a Thyrotropin-Secreting Microadenoma and Resistance to Thyroid Hormone (P453T). *J Clin Endocrinol Metab*. 2015 Jul;100(7):2511-2514.
    doi: 10.1210/jc.2014-3994. http://dx.doi.org/10.1210/jc.2014-3994
14. Beck-Peccoz P, Piscitelli G, Amr S, Ballabio M, Bassetti M, Giannattasio G, Spada A, Nissim M, Weintraub BD, Faglia G. Endocrine, biochemical, and morphological studies of a pituitary adenoma secreting growth hormone, thyrotropin (TSH), and a-subunit: evidence for secretion of TSH with increased bioactivity. *J Clin Endocrinol Metab*. 1986;62:704-711.
    http://dx.doi.org/10.1210/jcem-62-4-704

15. Gesundheit N, Petrick P, Nissim M, Dahlberg PA, Doppman L, Emerson CH, Braverman LE, Oldfield EH, Weintraub BD. Thyrotropin-secreting pituitary adenomas: clinical and biochemical heterogeneity. *Ann Intern Med*. 1989;111:827-835.
http://dx.doi.org/10.7326/0003-4819-111-10-827
16. Magner JA, Klibanski A, Fein H, et al. Ricin and lentil lectin affinity chromatography reveals oligosaccharide heterogeneity of thyrotropin secreted by 12 human pituitary tumors. *Metabolism*. 1992;41:1009-1015.
http://dx.doi.org/10.1016/0026-0495(92)90129-x
17. Beck-Peccoz P, Persani L. Variable biological activity of thyroid-stimulating hormone. *Eur J Endocrinol*. 1994;131:331-340.
http://dx.doi.org/10.1530/eje.0.1310331
18. Losa M, Mortini P, Minelli R, Giovanelli M. Coexistence of TSH-secreting pituitary adenoma and autoimmune hypothyroidism. *J Endocrinol Invest*. 2006 Jun;29(6):555-559.
http://dx.doi.org/10.1007/bf03344147
19. Iskandar SB, Supit E, Jordan RM, Peiris AN. Thyrotropin-secreting pituitary tumor and Hashimoto's disease: a novel association. *South Med J*. 2003;96:933-936.
http://dx.doi.org/10.1097/01.smj.0000054784.64420.8b
20. Ma W, Ikeda H, Watabe N, Kanno M, Yoshimoto T. A plurihormonal TSH-producing pituitary tumor of monoclonal origin in a patient with hypothyroidism. *Horm Res*. 2003;59:257-261.
http://dx.doi.org/10.1159/000070227
21. Lee MT, Wang CY. Concomitant Graves hyperthyroidism with thyrotrophin-secreting pituitary adenoma. *South Med J*. 2010 Apr;103(4):347-349.
http://dx.doi.org/10.1097/smj.0b013e3181d3ce93
22. Azukizawa M, Morimoto S, Miyai K, Miki T, Yabu Y, Amino N, Kuma K, Kumahara Y. TSH-producing pituitary adenoma associated with Graves' disease. In: Stockigt JR, Nagataki S. (eds). *Thyroid Research*. 1980;8:645-648.
23. Nguyen HD, Galitz MS, Mai VQ, Clyde PW, Glister BC, Shakir MK. Management of coexisting thyrotropin/growth-hormone-secreting pituitary adenoma and papillary thyroid carcinoma: a therapeutic challenge. *Thyroid*. 2010 Jan;(1):99-103.
http://dx.doi.org/10.1089/thy.2009.0160
24. Gasparoni P, Rubello D, Persani L, Beck-Peccoz P. Unusual association between a thyrotropin-secreting pituitary adenoma and a papillary thyroid carcinoma. *Thyroid*. 1998;8:181-183.
http://dx.doi.org/10.1089/thy.1998.8.181
25. Poggi M, Monti S, Pascucci C, Toscano V. A rare case of follicular thyroid carcinoma in a patient with thyrotropin-secreting pituitary adenoma. *Am J Med Sci*. 2009 Jun;337(6):462-465.
http://dx.doi.org/10.1097/maj.0b013e3181949948
26. Perticone F, Pigliaru F, Mariotti S, Deiana L, Furlani L, Mortini P, Losa M. Is the incidence of differentiated thyroid cancer increased in patients with thyrotropin-secreting adenomas? Report of three cases from a large consecutive series. *Thyroid*. 2015 Apr;25(4):417-424.
27. Lim EM, Bhagat CI, Walsh J. Asymptomatic thyrotropin-secreting pituitary microadenoma. *Intern Med J*. 2001;31:428-429.
http://dx.doi.org/10.1046/j.1445-5994.2001.00083.x
28. Gatto F, Grasso LF, Nazzari E, Cuny T, Anania P, Di Somma C, Colao A, Zona G, Weryha G, Pivonello R, Ferone D. Clinical outcome and evidence of high rate post-surgical anterior hypopituitarism in a cohort of TSH-secreting adenoma patients: Might somatostatin analogs have a role as first-line therapy? *Pituitary*. 2015 Oct;18(5):583-591.
doi: 10.1007/s11102-014-0611-8
29. Rimareix F, Grunenwald S, Vezzosi D, Rivière LD, Bennet A, Caron P. Primary Medical Treatment of Thyrotropin-Secreting Pituitary Adenomas by First-Generation Somatostatin Analogs: A Case Study of Seven Patients. *Thyroid*. 2015 Aug;25(8):877-882.
doi: 10.1089/thy.2015.0041
30. Beck-Peccoz P, Lania A, Beckers A, Chatterjee K, Wemeau JL. European thyroid association guidelines for the diagnosis and treatment of thyrotropin-secreting pituitary tumors. *Eur Thyroid J*. 2013 Jun;2(2):76-82.
http://dx.doi.org/10.1159/000351007
31. Mouslech Z, Somali M, Sakali AK, Savopoulos C, Mastorakos G, Hatzitolios AI. TSH-secreting pituitary adenomas treated by gamma knife radiosurgery: our case experience and a review of the literature. *Hormones (Athens)*. 2016 Jan 6.
doi: 10.14310/horm.2002.1640
32. Brucker-Davis F, Oldfield EH, Skarulis MC, Doppman JL, Weintraub BD. Thyrotropin-secreting pituitary tumors: diagnostic criteria, thyroid hormone sensitivity, and treatment outcome in 25 patients followed at the National Institutes of Health. *J Clin Endocrinol Metab*. 1999;84:476-486.
http://dx.doi.org/10.1210/jcem.84.2.5505
33. Losa M, Giovanelli M, Persani L, Mortini P, Faglia G, Beck-Peccoz P. Criteria of cure and follow-up of central hyperthyroidism due to thyrotropin-secreting pituitary adenomas. *J Clin Endocrinol Metab*. 1996;81:3086-3090.
http://dx.doi.org/10.1210/jcem.81.8.8768879
34. Atkinson JL, Abboud CF, Lane JI. Dramatic volume reduction of a large GH/TSH secreting pituitary tumor with short term Octreotide therapy. *Pituitary*. 2005;8(2):89-91.
http://dx.doi.org/10.1007/s11102-005-3279-2
35. Beck-Peccoz P, Persani L. Medical management of thyrotropin-secreting pituitary adenomas. *Pituitary*. 2002;5:83-88.
http://dx.doi.org/10.1007/978-1-4615-1115-1_8

Commentary

The article analyzes clinical cases of TSH-secreting tumor, which is an extremely rare endocrine disease. Measurement of TSH level is among the most commonly prescribed hormonal tests. Increased TSH requires an accurate differential diagnosis, because it can be caused by various endocrine disorders and therefore it can require fundamentally different approaches to the choice of treatment. In typical cases, thyrotropinoma is accompanied by development of thyrotoxicosis with normal or elevated TSH levels. Long-lasting untreated thyrotoxicosis (including cases of misinterpretation of hormonal disorders) leads to severe changes in many body systems (cardiovascular, nervous, digestive, reproductive, etc.).

The authors provide very important guidelines for practicing endocrinologists and neurosurgeons, characterizing clinical cases of thyrotropinomas. They pay attention to the very high percentage of misdiagnosis at the stage of outpatient examination before admission to the Burdenko Neurosurgical Institute; in some cases, patients with thyrotropinomas even underwent thyroid resection.

All reported tumors were macroadenomas, in 91% of cases they were endo-extrasellar. Most patients (76%) had clinical signs of hyperthyroidism. Along with clinical signs of hyperthyroidism, these patients also had various neurological symptoms, including visual disturbances and cephalgic syndrome. According to US study of the thyroid gland, 13 patients had various structural changes (diffuse goiter, nodular goiter, diffusely nodular goiter). When combined with thyrotoxicosis, this could contribute to inadequate differential diagnosis of primary, rather than central thyrotoxicosis. When comparing tumor growth patterns in 7 (71%) patients with a history of thyroid surgery, most of them were diagnosed with infiltrative growth. However, no statistical differences were found, when comparing tumor growth patterns in the groups of patients with and without history of thyroid surgery. In any

case, erroneous management of these patients may have irreversible consequences.

Concomitant primary hypothyroidism, either postoperative or resulting from chronic autoimmune thyroiditis, with thyrotropinoma is one of the most disputable and challenging problems. The authors regard these tumors as secondary thyrotropinomas.

Complex hormonal examination of some patients also detected other hormonal disorders. Tumors polymorphism was further confirmed by immunohistochemical studies, where isolated TSH expression was detected in only 14% of cases, while the majority of tumors showed expression of TSH and STH and/or PRL.

The paper points out that radical resection was possible in 33% of patients, having only endosellar and endo-suprasellar tumor. There were no cases of complete resection of infiltrative tumors. It would be proper to specify the tactics of management of these patient, when radical adenomectomy is impossible.

It was found that normal postoperative level of TSH or its decrease to 0.1 mIU/L, as well as transient postoperative hypothyroidism are not the criteria of the effectiveness of tumor removal. This proves once again that the verification of the diagnosis and radical treatment pose significant problems. The literature provides evidence of high efficacy of the use of somatostatin analogues for thyrotropinomas, as also shown in this work.

In this regard, the study of expression of dopamine and somatostatin receptors in the resected tissue of pituitary adenoma becomes highly important. The paper demonstrated high incidence of expression of type 2 dopamine receptors and type 5 somatostatin receptors.

In conclusion, the authors once again emphasize diagnostic criteria of TSH-secreting pituitary tumor and differential diagnosis of various types of thyrotoxicosis.

The article is extremely important, since it covers very challenging issues of diagnostic criteria and management of pituitary adenomas.

F.M. Abdulhabirova (Moscow, Russia)