doi: 10.17116/engneiro201680613-20

The First Experience with a New Technique of Portal Endoscopic Discectomy for Herniated Cervical Discs

A.O. GUSHCHA, S.O. ARESTOV, A.V. VERSHININ

Research Center of Neurology, Moscow, Russia

Selection of the most appropriate tactics for surgical treatment of herniated cervical discs is a topical issue to be discussed. The idea of herniated disc removal using an endoscopic technique is not new. This is a routine surgery for the lumbar spine. However, application of endoscopic techniques in the cervical spine surgery was first reported only in 2014 (J. Yang, et al.).

Objective. This study was aimed at mastering the methodology of a new technique, portal endoscopic discectomy, determining the indications for this surgery for herniated cervical discs, and comparing outcomes of this surgery with outcomes of anterior microsurgical discectomy. Material and methods. The study included 25 patients, who underwent portal endoscopic cervical discectomy. A comparison group consisted of 25 patients, who underwent anterior microsurgical discectomy and placement of an interbody cage.

Results. Comparison of surgical outcomes showed no significant difference ($p>0.05$) in the severity of postoperative local and radicular pain syndrome. According to the Neck Disability Index (NDI), significant improvement occurred in patients with endoscopic surgery. According to the Odom criterion, significant advantage in the number of excellent and good outcomes was observed in study group patients. There were significant differences between the groups in the duration of postoperative hospital stay. The average duration was 3 days in the study group and 5 days in the control group.

Conclusion. Portal endoscopic discectomy is a highly effective treatment for herniated cervical discs, which provides clinical outcomes associated with much less surgical trauma. The study demonstrates not only the efficacy of the suggested technique, but also its safety compared to conventional anterior microsurgical techniques, which usually involve interbody fusion. This surgery is superior to other interventions in terms of the rate of rehabilitation and social adaptation of patients and reduces postoperative hospital stay.

Keywords: portal endoscopic discectomy, cervical disc herniation, endoscopic spinal surgery.

The incidence of cervical discogenic compression syndromes is extremely high. According to J. Lawrence [1], despite the relatively small proportion of detectable lesions of the cervical intervertebral disc among the total number of degenerative spinal diseases, about 10% of the population experience periodic compression-related pain in the cervical spine or in the hand.

Assessment of cervical hernia is based on conventional staging classification of intervertebral disc herniation (protrusion, prolapse, and sequester) proposed by A. Decoulx [2], which is important in evaluation of the clinical course of the process and selection of treatment strategy, as well as classification of herniated intervertebral discs in terms of their axial arrangement and relationship with the bony structures of the spinal canal. The latter distinguish between median, paramedian (laterally shifted with respect to the sagittal plane), lateral, and foraminal hernia.

Based on the analysis of a large number of cases, J. Bland et al. [3] determined characteristic clinical symptoms associated with cervical radicular compression, having practical value to assess the severity of impairment and axial arrangement of hernia. Along with the characteristic radicular irradiation of pain, sensory disturbances, loss of tendon reflexes corresponding to innervated myosclerotome, and paresthesia, which are indicative of root compression in the intervertebral foramen, are often detected. In the case of questionable data, Spurling's test is recommended (axial load on the neck along with side-to-side shaking), which leads to worsening of paresthesia [4].

J. Knightly [5] conveniently distinguish two pathoanatomical type of compression substrate formation at the level of intervertebral disc: soft disc (or fragments of prolapsing disc as the acute phase of the disease) and hard disc (uncovertebral osteophytes as the chronic phase of the disease). In our opinion, the structural state of the compressing factor, as well as its axial arrangement is the key factor in in the choice of surgical treatment. In patients with "soft disc", clinical presentation is dominated by symptoms of brachialgia that often occur after physical activity, sudden movement of the head, or neck injury. Irradiation of acute radicular pain corresponds to dermatomes and often depends on the position of the head and limbs. "Helmet"-like or homolateral hemicrania-like irradiation of the pain is very typical for this group of patients. Hypesthesia, accompanying this kind of compression, always involve individual dermatomes and may be accompanied by an isolated reduction of tendon reflexes in adjacent muscles. Decrease in strength (paresis) of the proximal parts of the upper limbs, which is often unilateral and transient.

The symptoms associated with the development of "hard disc" are characterized by headache and armache, which are often symmetrical and accompanied by transient localized palpatory tenderness at the level of

© Group of authors, 2016

e-mail: sarestov@gmail.com

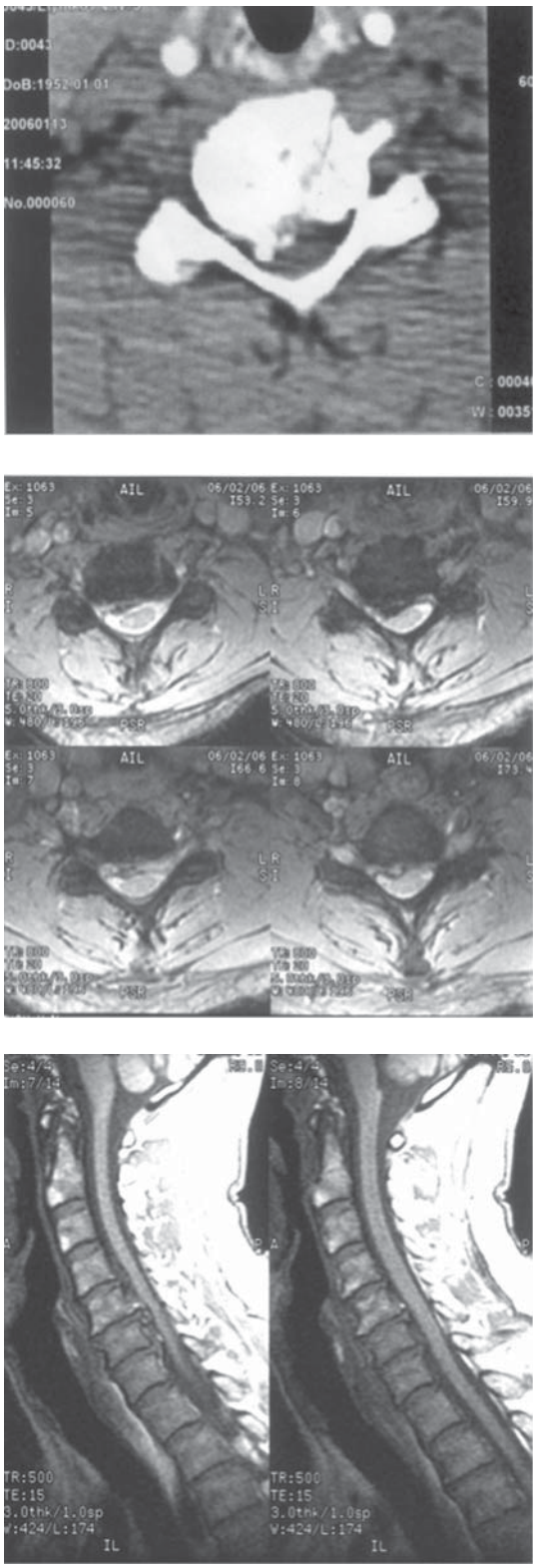

Fig. 1. **Neurodiagnostic studies in patients with right-sided osteophyte at C5—C6 level on the right and "soft" disc hernia at C6—C7 level on the right. The use of CT (a) in combination with MRI (b, c) enabled determining the morphological character of root compression. The arrow shows the bone-density disc herniation.**

hernia, which has a certain diagnostic value. This variant of the disease is characterized by multiple areas of desensitization up to conduction anesthesia, originating at the level of the lesion and accompanied by impaired muscle strength below the segment concerned, sometimes up to deep paresis. Clinical presentation of calcified compressing structures in the cervical spinal canal is characterized by normoreflexia or hyperreflexia, which is most likely due to chronic circulatory disturbances in the anterior spinal artery system.

In patients with "hard disc", development of clinical symptoms takes much more time compared to those in with "soft" hernias.

Conventional CT and MPT-studies provide complementary information in the diagnosis of the disease. The former method is preferable to identify compression factors (hernia, osteophytes), and the latter is preferable to detect the results of compression (compression of the spinal cord and roots). Bischoff (2003) investigated sensitivity, specificity, and accuracy of CT, MRI, and myelography when establishing the "herniated disc" and "spinal stenosis" diagnoses. The accuracy and sensitivity of CT is slightly higher compared to MRI. CT remains the best method to assess central stenosis. MRI provides images of the whole cervical spine and enables detecting stenosis in frontal and sagittal projections (**Fig. 1**).

The studies of J. Wilmink [6] showed the following clinical and radiographic correlations of CT results.

1. Complete occlusion of the intervertebral foramen by laterally migrated masses of the degenerated intervertebral disc ("soft disc") is always accompanied by radicular syndrome.
2. Narrowing of the intervertebral foramen due to osteophyte ("hard disc") results in the root swelling and less pronounced radicular syndrome compared to the first variant.
3. Paramedian disc protrusion that does not result in complete occlusion of the intervertebral foramen and pronounced compression of the spinal cord often causes the development of radicular symptoms on the contralateral (with respect to hernia) side.

Treatment of compression syndromes caused by degenerative changes in the cervical spine has a 50-year-long history, and, despite this fact, there is currently no common viewpoint on the criteria for selection of certain surgical procedures. This can be explained, on the one hand, by continuous improvement of the techniques of cervical spine surgery and development of "spinal design" operations, and, on the other hand, deepening of understanding of the pathogenesis and biomechanics of these changes. Both anterior and posterior approaches in the cervical spine surgery have been developing in parallel over 50 years. Many surgeons developed the anterior approach through the interfascial space, using the transverse or oblique incision along the anterior margin of the sternocleidomastoid muscle [7, 8]. The history of

posterior approaches begins in 1955, when D. Northfield [9] proposed bilateral laminectomy, extended by one segment above and below the pathological level. In 1961, W. Scoville [10] performed the limited bilateral laminectomy supplemented with bilateral facet resection. The development of the posterior approached was aimed at decompression of neural structures by means of resection of the posterior supporting complex of the arch and spinous process. These approaches did not always enables removal of compressing masses located on the ventral surface of the spinal canal, although several cases of removal of disc hernia and vertebral body osteophytes have been reported [11]. Posterolateral approaches include posterior foraminotomy or facetectomy. This surgical technique was developed in 1944 by R. Spurling [4] and later on, in more detail, by Frykholm, W. Scoville [12] ("keyhole" technique). This posterior approach enabled foraminotomy and herniated disc resection through a small incision. However, most neurosurgeons still prefer to use a more safe anterior approach due to the probability of neurological deficit and the need for segment stabilization [13]. Existing endoscopic methods belong to intradisc interventions, which are not capable of sufficient decompression of the spinal structures.

During the last 10 years, portal endoscopic discectomy, which was proved to be effective and safe, has been widely used in our department to treat herniated lumbar intervertebral discs [14]. Since 2014, this technique has been successfully used to treat herniated cervical intervertebral discs. In this paper, we provide a detailed description of the portal endoscopic discectomy for herniated cervical intervertebral discs and the most important technical features of this method based on our own experience.

It should be noted that this is the first ever detailed report on application of this method in cervical surgery both in Russian and international literature. When analyzing published data, we found a large number of research dealing only with application of full endoscopic technique (i.e., cervical surgery through percutaneous approach, both anterior and posterior, including only foraminotomy) [15—17]. It should be taken into account that both lumbar and cervical portal endoscopic methods are technically similar to microsurgical interventions, but differ from the latter in the degree of soft tissue traumatization associated with these approaches and visualization quality, which in this case enables "peeking behind the root".

The study was aimed at mastering the methodology of the new technique, portal endoscopic discectomy, determining the indications for this operation in patients with herniated cervical disc, and comparing the results of this operation with the results of the anterior microsurgical discectomy.

Material and Methods

We compared surgical outcomes in 25 patients with C5—C6 [9] and C6—C7 lateral disc herniation [16], who underwent endoscopic portal cervical discectomy. Retrospective evaluation of surgical outcomes in 25 patients, who were also operated on by the first author and underwent a microsurgical single-level anterior cervical discectomy with interbody fusion at C5—C6 or C6—C7, was used as a comparison group. The operation performed in the control group patients is described in detail in relevant guidelines [14, 15].

In both groups, early postoperative outcomes were assessed as follows: VAS (visual analogue scale) — timing and extent of radicular pain regression; decrease in pain based on NDI (Neck Disability Index) — social adaptation of patients; Odom criteria — overall postoperative recovery. NDI provides a measure of patient's social adaptation based on summation of points characterizing the possibility of usual activities (walking, sleeping, reading, recreation, etc.). Odom characterizes the effect of the surgery in general, from good to unsatisfactory. Evaluation of NDI and Odom criteria was carried out immediately before the discharge. In addition, the time of postoperative hospital stay was evaluated.

Mann-Whitney test was used in statistical processing to assess the validity of the results.

The technique of portal endoscopic cervical discectomy

Patient's positioning on the operating table

The patient is laid on the operating table in prone position with hands placed along the body. The head is placed on the soft headrest or fixed in Mayfield head clamp. The cervical spine is placed in neutral position.

Planning the incision

Electron-optical converter (EOC) is typically used for incision planning, images of the cervical spine are taken in the lateral projection. A sterile needle is placed in the plane of the target intervertebral disc. Incision is planned 1—2 cm lateral to the midline, depending on patient's physique (**Fig. 2**).

Operative approach

Skin incision is followed by incision of fascia and EOC-controlled punctural placement of surgical cone at the projection of the desired interval (**Fig. 3**). The base of the lower articular process of the overlying vertebra is and optimal point to place a port. Surgical port installation is followed by preserving resection of adjacent vertebral arches and flaval ligament is released. When the port is properly installed, no significant resection of the intervertebral joint is required. It should be remembered that, according to various authors [16—18], resection of

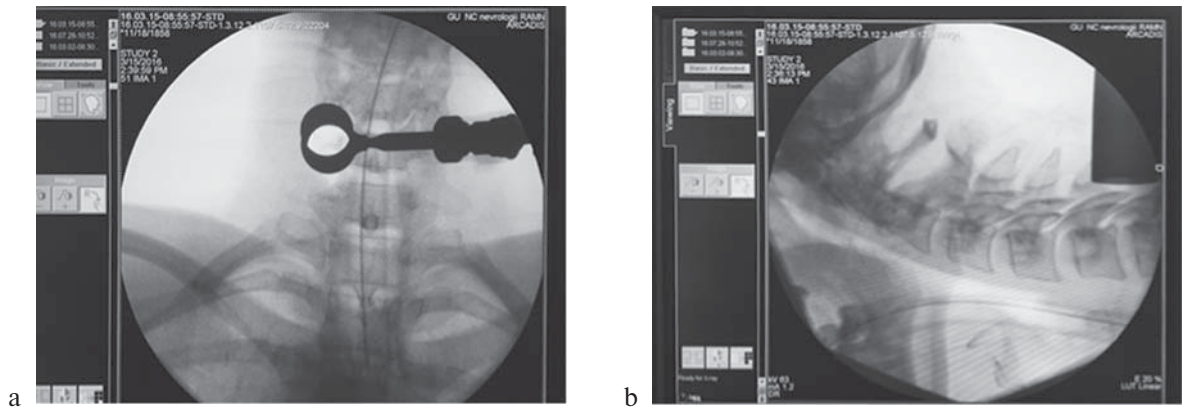

Fig. 2. **Positioning of incision, frontal (a) and lateral (b) projection (EOC display view).**

25 to 50% of the intervertebral joint results in segmental instability. Soft tissue removal from the intralaminar space is followed by opening of the flaval ligament, preferably as medial as possible and by blunt dissection [19].

The main stage of the surgery

Opening of the flaval ligament usually results in visualization of dural sac, whose separation provides the approach to the gaine radiculaire. There is usually venous plexus along the latter (**see Fig. 3a**), which is coagulated and intersected. After that, the root becomes more mobile despite the compression. Root displacement enables visualization of disc hernia and its removal (**see. Fig. 3b**).

Surgical wound closure

The wound is closed layer by layer. Particular attention is paid to restoration of the integrity of the muscle aponeuroses in the surgical area.

Rigid cervical collar should be used for 3 weeks in the early postoperative period to reduce axial loads on the operated spinal motion segment.

Results

There was no worsening of neurological deficit in both the study and control groups. In 2 (8%) patients in the group of endoscopic removal of disc hernia, transient numbness in the region of innervated dermatome was observed followed by full regression by the time of discharge. Preoperatively, median intensity of pain in the shoulder and forearm as assessed by VAS score was 6 (3; 8) in the endoscopic discectomy group and 6 (4; 8) in the microsurgical anterior discectomy group. After surgery, this value decreased to 1 (0, 6) in the posterior endoscopic discectomy group and 2 (1; 6) in the microsurgical anterior discectomy group. In both groups, there was significant decrease in pain (p=0.016 and p=0.034, respectively). Immediately before discharge from the

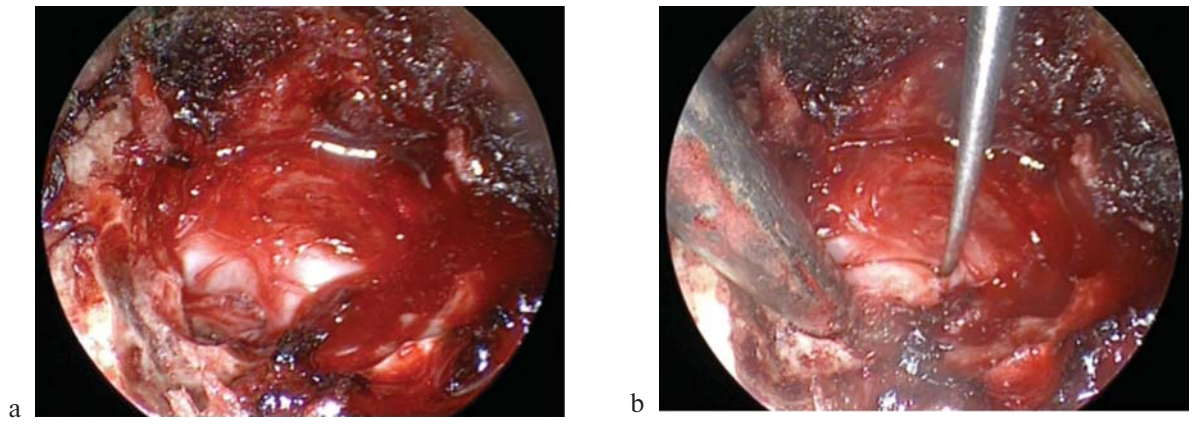

Fig. 3. **The main stage of the operation.**

a — separation of the gaine radiculaire; b — removal of disc herniation.

Table 1. **The intensity of pain in the neck, shoulder, and forearm on the visual analogue scale (VAS) before and after surgery**

Criterion	Patients with endoscopic posterior discectomy (n=25), study group	Patients with microsurgical anterior discectomy (n=25), control group
	Pain in the shoulder and forearm (median and range)	
Preoperative score	6 (3; 8)	6 (4; 8)
Score before discharge	1 (0; 4)	2 (1; 6)
Whitney-Mann test, p	0,016	0,034
	Pain in the neck (median and range)	
Preoperative score	5 (2; 6)	6 (3; 7)
Score before discharge	1 (0; 3)	3 (1; 5)
Whitney-Mann test, p	0,024	0,034

hospital, the level of pain in the shoulder and forearm did not differ significantly in these two groups (p>0.05). When assessing pain in the neck, two groups were comparable in the preoperative period (p>0.05) and significant decrease in the severity of pain was observed in the postoperative period (p=0.024 in the study group and p=0.034 in the control group) (**Table 1**).

All study group patients noted complete or nearly complete regression of pain syndrome immediately after the operation.

Significant improvement of the score was observed in patients who underwent endoscopic surgery. In both groups, patients were subjectively satisfied with the outcome. As for Odom criteria, there were significantly more excellent and good outcomes in study group patients (**Table. 2**).

Significant differences were found, when comparing the time of postoperative hospital stay: it was 3 (2; 5) days in the study group and 5 (4; 6) days in the control group. In the study group, 1 (4%) patient reported the recurrence of radicular pain one week after surgery. Preoperative and postoperative MPT of this patient are shown in **Fig. 4** and **5**. Control MRI showed that disc hernia was completely removed and the pain was not associated with its recurrence. Antineuritic therapy for 2 weeks resulted in complete regression of pain syndrome.

Thus, these studies demonstrate safety and efficacy of the posterior portal endoscopic discectomy. When the anatomy of the compressing factor is quite clearly understood, this type of intervention is superior to other operations in terms of the rate of rehabilitation and social adaptation of patients and shortens postoperative hospital stay.

Our results provided the basis for formulation of indications and contraindications for the portal cervical endoscopic discectomy.

Surgery is indicated in the following cases:

— clinical presentation of radiculopathy corresponds to the side and level of the lesion detected by MRI/CT;

— CT/MRI studies confirm the correspondence between the “soft” compression of the root, which is located in the lateral third of the width of the spinal canal, and the clinical presentation of the disease;

— there is no effect of conservative treatment during 3 weeks.

The operation is contraindicated in the following cases:

— There are signs of segmental instability;

— There is kyphotic deformity of the spine at the level of disc herniation.

Discussion

The choice of surgical approaches in the treatment of compression syndromes presenting with neurological and vascular disorders is associated with a number of controversial issues [20, 21], although these interventions have been existing for rather long period [15]. The main problem is, which decompression option should be selected, either anterior or posterior one. Both methods enable quite adequate solution of this problem. Selection of decompression direction is determined by localization

Table 2. **Surgical outcomes according to NDI index and Odom criterion**

Criterion (criterion)	Patients with endoscopic posterior discectomy (n=25), study group	Patients with microsurgical anterior discectomy (n=25), control group
	NDI (median and range)	
Preoperative score	24 (8; 32)	23 (6; 39)
Score before discharge	13 (5; 25)	13 (5; 19)
Whitney-Mann test, p	0,056	0,026
	Odom criterion (median and range)	
Very good/good	21	17
Satisfactory/unsatisfactory	4	8

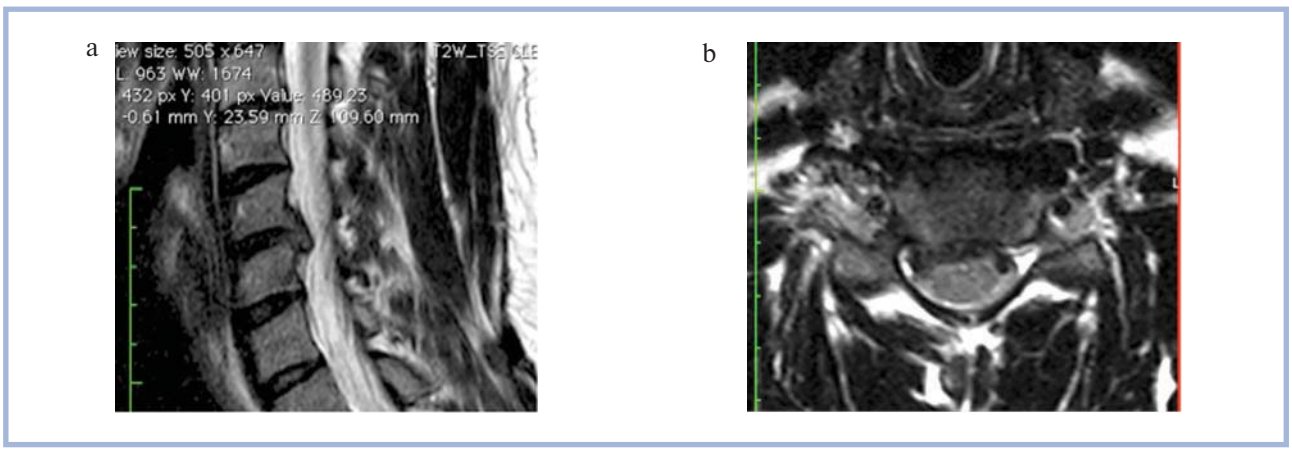

Fig. 4. **Preoperative MRI.**
a — sagittal projection; b — axial projection (explanation in the text).

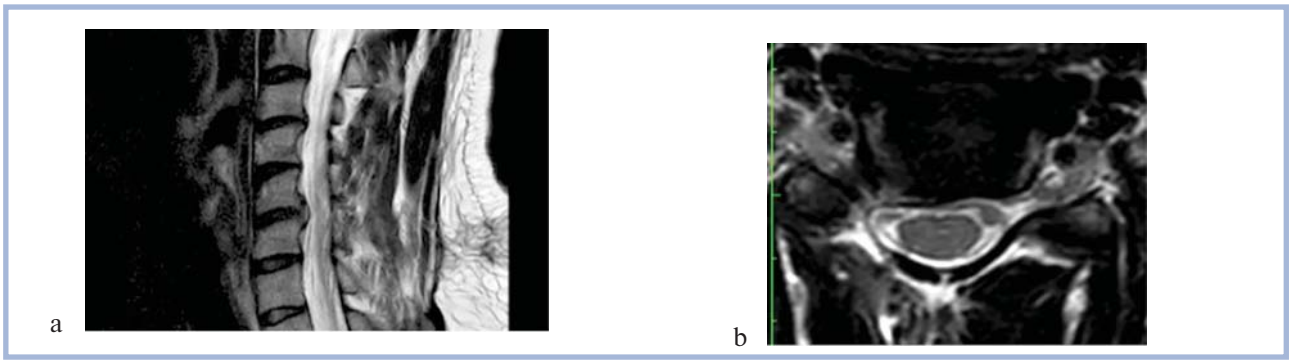

Fig. 5. **Postoperative MRI.**
a — sagittal projection; b — axial projection (explanation in the text).

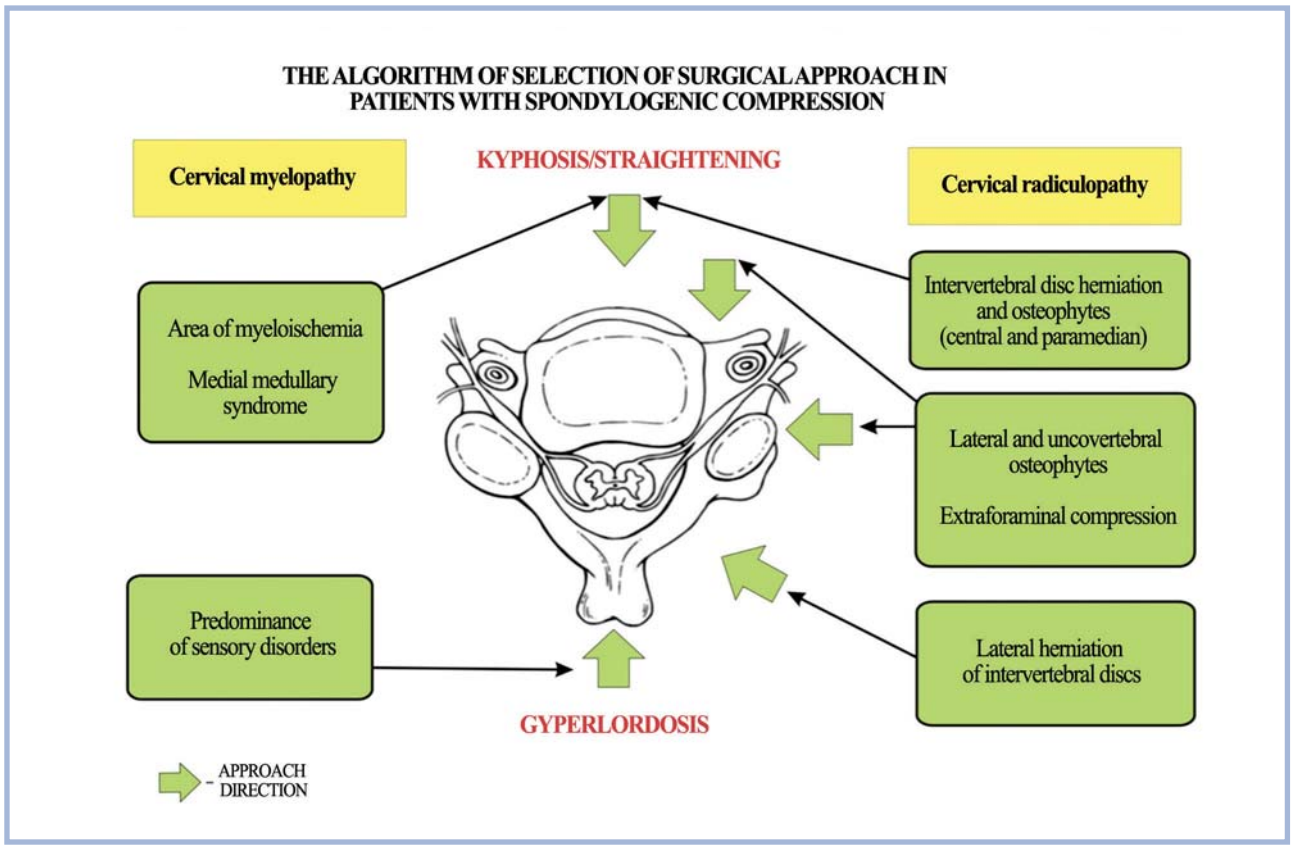

Fig. 6. **The algorithm of selection of surgical approach in patients with cervical spondylogenic compression.**

of compressing factor as proved for single-level procedures.

According to opinion of H. Jho expressed in a private conversation, posterior cervical foraminotomy has limitations in the case of frontal compression with osteophyte, posterior compression with uncovertebral joint, and pronounced cicatricial process. The cardinal clinical syndrome of cervical radiculopathy requires more thorough examination of the patient, since it is often not accompanied by unequivocal x-ray data about the cause of the compression, and almost never has pathognomonic changes in neurovascular structures. The highest accuracy of detection of muscular atrophy in corresponding muscles was proved to be the main criterion of the level of radiculopathy. Modern neurovisualization methods enable identification of the compressing factor: "soft" (herniated disc) or "hard" (osteophyte or bone spike), which is a decisive factor in the choice of surgical approach. In the case of lateral "soft" disc, posterior portal endoscopic resection is indicated, whereas more radical removal of osteophyte in this area can be achieved through the ventral approach. The nature of the compressing factor in patients with the cervical radiculopathy syndrome should also be considered in the context of neurological symptoms. In the case of osteophyte, the severity of radicular symptoms (especially pain) is substantially lower than in the case of "soft" hernia.

To our knowledge, inefficiency of surgical treatment of patients with radiculopathy is primarily due to underestimation of neurological symptoms and interpretation of neurovisualization data. In particular, the paramedian location of disc hernia is often accompanied by radicular symptoms in the contralateral hand. The ignorance of this fact may cause inadequate choice of the side of surgical approach and therefore the lack of clinical effect of the surgery.

Confirmed spine deformity and detected segmental instability are significant factors in choosing the direction of surgical approach. Cervical spine kyphosis associated with degenerative processes in the vertebrae always suggests the use of ventral approach accompanied by appropriate stabilizing measures.

Based on these data and surgical outcomes, we developed the algorithm for selection of surgical approach in patients with cervical spondylogenic compression (**Fig. 6**).

The use of endoscopic microdiscectomy in the treatment of herniated cervical intervertebral discs is highly effective and provides clinical results with considerably less surgical trauma. We discovered technical features and proposed recommendations, which will contribute to widespread use of this promising minimally invasive technique in neurosurgical practice.

There is no conflict of interest.

REFERENCES

1. Lawrence JC. Disc degeneration: its frequency and relationship to symptoms. *Ann Rheum Dis*. 1969;28:121-127.
   PMID: 4237972
2. Decoulx P, Houcke E. Anatomie pathologique de la hernia discale. *Presse Medicale*. 1958;40:899-905.
   PMID: 13567472
3. Bland JH. *Disorders of the Cervical Spine*. 2nd ed. Philadelphia: W.B. Saunders Company. 1994;390.
4. Spurling RG. Lesions of the cervical intervertebral disc. *J Am Med Assoc*. 1953 Jan 31;151(5):354-359.
   PMID: 13010997
5. Knightly JJ, Greene KA. Locked facets and disk herniation. *J Neurosurg*. 1994;80:952-953.
   PMID: 8169646
6. Wilmink JT, Hofman PAM. T2-weighted 3D FSE MR myelography in the cervical spine: comparison of 2 techniques. *Neurorad*. 2005;37:Supp.1:56.
7. Smith G, Robinson R. The treatment of certain cervical spine disorders by anterior removal of the intervertebral disc and interbody fusion. *J Bone Joint Surg*. 1958;40A:607-624.
   PMID: 13539086
8. Szpalski M, Gunzburg R. *The Degenerative Cervical Spine*. Lip Will & Wilk. 2001;338.
9. Northfield DW. Diagnosis and treatment of myelopathy due to cervical spondylosis. *Br Med J*. 1955 Dec 17;2(4954):1474-1477.
   PMID: 13269895 PMCID: PMC1981414
10. Scoville WB. Cervical spondylosis treated by bilateral facetectomy and laminectomy. *J Neurosurg*. 1961 Jul;18:423-428.
    PMID: 13749416
    doi: 10.3171/jns.1961.18.4.0423
11. Shen FH, Samartzis D, Khanna BS, Goldberg EJ, An H. Comparison of clinical and radiographic outcome in instrumented anterior cervical discectomy and fusion with or without direct uncovertebral joint decompression. *Spine J*. 2004;4:629-635.
    PMID: 15541694
    doi: 10.1016/j.spinee.2004.04.009
12. Scoville WB. Newer techniques in neurosurgery. *Turk J Pediatr*. 1965 Jan;6:55-59.
    PMID: 14295201
13. Shevelev IN, Shulev YuA, Goushcha AO, Tissen TP, Remenec VV, Denisenko EI, Stepanenko VV. Differencirovannaja taktika hirurgicheskogo lechenija bol'nyh s vertebral'nymi kompressionnymi sindromami na shejnom urovne. *Voprosy nejrohirurgii im. N.N. Burdenko*. 2003;3:28 (In Russ.).
14. Arestov SO, Vershinin AV, Gushha AO. Sravnenie jeffektivnosti i vozmozhnostej jendoskopicheskogo i mikrohirurgicheskogo metodov udalenija gryzh mezhpozvonkovyh diskov pojasnichno-krestcovogo otdela pozvonochnika. *Voprosy nejrohirurgii im. N.N. Burdenko*. 2014;78:6:9-14 (In Russ.).
15. Goushcha AO, Arestov SO. *Endoskopicheskaya spinal'naya khirurgiya*. Monography. 2010. (In Russ.).
    ISBN: 978-5-9704-1699-0
16. Nowinski GP, Visarius H, Nolte LP, Herkowitz HN. A biomechanical comparison of cervical laminoplasty and cervical laminectomy with progressive facetectomy. *Spine* (Phila Pa 1976). 1993 Oct 15;18(14):1995-2004.
    PMID: 8272949
17. Raynor RB, Pugh J, Shapiro I. Cervical facetectomy and its effect on spine strength. *J Neurosurg*. 1995;63:278-282.
    PMID: 4020449. doi: 10.3171/jns.1985.63.2.0278

18. Zdeblick TA, Ducker TB. The use of freeze-dried allograft bone for anterior cervical fusions. *Spine* (Phila Pa 1976). 1991 Jul;16(7):726-729.
PMID: 1925745

19. Goushcha AO, Arestov SO. Torakoskopicheskaya khirurgiya v lechenii novoobrazovanii pozvonochnika i paraspinal'nykh neirogennykh opukholei. *Russian traumotology and orthopedy*. 2010;2(56):129-131. (In Russ.).

20. Yang JS, Chu L Chen L, Chen F, Ke ZY, Deng ZL. Anterior or posterior approach of full-endoscopic cervical discectomy for cervical intervertebral disc herniation? A comparative cohort study. *Spine* (Phila Pa 1976). 2014 Oct 1;39(21):1743-1750.
PMID: 25010095
doi: 10.1097/BRS.0000000000000508

21. Li XC, Zhong CF, Deng GB, Liang RW, Huang CM. Full-Endoscopic Procedures Versus Traditional Discectomy Surgery for Discectomy: A Systematic Review and Meta-analysis of Current Global Clinical Trials. *Pain Physician*. 2016 Mar;19(3):103-118.
PMID: 27008284

Commentary

The article provides a detailed description and comparative analysis of the use of innovative technique of portal endoscopic discectomy in treatment of herniated cervical discs. The study included 25 patients, who were operated on in 2014—2016. The control group included 25 patients, who were operated on using anterior cervical discectomy with installation of a single-level interbody implant. The authors suggested indications for the use of portal endoscopic discectomy: paramedian or lateral herniation of the cervical disc with monoradicular symptoms and no calcification of disc herniation as evidenced by CT. The signs of segmental instability and spinal deformity, which is usually indicative of segment stabilization, are considered as contraindication. The technique of surgical intervention from patient positioning on the operating table to surgical wound suturing is described in detail.

Treatment outcomes were assessed on VAS scale (visual analog scale), preoperative and postoperative values were compared. Preoperative comparison of the groups showed no statistically significant difference between the groups of patients. Social adaptation and quality of life have been assessed using NDI (Neck Disability Index). Additionally, overall recovery of patients was compared using Odom criterion and time of patients' hospital stay was evaluated. High level statistical processing of the results was performed using modern statistical processing tools, which proves the validity of the results of the study.

In my opinion, this article is a valuable and relevant scientific work. The provided information can be used to develop methods of portal cervical endoscopic discectomy. The presented data demonstrate the efficacy and safety of the method.

The bulk of the article focuses on describing the techniques and nuances of the operation. In our clinic, we use portal endoscopic discectomy to treat lumbosacral intervertebral disc herniation, but the use of this technique in the cervical spine is associated with a number of difficulties. The correct positioning of the endoscopic port is the most challenging problem. The authors carefully describe this issue and note the nuances, so that it is, in fact, guidelines to master this method.

Selection of patients for this operation is a disputable question. Indeed, the posterior approach is only suitable for resection of lateral and paramedian disc hernia, since even a small traction of the compressed spinal cord can cause severe postoperative neurological disorders. This fact was the main argument to switch from the posterior microsurgical approach to anterior approaches in the late 1900s. The authors supplemented the standard preoperative examination complex with CT of the cervical spine to measure preoperative density of disc hernia. This is due to the fact that significant traction of nerve structures and the use of bulky microsurgical instruments is required for removal of ossified herniation of intervertebral discs, which in turn eliminates the advantages of endoscopic approach. In our view, this additional preoperative examination is reasonable and improves safety of the technique.

Therefore, this material is relevant and highly informative. The detailed description of the procedures and techniques of the portal endoscopic discectomy makes this work a valuable guideline for the operation. This technique is a new promising trend in neurosurgery. The authors fully proved the effectiveness and safety of the method.

N.L. Konovalov (Moscow)