doi: 10.17116/engneiro20168064-12

Outcomes of Application of Modern First-Line Chemotherapy Regimens in the Multimodality Therapy of Patients with Glioblastoma

O.V. ABSALYAMOVA, G.L. KOBYAKOV, M.V. RYZHOVA, A.A. PODDUBSKIY, M.V. INOZEMTSEVA, K.S. LODYGINA

Burdenko Neurosurgical Institute, Moscow, Russia

Objective. The objective of this study is to describe the procedure and outcomes of comprehensive first-line treatment in glioblastoma patients.
Material and methods. We analyzed 107 glioblastoma patients who were operated on in 2010—2011. Seventy five patients underwent combined chemoradiotherapy (CRT) with simultaneous administration of 75 mg/m^2 temozolomide (TMZ) followed by chemotherapy with 200 mg/m^2 TMZ for 5 days, every 28 days. Separately, we examined 32 patients with large tumors, who received alternative treatments.
Results. The median time to progression was 11.7 months in the study group and 7.2 and 8.1 months in the groups of alternative therapy. The one-year progression-free survival rate was 37%. Overall survival was 29.2 months.
Conclusion. The chemoradiotherapy regimen involving TMZ followed by one-year TMZ monotherapy is an appropriate treatment for patients who underwent glioblastoma resection. With this approach, no tumor progression occurs in one third of patients during the first year. Thorough study of clinical and radiological findings in the course of treatment makes it possible to achieve maximum efficacy, avoid unreasonably early switch to second-line therapy, and timely detect tumor recurrence signs. The Response Assessment in Neuro-Oncology (RANO) criteria should be used to assess MRI-detected changes in the tumor size. The rates of overall and recurrence-free survival were significantly lower in patients with inoperable or partially resected tumors. The applied approaches provide only a slight advantage in tumor growth control, which necessitates the search for more effective treatment options for these patients. Inclusion of bevacizumab to the first-line therapy regimen may be a possible approach.

Keywords: glioblastoma, chemotherapy, evaluation criteria, tumor pseudoprogression.

Glioblastoma (GB) is the most common primary malignant tumor of the central nervous system in adults, whose incidence is 20%. GB is characterized by an extremely unfavorable prognosis: in most patients, progression of the disease is detected within the first year after surgery; overall survival (OS) did not exceed 1 year for a long time [1]. Currently, a comprehensive approach is used to treat GB patients, including surgery, radiotherapy (RT), and chemotherapy (CT) and life expectancy is up to 2 years.

Maximum possible tumor resection followed by a combination of chemoradiotherapy (CRT) with temozolomide (TMZ) and subsequent adjuvant chemotherapy (TMZ) is the "gold standard" of the first-line treatment of patients with GB. RT is applied on the tumor area (including about 2—3 cm around it) at a total dose of 60 Gy and single dose of 2 Gy along with administration of TMZ (75 mg/m^2). Chemotherapy with TMZ at a unit dose of 200 mg/m^2 is started 28 days after completion of this treatment (during 5 days followed by 23-day break). This regimen was first described by R. Stupp et al. [2], who have shown that inclusion of TMZ in this treatment regimen increases the median time to progression (MTTP) from 5 to 6.9 months, and OS from 12.1 to 14.6 months as compared to the group of patients treated with radiation therapy alone. According to the study by M. Gilbert et al. [3], which was completed in 2013, MTTP was 8.8 months, and OS was 18.9 months, when using this regimen.

This study was aimed at evaluating the overall and disease-free survival of 107 patients with morphologically verified glioblastoma, who were treated at the Burdenko Neurosurgical Institute in 2010—2011.

Materials and methods

We analysed treatment outcomes of 107 patients with morphologically verified GBs, who were operated on in 2010—2011 and followed on a regular basis at the Burdenko Neurosurgical Institute. We retrospectively analyzed the results of everyday work, when the decision was made in each case in accordance with modern standards of GB treatment with allowance for individual characteristics, such as tumor size, general status, and presence of intracranial hypertension.

A total of 75 patients underwent a combined CRT with simultaneous administration of TMZ at a dose of 75 mg/m^2 followed by CT with TMZ at a dose of 200 mg/m2 for 5 days and then a 23-day break. Patients, who postoperatively had large residual tumors, received the combined chemoradiotherapy followed by CT with TMZ at a dose of 150 mg/m^2 from the 1st to 5th day of treatment session + Carboplatin 300 mg/m^2 on the first day of the course; treatment courses repeated every 28 days (treatment regimen with TMZ and Carboplatin, TC). There were a total of 20 such patients. The average number of CT courses in both groups was 6.2, from 0 (7 patients) to 21 (2 patients) courses. Twelve patients did not receive RT. This decision was taken in patients, who postoperatively had persisting signs of intracranial hypertension in the fundus and/or very large tumor (tumor remnants) accompanied by shift of midline

© Group of authors, 2016

e-mail: 5732493oks@gmail.com

structures. These patients underwent CT in TC mode; in the case of regression of intracranial hypertension signs and decrease in tumor signs, RT was performed in combination with CT. Postoperative treatment was carried out at the Burdenko Neurosurgical Institute and Oncology Centers in Moscow and other regions of Russian Federation.

General information about the patient is shown in **Table 1**.

Tumor size dynamics was assessed based on the archival data of contrast-enhanced MRI of the brain performed before CRT, 1 month after completion of the CRT, and then after every 3 CT courses. Upon completion of treatment, MRI was performed every 3—5 months and in the case of clinical signs of tumor progression and evaluated according to RANO (Response Assessment in Neuro-Oncology International Group) criteria.

Results

At the time of data analysis, progression of the disease was observed in 91 (85%) of 107 patients. Progression-free survival for more than 1 year was observed in 37% (40 patients). Progression-free survival for 12—18 months was observed in 17 (15.8%) patients, PFS for 18—24 months was observed in another 12 (11.2%) patients, more than 24 months — 11 patients (10 — up to 3 years and 1 — more than 3 years). Regardless of treatments, MTTP was 10.3 months, OS — 29.2 months. In treatment groups, MTTP was as follows: combined CRT with TMZ followed by therapy with TMZ — 11.7 months; combined CRT with TMZ followed by TC treatment — 7.2 months; patients who started CT possibly followed by RT — 8.1 months (p=0.008) (**Fig. 1**). Overall survival was 33.3, 26.3, and 18 months, respectively (p=0,007).

Discussion

Objective of the study was to assess treatment outcomes of patients with glioblastoma, using high-level surgical techniques, modern RT techniques, and sufficient number of modern CT courses.

The number of followed patients

We describe treatment outcomes of only 107 patients, which accounts for 31.4% of all patients, who were for the first time operated on for GB at the Burdenko Neurosurgical Institute in 2010—2011. Relatively small number of patients included in the analysis was due to both loss of medical history and failure to comply with GB treatment standards [4]. Our findings are consistent with data of A.V. Smolin et al., who conducted the Russian multi-centered study on the epidemiology of malignant gliomas from 01.01.2012 to 31.12.2013. This study included 325 patients from 29 medical centers in Russia. It has been shown that only every fourth patient received combined CRT and 1/3 of patients received no first-line CT. Among the patients who received first-line CT, some patients received medications other than TMZ [5].

Thus, higher numbers of MTTP obtained in this study were due to the use of modern glioblastoma treatment regimens. Furthermore, patients who did not receive treatment, did not request re-consultation, those who were unavailable for history taking and possibly died in the early postoperative period, were not included in our study.

Combined chemoradiation therapy with temozolomide followed by adjuvant therapy with temozolomide

In the study group, MTTP was 11.7 months. In patients, who were treated at the Burdenko Neurosurgical Institute using an identical regimen in 2006—2007, MTTP was 9.7 months [6].

In world practice, the standard CRT mode with TMZ followed by treatment with TMZ includes only 6 CT courses.

However, some clinicians are inclined to the opinion that larger number of courses are advisable, especially in patients with contrasted tumor remnants. There were no comparative randomized trials assessing the effectiveness of this approach. When comparing suitable groups from various studies, the following results were obtained. In the study by M. Stupp et al. [2], MTTP was 6.9 months in the group of patients, who received CRT + 6 courses of TMZ; in the study by Chinot O. et al. [7], MTTP was 6.2 months in the group of CRT + 6 courses of TMZ; in the study by M. Gilbert et al. [4], MTTP was 8.8 months in

Table 1. **General information about 107 patients with glioblastoma**

Combination therapy	CRT + TMZ, abs. (%)	CRT + TC, abs. (%)	TC +/- RT, abs. (%)	Total, abs. (%)
Number of patients	75 (70)	20 (18,7)	12 (11,3)	107
Males	37 (49,4)	8 (40)	7 (58,4)	52 (49)
Females	38 (50,6)	12 (60)	5 (41,6)	55 (51)
Average age, years	49	47	48	—
Local lesion	74 (98)	19 (95)	8 (66,6)	101 (94)
Multiple lesions	1 (2)	1 (5)	4 (33,4)	6 (6)
Tumor resection	75 (100)	19 (95)	9 (75)	103 (96,2)
Biopsy	0	1 (5)	3 (25)	4 (3,8)

the group of patients who received CRT + 12 courses of TMZ. It should be noted that in the study of R. Stupp et al., 16—17% of patients underwent only tumor biopsy, in the study of Chinot O. et al., the proportion of biopsies was 9.5—13.1%, M. Gilbert — 3%. Thus, it is still unclear what exactly has determined increase in MTTP, either longer CT or radical tumor resection.

In our series, 3.8% of patients underwent only tumor biopsy. When prescribing more than 6 CT courses, we were primarily guided by tolerability of therapy and the presence of residual tumor. If therapy was tolerated satisfactorily (blood parameters), we continued treatment up to 10 courses. Retrospective analysis has shown that 51 patients had no progression after CRT and 6 CT courses. In the cases, where CT was stopped or continued, MTTP was 17.7 and 17.3 months, respectively, the differences are not significant (p=0.512) (**Fig. 2**). When extending CT for more than 10 courses, we were guided by the presence of contrasted tumor remnants, absence of progression signs during continued treatment, as well as increased metabolic activity in a tumor as shown by positron emission tomography (PET) of the brain with C11 methionine. In 20 patients without progression after 10 CT courses, MTTP was 26.4 months in the cases when CT was termination, and 19.2 months when it was continued over 10 courses (p=0.015) (**Fig. 3**). The differences were not significant. This results lead to conclusion that these patients require continued antitumor therapy, by probably in other regimens.

Bevacizumab in the first-line therapy for GB

The study of Cloughesy was one of the first researches that provided the basis for the use of bevacizumab (Bev) in patients with GB progression. The study described 167 patients with GB relapse, who were treated with Bev or Bev in combination with irinotecan. Partial response (tumor reduction by 50% or more) was achieved in 28.3% of patients who received Bev and 37.8% of patients who received Bev + irinotecan; in several patients, complete response was achieved. We obtained similar results in 36 patients with GB relapse, who received combinations of various cytostatics with Bev (in Russian Federation, Bev was approved for the treatment of GB since November 2009). Partial response was achieved in 13 patients, complete response – 3 patients [9].

According to the results of Avaglio and RTOG 0825 studies, application of Bev in the first-line treatment in addition to R. Stupp's regimen increases the MTTP, but does not affect the OS. For example, MTTP was 6.2 months in patients, who were included in Avaglio and used CRT regimen with TMZ. When this regimen was supplemented with Bev at a dose of 10 mg/kg every 2 weeks starting from the first day of the CRT and further until progression, MTTP was 10.8 months. OS was 16.7 and 16.8 months, respectively [7]. Such a difference in the effect of Bev on the MTTP and OS was due to the fact that patients, who did not receive Bev in the first line treatment, received it in the second-line treatment and for this reason OS was similar in both groups of patients.

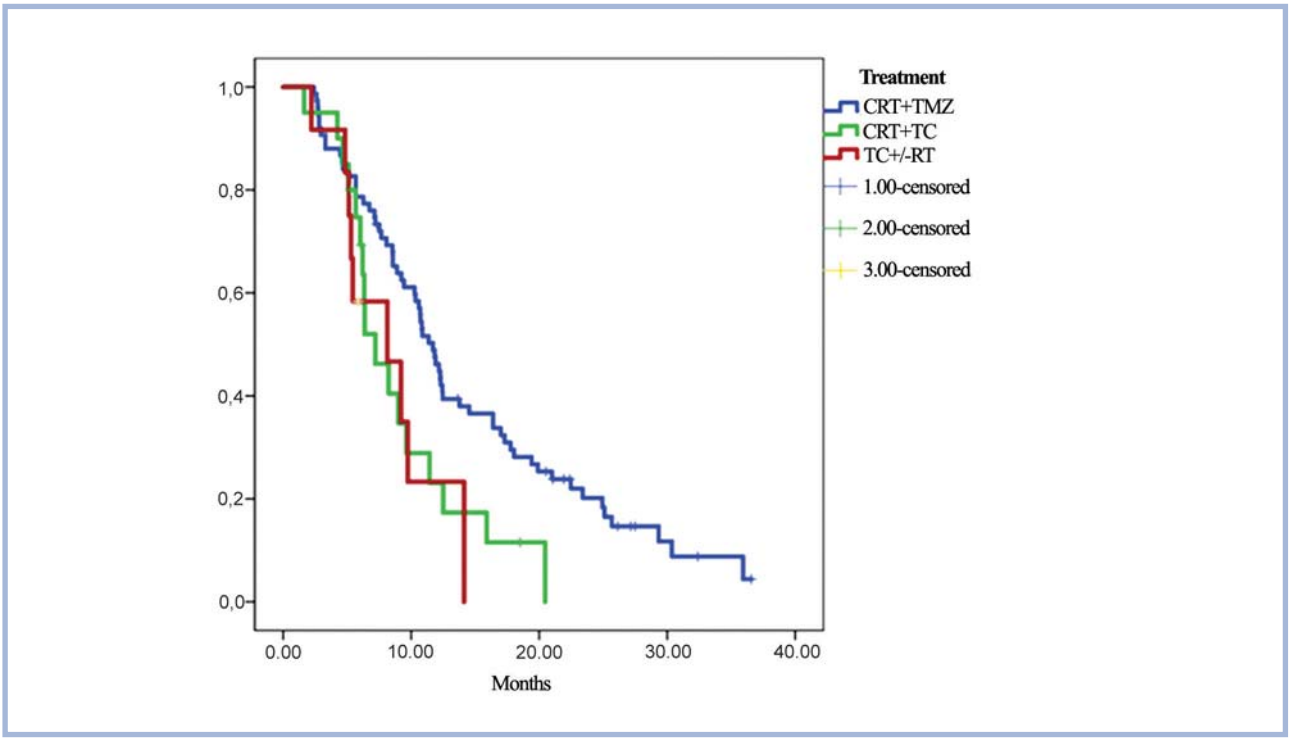

Fig. 1. **Median time to tumor progression in patients with glioblastoma who received various types of post-operative treatment.**

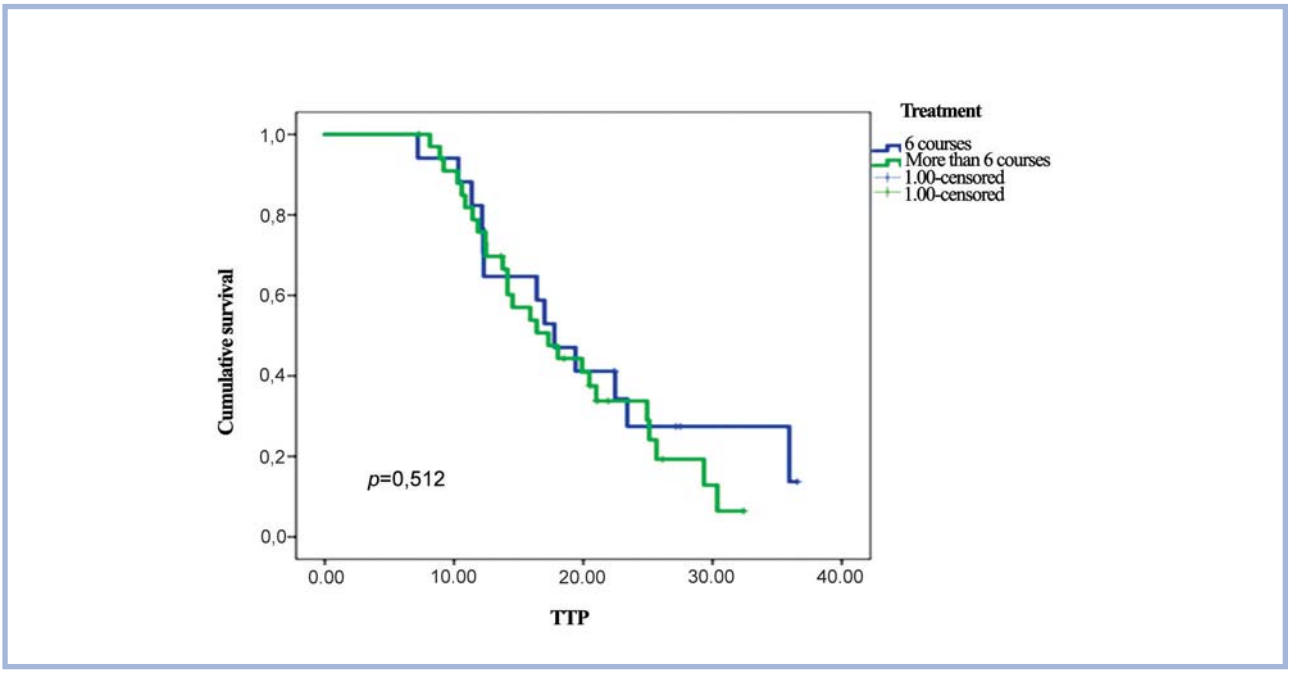

Fig. 2. **Median time to tumor progression in GB patients, who received 6 cycles of TMZ and more.**

Currently, Bev is not recommended as the first-line therapy for GB.

Criteria to assess the efficacy of treatment of central nervous system tumors

When speaking of tumor progression, the criteria for determining progression signs should be mentioned. Since 1990, criteria suggested by D. Macdonald et al. [10] were used in neuro-oncology for tumor evaluation. They take into account tumor size, the presence of new lesions, the dynamics of neurological symptoms, and the use of steroid therapy. However, these criteria can not be used to assess non-contrasted tumors, which is a drawback. Another serious problem lies in the fact that Macdonald's criteria are used for the tumors subjected to therapy with anti-angiogenic drugs (e.g., Bev), which change the permeability of the capillaries and thereby inhibit tumor contrasting. In this situation, the true spread of the tumor can only be determined in the T2/FLAIR-mode. For this reason, RANO [11] criteria are used since 2010. RANO criteria assess tumor size over time using T1 contrast-enhanced MRI and hyperintensive signal area using T2 and FLAIR modes and also take into account neurological status and the use of dexamethazone (**Table 2**).

Case report

Here we provide a case report to illustrate our treatment strategy.

Patient *C.*, 40 years old. Since May 2012, the patient experienced progressive headaches, there was an episode of generalized seizure. MRI of the brain with intravenous contrast performed on 26 May 2012 detected a mass lesion of the right temporal lobe, actively accumulating contrast and accompanied by a pronounced perifocal edema (**Fig. 4a**). Tumor was resected on 02.07.12. Histological examination identified GB. In July — August 2012, the patient underwent CRT: RT single dose of 2—3 Gy, total dose of 48 Gy (unfortunately, in some institutions in the Russian Federation, non-standard single-dose radiation therapy is used in the treatment of patients with brain tumors) with simultaneous oral intake of TMZ at a dose of 140 mg daily. MRI in September 2012 detected no contrasted tumor remnants (see **Fig. 4b**). During the period from September 2012 to July 2013, the patient underwent 11 courses of chemotherapy with oral intake of TMZ at a dose of 400 mg for 5 days every 28 days. MRI in July 2013 detected no contrasted tumor remnants (see **Fig. 4c**). In July 2013, PET of the brain with C11 methionine detected the area with enhanced accumulation of radiopharmaceutical, accumulation index (AI) 1.62, tumor remnants with moderate metabolic activity. Due to this fact, CT with TMZ was continued and a total of 17 courses were conducted by February 2014. Patient's condition was satisfactory, steroid therapy was not carried out, seizures did not recur, and the patient returned to work. During the period from February 2014 to September 2015 (20 months), chemotherapy was not carried out. Scheduled MRI in September 2015 (38 months after surgery) detected increased area of hyperintensive signal in FLAIR mode at the surgical area and in the right pole of the temporal lobe. There was no worsening of neurological symptoms. On 28.09.15, PET detected hypermetabolic area with AI of 2.05 at the pole of the temporal lobe in accordance with the changes detected by MRI, continued tumor growth (**see Fig. 4c**). During the period from

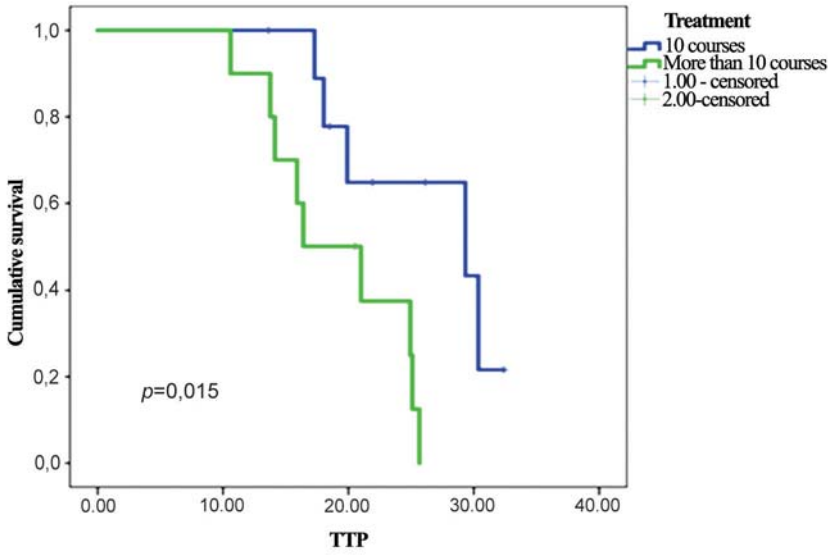

Fig. 3. **Median time to tumor progression in GB patients, who received 10 courses of TMZ and more.**

19.10.15 to 21.10.15, the patient underwent stereotactic radiotherapy using hypofractionation regimen at the area of tumor recurrence in the right temporal lobe, including 3 mm margin around this area (GTV/CTV 2.969/5.612 cm3), a total of 3 fractions, 8 Gy per fraction until average total dose of =24.82/24.1 Gy using multiple beams method (*A*=145), until total dose of 21.5 Gy prescribed at the isodose of 81%. TMZ chemotherapy was resumed from October 2015 to March 2016, a total of 6 courses were carried out. In February 2016 (44 months after surgery), MRI showed decrease in the hyperintensive signal area in FLAIR mode at the pole of the right temporal lobe and stable pattern at the surgical area. PET of the brain with C11 methionine: decreased accumulation of the radiopharmaceutical, AI 1.23 (see **Fig. 5d**). There was no worsening of neurological status. Headache and seizures did not recur since the surgery. At the time of writing of this article, 48 months have elapsed, there is no signs of disease progression.

Pseudoprogression

"Pseudoprogression" term was first suggested in 2007. Pseudoprogression (PsP) is a name for subacute changes, developing within 12 weeks after RT and characterized by X-ray picture of increase in contrasted area by more than 25%. It is believed that combined CRT with TMZ increases the incidence of PsP phenomenon. Despite the MR-signs of disease progression, spontaneous regression of both clinical symptoms and contrasted area (MRI) is subsequently observed in some of these patients. The incidence of PsP averages 20—30%. It was shown that development of PsP correlates with methylated MGMT gene in the tumor and may be a predictor of high efficacy of the therapy [12]. Therefore, the use of the aforementioned evaluation criteria is relevant no earlier than 12 weeks after completion of RT. Before that time, appearance of new lesions outside the irradiated area is the main symptom of tumor progression.

For clinicians, pseudoprogression phenomenon causes doubts in the choice of further treatment strategy. On the one hand, when ignoring the PsP phenomenon and changing treatment schedule, we deprive a patient of the possibility to continue effective and convenient therapy with TMZ. On the other hand, true progression is much more common, and in this case, continuation of previous therapy is inadvisable. A number of investigators [13] "modify" pseudoprogression criteria, considering as PsP only those cases, where increase is contrasted area is not associated with worsening of symptoms and the time acceptable for PsP diagnosis does not exceed 1 month after chemoradiotherapy.

It is highly important to distinguish between true progression and pseudoprogression, when planning a second-line therapy of GB. False-high effectiveness values can be obtained when including PsP patients in the study.

In our series, we observed increase in contrasted area by more than 25% within the period of 160 days after diagnosis, i.e. about 12 week after completion of CRT, in 17 patients (10 of these patients continued treatment). Seven (41%) of 17 patients survived for more than 1 year after detection of progression. At the time of writing of this article, 6 patients died and 1 patient is alive; overall survival in this group is 22 to 66 months (average survival is 33 months). Most likely, these 7 patients had pseudoprogression phenomenon.

Metabolic, perfusion, diffusion, and X-ray studies can be used to distinguish between progression and pseudoprogression. Further studies are required to investigate reliability and procedure of their use [12].

Table 2. **Criteria to assess the dynamics of central nervous system tumors**

	Complete response		Partial response		Stabilization		Progression	
	*M	**R	M	R	M	R	M	R
Contrasted foci in T1 mode	No	No	Decrease by 50% and more compared to the baseline	Decrease by 50% and more compared to the baseline	Any other situation	Any other situation	Increase by 25% and more compared to the baseline	Increase by 25% and more compared to the baseline
T2/FLAIR	Not considered	Stable or decrease	Not considered	Stable or decrease	Not considered	Stable or decrease	Not considered	Increase significantly
New foci	No	No	No	No	No	No	Yes	Yes
Corticosteroids	No	No	Stable or decrease	Stable or decrease	Stable or decrease	Stable or decrease	Any	Any
Clinical status	Stable or improved	Stable or improved	Stable or improved	Stable or improved	Stable or improved	Stable or improved	Worsened	Worsened
Considered in evaluation	All		All		All		Any of the above	

Note: *Macdonald's criteria; **RANO criteria.

Patients with large and inoperable GBs

In 2009, the study "Chemotherapy in the treatment of patients with inoperable malignant supratentorial astrocytic gliomas" was completed at the Burdenko Neurosurgical Institute. In this study, 37 patients with inoperable large GBs, who underwent only STB followed by CT, were treated using three regimens: PCV was used in 15 (40.5%) patients, TMZ — 5 (13.5%), TMZ + cisplatin — 17 (54%) patients. MTTP was 5, 4, and 8 months, median OS — 8.5, 6.0, and 10.5 months, respectively. In the cases, where only CT was applied, the highest direct effectiveness was obtained when using the TMZ + cisplatin regimen: complete response was observed in 2 patients, partial response — 10, stabilization — 7, and progression — 7. When using monotherapy with TMZ, stabilization was the maximum effect [14].

The study of combination of TMZ + cisplatin was preceded by a series of studies performed in patients with recurrent GB. The study by A. Brandes et al. [15] was the first and the largest series of cases that showed the efficacy of the combination of TMZ + cisplatin in patients with recurrent GB, who were not previously treated with CT. The investigation was based on in vitro study, showing that cisplatin is capable of not only reducing activity of MGMT, but also enhancing the efficacy of TMZ in this direction. Additionally, the efficacy of combination TMZ + cisplatin as the first-line treatment was shown in patients, who already received TMZ and thereafter had PROP [16]. S. Balana et al. [17] have shown the effectiveness of the use of TMZ + cisplatin as the first-line treatment in patients with verified inoperable GB.

We used carboplatin instead of cisplatin in combination with TMZ in this group of GB patients. Carboplatin is less nephrotoxic and significantly less emetogenic.

In 792 patients with advanced ovarian cancer, combination carboplatin + paclitaxel was no less effective than combination cisplatin + paclitaxel, had fewer side effects and more convenient administration regimen [18]. When comparing the effectiveness of combinations bleomycin + etoposide + carboplatin or cisplatin (BEC/BEP), it was shown that BEP is essentially superior to BEC in terms of relapse-free and overall survival [19]. Previous treatment of 618 patients with disseminated non-small cell lung cancer using carboplatin + paclitaxel or cisplatin + paclitaxel modes showed that, while the number of responses to treatment was similar, OS of patients was higher in the case of the combination cisplatin + paclitaxel, and carboplatin + paclitaxel combination is a reasonable alternative, with the same response rate, good safety profile, acceptable toxicity, and ease of application [20]. No comparative evaluation of the efficacy of the combinations cisplatin + paclitaxel and TMZ + carboplatin was carried out in patients with inoperable gliomas.

In our series, 12 patients received only CT as a first-line therapy. Multifocal GBs were detected in 4 patients, STB was performed in one of them and the rest underwent resection of one tumor node. Disseminated diffuse GB was observed in 8 patients. STB was done in 2 cases, partial tumor resection — 6. In all cases, the size of the original tumor or tumor remnants after resection excluded the possibility of RT. These 12 patients received CT in the TC mode. Six patients underwent RT after tumor size reduction. MTTP was 8.1 months in the entire group.

Based on the available data on the effectiveness of TMZ in combination with platinum preparations in patients with large GBs, we administered TC after completion of CRT in patients with partially resected GBs, a total of 20 patients. Of these, tumor progression before completion of 6 CT courses was observed in 16 patients. Four patients continued treatment for more than 6 courses, including 3 patients who had progression after 8, 9 and 12 courses, respectively. The treatment was

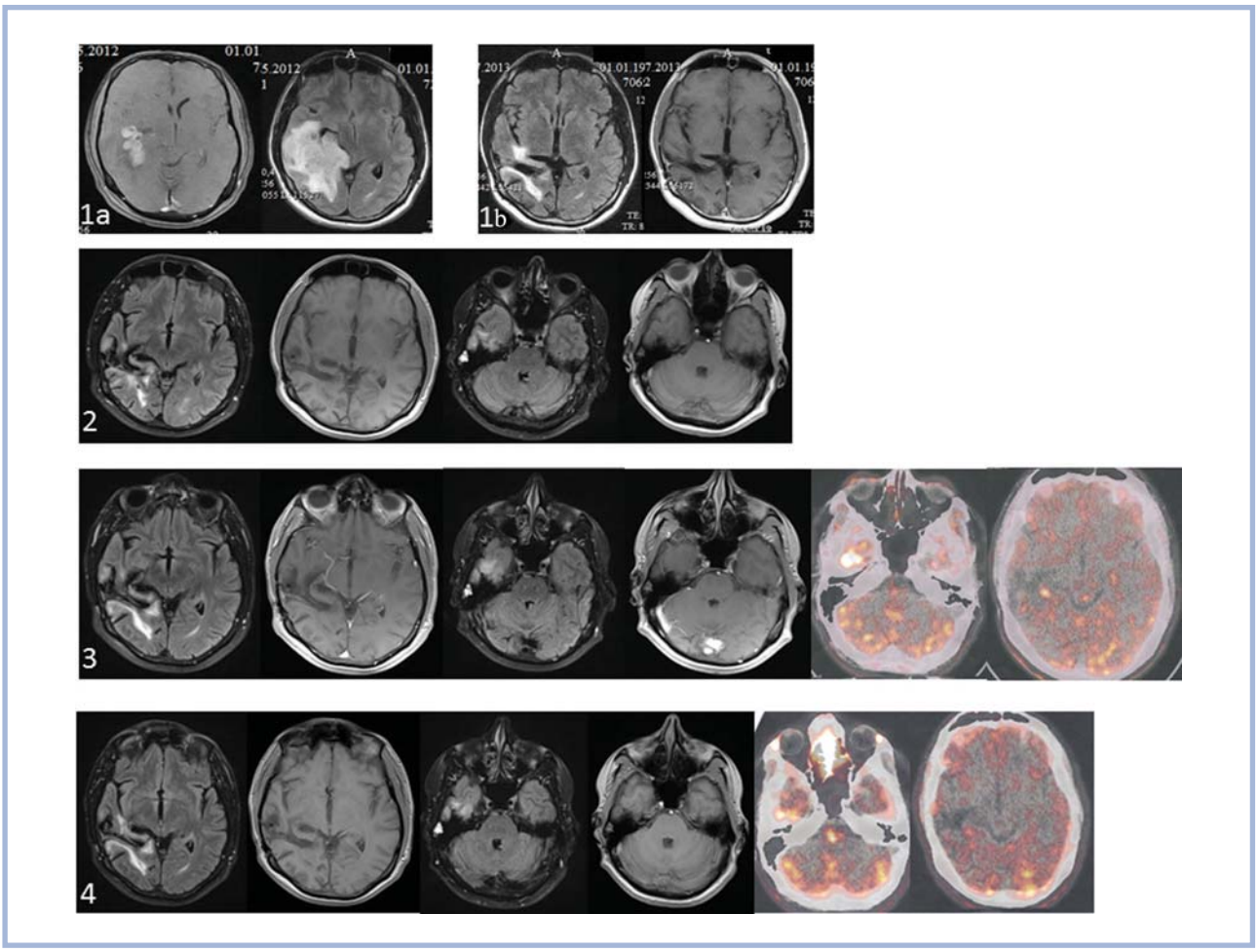

Fig. 4. **Example of treatment of a patient with glioblastoma of the right temporal lobe.**

Explanation in the text.
1, a — preoperative MRI; 1,b — MRI 2 months after surgery; 2 — MRI one year after surgery; 3 — PET and MRI 38 months after surgery, tumor progression; 4 — PET and MRI 44 months after surgery, positive dynamics.

stopped after 10 courses in 1 patient. The median time to progression in this group was 7.2 months.

Historical data show that patients with inoperable GBs who receive only symptomatic therapy survive for about 3 months, while those who receive radiotherapy survive for 6—7 months [21]. Therefore, temozolomide + cisplatin and TMZ + carboplatin regimens can be recommended for the use in patients with disseminated diffuse glioblastoma. However, in spite of the improved OS, the results of treatment of patients with large GBs remain unsatisfactory.

Early tumor progression in these patients is indicative of relatively low efficacy of therapy and the need for more effective medications, for example, Bev.

As mentioned above, the results of randomized phase III studies show that Bev is not indicated in the first-line treatment of GB. However, data analysis by O. Chinot have shown that the use of Bev in the first-line treatment has different effects on survival of patients with various subtypes of GB. Thus, in patients with proneural GB and no mutations of IDH1 gene, who received Bev in the first-line treatment, OS was 17.1 months, while in the placebo group it was 12.8 months ($p = 0.002$) [22]. It was also shown that the use of Bev resulted in significantly longer time to worsening of overall health status, physical and social functioning, communication, and motor deficits. It was reported that Bev can effectively reduce the cerebral edema [23].

It should also be noted that the criteria for inclusion of patients to Avaglio and RTOG 0825 implied that they have Karnofsky score of 70 or higher, while the majority of patients in our series who received TC had a lower score. Thus, taking into account high direct efficacy of Bev, which was detected both clinically and in MRI studies, it is reasonable to examine its efficacy in the first-line treatment of patients with diffuse disseminated GB. The factors, predicting beneficial effect of Bev, such as GB subtype, serum level of matrix metalloproteinase, and methylation status of the MGMT gene, should be studied.

Conclusion

Chemoradiation therapy with temozolomide followed by a year-long temozolomide monotherapy is an optimal treatment regimen for patients who underwent resection of GB. A third of patients treated using this approach have no signs of tumor progression during the first year. Thorough study of clinical and radiological findings in the course of treatment makes it possible to achieve maximum efficacy, avoid unreasonably early switch to second-line therapy, and timely detect tumor recurrence signs. The Response Assessment in Neuro-Oncology (RANO) criteria should be used to assess MRI-detected changes in the tumor size. The rates of overall and recurrence-free survival were significantly lower in patients with inoperable or partially resected tumors. The applied approaches provide only a slight advantage in control of tumor growth, which necessitates the search for more effective treatment options for these patients. Inclusion of bevacizumab to the first-line therapy regimen may be a possible approach.

Commentary

This work focuses on an obviously important issue, the treatment of patients with brain glioblastomas. Strength of this study lies in the analysis of authors' own results of treatment of patients in their routine practice, careful follow-up history taking, thoughtful analysis of the results, and the use of both international and Russian studies in their discussion. The authors collected information about 107 patients treated at the Burdenko Neurosurgical Institute in 2010—2012. Treatment of glioblastomas is expensive, and for this reason in does not meet international standards in a significant number of cases in Russia. The situation, when a large number of patients were treated at the same institution in full compliance with its standards, is quite rare. However, as shown in this study, this approach enables not only reproducing, but also going beyond the results of treatment obtained in the world's best clinics. The authors' findings, demonstrating that there is no need to increase the number of temozolomide chemotherapy courses to more than six, is important from a practical viewpoint.

A.V. Smolin (Moscow, Russia)

There is no conflict of interest.

REFERENCES

1. Michaud DS, Zhou J, Batchelor TT. Cancer and the Nervous System — Chapter 52A. *Epidemiology of Brain Tumors*: Elsevier Inc., Ltd., BV;1107-1100. doi: 10.1016/B978-1-4377-0434-1.00067-0
2. Stupp R, Mason WP, van den Bent MJ, Weller M, Fisher B, Taphoorn MJ, Belanger K, Brandes AA, Marosi C, Bogdahn U, Curschmann J, Janzer RC, Ludwin SK, Gorlia T, Allgeier A, Lacombe D, Cairncross JG, Eisenhauer E, Mirimanoff RO. Radiotherapy plus Concomitant and Adjuvant Temozolomide for Glioblastoma. *Oncology Times*. 2005;27(9):15-16. doi: 10.1097/01.cot.0000289242.47980.f9
3. Gilbert MR, Wang M, Aldape KD, Stupp R, Hegi ME, Jaeckle KA, Armstrong TS, Wefel JS, Won M, Blumenthal DT, Mahajan A, Schultz CJ, Erridge S, Baumert B, Hopkins KI, Tzuk-Shina T, Brown PD, Chakravarti A, Curran WJ, Mehta MP. Dose-Dense Temozolomide for Newly Diagnosed Glioblastoma: A Randomized Phase III Clinical Trial. *Journal of Clinical Oncology*. 2013;31(32):4085-4091. doi: 10.1200/jco.2013.49.6968
4. Standards, options, recommendations for the treatment of primary CNS tumors (2012—2013). *Assotsiatsiya neirokhirurgov Rossii*. 2013. (In Russ.).
5. Smolin AV, Bekyashev AH, Kobyakov GL, Sharabura TM, Mufazalov FF, Kanischeva NV, BumaginaVO. First results of the russian multicenter epidemiology project on the malignant gliomas. *Journal of modern oncology*. 2014;16(2):50-55. (In Russ.).
6. Kobyakov GL, Borisov VI,Absalyamova OV, Amanov RD, Korshunov AG, Golanov AV. Chemoradiotherapy with temozolomide patients with glioblastoma. *Farmateka*. 2008;18:67-72.
7. Chinot OL, Wick W, Mason W, Henriksson R, Saran F, Nishikawa R, Carpentier AF, Hoang-Xuan K, Kavan P, Cernea D, Brandes AA, Hilton M, Abrey L, Cloughesy T. Bevacizumab plus Radiotherapy–Temozolomide for Newly Diagnosed Glioblastoma. *New England Journal of Medicine*. 2014;370(8):709-722. doi: 10.1056/nejmoa1308345
8. Friedman H, Prados MD, Wen PY, Mikkelsen T, Schiff D, Abrey LE, Alfred Yung AWK, Paleologos N, Nicholas MK, Jensen R, Vredenburgh J, Huang J, Maoxia Zheng, Cloughesy T. Bevacizumab Alone and in Combination With Irinotecan in Recurrent Glioblastoma. *Journal of Clinical Oncology*. 2009;27(28):4733-4740. doi: 10.1200/jco.2008.19.8721
9. Kobyakov GL, Absalyamova OV, Urakov SV, Smolin AV, Strazhev SV. Antiangiogenic therapy in glioblastoma treatment: review and personal experience. *Journal of modern oncology*. 2012;2:31-37. (In Russ.).
10. Macdonald D, Cascino T, Schold S. Response criteria for phase II studies of supratentorial malignantglioma. *J Clin Oncol*. 1990;8:1277-1280.
11. Linhares P, Carvalho B, Figueiredo R, Reis R, Vaz R. Early Pseudoprogression following Chemoradiotherapy in Glioblastoma Patients: The Value of RANO Evaluation. *Journal of Oncology*. 2013;2013:1-9. doi: 10.1155/2013/690585
12. Yoo RE, Choi SH. Recent Application of Advanced MR Imaging to Predict Pseudoprogression in High-grade Glioma Patients. *Magn Reson Med Sci*. 2016;15(2):165-177. doi: 10.2463/mrms.rev.2015-0053
13. Chinot O, Macdonald D, Abrey L, Zahlmann G, Kerloëguen Y, Cloughesy T. Response Assessment Criteria for Glioblastoma: Practical Adaptation and Implementation in Clinical Trials of Antiangiogenic Therapy. *Current Neurology and Neuroscience Reports*. 2013;13(5). doi: 10.1007/s11910-013-0347-2
14. Amanov RD. *Chemotherapy in the treatment of patients with inoperable malignant supratentorial astrocytic gliomas:* Dissertatsiya na soiskanie uchenoi stepeni kandidata meditsinskikh nauk. M. 2009. (In Russ.).

15. Brandes A, Basso U, Reni M, Vastola F, Tosoni A, Cavallo G, Scopece L, Ferreri AJ, Panucci MG, Monfardini S, Ermani M. First-Line Chemotherapy With Cisplatin Plus Fractionated Temozolomide in Recurrent Glioblastoma Multiforme: A Phase II Study of the Gruppo Italiano Cooperativo di Neuro-Oncologia. *Journal of Clinical Oncology*. 2004;22(9):1598-1604.

doi: 10.1200/jco.2004.11.019

16. Zustovich F, Lombardi G, Puppa A, Rrotilio A, Sscienza R, Pastorelli D. A Phase II Study of Cisplatin and Temozolomide in Heavily Pre-treated Patients with Temozolomide-refractory High-grade Malignant Glioma. *Anticancer Research*. 2009 October;29:10:4275-4279.

17. Balana C, López-Pousa A, Berrocal A, Yaya-Tur R, Herrero A, García JL, Martín-Broto J, Benavides M, Cerdá-Nicolás M, Ballester R, Balart J, Capellades J. Phase II study of temozolomide and cisplatin as primary treatment prior to radiotherapy in newly diagnosed glioblastoma multiforme patients with measurable disease. A study of the Spanish Medical Neuro-Oncology Group (GENOM). *J Neurooncol*. 2004;70(3):359-370.

doi: 10.1007/s11060-004-9175-1

18. Ozols RF, Bundy BN, Greer BE, Fowler JM, Clarke-Pearson D, Burger RA, Mannel RS, DeGeest K, Hartenbach EM, Baergen R. Phase III Trial of Carboplatin and Paclitaxel Compared With Cisplatin and Paclitaxel in Patients With Optimally Resected Stage III Ovarian Cancer: A Gynecologic Oncology Group Study. *Journal of Clinical Oncology*. 2003;21(17):3194-3200.

doi: 10.1200/jco.2003.02.153

19. Horwich A, Sleijfer DT, Fosså SD, Kaye SB, Oliver RT, Cullen MH, Mead GM, de Wit R, de Mulder PH, Dearnaley DP, Cook PA, Sylvester RJ, Stenning SP. Randomized Trial of Bleomycin, Etoposide, and Cisplatin Compared With Bleomycin, Etoposide, and Carboplatin in Good-Prognosis Metastatic Nonseminomatous Germ Cell Cancer: A Multiinstitutional Medical Research Council/European Organization for Research and Treatment of Cancer Trial. *The Journal of Urology*. 1998;159(3):1099-1100.

doi: 10.1016/s0022-5347(01)63845-x

20. Rosell R, Gatzemeier U, Betticher DC, Keppler U, Macha HN, Pirker R, Berthet P, Breau JL, Lianes P, Nicholson M, Ardizzoni A, Chemaissani A, Bogaerts J, Gallant G. Phase III randomised trial comparing paclitaxel/carboplatin with paclitaxel/cisplatin in patients with advanced non-small-cell lung cancer: a cooperative multinational trial. *Annals of Oncology*. 2002;13(10):1539-1549.

doi: 10.1093/annonc/mdf332

21. Nieder C, Grosu A, Astner S, Molls M. Treatment of unresectable glioblastoma multiforme. *Anticancer Res*. 2005 Nov-Dec;25(6C):4605-4610.

22. Sandmann T, Bourgon R, Garcia J, Li C, Cloughesy T, Chinot OL, Wick W, Nishikawa R, Mason W, Henriksson R, Saran F, Lai A, Moore N, Kharbanda S, Peale F, Hegde P, Abrey LE, Phillips HS, Bais C. Patients With Proneural Glioblastoma May Derive Overall Survival Benefit From the Addition of Bevacizumab to First-Line Radiotherapy and Temozolomide: Retrospective Analysis of the AVAglio Trial. *Journal of Clinical Oncology*. 2015;33(25):2735-2744.

doi: 10.1200/jco.2015.61.5005

23. Smolin AV, Konev AV, Kobyakov GL, Nikolaeva SN, Shamanskaya YuE, Gorbunov AV. Bevacizumab in combination with chemoradiotherapy in patients with glioblastoma. *Journal of Modern Oncology. 2013;03:16-23. (In Russ.)*.