doi: 10.17116/neiro201579366-74

Cardiac Arrest after Induction of Anesthesia in Neurosurgical Patients (Analysis of Two Clinical Cases)

A.YU. LUBNIN*, L.A. ISRAELYAN, V.N. SHIMANSKIY, D.A. ODAMANOV

Burdenko Neurosurgical Institute, Moscow, Russia

The paper reports two clinical cases observed in the Burdenko Neurosurgical Institute with a time lag of four years. Both patients showed severe clinical symptoms of intracranial hypertension before surgery. Immediate full-scale resuscitation was required in both cases due to asystole that developed immediately after induction of anesthesia and tracheal intubation. **Objective.** The objective of the study was to analyze the possible causes of the complication and preventive measures. **Material and Methods.** The first patient (33 years of age) diagnosed with multiple space-occupying brain lesions underwent resuscitation for cardiac arrest after induction of anesthesia, but emergency measures were not effective and the patient was certified dead. The second patient (28 years of age) diagnosed with cystic cerebellar tumor also experienced cardiac arrest after induction of anesthesia. During resuscitation, the anterior horn of the right lateral ventricle was punctured and then cardiac activity was successfully recovered. **Results.** In both patients, tonsillar herniation into the foramen magnum after induction of anesthesia was detected based on the clinical presentation, postmortem diagnosis, and successful drainage of the cerebrospinal fluid. Possible causes of complications and preventive measures were discussed. Conclusion. Under certain circumstances, neurosurgical patients with intact cardiovascular system can face a risk of cardiac arrest at any stage of surgery. In neurosurgical patients, a cystic mass compressing the floor of the fourth ventricle and hypertensive crisis before surgery are the risk factors for tonsillar herniation into the foramen magnum after induction of anesthesia, followed by cardiac arrest.

Keywords: *intracranial hypertension, anesthesia, cardiac arrest.*

Cardiac arrest in patients at any stage of anesthesia is always difficult and disastrous for both the patient and anesthesiologist. The problem is complex and multidimensional, so let us specify right away that it comes not for patients with severe cardiovascular pathology (in the case of cardiovascular pathology, the risk of this complication is quite evident), but for those with the intact cardiovascular system. Neurosurgical patients with intracranial pathology are at the risk of this severe complication under certain circumstances. The description of two similar clinical cases observed in our practice at two-year intervals is presented below and analyzed with allowance for literature data.

Description of clinical cases

Case report 1

A 33-year-old male patient *K.*, a truck driver with body weight of 57 kg, was admitted to the Burdenko Neurosurgical Institute with a diagnosis of "multiple space-occupying brain lesions" in November, 2007. His past medical history revealed that the first signs of the disease appeared in August, 2007 as coordination impairments followed later by headaches. Impairment of health occurred after 2 months when the intensity and incidence of headaches sharply increased. Examination of the patient at the Burdenko Neurosurgical Institute revealed balance and gait impairments and incoordination in the limbs on the background of pronounced intracranial hypertension characterized by morning headaches, nausea, vomiting, and retinal venous congestion. CT and MRI of the brain and cervical spine revealed multiple intracranial cystic neoplasms: a large node in the fourth ventricle projection and three nodes in the left occipital region **(Fig. 1)**. Interestingly, no typical hydrocephalus (enlargement of the ventricles) was observed. Physical status of the patient revealed no significant anomalities with the exception of resting ECG signs of inadequate coronary blood supply into the high lateral regions of the left ventricle **(Fig. 2)**, in the absence of any clinical symptoms.

On the basis of clinical presentation and MRI data, which showed a multifocal and multiple lesion, the presence of a pronounced cystic component, and the absence of perifocal edema, parasitic brain infection (cerebral echinococcosis) was suspected. For this reason, the patient consulted the specialists of the Department of Medical Parasitology and Tropical Medicine at the Clinical Center of the I.M. Sechenov First MGMU. According to their recommendations, the patient underwent ultrasound of the abdominal and pleural cavities and urogenital ultrasound; however, neither any abnormalities were detected, nor were specific antibodies in his blood. Given the severe syndrome of intracranial hypertension and the lack of signs of damages to internal organs, the treatment strategy was as follows: intracranial neurosurgical procedure with single-stage resection of the abnormal nodes in the

© Group of authors, 2015

*e-mail: lubnin@nsi.ru

occipital lobe and lumen of the fourth ventricle, followed by antiparasitic chemotherapy in the postoperative period. The day before surgery, the patient felt a sudden headache followed by nausea and vomiting and his upward glance was restricted, which was regarded as occlusive hydrocephalus. The latter was stopped using the conventional method, and the doctors on duty were recommended to apply the external ventricular drainage in the case of recurrent attack.

On the morning of the surgery, the patient was transferred to the operating room without any premedication. In the operating room, the catheter was inserted into his peripheral vein, through which he received initial crystalloid infusion. During standard monitoring (3-lead electrocardiogram (ECG), noninvasive blood pressure monitoring, capnography, and pulse oximetry) the patient intravenously received: Dormicum (5 mg), propofol (200 mg), fentanyl (0.2 mg), rocuronium bromide (4 mg), and Lysthenon (200 mg). As these drugs began to work, supportive mechanical ventilation with 100% oxygen using an oxygen mask of the anesthetic machine was initiated. Tracheal intubation was successful at the first try and caused no complications. Mechanical ventilation was provided through the endotracheal tube as the intermittent positive-pressure ventilation. After 3 minutes, however, persistent bradycardia was detected (heart rate was as low as 30 bpm) and the blood pressure (BP) rapidly fall to

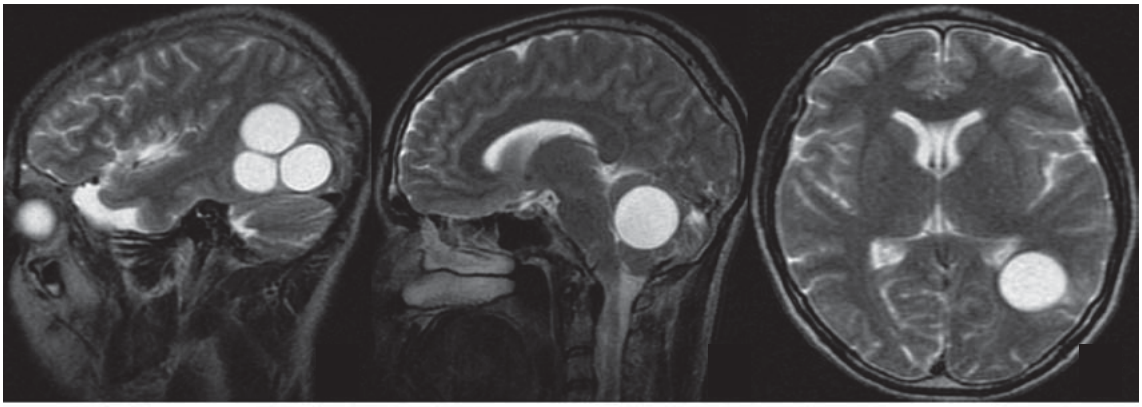

Fig. 1. **T2-weighted MRI of the male patient *K.*, sagittal (a and b) and axial (c) views, 19 days before surgery.**

Three cystic nodes in the left occipital region (a) and in the cavity of the fourth ventricle (b) with the absence of perifocal brain edema are visualized. Insignificant tonsillar herniation below the foramen magnum level, the absence of hydrocephalus, and displacement of medial brain structures are noteworthy.

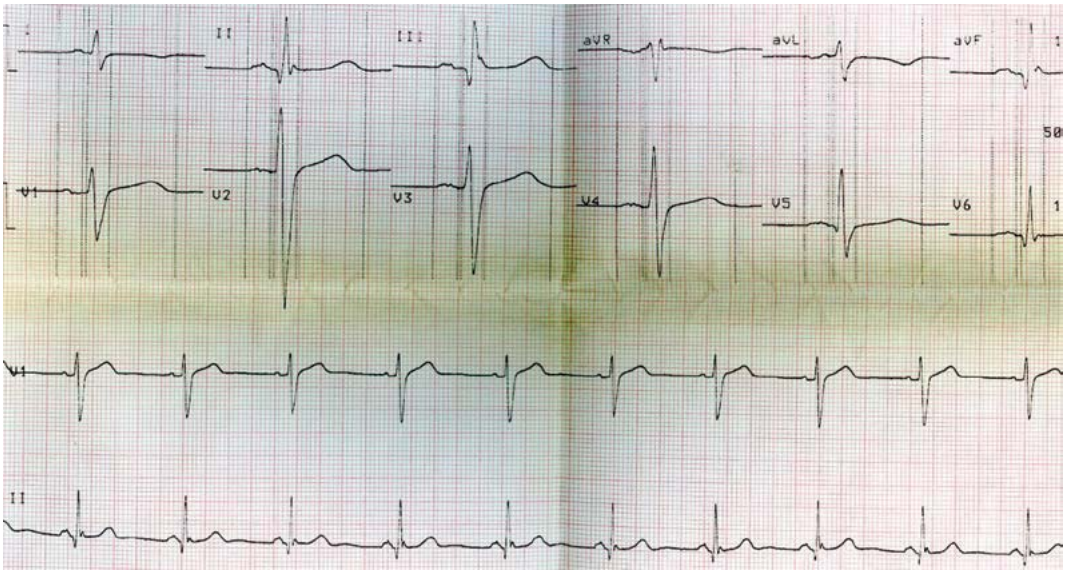

Fig. 2. **Preoperative ECG of the patient *K.***

Signs of slightly reduced coronary blood flow into the superolateral left ventricle.

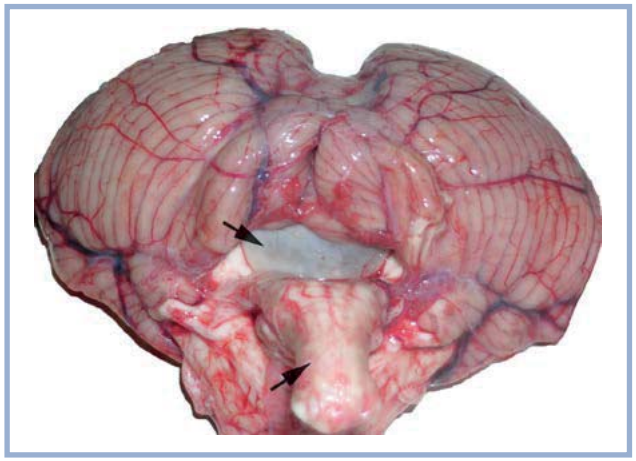

Fig. 3. **Brainstem edema (autopsy material of the patient *K.*) with a constriction mark at the foramen magnum level (edema is indicated by the lower arrow).**

A parasitic cyst is visualized in the lumen of the fourth ventricle, causing occlusion (the cyst is indicated by the upper arrow).

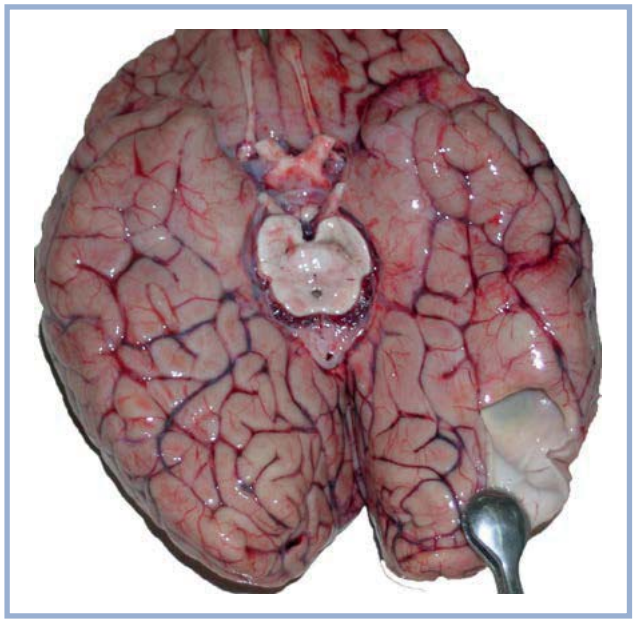

Fig. 4. **Parasitic cysts in the left occipital lobe of the brain (autopsy material of the patient *K.*). One of the cysts appeared on the brain surface.**

70/30 mmHg. Subsequently, asystole was visualized on the monitor; BP was not detectable. In this regard, full-scale resuscitation was initiated immediately (closed-chest massage, catheterization of the right subclavian vein, bolus infusion of 6% hydroxyethyl starch solution and soda, intravenous administration of sympathomimetic drugs and corticosteroids, and repeated defibrillation). However, the aforementioned resuscitation failed and the patient was certified death after 40 minutes.

Postmortem examination confirmed the clinical diagnosis of the parasitic brain infection **(Figs. 3, 4)**. Disseminated parasitic infection to the internal organs, which was not diagnosed preoperatively by ultrasound, was detected (multiple cysts in the liver, kidneys, and even in the myocardium) **(Figs. 5—7).** This finding, as well as a scar in the posterior part of the apical region of the interventricular septum could explain the ECG changes in a young person with no coronary artery disease. Three cysts with transparent colorless liquid content were observed in the occipital lobe of the left cerebral hemisphere. A similar cyst was observed in the lumen of the fourth ventricle. Brain tissue was edematous, with signs of cerebellar tonsillar herniation into the foramen magnum, which was the cause of death.

Case report 2

A 28-year-old male patient *O.*, a dentist with body weight of 62 kg, was admitted to the Burdenko Neurosurgical Institute with a diagnosis of "cystic tumor of the cerebellum, occlusive hydrocephalus". After a viral infection three months before admission, the patient complained of periodic headaches, nausea, and vomiting, as well as of dizziness, gait impairment, and coordination impairment in both hands. A significant worsening of the neurological symptoms in the form of headache aggravation occurred one week before the admission to the Burdenko Neurosurgical Institute. MRI of the brain revealed a cerebellar mass with a cystic component and occlusive hydrocephalus **(Fig. 8)**.

The patient was presented with relatively satisfactory condition during examination at the Burdenko Neurosurgical Institute. On the background of the intracranial hypertension syndrome presented by paroxysmal hemicrania with nausea and vomiting during the acute phase, the clinical presentation of the disease included symptoms of the posterior cranial fossa (PCF) lesions causing multiple spontaneous horizontal nystagmus, balance and gait impairments, and incoordination of the upper and lower limbs. Ophthalmoscopy revealed no signs of intracranial hypertension.

No anomalities were observed in the physical status of the patient, including the state of the cardiovascular system. Previously, the patient had undergone only one surgical intervention (rhinoplasty). On the basis of the ECG results, no anomalities were observed except the insignificant intraventricular conduction delay **(Fig. 9)**.

The day before surgery, the symptoms of acute occlusive hydrocephalus were developed, so the possibility of applying the external ventricular drainage was discussed, but the crisis was stopped by drug administration. The patient was leaved under supervision of the doctors on duty with instructions to use the ventricular drainage immediately in the case of a recurrent attack.

The next morning, the patient was transferred to the operating room without any preanesthetic medication. After the peripheral venous catheter was inserted, intravenous crystalloid infusion was initiated. The

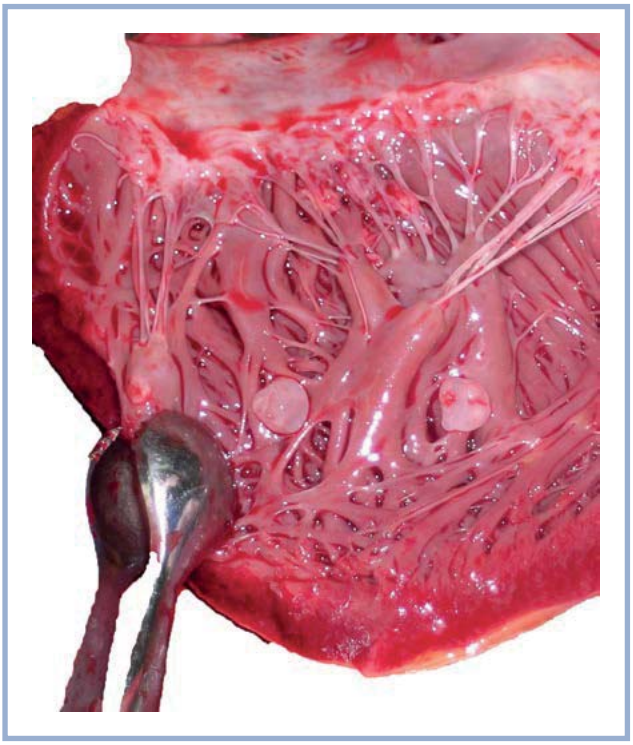

Fig. 5. **Ventricular cavity of the heart (autopsy material of the patient *K.*) with a variety of parasitic cysts affecting trabeculae.**



Fig. 6. **Parasitic cysts in the liver parenchyma (autopsy material of the patient *K.*).**

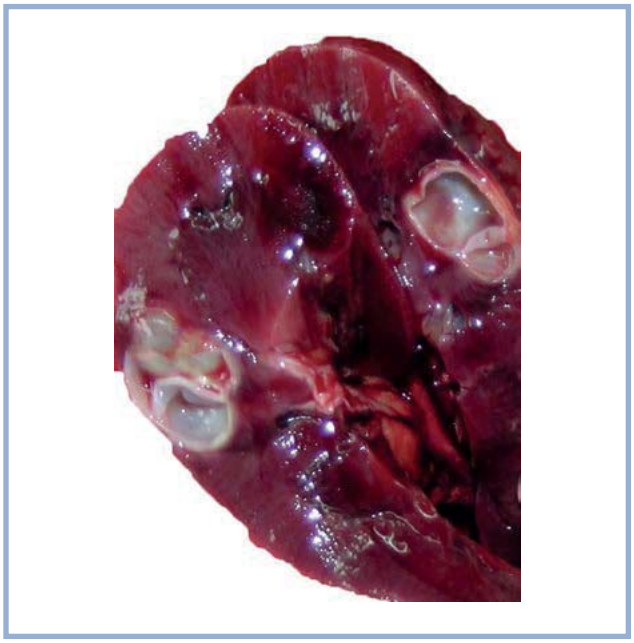

Fig. 7. **Parasitic cysts in the renal cortex (autopsy material of the patient *K.*)**

monitoring included: noninvasive and invasive BP monitoring (the catheter was placed into the left radial artery under local anesthesia before induction of general anesthesia), 3-lead ECG, pulse oximetry, and capnography. Anesthesia was inducted with intravenous injection of a combination of propofol (150 mg), fentanyl (0.2 mg), lidocaine (80 mg), and Esmeron (50 mg). Intubation of trachea was performed at the first try and with no technical difficulties. Mechanical ventilation was provided through a tracheostomy tube in a moderate hyperventilation mode (CO_2 level in the expired air was 34 mmHg). When the stable anesthesia was achieved (intravenous administration of propofol and fentanyl with the bispectral index monitoring), sudden asystole was registered on the monitor during the right subclavian vein catheterization. Emergency resuscitation included: closed-chest massage, mechanical ventilation with 100% oxygen, intravenous crystalloid infusion, and then HyperHAES (250 mL), soda, as well as intravenous atropine, epinephrine, and dexamethasone. Single defibrillation allowed to restore the own heart rate of the patient. During resuscitation, neurosurgeons punctuated the anterior horn of the right lateral ventricle during 2—3 minutes. The thus obtained transparent colorless cerebrospinal fluid outflowed under high pressure (as a liquid jet), so external ventricular drain system was adjusted. Within 30 minutes, the doctors managed to fully stabilize the cerebral hemodynamics and made a coordinated decision to move forward with surgery.

With the patient lying in the prone position, the occipital squama over the medial regions in both hemispheres and the part of the arch of the atlas were resected via midline suboccipital approach. Hemangioblastoma (angioreticuloma) of the cerebellar hemisphere was resected. The duration of the surgery was 4.5 hours; blood loss was less than 500 mL.

The postoperative period was complicated, but no major problems occurred. During the patient's stay in the intensive care unit (5 days), he fully recovered consciousness on the background of stable vital functions, and then he was transferred to his ward. However, during feeding after 2 days, the aspiration of food occurred and the patient was transferred again to the intensive care unit and underwent percutaneous dilatational tracheostomy for the purpose to protect the respiratory tracts from aspiration on the background of pronounced pseudobulbar disorders. After 3 days, the patient was transferred again to his ward. Further healing proceeded normally. The patient was discharged on the 15th

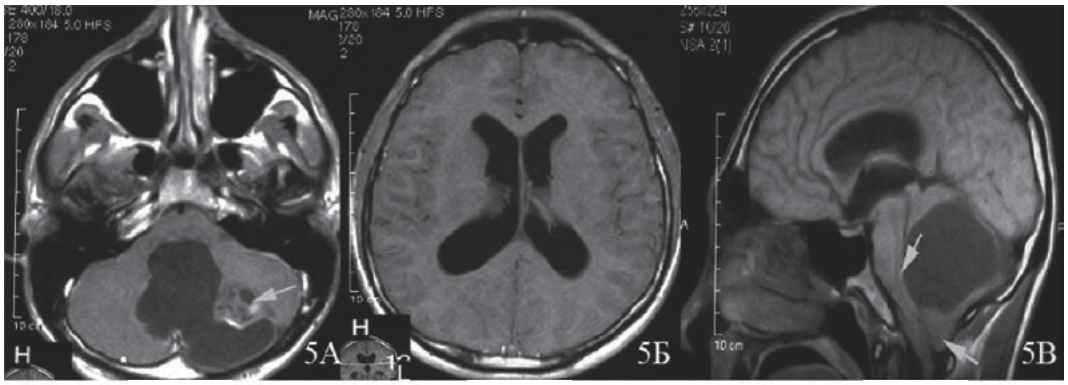

Fig. 8. **T1-weighted MRI of the brain of the male patient *O.*: axial (a and b) and sagittal (c) views, before surgery.**

Tumor of the PCF includes a significant component in the left cerebellar hemisphere (a — the tumor is shown by the arrow) and a large cyst compressing the fourth ventricle in the projection of the left hemisphere and cerebellar vermis (c — the cyst is shown by the upper arrow). The tumor caused tonsillar herniation into the foramen magnum (c — the bottom arrow) and occlusive hydrocephalus.

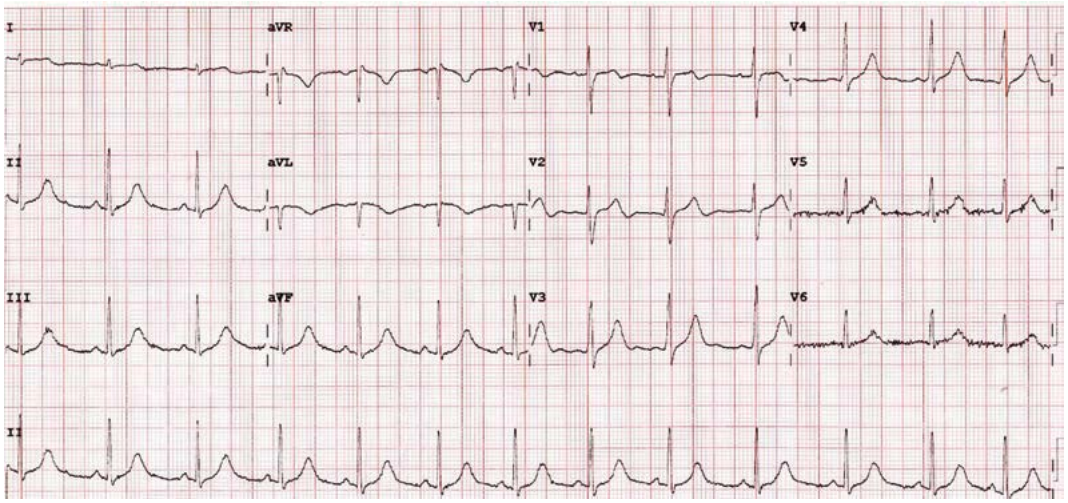

Fig. 9. **ECG of the patient *O.*, before surgery. No anomalities were detected.**

postoperative day. At that time, the neurological symptoms regressed, endotracheal tube was removed, and mental and emotional well-being of the patient was stabilized.

Discussion

Two aforementioned clinical cases significantly differ from each other in the main clinical diagnosis and outcome. But still they also have certain similarities, which allows making the following conclusions after analysis of these clinical cases:

1. Both patients were young males without any severe chronic cardiac pathology. However, before surgery, the first of them showed difficult to be explained ECG changes, and bullae of echinococcus in his heart and scars of unknown origin were revealed during his autopsy, but all of this could hardly be the cause of a sudden asystole unresponsive to resuscitation.

2. In both patients, acute intracranial process caused the development of the intracranial hypertension syndrome; the second patient also experienced severe occlusive hydrocephalus. In both cases, clinical symptoms of intracranial hypertension were the main manifestation of the disease and developed rapidly. This fact can possibly explain the absence of papilledema.

3. In both patients, clinical symptoms indicated extremely severe intracranial hypertension. Moreover, on the background of clear consciousness on the day before surgery, both patients showed clinical symptoms

of occlusive hydrocephalus in the form of an episode of severe headache, nausea, vomiting, and upward glance limitation. For both patients, teams of doctors on duty discussed the necessity of the external ventricular drainage, but they still refused to use it due to the effects of dehydration therapy and the lack of vital impairments after the procedure.

A fundamental question arises: what happened to our patients at the stage of induction of anesthesia and tracheal intubation, which caused sudden asystole on the background of initially intact cardiovascular system, and what exactly happened in the preoperative phase of the surgery?

According to the literature, in any person, sudden cardiac arrest may be caused by several problems, with cardiological problems taking the leading positions [1]. In neurosurgical patients, asystole may be caused by various reasons as well, but they significantly differ from those that cause sudden asystole in patients with no cerebral disease. In a similar way, acute subarachnoid hemorrhage (ASH) from a cerebral aneurysm may manifest [2]. Moreover, aneurysmal ASH is now recognized as the most common neurological cause of asystole. However, our patients had other neurosurgical pathology.

In patients with epilepsy, the phenomenon of a sudden unexpected death in epilepsy (SUDEP) is described, explaining more than 20-fold higher risk of a sudden death in epilepsy compared to the general population [3]. The main causes of sudden death in these patients are recognized as follows: respiratory depression due to seizures, cardiac arrhythmia, cerebral depression, and autonomic dysfunction. However, our patients did not have epilepsy.

Brain herniation and impaction (into the Bichat's fissure and foramen magnum) can manifest with asystole on the background of the formation of space-occupying brain lesion. Such situations occur after lumbar puncture that forms a caudal dislocation gradient even if withdrawing a small amount of cerebrospinal fluid [4—6]. Brain herniation causing the cardiac arrest may develop in the cranial direction due to rapid ventricular decompression, as described by C. Bahl and S. Wadwa [7]. In that case, resuscitation was ineffective until the dislocation gradient was eliminated after infusion of saline solution. Perhaps, that situation seems to be very similar to our cases, but with certain restrictions. It is described in more detail at the end of the discussion.

During anesthesia and surgery, neurosurgical patients may show their own specific causes of asystole. One of the most common causes of asystole at the beginning of the surgery in neurosurgical patients with paretic limbs is the use of depolarizing muscle relaxants such as suxamethonium chloride [8—10]. The analysis of a large number of such cases revealed the cause: the administration of a depolarizing muscle relaxant causes asynchronous contraction of skeletal muscles (fasciculation), which results in the potassium release from myofibrils; especially high potassium content is in paretic muscles. The sudden release of such amount of potassium into the blood flow creates favorable conditions for hyperkalemia-induced cardiac arrest. In addition, in this situation, the level of the potassium increase in the blood serum is more significant than the absolute values, which may be normal. At present, this situation is well-known in clinic, the schemes to overcome it are developed (the risk groups for this complication; preliminary administration of the depressing subapneic dose of nondepolarizing muscle relaxants or refusal of their use in general), and it is no longer a serious clinical problem today.

Trigeminocardiac reflex during surgical interventions on the structures of the PCF is likely the most studied (after the massive intraoperative blood loss) situation related to intraoperative cardiac arrest in neurosurgical patients [11—13]. However, the development of trigeminocardiac reflex is also described in the case of transnasal pituitary surgery [14, 15] and various cranio-maxillofacial surgeries [16]. As for the trigeminocardiac reflex, it is characterized by the sudden onset of progressive bradycardia (up to the development of asystole) during surgical manipulations near the trigeminal nerve or its branches. The immediate cessation of surgical manipulations and intravenous infusion of anticholinergic drugs are highly effective, and resuscitation is not required in most cases.

Venous air embolism (VAE) is another possible risk factor of intraoperative asystole in neurosurgery. A classic example of VAE development is neurosurgical interventions on the PCF structures or occipital lobes, with a patient placed in the sitting position [17—20]; however, in the literature, there is a series of publications describing the development of massive and even fatal VAE during spinal neurosurgical interventions, with a patient being in the lying position [21—23]. Acute massive VAE can actually cause asystole, but its development is related to damages to large venous collectors with rigid walls preventing the collectors to collapse if the internal pressure is negative (e.g., cerebral sinuses) and to the presence of a pressure gradient leading the air being sucked into a venous collector. However, all of this does not coincide with our situation.

Reflex asystole directly affecting the vagus nerve is described for carotid endarterectomy, facial nerve plasty, and some other cervical spine surgeries. Severe bradycardia (up to the development of asystole) is a described complication of angioplasty and carotid stenting [24—28]; it can also occur during functional neurosurgical interventions [29]. Finally, asystole may occur at the stage of completing the neurosurgical intervention and be caused by the syndrome of excessive subgaleal drainage [30] or by the spontaneous intracranial hemorrhage in the area of surgical wound, leading to the compression of the brainstem [31]. All the aforementioned

clinical cases occur relatively rare but still they are described in the literature. However, these cases also have nothing to do with our clinical cases.

Finally, the drugs administered during anesthesia and surgery may also cause or stimulate asystole for various reasons. Opioid analgesics (especially opioid full agonists), such as fentanyl, sufentanyl, alfentanyl, and remifentanyl, can cause bradycardia via the well known central mechanism of vagus nerve stimulation [32]. However, this effect in our clinical situation may be regarded as only a contributing factor. Central alpha-2 adrenergic agonists (clonidine and dexmedetomidine) are regarded as another group of drugs which can cause asystole during surgery. For example, there are enough alarming publications regarding dexmedetomidine [33, 34]. Finally, we have found in the literature a case report on intraoperative asystole after adriamycin cytostatic administration during surgery [35]. However, our patients did not receive these drugs, except opioid analgesics (fentanyl) in relatively small doses.

None of the aforementioned causes of asystole that are described in the literature (except perhaps the herniation and impaction) clarify anything regarding our clinical observations. Consequently, the most likely explanation seems to be as follows. It is known that intubation of trachea is accompanied with a specific hemodynamic effects of varying severity, the so-called pressor response (PR), which is also associated with increased intracranial pressure [36]. It is also known that severe PR is a real risk factor for patients with severe cardiac insufficiency (there is the risk of acute decompensation) and cerebral aneurysms (there is the risk of aneurysm rupture) [37]. This list should apparently include neurosurgical patients with severe intracranial hypertension at the subcompensation and decompensation phases.

On the background of increasing systemic arterial pressure under PR, even a slightly increased cerebral blood flow can apparently induce that minimally increased level in intracranial pressure which may cause decompensation of the intracranial system and displacement of certain brain structures. This is evidenced by the autopsy report of the first patient. In addition, vagus nerve stimulation is likely to contribute to the development of asystole in our observations as well. The risk factors for asystole could include the administration of fentanyl (that can cause bradycardia) during induction of anesthesia and the nonuse of anticholinergic drugs during premedication. Despite the fact that the anesthetists took the necessary steps to stop PR in both observations (by applying the adequate dose of propofol, an opioid analgesic, and lidocaine during induction of anesthesia) and the intubation was performed quickly and was nontraumatic, it seems that the intracranial pressure reached that critical level that even slightly increased BP and cerebral blood flow caused the decompensation.

Interestingly, in one of the most large (22 case reports!) published series of clinical cases regarding asystole in neurosurgical patients, five patients had asystole at the stage of induction of anesthesia and at the beginning of the surgery, but still the authors recommend as follows: "... during resuscitation of a neurosurgical patient, it is of particular importance to perform timely measures aimed at reducing the intracranial pressure and preventing edema and brain swelling." [38].

External ventricular drainage used prior to anesthesia is still likely to be reasonable for patients with pronounced symptoms of occlusive hydrocephalus, especially after acute occlusive hydrocephalus occurring immediately prior to surgery, even if it was successfully stopped by drug administration.

REFERENCES

1. Gaba DM, Fish KJ, Howard SK. Crisis Management in Anesthesiology. Amsterdam: Elsevier 2014;432.
2. Pothiawala S. Spontaneous subarachnoid hemorrhage as a differential diagnosis of pre-hospital cardiac arrest. *Indian J Crit Care Med*. 2012;16(4):216-218. doi: 10.4103/0972-5229.106506.
3. Shorvon S, Tomson T. Sudden unexpected death in epilepsy. *Lancet*. 2011;378(9808):2028-2038. doi: 10.1016/S0140-6736(11)60176-1.
4. Dagnew E, van Loveren HR, Tew JM. Acute foramen magnum syndrome caused by an acquired Chiari malformation after lumbar drainage of cerebrospinal fluid: report of three cases. *Neurosurgery*. 2002;51:823-828. doi.10.1097/00006123-200209000-00043.
5. Oyelese AA, Steinberg GK, Huhn SL, Wijman CA. Paradoxical cerebral herniation secondary to lumbar puncture after decompressive craniectomy for a large space-occuping hemispheric stroke: case report. *Neurosurgery*. 2005;57:E594. doi:10.1227/01.neu.0000170437.79760.df .
6. Surgue PA, Hsieh PC, Getch CC, Batjer HH. Acute symptomatic cerebellar tonsilar herniation following intraoperative lumbar drainage. *J Neurosurg*. 2009;110:800-803. doi.10.3171/2008.5.17568.
7. Bahl CP, Wadwa S. Cardiovascular collapse after rapid ventricular decompression in hydrocephalus: a case report. *Br J Anaesth*. 1967;39:657-658. doi.10.1093/bja/39.8.657.
8. Kazantsev F.N., Zakirov E.Kh. Depolarizing muscle relaxants and cardiac arrest in neurosurgical patients. *Voprosy Neyrokhirurgii*. 1972;5:11-13. In Russian.
9. Gronert GA. Cardiac arrest after succinylcholine: mortality greater with rhabdomiolysis than receptor upregulation. *Anesthesiology*. 2001;94:523-529. doi.10.1097/00000542-200103000-00026.
10. Smith RB. Hyperkalemia following succinilcholine administration in neurological disorders: a review. *Can Anaesth Soc J*. 1971;18:199-201. doi.10.1007/bf03025450.
11. Jaiswal AK, Gupta D, Verma N, Behari S. Trigeminocardiac reflex: a cause of sudden asystole during cerebellopontine angle surgery. *J Clin Neurosci*. 2010;17:641-644. doi: 10.1016/j.jocn.2009.07.117.
12. Prabhakar H, Anand N, Chouhan RS, Bithal PK. Sudden asystole during surgery in cerebellopontine angle. *Acta Neurochir*. 2005;148:699-700. doi.10.1007/s00701-005-0712-2.

13. Usami K, Kamada K, Kunii N, Tsujihara H, Yamada Y, Saito N. Transient asystole during surgery for posterior fossa meningeoma caused by activation of trigeminocardiac reflex: three case reports. *Neurol Med Chir.* 2010;50:339-342. doi.org/10.2176/nmc.50.339.

14. Abou-Zeid AH, Davis JR, Kearney T, Gnanalingham KK. Transient asystole during endoscopic trenssphenoidal surgery for acromegaly: an example of trigeminocardiac reflex. *Pituitary.* 2008;12:373-374. doi.10.1007/s11102-008-0118-2.

15. Cho JM, Min KT, Kim EH, Oh MC, Kim SH. Sudden asystole due to trigaminocardiac reflex during transsphenoidal surgery for pituitary tumor. *World Neurosurg.* 2011;76:477. doi.10.1016/j.wneu.2011.01.043.

16. Lubbers HT, Zweifel D, Gratz KW, Kruse A. Classification of potencial risk factors for trigeminocardiac reflex in craniomaxillofacial surgery. *J Oral Maxillofac Surg.* 2010;68:1317-1321. doi.10.1016/j.joms.2009.12.039.

17. Konovalov A.N., Lubnin A.Yu., Oskanova M.Yu. Massive recurrent venous air embolism in a female patient with brainstem cavernoma, who was operated in a sitting position (case report). *Voprosy Neyrokhirurgii.* 2001;2:21-23. In Russian.

18. Lubnin A.Yu. Recurrent massive air embolism in a male patient operated in a sitting position. *Anesteziologiya i reanimatologiya.* 1991;4:36-37. In Russian.

19. Lubnin A.Yu., Oskanova M.Yu. Air embolism during neurosurgical interventions. *Voprosy neyrokhirurgii.* 1995;4:33-38. In Russian.

20. Albin MS. *Textbook of Neuroanesthesia: With Neurosurgical and Neuroscience Perspectives*. New York City: McGraw-Hill Professional. 1996;1433.

21. McCarthy RE, Lonstein JE, Mertz JD, Kuslich SD. Air embolism in spinal surgery. *J Spin Disord.* 1990;3:1-5. doi.10.1097/00002517-199003000-00001.

22. McDouall SF, Shlugman D. Fatal venous air embolism during lumbar surgery: the tip of iceberg? *Eur J Anaesth.* 2007;24:803-805. doi.10.1017/s0265021506002201.

23. Sutherland RW, Winter RJ. Two cases of fatal air embolism in children undergoing scoliosis surgery. *Acta Anaesth. Scand.* 1997;41:1073-1076. doi.10.1111/j.1399-6576.1997.tb04839.x.

24. Cayne NS, Faries PL, Trocciola SM, Saltzberg SS, Dayal RD, Clair D, Rockman CB, Jacobowitz GR, Maldonado T, Adelman MA, Lamperello P, Riles TS, Kent KC. Carotid angioplasty and stent-induced bradycardia and hypotension: Impact of prophylactic atropine administration and prior carotid endarterectomy. *J Vasc Surg.* 2005;41:956-961. doi.10.1016/j.jvs.2005.02.038.

25. Mylonas SN, Moulakakis KG, Antonopoulos CN, Kakisis JD, Liapis CD. Carotid artery stenting-induced hemodynamic instability. *J Endovasc Ther.* 2013;20:48-60. doi.10.1583/12-4015.1.

26. Nano G, Dalainas I, Bianchi P, Stegher S, Bet L, Malacrida G, Tealdi DG. Balloon-induced bradicardia during carotid stenting in primary stenosis and restenosis. *Neuroradiology.* 2006;48: 533-536. doi.org/10.1007/s00234-006-0096-x.

27. Pappada G, Beghi E, Marina R, Agostoni E, Cesana C, Legnani F, Parolin M, Petri D, Sganzerla EP. Hemodynamic instability after extracranial carotid stenting. *Acta Neurochir.* 2006;148:639-645. doi.10.1007/s00701-006-0752-2.

28. Quereshi AI, Luft AR, Sharma M, Janardhan V, Lopes DK, Khan J, Guterman LR, Hopkins LN. Frequency and determinants of postprocedural hemodynamic instability after carotid angioplasty and stenting. *Stroke.* 1999;30:2086-2093. doi.10.1161/01.str.30.10.2086.

29. Brisman R. Complications of intracranial pain surgery. In: Post K.D., Friedman E., McCormic P. (Eds.). *Postoperative complications in intracranial neurosurgery*. Thieme (NY). 1993;181-206.

30. Byagat H, Mangal K, Jain Amit, Sinha R, Mallik V, Gupta SK, Sethi S. Asystole following craniotomy closure: Yet another complication of negative pressure suctioning of subgaleal drain. *Indian J Anaesth.* 2012;56:304-305. doi.10.4103/0019-5049.98787.

31. Tyler DS, Bacon D, Mahendry V, Lema MJ. Asystole as a neurologic sign. *J Neurosurg Anesth.* 1997;9:29-30. doi.10.1097/00008506-199701000-00009.

32. Schafer M. Mechanism of action of opioids. In: Evers A.S., Maze M., Kharasch V.D. (Eds.). *Anesthetic pharmacology*. 2nd ed. Cambridge University Press 2011;493-508.

33. Bharati S, Pal A, Biswas C, Biswar R. Incidence of cardiac arrest increases with the indiscriminate use of dexmeditomedine: a case series and review of published case reports. *Acta Anaesthesiol.* (Taiwan). 2011;49:165-167. doi.10.1016/j.aat.2011.11.010.

34. Gerlach AT, Murphy CV. Dexmedetomedine-associated bradicardia progressing to pulseless electrical activity: case report and review of the literature. *Pharmacotheraphy.* 2009;29:1492. doi.10.1592/phco.29.12.1492.

35. Chander B, Bhagat H, Prabhakar H. Adriamycin induced pulseless electrical activity and cardiovascular collapse during general anesthesia for ventriculo-peritoneal shunt insertion. A case report. *Middle East J Anesthesiol.* 2008;19:841-846.

36. Latto IP, Rosen M. Difficulties in Tracheal Intubation. London: Bailliere Tindall 1987.

37. Lubnin A.Yu., Shishkina L.V., Filatov Yu. M., Salalykin V.I. Intracranial aneurysm rupture during intubation of trachea. *Voprosy neyrokhirurgii.* 1990;5:38-39. In Russian.

38. Salalykin V.I., Fedorov S.N. Experience in cardiac resuscitation in neurosurgical patients. *Voprosy neyrokhirurgii.* 1966;3:51-54. In Russian.

Commentary

In the given study, the authors presented their own experience regarding two clinical cases of hemodynamic instability in neurosurgical patients during surgery. Despite the development of pharmacology and the use of modern methods of intraoperative monitoring, the issue of cardiac arrest at various stages of anesthesia remains extremely problematic. For preventing the anesthesia-induced complications, algorithms of preoperative management and examination of the patient are developed and different anesthesia-related risk scales are used. However, even the strict observance of all pre- and intraoperative algorithms of patients' management does not exclude the possibility of a sudden cardiac arrest.

Clinical cases presented by the authors describe the dramatic events occurring during anesthesia in neurosurgical patients. Despite the different nosology, both cases were appropriately united for a joint analysis of a clinical situation. In both patients, hemodynamic instability and the development of asystole were detected on the background of a stable state during preparation for surgery. Despite the resuscitation, the first patient died; in the second case, all emergency actions were timely and effective, which even enabled continuing the surgery. In the second patient, overall clinical outcome was favorable.

In the discussion, the authors presented a comprehensive and accurate analysis of the preoperative management of patients and analyzed the possible factors of sudden cardiac arrest. The main possible factors causing hemodynamic instability in patients without cardiac pathology are exhaustively specified. On the basis of clinical data analysis and autopsy reports, the authors concluded that the cause of sudden cardiac

arrest in the presented patients is the pressor response to procedures and then the subsequently increased intracranial pressure and displacement of the brain.

In my opinion, the authors were close to the truth in their conclusions. A few hours before surgery, the patients had episodes of aggravated clinical symptoms of brain herniation, which were effectively stopped by pharmacological methods. The initial cause of patients' health impairment was likely not so much the pressor response during procedures. In my opinion, placing the patient in the recumbent position in bed and on the operating table during intubation and preparation for surgery was more significant cause. In patients with signs of intracranial hypertension that already occurred due to transfer a patient in the recumbent position, changes in intracranial pressure gradients and disturbance of venous outflow from the cranial cavity may occur, which can induce (along with hemodynamic changes) displacement and impaction of the cerebral structures. Brain herniation was confirmed by the autopsy report of the deceased patient. In the early stages of anesthesia during procedures, a possible solution to the problem could have been measures aimed at the correction of intracranial hypertension, i.e. the patient's head end should have been raised, hyperosmolar solutions should have been used, and ventricular drainage should have been applied early. (Probably, ventriculostomy and ventricular drainage should have been performed at the very first clinical signs of occlusive intracranial hypertension on the night before the surgery.) Neuroimaging could have probably helped in the decision (CT and/or MRI signs of brain herniation and progression of hydrocephalus). Timely detection of risks of intracranial hypertension and displacement of the brain structures, as well as measures aimed at preventing high intracranial pressure can help to avoid hemodynamic instability at various stages of anesthesia.

In the study, the authors describe a very significant problem in anesthesiology; the article is easy to read, but also requires us to reflect on the way of solving the particular clinical situation. Although the article is relatively short, it includes a detailed analysis of the possible causes of intraoperative cardiac arrest. Given the extensive experience of the authors, I wish them to share more often their priceless observations with colleagues.

The article can be useful not only for anesthesiologists, resuscitation specialists, and neurosurgeons, but also for all specialists involved in the treatment of neurosurgical patients.

A.A. Solodov (Moscow, Russia)